Evaluation of living related kidney donors using digital subtraction angiography[1]

Stuart M. Flechner, M.D.
Carl M. Sandler, M.D.
Yoram Ben-Menachem, M.D.
Charles T. Van Buren, M.D.
Barry D. Kahan, M.D.

Digital subtraction angiography (DSA) was incorporated into the initial radiographic evaluation of 51 potential living related kidney donors. Forty-nine patients underwent combined DSA and excretory urography, and 2 patients underwent staged studies. Each of the 51 patients also underwent nephrectomy to confirm the accuracy of the DSA images for identification of the number of renal vessels to the donor kidney. In the entire series, 35 donors (69%) had bilateral single renal arteries, and 16 donors (31%) had multiple vessels on at least one side. Six patients (11.7%) required the performance of standard catheter angiography due to inadequate DSA studies. Of the 45 patients who underwent DSA alone, 44 had a single renal artery as verified during surgery (accuracy rate, 98%). Thus, potential donors can be spared the risks of standard catheter angiography in most cases and can be fully evaluated on an outpatient basis.

Index terms: Angiography • Kidney, transplantation • Subtraction technic

Cleve Clin Q 51:339–343, *Summer* 1984

With the untimely passing of Dr. Bruce H. Stewart, the urologic community has lost a great innovator, educator, and practitioner. His free-spirited and direct approach to difficult clinical problems was a sterling example for all of his students. It is appropriate that this report describes an innovative approach to the radiographic evaluation of potential living related kidney donors. Dr. Stewart, one of the early practitioners of clinical renal transplantation, taught many Cleveland Clinic fellows the technique of living related donor nephrectomy.[1] His description of a

[1] Departments of Surgery (S.M.F., C.T.V.B., B.D.K.) and Radiology (C.M.S., Y.B-M.), The University of Texas Medical School at Houston. (Address reprint requests to: S.M.F., Dept. of Surgery, Division of Organ Transplantation, The University of Texas Medical School at Houston, 6431 Fannin, Suite 6018, Houston TX 77030.) Submitted for publication Dec 1983; accepted Jan 1984. sb

0009-8787/84/02/0339/05/$2.25/0

Copyright© 1984, The Cleveland Clinic Foundation.

Downloaded from www.ccjm.org on April 17, 2024. For personal use only. All other uses require permission.

cost-effective, noninvasive evaluation of patients with a pheochromocytoma is followed in many medical institutions today.[2]

Digital subtraction angiography, performed with an intravenous injection of iodinated contrast material (IV-DSA), is a modality that uses computer processing to enhance image clarity. This technique appears to be less invasive and more cost effective than standard catheter angiography. A prospective study was performed in our center to compare IV-DSA and standard angiography for the evaluation of living related kidney donors.[3] The accuracy of IV-DSA, established in the prospective study, has led to the use of this technique as the principal imaging method to evaluate potential donors.

Materials and methods

Fifty-one consecutive potential donors (29 men, 22 women; age range, 21–59 yrs old) were selected for evaluation based on the immunologic assessment of donor-recipient compatiblity (ABO and tissue type, as well as a mixed lymphocyte culture). Prior to the radiologic evaluation, each potential donor was screened for metabolic, infectious, congenital, systemic, or psychologic pathology that would preclude organ donation. If these evaluations were satisfactory, a radiologic examination of the urinary tract was performed. Scout views of the abdomen and pelvis were obtained routinely. Next, a 6.5-F pigtail-shaped catheter was positioned in the right atrium via a percutaneous antecubital or transfemoral approach. Glucagon (1 mg) was administered through the catheter at the beginning of the procedure to reduce gastrointestinal peristalsis. The angiographic studies were then performed using a commercially available unit (from ADAC Laboratories, 255 San Geronimo Way, Sunnyvale CA 94086) fitted with a 12-in image intensifier. After an injection of contrast media (Renografin-76, Squibb & Sons, Inc., P.O. Box 4000, Princeton NJ 08540) at a rate of 25–35 mL/sec for a total volume of 40–50 mL, the initial imaging series (anteroposterior projection) was obtained. The routine imaging sequence included one image per second for five seconds, two images per second for five seconds, and one image per second for 10 seconds. Additional image series were obtained, either using a posteroanterior or a slightly oblique (right or left posterior) projection, when the information yielded by the first series was not entirely adequate (i.e., when mesenteric vessels were superimposed over a renal artery). When a satisfactory IV-DSA series was completed, an additional 50 ml of contrast material was administered through the catheter prior to its removal in final preparation for excretory urography.

The patient was then transferred by stretcher to an adjacent uroradiology suite where 14 × 17-in full abdominal images were obtained. Abdominal views were obtained with and without the use of compression. A series of three tomographic sections of the kidneys were also obtained. These images, together with the scout views, obtained before the performance of IV-DSA, constituted the excretory-urography portion of the examination.

Each of the 51 potential donors underwent surgical nephrectomy, and the number of arterial vessels in the donor organ was verified. If the two organs were anatomically similar, the left kidney was removed due to the longer renal vein and ease of reimplantation. The kidney with a single renal artery was used if the contralateral organ had multiple vessels. The smaller of the two kidneys was used if the renal length, according to the anteroposterior projection, differed by more than 2 cm. A kidney with a congenital anomaly, ptosis, or cyst was used in preference to the normal-appearing opposite.

Results

The radiologic examination of the urinary tract was successfully completed in 51 patients. Forty-nine of the 51 underwent combined IV-DSA and excretory urography without complications. Two donors, whose recipients had adult polycystic kidney disease, underwent separate screening excretory urography and computed tomography prior to IV-DSA. A single series (anteroposterior projection) was adequate to image the kidneys in 19 patients (37%). Two series (anteroposterior and oblique projections) were adequate for 27 patients (53%). Three series (anteroposterior and posteroanterior or oblique projections) were required for 5 patients (10%).

Using the 12-in camera, IV-DSA usually demonstrated both renal outlines and the abdominal aorta from the level of the diaphragm to the aortic bifurcation (*Fig. 1*). The later images visualized the renal veins and a portion of the inferior vena cava (*Fig. 2*). In most studies, the main renal arteries and first-order branches were seen, but rarely were intraparenchymal vessels distinguished.

Standard transfemoral catheter angiography

Downloaded from www.ccjm.org on April 17, 2024. For personal use only. All other uses require permission.

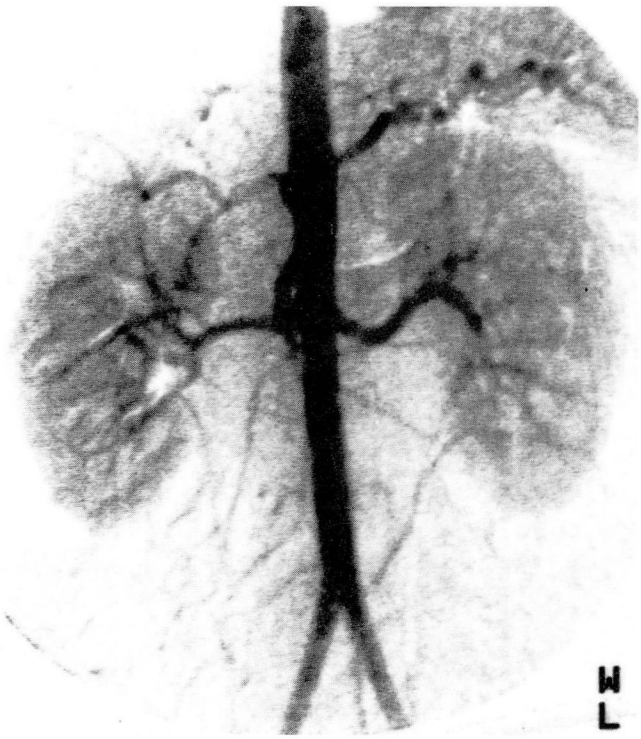

Fig. 1. Angiogram (anteroposterior projection) reveals bilateral single renal arteries. The aorta is visualized from the diaphragm to the bifurcation of the iliac arteries.

was required in 6 of the 51 donors (11.7%). In 3 patients (5.8%), the IV-DSA images were suboptimal because of either patient or bowel motion or overlying bowel gas (*Fig. 3*). In an additional 3 patients (5.8%), catheter angiography was required to confirm the presence of multiple renal vessels which were obscured by superimposed

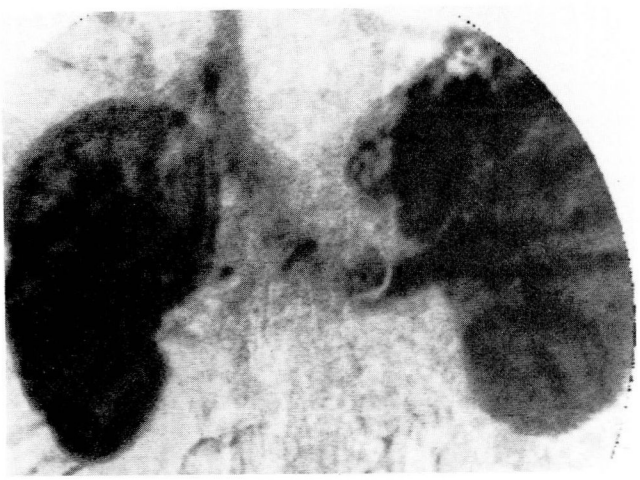

Fig. 2. Later phase of the IV-DSA study. The image shows the renal veins and a portion of the inferior vena cava.

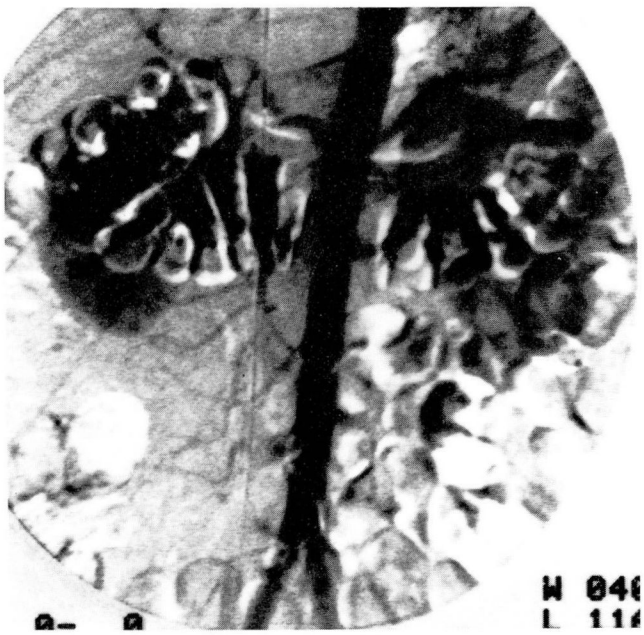

Fig. 3. This angiogram is inadequate due to patient and bowel motion.

mesenteric branches on the IV-DSA views. In the entire series, 35 donors (69%) had bilateral single renal arteries and 16 donors (31%) had multiple vessels on at least one side (*Table*); this included 15 patients with double renal arteries (*Fig. 4*) to at least one kidney, and 1 patient with three renal arteries.

A total of 34 left kidneys and 17 right kidneys were removed, each with a single renal artery demonstrated by preoperative angiography. In 45 patients, only IV-DSA was used to image the renal vasculature. A single renal artery was found in 44 patients during nephrectomy for an accuracy rate of 98%. A second renal artery, not imaged by IV-DSA, was found in one patient (*Fig. 5*). A microvascular end-to-side anastamosis of the branch to the main renal artery was necessary. The 6 patients who required standard catheter angiography in addition to IV-DSA also had single renal arteries; this was verified during surgery.

Table. Frequency of multiple vessels in potential kidney donors as determined by angiography*

Number of vessels	Left kidney	Right kidney
1	40	46
2	10	5
3	1	0
TOTAL	51	51

* In this series, 31% (16/51) of all patients had multiple vessels.

Downloaded from www.ccjm.org on April 17, 2024. For personal use only. All other uses require permission.

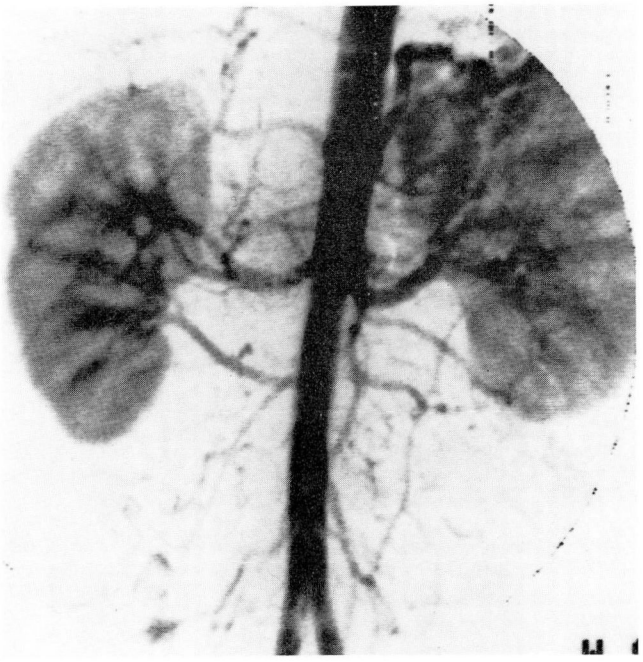

Fig. 4. This potential donor had two right renal arteries. The left kidney, which was used for the transplantation, had a single left renal artery.

Discussion

Renal transplantation from a healthy, well-motivated, and immunologically compatible living related donor is preferred for patients with end-stage renal disease. Potential donors require a thorough evaluation to disclose any underlying medical or psychologic conditions which could impair their future health. An important part of this process is the radiologic evaluation of the urinary tract, which is required to disclose the number, size, position, and structure of the renal units, as well as the number of renal vessels. In the past, this information has been determined by excretory urography, and on a separate day, abdominal midstream aortography with or without selective renal artery injections. To perform angiography, patients may require intravenous hydration, six to eight hours of observation after the study, and may suffer one of several, although infrequent, complications as described by Kincaid.[4] In most hospitals, angiography requires one to two days of hospitalization.

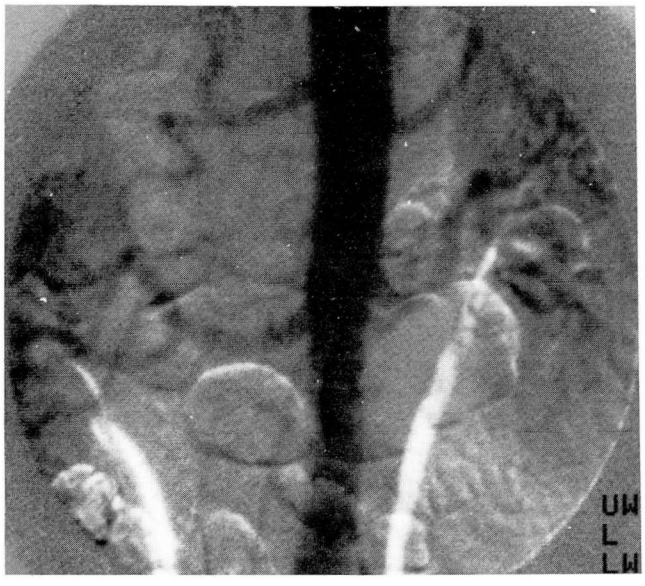

Fig. 5. This patient had two left renal arteries and a single right artery initially identified by IV-DSA. The right kidney was removed and found to have an additional lower pole vessel which was partially obscured on the angiogram by bowel gas.

The utility of digital subtraction angiography for the evaluation of the renal vasculature has been described.[5,6] Prospective comparisons with the results of standard catheter angiography when screening for main renal artery lesions have revealed a greater than 95% accuracy rate.[7,8] A pilot study performed at the University of Texas Medical School confirmed the accuracy of IV-DSA for the evaluation of the potential living related kidney donor.[3] We used catheter angiography when IV-DSA studies were inadequate or equivocal. By using this format, 88% (45/51) of the potential donors described here did not undergo invasive angiography. In the entire series, 98% (50/51) of the kidneys removed proved to have a solitary renal artery. The frequency of patients with multiple renal vessels (31% [16/51]) was comparable to other reported series,[9] and the results obtained with IV-DSA were similar to those reported when only catheter angiography was performed.[10,11] In addition, no aortic or renal parenchymal abnormality was missed.

The major cause of IV-DSA inaccuracy is due to the superimposition of mesenteric vessels over the renal outline. Since contrast material is administered intravenously, the abdominal vessels are opacified as shown on a single exposure (anteroposterior projection). The performance of IV-DSA and the subsequent interpretation of the images have improved at our center with the use of the larger 12-in image intensifier and a more frequent use of oblique projections. Vessel overlap as a cause of error when evaluating live donors has been reported,[12] but would have been obviated if oblique projections had been employed. Misinterpretation of standard catheter

Downloaded from www.ccjm.org on April 17, 2024. For personal use only. All other uses require permission.

angiograms can also occur without the use of oblique projections. Another cause of inadequate studies is the inability of the patient to suspend respiration. Hyperactive peristalsis, which may be minimized by administering glucagon, can also degrade image clarity.

The advantages of IV-DSA as compared to standard catheter angiography include diminished invasiveness, decreased cost, and the ability to perform the study at the same time as excretory urography. In addition, these radiologic evaluations can be performed completely on an outpatient basis, decreasing the cost of the evaluation and minimizing time off from work for the donor. The potential complications of catheter angiography can be avoided in most patients, providing an added degree of safety. Further advances in technology, such as increased framing rates and improved computer subtraction, may minimize the use of catheter angiography even further.[13] Nevertheless, the occasional unusual anatomy with multiple or ectopic vessels may require a selective catheter angiographic study; this should be necessary in less than 10% of all patients. Accessory vessels that are less than 1mm in diameter may be missed with any radiologic evaluation. Yet, these vessels invariably supply less than 5% of the renal parenchyma and their preservation during surgery is not crucial.

Conclusion

IV-DSA combined with excretory urography is effective for the evaluation of the renal anatomy of potential living related donors. We no longer perform catheter angiography routinely. When determining the number and position of main renal arteries, the resulting accuracy of IV-DSA is comparable to that obtained when performing midstream abdominal aortography. The use of IV-DSA should permit the donor evaluation to be performed completely on an outpatient basis.

References

1. Stewart BH, Hewitt CB, Kiser WS, Straffon RA. Anterior transperitoneal operative approach to the kidney. Cleve Clin Q 1969; **26:**123–131.
2. Stewart BH, Brown EL, Haaga J, Meaney TF, Tarazi R. *Localization of pheochromocytoma by computed tomography.* New Engl J Med 1978; **299:**460–461.
3. Flechner SM, Rauschkolb EN, Cohen G. Use of digital subtraction angiography for the evaluation of living related renal transplant donors. Transplantation 1982; **33:**645–647.
4. Kincaid OW. Technics and hazards of renal angiography. [In] Kincaid OW, Davis GD, eds. Renal Angiography. Chicago, Yearbook, 1976, pp 36–76.
5. Buonocore E, Meaney TF, Borkowski GP, Pavlicek W, Gallagher J. Digital subtraction angiography of the abdominal aorta and renal arteries: comparison with conventional aortography. Radiology 1981; **139:**281–286.
6. Hillman BJ, Ovitt TW, Capp MP, et al. The potential impact of digital video subtraction angiography on screening for renovascular hypertension. Radiology 1982; **142:**577–579.
7. Clark RA, Alexander ES. Digital subtraction angiography of the renal arteries: prospective comparison with conventional arteriography. Invest Radiol 1983; **18:**6–10.
8. Osborne RW Jr, Goldstone J, Hillman BJ, Ovitt TW, Malone JM, Nudelman S. Digital video subtraction angiography: screening technique for renovascular hypertension. Surgery 1981; **90:**932–938.
9. Spring DB, Salvatierra O Jr, Palubinskas AJ, Amend WJC Jr, Vincenti FG, Feduska NJ. Results and significance of angiography in potential kidney donors. Radiology 1979; **133:**45–47.
10. Sherwood T, Ruutu M, Chisholm GD. Renal angiography problems in live kidney donors. Br J Radiol 1978; **51:**99–105.
11. Strauser GD, Stables DP, Weil R III. Optimal technique of renal arteriography in living renal transplant donors. AJR 1978;**131:**813–816.
12. Rabe FE, Smith EJ, Yune HY, Klatte EC, Leapman SB, Filo RS. Limitations of digital subtraction angiography in evaluating potential renal donors. AJR 1983; **141:**91–93.
13. Riederer SJ, Kruger RA. Intravenous digital subtraction: a summary of recent developments. Radiology 1983; **147:**633–638.

Downloaded from www.ccjm.org on April 17, 2024. For personal use only. All other uses require permission.