

Fibrodysplasia ossificans progressiva presenting as fibrous scalp nodules¹

Greta S. McFarland, M.D.
Bernard Robinowitz, M.D.
Burhan Say, M.D.

An infant with subcutaneous nodules was diagnosed as having congenital generalized fibromatosis based on the histopathological examination. During the child's first year of life, additional symptoms developed which were compatible with a diagnosis of fibrodysplasia ossificans progressiva; this was later confirmed radiologically.

Index terms: Case reports • Fibroma, congenital • Myositis ossificans, pathology

Cleve Clin Q 51:549-552, Fall 1984

Fibrodysplasia ossificans progressiva (FOP) is a disorder of the connective tissue characterized by early transient subcutaneous lesions, progressive calcification, and decreased mobility. We report a young child with the clinical and radiological diagnosis of FOP who presented with subcutaneous nodules at 3½ months of age. These subcutaneous lesions were benign proliferations of fibroblasts similar histologically to the lesions of congenital generalized fibromatosis (CGF).

¹ Tulsa Medical College, University of Oklahoma. This paper was presented in part at the American Academy of Dermatology Meeting during the presentations made by the Society of Dermatologic Genetics, December 7, 1982, in New Orleans. Submitted for publication Jan 1984; revision accepted June 1984.

Dr. Robinowitz was a resident in dermatology (1971-1975) at the Cleveland Clinic. jw

0009-8787/84/03/0549/04/\$2.00/0

Copyright © 1984, The Cleveland Clinic Foundation

Case report

A white boy was the product of a term pregnancy of a 19-year-old gravida 2, para 2 mother. The father was 29 years old. During the first trimester, the mother had a "viral" illness with symptoms of vomiting, diarrhea, and chills. At that time, she had been exposed to organic chemicals (type unknown) for two weeks. During the sixth month of gestation, she was thought to have encephalitis, though this was never confirmed. The labor and vaginal delivery were normal. The infant's birth weight was 3,400 g, and his length was 56 cm. At two months of age, he was hospitalized for evaluation of nodules. Numerous lesions were located over the left temporal bone, with several others over the entire skull. Studies included a computed-tomographic scan of the head, a chest radiograph, VDRL, liver studies, a urinalysis, and a complete blood count. In all instances, the results were normal. A biopsy specimen of one of the scalp lesions was interpreted as a benign fibroma. When the patient was six months of age, his head demonstrated right-sided deviation. An orthopedic evaluation at that time included cervical spine radiographs showing posterior arch abnormalities in C-1, C-2, and C-3; the latter two appeared to be almost fused. A diagnosis of Klippel-Feil syndrome was suggested. Additional congenital anomalies noted when the patient was nine months old included mild facial asymmetry, with the left side being larger than the right. Hallus valgus was noted (Fig. 1). Increased space between the fourth and fifth toes, as well as cutaneous syndactyly of the second and third toes, was seen bilaterally. His development status at nine months of age revealed bilateral hallux valgus, associated with almost complete proximal phalanx fusion to the first metatarsal—a finding frequently seen in FOP.¹ The middle phalanx of the fifth fingers bilaterally appeared hypoplastic. The thumbs were also hypoplastic. Spur-like projections were noted from the proximal left humerus, the proximal left femur, and the calcaneus. The thoracic spine showed a small amount of calcification between two of the spinous processes, confirming the clinical diagnosis of FOP.

The multiple subcutaneous scalp nodules continue to

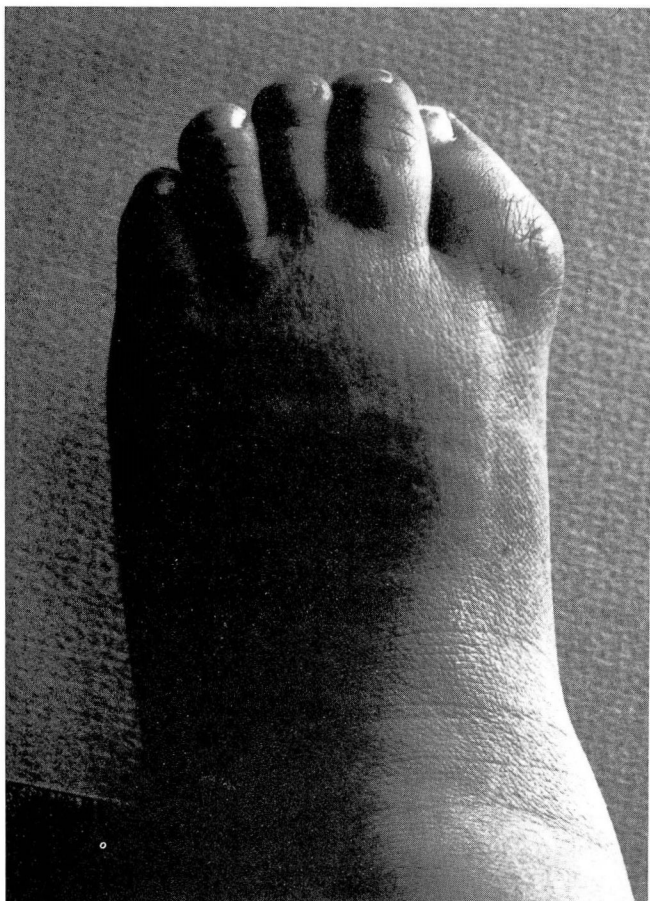


Fig. 1. Hallux valgus.

form, then regress. There is no identifiable pattern to their cycle or location, although they occur only on the head and neck. The family history is negative.

Histopathology

The lesion, which was biopsied when the child was 3½ months old, was a nonencapsulated, circumscribed proliferation of fibrous tissue. Both the dermis and subcutaneous tissue were involved, and the lesion's borders appeared lobulated (*Fig. 2*). The pattern consisted of benign-appearing fibrocytes in whirls. Three different cellular patterns were noted: areas of bland necrosis, areas wherein cells had abundant amphophilic cytoplasm and elongated nuclei (suggesting smooth muscle differentiation), and areas mimicking neurofibromas. Thin-walled vascular channels were present throughout the lesion. The nuclei were ovoid or elongate with vesicular or stippled chromatin. The cytoplasm was eosin-

ophilic. Mitotic figures were rare, and no multinucleated giant cells were noted. The cell borders in general were indistinct. All of these findings were characteristic of benign fibroblastic proliferation, as seen in CGF.

Discussion

Congenital fibromatosis is an incompletely understood group of disorders. In 1965, Kauffman and Stout² divided the fibromatoses into three groups: solitary lesions, multiple congenital fibromatosis, and CGF. They considered multiple congenital fibromatosis to be limited to the subcutaneous tissue, with occasional bone involvement. The lack of visceral involvement separated this entity from CGF. In 1980, Briselli et al³ suggested that the original term, CGF, be used for all lesions with characteristic histopathology and that recognition be given to the importance of specific organ involvement when determining the prognosis. They found the lesions of CGF in their study to be well-circumscribed with smooth or slightly lobulated borders. Some areas of the biopsy resembled neurofibromas, fibrosarcomas, or hemangiopericytomas. Densely cellular areas were interspersed with more hypocellular areas. Nuclei were elongated, had stippled chromatin, and had an abundant amphophilic hyalin-like appearance. Another common finding was bland necrosis with stippled calcification. Multinucleated cells were uncommon. Pathological mitoses were absent. The histopathologic findings of our patient's early subcutaneous lesions were similar to those of lesions seen in CGF. Both are characterized by the benign proliferation of fibroblasts.^{1,3}

According to Ryan,⁴ FOP was first reported in 1692. The onset of the disease is usually before the age of 10 years, with swellings located on the neck and back. These swellings may be cystic and/or fluctuant. The lesions disappear and then return. Eventually, they calcify. With time, the calcification affects the entire body, leading to immobility and sometimes death in the third or fourth decade. As reported by Cramer et al,⁵ the late histopathology is characterized by nodules of multifocal, interconnecting, spindle-shaped fibroblast-like cells. Bone spicules are noted centrally. Ossification also starts centrally.

In our case, the diagnosis of FOP was suspected

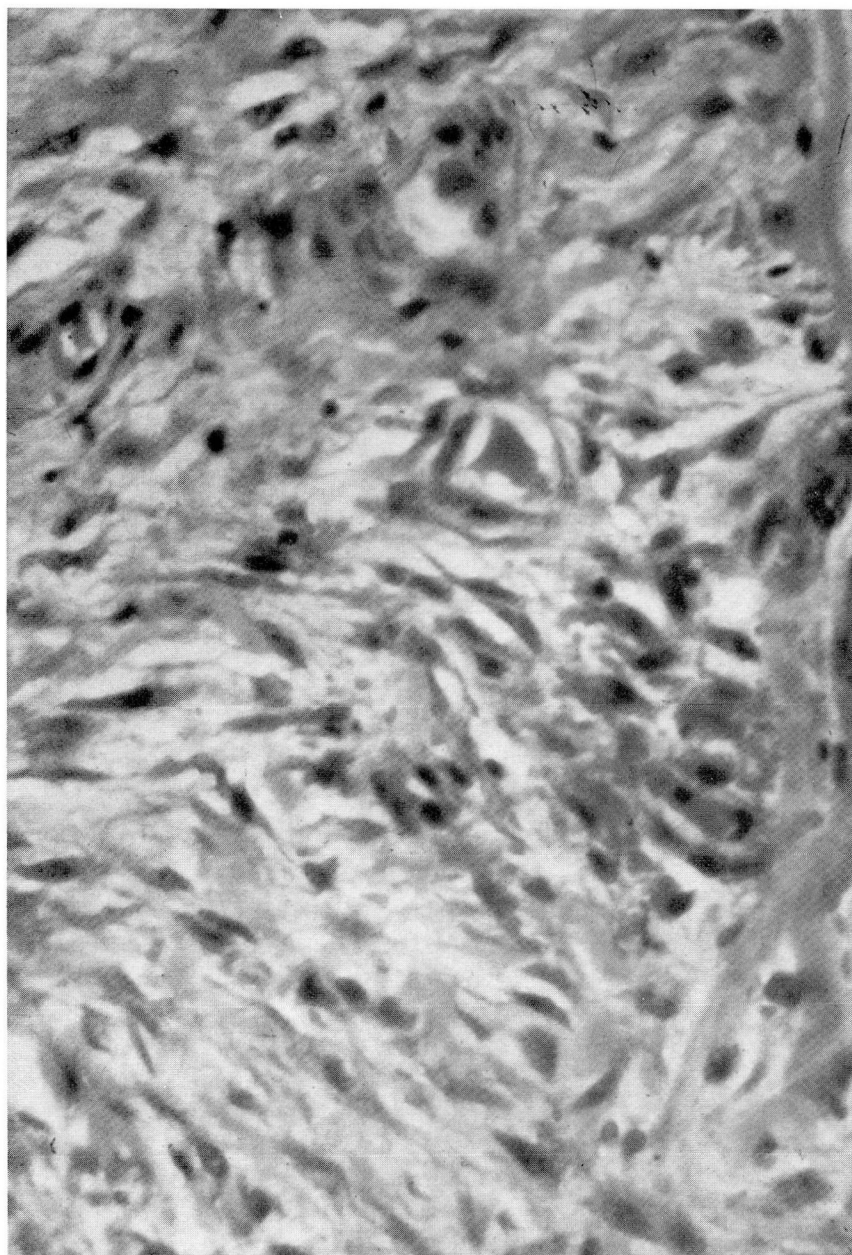


Fig. 2. High-powered photomicrograph of the occipital lesion, showing tumors in the dermis and subcutaneous tissue (hematoxylin-eosin stain, $\times 250$).

on clinical grounds, but the final diagnosis was established by radiography. The malformations of FOP in the earliest stages are best identified radiographically. The early findings are bilateral shortening of the fingers, absence of the thumbs and great toes, and digital deviations, especially bilateral hallus valgus. During the later stages of

the disease, bony bridges are noted within muscles and tendons, and finally, contractures and ankylosis of the shoulder, elbow, and other joints occur.

When evaluating a child with benign fibrous scalp nodules, a radiographic examination should be part of the workup.

Acknowledgments

We wish to thank Peter Lazarus, M.D., for referring this patient and Andrew K. Poznanski, M.D., Radiologist-in-Chief, Children's Memorial Hospital, Chicago, for his assistance in confirming the diagnosis.

Bernard Robinowitz, M.D.
6565 S. Yale
Tulsa OK 74144

References

1. Enzinger FM, Weiss SW. Soft Tissue Tumors. St. Louis, CV Mosby, 1983, pp 729-733.
2. Kauffman SA, Stout AP. Congenital mesenchymal tumors. *Cancer* 1965; **18**:460.
3. Briselli MF, Soule EH, Gilchrist GS. Congenital fibromatosis. Report of 18 cases of solitary and 4 cases of multiple tumors. *Mayo Clin Proc* 1980; **55**:554-562.
4. Ryan KJ. Myositis ossificans progressiva: review of literature with report of a case. *J Pediatr* 1945; **27**:348-352.
5. Cramer SF, Ruehl A, Mandel MA. Fibrodysplasia ossificans progressiva: a distinctive bone-forming lesion of the soft tissue. *Cancer* 1982; **48**:1016-1021.