

Extracorporeal renal surgery and autotransplantation for complicated stone disease¹

Andrew C. Novick, M.D.

Most patients with extensive renal calculous disease can be managed satisfactorily by percutaneous or in situ surgical techniques. However, in selected patients with advanced nephrolithiasis in whom prior surgical therapy has failed, extracorporeal renal lithotomy and/or autotransplantation may provide the best method of achieving complete stone removal and unobstructed urinary drainage from the upper urinary tract. The most common indications for this approach are recurrent nephrolithiasis with stenosis of the renal pelvis or ureter, recurrent renal colic, and extensive ureteral loss following prior operative therapy. In all cases, close postoperative follow-up, with prevention of infection and treatment of metabolic disorders, is integral to successful long-term management.

Index terms: Kidney calculi, therapy • Kidney, surgery • Kidney, transplantation

Cleve Clin Q 52:21–26, Spring 1985

¹ Section of Renal Transplantation, Department of Urology, The Cleveland Clinic Foundation. Submitted for publication Aug 1984; accepted Nov 1984.

0009-8787/85/01/0021/06/\$2.50/0

Copyright © 1985, The Cleveland Clinic Foundation

There is little doubt that most patients who require removal of renal calculi can be treated successfully with percutaneous or in situ surgical techniques. Nevertheless, extracorporeal surgery and autotransplantation may occasionally be useful in managing selected patients with advanced renal calculous disease.¹ In general, these are patients with recurrent calculi and a history of surgical therapy. In some cases, it is possible to remove the calculi while leaving the kidney in its native location and the primary rationale for performing autotransplantation is to ensure unobstructed drainage of urine and/or passage of recurrent calculi from the upper urinary tract to the bladder.

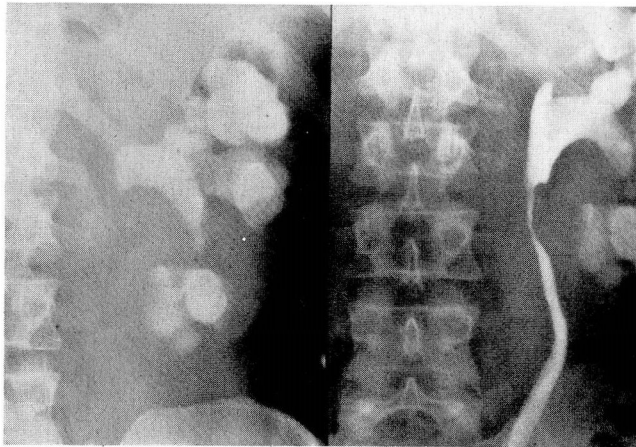


Fig. 1. A plain radiograph (left) shows a recurrent staghorn calculus in a 43-year-old man with a solitary left kidney. An intravenous pyelogram (right) demonstrates a stricture of the upper ureter caused by fibrosis following a prior operation. Extracorporeal pyelolithotomy and autotransplantation were performed.

The advantages of performing extracorporeal renal surgery include optimal exposure and illumination, a bloodless surgical field, greater protection of the kidney from ischemia, easier employment of microvascular techniques and optical magnification, facilitation of nephroscopy, superiority of extracorporeal roentgenography for detection of retained calculi, and the ability to extract difficult stones under direct fluoroscopy. In the case of repeat surgery involving extensive perihilar fibrosis, the ureter and renal pelvis can be dissected meticulously while preserving their blood supply and avoiding injury to major arterial or venous branches. Also, removing and flushing the kidney causes it to contract, thereby facilitating more peripheral intrasinusoidal exposure for extended pyelolithotomy. This may obviate the need for nephrotomy incisions that would otherwise be required to achieve complete stone removal in situ.

Autotransplantation of kidneys with severe parenchymal disease should be avoided. Such kidneys generally flush poorly following their removal, which could result in irreversible ischemic damage with lack of function postoperatively. Also, autotransplantation may not be possible when severe atherosclerotic disease renders the iliac arteries unsuitable for anastomosis to the renal artery. This determination can be made through preoperative pelvic arteriography, which should be adjunctively performed with preliminary renal arteriography in such cases.

Specific indications

Recurrent nephrolithiasis with stenosis of the renal pelvis or ureter

Some patients with recurrent nephrolithiasis will have associated fibrotic obstruction of the renal pelvis and/or upper ureter as the result of prior surgery. Proper management in such cases involves not only removal of calculi, but also upper urinary tract reconstruction to ensure free drainage, thereby eliminating stasis as a factor promoting recurrent calculi. These combined goals are most likely to be achieved with extracorporeal renal lithotomy and autotransplantation (Fig. 1).

Complications secondary to stone surgery

Ureteral obstruction and fistula formation are distressing complications of upper urinary tract surgery performed for stone disease. Extensive ureteral loss may be a sequela of such intervention and, when in situ ureteral repair is not possible, autotransplantation provides an excellent method of urinary tract reconstruction.² Although ileal interposition has been the traditional method of ureteral replacement and has yielded good results in properly selected patients, autotransplantation appears to offer several advantages. Most significantly, autotransplantation allows the integrity of the urinary tract to be maintained, thereby avoiding problems such as mucous secretion and electrolyte reabsorption which may result from ileal ureteral replacement. Postoperative bacteriuria occurs commonly with an ileal ureter and this can generally be prevented by autotransplantation. Approximately 25% of patients treated with an ileal ureter have experienced some degree of functional renal deterioration³; however, this has not occurred following autotransplantation, suggesting that this procedure may provide a more effective long-term method of preserving renal function. A final advantage of autotransplantation is that operative repair can be performed in the iliac fossa, away from previous scarring and inflammation.

Recurrent renal colic

In some patients, multiple recurrent renal calculi and repeated episodes of ureteral obstruction occur despite optimum medical therapy. Recurrent calculous disease in these patients is generally due to chronic pyelonephritis, renal tubular acidosis, cystinuria, or primary hyperparathy-

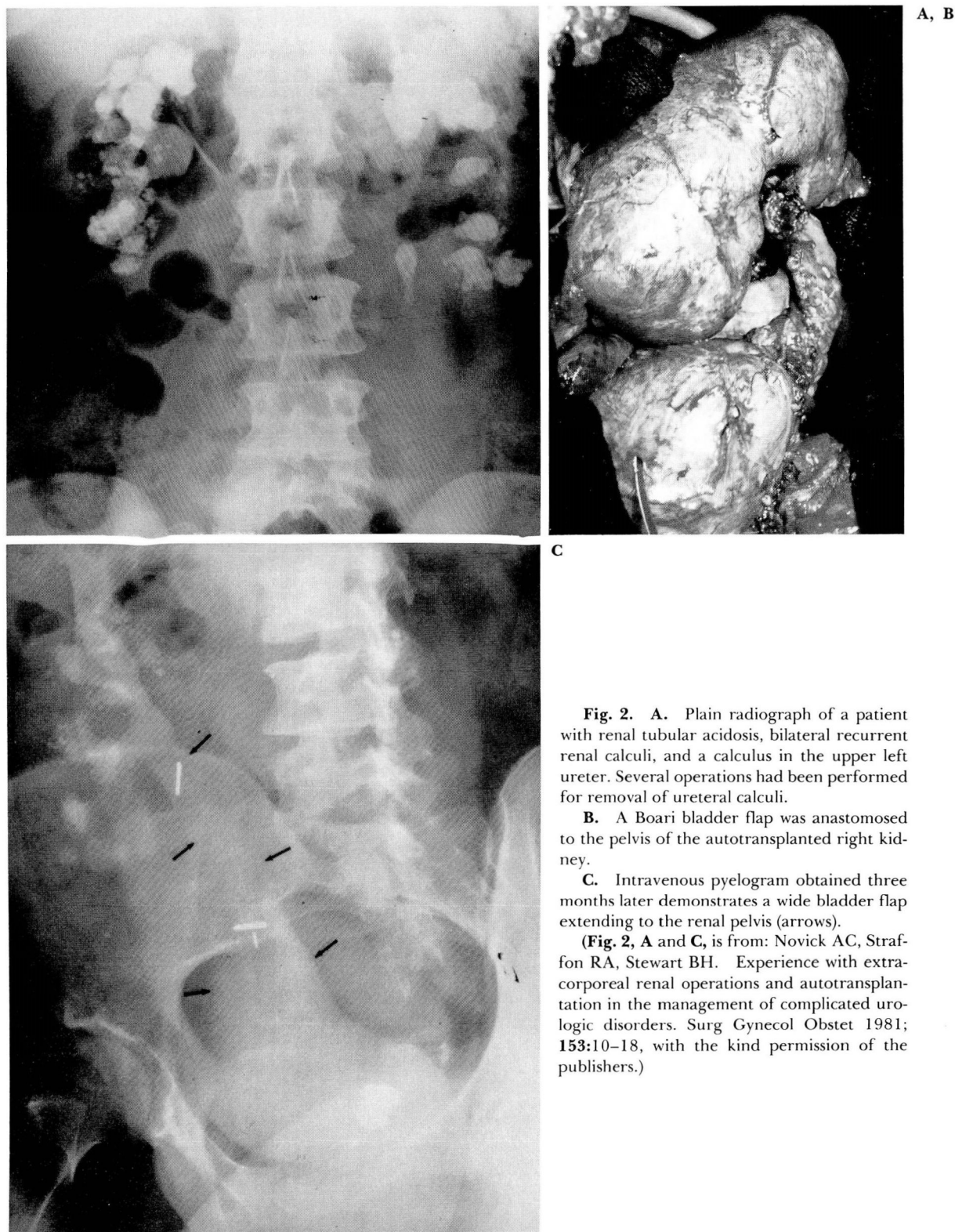


Fig. 2. A. Plain radiograph of a patient with renal tubular acidosis, bilateral recurrent renal calculi, and a calculus in the upper left ureter. Several operations had been performed for removal of ureteral calculi.

B. A Boari bladder flap was anastomosed to the pelvis of the autotransplanted right kidney.

C. Intravenous pyelogram obtained three months later demonstrates a wide bladder flap extending to the renal pelvis (arrows).

(Fig. 2, A and C, is from: Novick AC, Straffon RA, Stewart BH. Experience with extracorporeal renal operations and autotransplantation in the management of complicated urologic disorders. *Surg Gynecol Obstet* 1981; 153:10-18, with the kind permission of the publishers.)

roidism. In this setting, autotransplantation with pyelovesicostomy is performed to allow direct passage of subsequent stones into the bladder. This is accomplished by anastomosing the renal pelvis to a Boari bladder flap, which then functions as a nonrefluxing large-calibre urinary conduit.⁴ Patients with renal calculous disease that is refractory to medical therapy have benefited from this approach, which is preferable to ileal interposition for the reasons just discussed (Fig. 2).

Coexisting staghorn calculus and renovascular disease

Sullivan et al⁵ described the successful application of bench surgery for stone disease in a patient with a staghorn calculus and renal artery stenosis in the same kidney. The coexistence of these two renal disorders, although distinctly uncommon, is a valid indication for extracorporeal lithotomy and autotransplantation, as they are the most effective methods for achieving simultaneous stone removal and vascular reconstruction.

Recurrent staghorn calculus

There have been reports of extracorporeal removal of recurrent staghorn calculi in patients previously operated on for stone disease in the involved kidney.^{6,7} In such cases, the need for bench surgery ultimately depends upon the degree to which postsurgical scarring interferes with access to the renal vessels, pelvis, and ureter. In particularly difficult cases, the improved exposure provided by extracorporeal dissection of these structures will allow pyelonephrolithotomy to be performed more safely and effectively. In patients with recurrent staghorn calculi in a solitary kidney, the importance of preserving functioning renal parenchyma also favors extracorporeal stone removal because it affords greater protection from prolonged renal ischemia.

Extracorporeal renal preservation

Patients undergoing renal bench surgery and autotransplantation require the same adjunctive preoperative and intraoperative measures as transplant donors to ensure minimal renal ischemia and immediate function after revascularization. Such measures include adequate preoperative hydration, prevention of hypotension during anesthesia, intraoperative administration of mannitol, and rapid flushing and cooling of

the kidney after its removal. The first step in extracorporeal renal preservation is immediate flushing of the removed kidney with a chilled electrolyte solution (500 mL) instilled into the renal artery. This achieves rapid and uniform cooling of the kidney; removes blood, with its coagulation factors and isoagglutinins; and prevents cell damage by virtue of the composition of the particular electrolyte solution being employed. The removed, flushed kidney is then submerged in ice slush to achieve preservation by simple cold storage.

There are two types of electrolyte flushing solutions: extracellular (i.e., saline, Ringer's lactate) or intracellular. The various intracellular solutions are all basically modifications of the original Collins' solution. With simple cold storage preservation, both types of solution are equally effective for ischemic periods lasting up to five hours. For longer periods of cold storage, intracellular solutions are superior. In patients undergoing bench surgery or autotransplantation for renal calculous disease, the period of extracorporeal renal preservation invariably lasts considerably less than five hours; therefore, either an extracellular or intracellular flushing solution may be employed satisfactorily.⁸

When autotransplantation alone is performed, renal flushing is the only necessary preservative measure since circulation to the kidney will be restored within 30 to 60 minutes by anastomosis of the renal artery and vein to the prepared iliac vessels. When bench surgery is done, the flushed kidney is submerged in a basin of ice slush to maintain hypothermia. With the kidney preserved in this manner, extracorporeal removal of the calculi and appropriate renal reconstruction are then performed. Pulsatile perfusion is unnecessary in these cases and carries the risk of bacteria or tiny stone fragments entering the perfusate and being disseminated into the renal circulation. If necessary, vascular patency and integrity of the repaired kidney can be tested by reflushing with an electrolyte solution through the renal artery. Following completion of the extracorporeal operation, the kidney is removed from the ice slush basin and autotransplantation is performed.

Operative technique

Autotransplantation is generally performed via an anterior subcostal transperitoneal incision in combination with a separate transverse semilunar

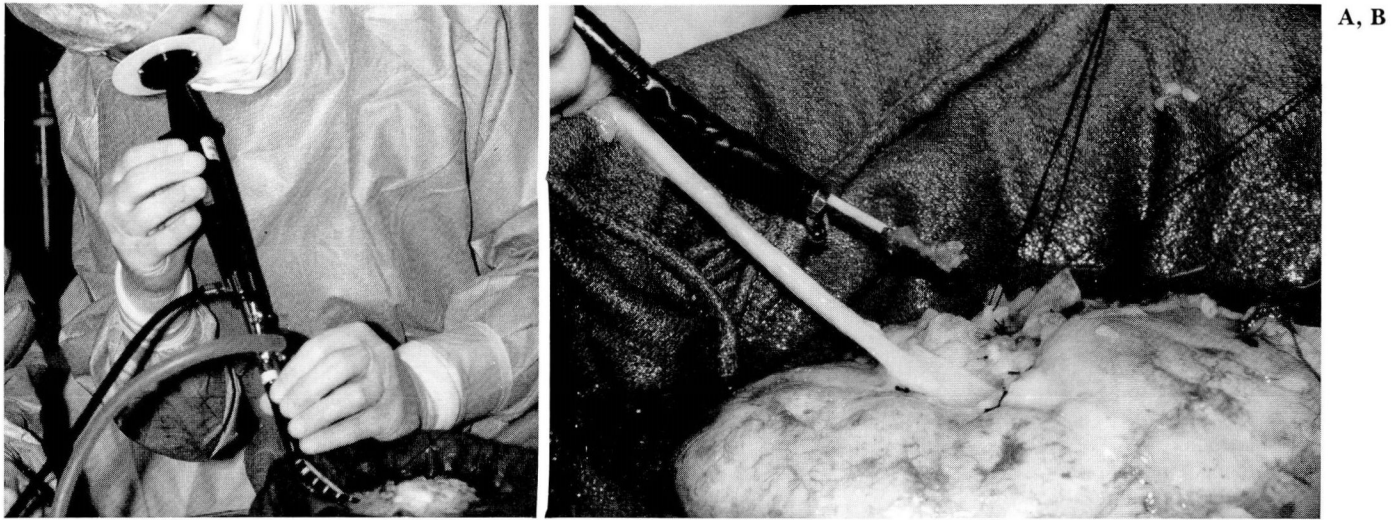


Fig. 3. A. Nephroscopy of the removed kidney, which is being preserved in a basin of ice slush.
B. Direct nephroscopic extraction of calculus through the pelvis of the removed kidney.

incision in the lower quadrant. In nonobese patients, a single midline incision extending from the xyphoid to the symphysis pubis may be used alternatively. Most patients with calculous disease will have undergone prior renal surgery and mobilization of the kidney may therefore be difficult because of perirenal scarring. It is important to remove the kidney with minimal manipulation when the patient is in a state of active diuresis. The renal vessels should be mobilized proximally while avoiding dissection within the renal hilus.

If the ureter is divided and the kidney is placed on a separate workbench when performing extracorporeal surgery, better exposure for the extracorporeal operation is provided, performance of radiography and nephroscopy is facilitated, and simultaneous preparation of the iliac fossa is possible. The operation begins with mobilization of the renal pelvis and infundibula posteriorly, extending well into the renal sinus. The exposure provided by this intrasinusoidal approach allows most calculi to be removed with an extended pyelotomy. Nephroscopy is a valuable adjunct for locating and removing retained calculi (*Fig. 3*).⁹ Direct extraction under fluoroscopy is also possible if the stones are small and difficult to locate. To preserve the renal parenchyma, a nephrotomy is reserved for calyceal stones that cannot be removed through a pyelotomy, because of either severe impaction or a stenotic infundibulum. In the latter case, repair of the intrarenal collecting system is accomplished as described by Smith and Boyce¹⁰ to ensure unob-

structed drainage. Plain radiographs of the kidney are essential to make certain that all calculi have been removed prior to autotransplantation. Autotransplantation is done by anastomosis of the renal vein to the external iliac vein and anastomosis of the renal artery to the internal, external, or common iliac artery.

Following autotransplantation, a variety of methods are available for restoring urinary continuity, including ureteroneocystostomy, ureteropyelostomy, ureteroureterostomy, and direct pyelovesicostomy. In patients with recurrent renal colic, the entire ureter is resected and a wide-calibre Boari bladder flap is anastomosed to the renal pelvis. Interestingly, vesicorenal reflux is absent postoperatively in many of these patients.⁴ In other cases, when fibrotic obstruction of the upper ureter and pelvis is present, the strictured areas are resected and the renal pelvis is anastomosed to the lower disease-free portion of the ureter.

Postoperative care

Within the first 24 hours after the operation, a technetium scan is obtained to verify perfusion of the autotransplanted kidney. Subsequent radioisotope monitoring with I-131 orthoiodohippurate provides a functional assessment of the autograft, and in the absence of postoperative vasomotor nephropathy, this scan will show prompt uptake, early excretion, and complete clearance of the isotope from the graft. Postoperative care also includes general measures that

are applicable to any patient with stone disease, such as liberal fluid administration to maintain dilute urine, use of diuretic agents, continued parenteral antimicrobial therapy to eradicate existing urinary infection, and treatment of any underlying metabolic abnormality. After ureteroneocystostomy or pyelovesicostomy has been performed, urethral catheter drainage of the bladder is maintained for one week postoperatively. Patients are then instructed to void at least once every two hours. All drains are removed over the next 48 hours. One month postoperatively, digital subtraction angiography and intravenous pyelography are performed simultaneously using a single intravenous injection of contrast material (30 mL). This is an excellent noninvasive method of identifying both arterial patency and unobstructed urinary drainage from the autograft.

Head, Section of Renal Transplantation
Department of Urology
The Cleveland Clinic Foundation
9500 Euclid Ave.
Cleveland OH 44106

References

1. Novick AC. Extracorporeal renal surgery and autotransplantation. [In] Novick AC, Straffon RB, eds. *Vascular Problems in Urologic Surgery*. Philadelphia, WB Saunders, 1982, pp 305-328.
2. Stewart BH, Hewitt CB, Banowsky LH. Management of extensively destroyed ureter: special reference to renal autotransplantation. *J Urol* 1976; **115**:257-261.
3. Boxer RJ, Fritzsche P, Skinner DG, et al. Replacement of the ureter by small intestine: clinical application and results of the ileal ureter in 89 patients. *J Urol* 1979; **121**:728-731.
4. Olsson CA, Idelson B. Renal autotransplantation for recurrent renal colic. *J Urol* 1980; **123**:467-474.
5. Sullivan MJ, Joseph E, Taylor JC. Extracorporeal renal parenchymal surgery with continuous perfusion. *J Am Med Assoc* 1974; **229**:1780-1781.
6. Andersen OS, Clark SS, Marlett MM, Jonasson O. Treatment of extensive renal calculi with extracorporeal surgery and autotransplantation. *Urology* 1976; **7**:465-469.
7. Turini D, Nicita G, Selli C, et al. Clinical experience in ex situ surgery of renal lesions and staghorn renal stones. Presented at the Societe' Internationale D'Urologie Meeting in Paris, 1979.
8. Novick AC. Renal hypothermia: in vivo and ex vivo. *Urol Clin N Am* 1983; **10**:637-644.
9. Gittes RF. Operative nephroscopy. *J Urol* 1976; **116**:148-152.
10. Smith MJV, Boyce WH. Anatomic nephrotomy and plastic calyrrhaphy. *J Urol* 1968; **99**:521-527.