Nonurographic evaluation of renal calculous disease[1]

Gregory P. Borkowski, M.D.
Craig R. George, M.D.
Peter B. O'Donovan, M.D.

While excretory urography has been useful in the evaluation of patients with renal calculi, it does have certain limitations. These include (*a*) poor differentiation of calculi from other causes of radiolucent filling defects within the renal collecting system, (*b*) poor visualization because of decreased renal function, and (*c*) possible contraindication in patients with a history of significant allergic reaction. Computed tomography (CT) and ultrasound are noninvasive techniques which have proved to be useful in the evaluation of nonopaque calculi. The greater density discrimination of CT allows stones to be visualized as areas of increased density without the need for intravenous contrast material. On ultrasound, calculi appear as echogenic areas with posterior acoustical shadowing. These imaging modalities have also been useful for preoperative assessment of the position of renal calculi, intraoperative localization of calculi, and determination of the response of a calculus to dissolution therapy.

Index terms: Kidney calculi • Kidney, computed tomography • Kidney, ultrasound studies

Cleve Clin Q 52:3–9, Spring 1985

Excretory urography has been used for a considerable period of time in the evaluation of suspected renal disease. One of its major limitations is its nonspecificity with respect to the detection of a radiolucent filling defect within the renal collecting system. There are several pathological entities which may be responsible for this finding,[1] however, the most common include transitional cell carcinoma, calculus, and blood clot. Differentiation of these entities is important in order to establish the proper therapeutic regimen. Prior to the advent of computed tomography

[1] Department of Radiology, The Cleveland Clinic Foundation. Submitted for publication July 1984; revision accepted Nov 1984.

0009-8787/85/01/0003/09/$3.25/0

Copyright © 1985, The Cleveland Clinic Foundation

Downloaded from www.ccjm.org on April 23, 2024. For personal use only. All other uses require permission.

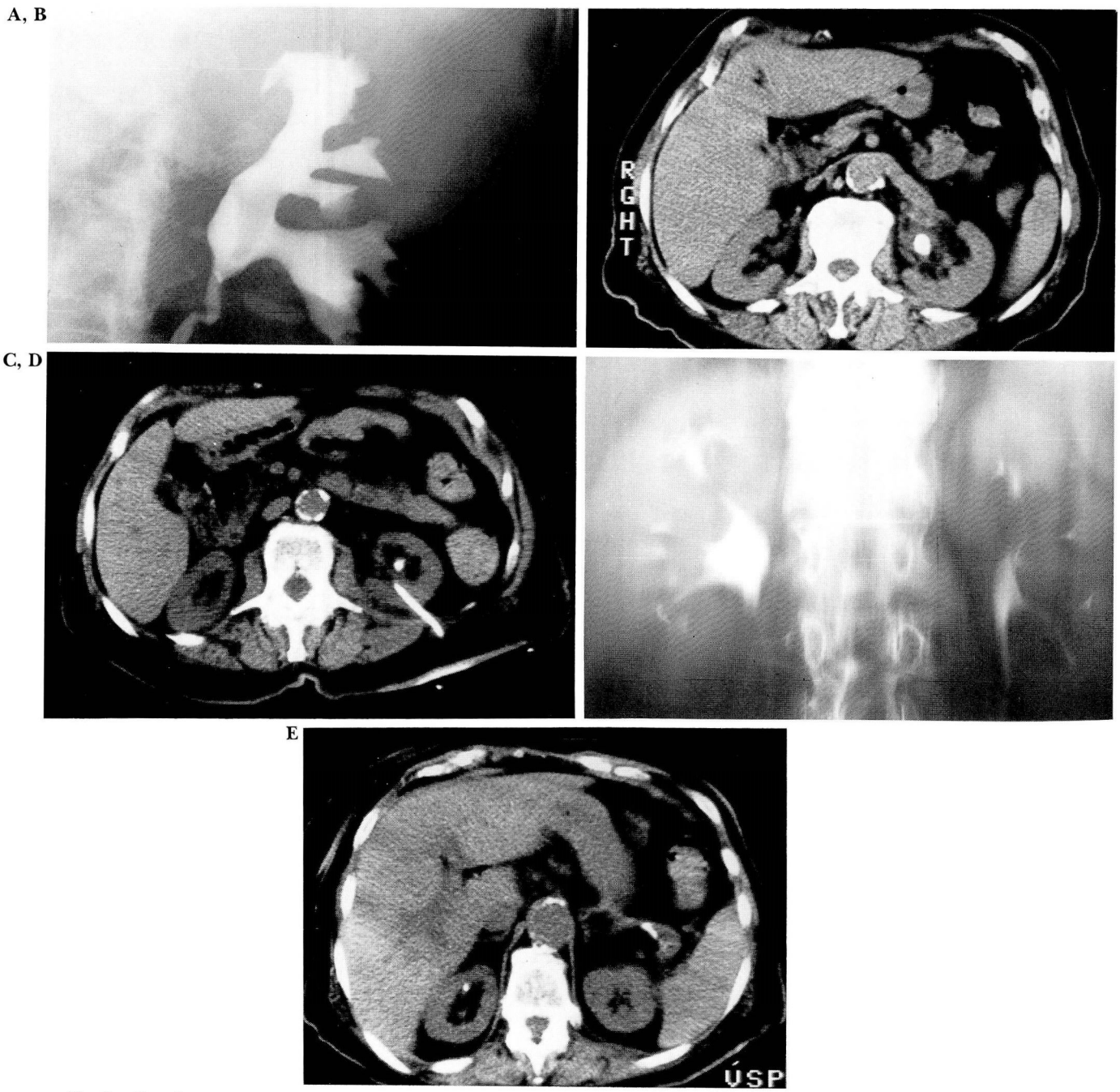

Fig. 1. Case 1.

A. Retrograde pyelogram demonstrates a large radiolucent defect within the pelvis.

B. CT scan, obtained approximately 24 hours later, shows a large area of increased density within the renal pelvis. This conforms to the location of the radiolucent defect noted on the retrograde pyelogram.

C. Repeat CT scan, performed approximately one month later, shows dissolution of the calculus. The percutaneous catheter can be seen extending through the posterior aspect of the left kidney, while the density within the collecting system represents the coiled end of the catheter.

D. Follow-up urogram, obtained two weeks after the second CT scan, confirms dissolution of the calculus.

E. A scan obtained at a different level through the kidneys demonstrates an incidental calculus involving the right kidney.

Downloaded from www.ccjm.org on April 23, 2024. For personal use only. All other uses require permission.

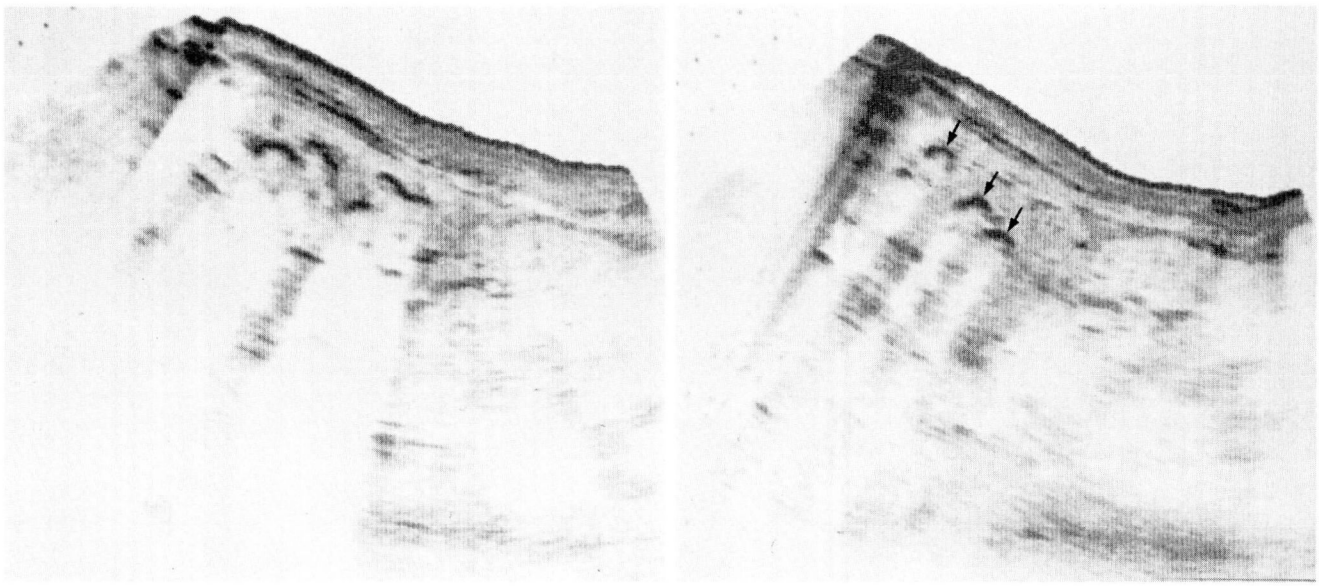

Fig. 2. Case 2.
A and **B.** Ultrasound images (coronal plane) at two levels within the left kidney show several focal areas of increased echogenicity (arrows) with acoustical shadowing, suggesting multiple calculi.

(CT) and ultrasound, invasive studies, such as retrograde pyelography, brush biopsy, or surgery, were required. Now, CT and ultrasound have proved useful in differentiating calculous disease from soft tissue masses.[2–5] These techniques have also been useful for defining the full extent of a relatively nonopaque calculus. Poor renal function, whether secondary to intrinsic renal disease or as a result of obstructive uropathy from calculus, may also limit the usefulness of excretory urography. The use of intravenously administered contrast material may be contraindicated in patients with a known sensitivity to these agents. It is in these cases that we have found CT and ultrasound to be worthwhile.

Case reports

Case 1. A 78-year-old woman presented with uric acid

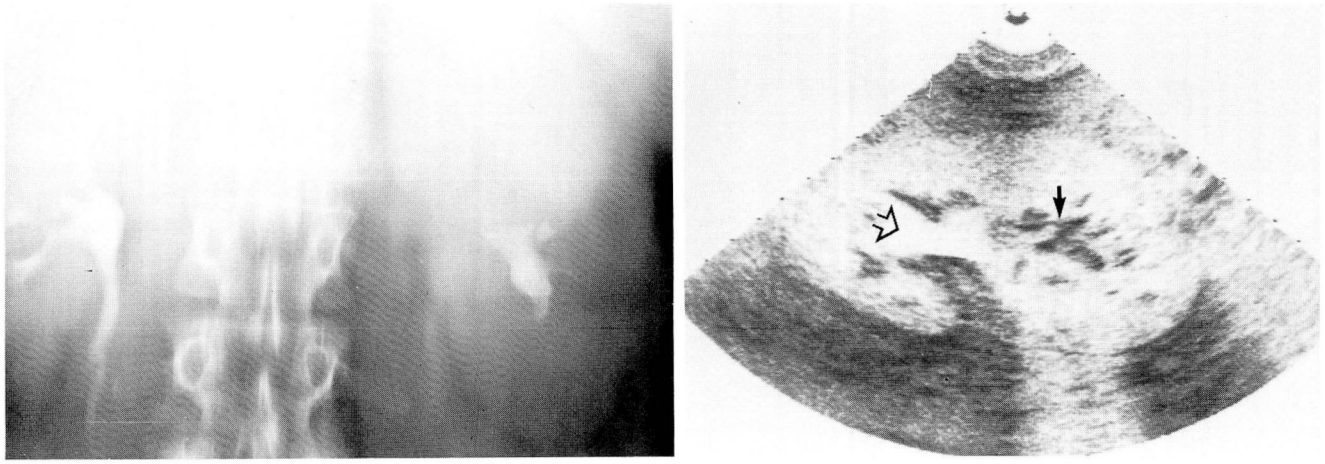

Fig. 3. Case 3.
A. Excretory urogram shows nonfunction of the left kidney, as well as a staghorn calculus involving the lower portion.
B. Ultrasound image of the left kidney demonstrates dilatation of the collecting system (open arrow) and a staghorn calculus (solid arrow) associated with acoustical shadowing.

Downloaded from www.ccjm.org on April 23, 2024. For personal use only. All other uses require permission.

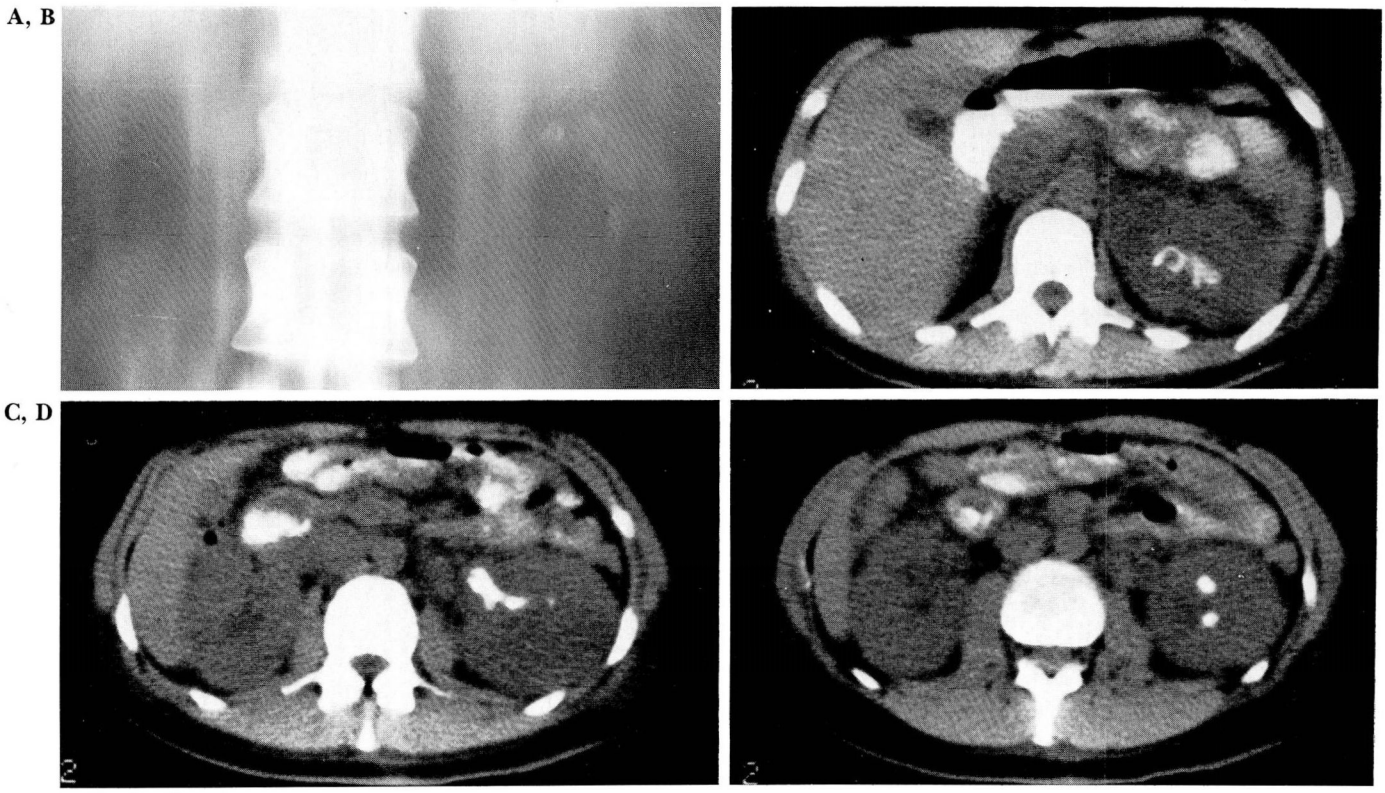

Fig. 4. Case 4.
A. Laminagram of the renal beds shows multiple calcific densities within the region of the left kidney.
B–D. CT scans through the kidneys, obtained without intravenous contrast material, demonstrate the size and extent of the radiodense staghorn calculus.

calculi involving the left kidney. Excretory urography revealed a radiolucent defect within the left renal pelvis (*Fig. 1A*). CT demonstrated a high-attenuation area within this region (*Fig. 1B*). This finding confirmed the presence of a calculus. A percutaneous nephrostomy tube was positioned with subsequent infusion of an alkalinizing agent for dissolution of the uric acid stone. A repeat CT examination, performed approximately one month later, demonstrated dissolution of the calculus (*Fig. 1C*). A subsequent excretory urogram showed complete resolution of the previously noted defect (*Fig. 1D*).

Case 2. A 58-year-old man was known to have uric acid calculi in both kidneys. Renal function was poor, and an ultrasound examination was requested to exclude the possibility of obstruction. The sonogram revealed multiple areas of increased echogenicity with acoustical shadowing posteriorly (*Fig. 2*), but no evidence of obstruction.

Case 3. A 64-year-old woman, with a history of hyperparathyroidism and a left staghorn calculus, presented with a one-week history of left flank pain, chills, and fever. At admission, an excretory urogram revealed a left staghorn calculus as well as a marked decrease in function on that side compared to the right. Since acute pyelonephritis could not be distinguished from obstruction, an ultrasound examination was requested and revealed a large staghorn calculus with concomitant hydronephrosis (*Fig. 3*).

Case 4. A 28-year-old woman was admitted for management of a left staghorn calculus. Approximately one year prior to admission, the patient began to have recurrent urinary tract infections with left flank pain, chills, fever, and dysuria. Tomography (*Fig. 4A*) demonstrated a staghorn calculus involving the left kidney; however, it was difficult to delineate the full extent of the calculus because it was only slightly radio-opaque. A CT scan revealed the complete extent of the calculus (*Fig. 4B–D*).

Case 5. A 46-year-old man presented for evaluation as a possible renal transplant donor. He had been asymptomatic. However, several years earlier, he had had an episode of gross hematuria and severe flank pain. Evaluation for renal calculi was negative at that time; however, during the course of his present examination, excretory urography revealed a renal mass. A preliminary examination of the abdomen demonstrated a small calcification overlying the midportion of the left kidney. A subsequent CT scan was obtained both with and without the use of contrast material (*Fig. 5*). The mass was identified as a simple cyst. The nonenhanced scan demonstrated a small calculus within the midportion of the left kidney which was obscured by contrast material on the enhanced scan.

Case 6. A 34-year-old woman presented with a two-year history of abdominal suprapubic and left flank pain associ-

Downloaded from www.ccjm.org on April 23, 2024. For personal use only. All other uses require permission.

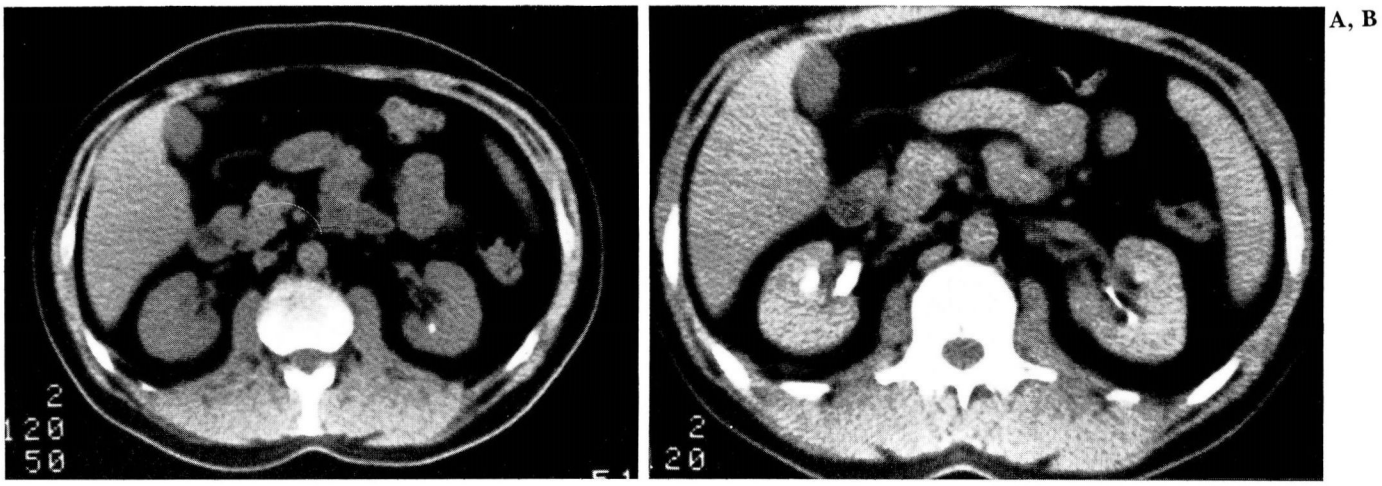

Fig. 5. Case 5.
A. Nonenhanced CT scan through the kidneys demonstrates a calculus involving the left kidney.
B. Following the intravenous adminstration of contrast material, the collecting system is radio-opaque and the calculus is no longer identifiable.

ated with gross hematuria. An intravenous pyelogram, obtained approximately one year earlier, was reported to be normal. A plain radiograph of the abdomen, obtained during the current evaluation, demonstrated two calcifications overlying the region of the left kidney. CT disclosed severe hydronephrosis of the left kidney, secondary to an obstructing calculus at the ureteropelvic junction (*Fig. 6*). At surgery, an obstructing calculus at the ureteropelvic junction, with pyonephrosis, was found.

Discussion

The incidence of radiolucent calculi has been reported to be approximately 8%.[6] While most consist of uric acid and urate stones, xathine, cystine, and some matrix calculi are included in this group. These stones present difficult diagnostic dilemmas when they are seen on an excretory urogram because they must be differentiated from neoplasms of the collecting system. Linear tomography has been advocated for detection of low density stones,[7] but this technique is dependent on the detection of calcium density within the filling defect. A faint homogeneous or ring-like calcification in the area of the filling defect establishes the diagnosis[4]; however, the absence

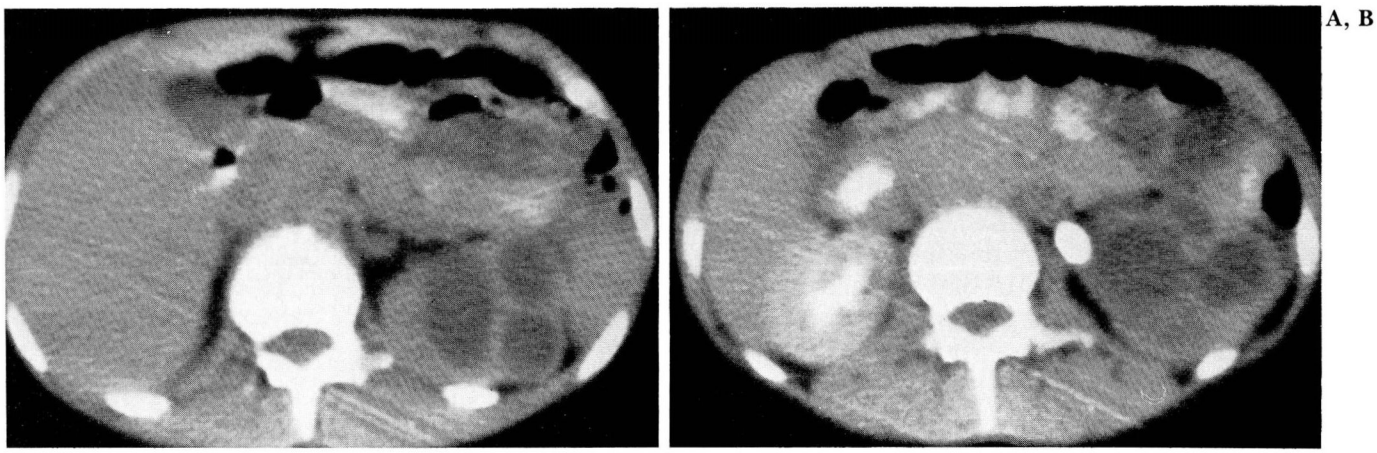

Fig. 6. Case 6.
A. CT scan of the midabdomen demonstrates no excretion of the intravenous contrast material by the markedly hydronephrotic left kidney.
B. A radio-opaque calculus can be seen in the region of the ureteropelvic junction.

Downloaded from www.ccjm.org on April 23, 2024. For personal use only. All other uses require permission.

of calcification does not exclude the possibility of a calculus.

Because of its superior density discrimination, CT is able to detect the significant density difference between nonopaque calculi and soft tissue causes of lucent defects on the excretory urogram. Calcium-containing calculi will be represented as CT densities in the range of 400–600 Hounsfield units (HU) while nonopaque calculi have measurements in the range of 180–500 HU. Transitional cell carcinoma has densities in the range of 20–40 HU when the scans are performed without the use of intravenous contrast material.[2,3] Blood clots have been reported to have measurements of approximately 55 HU, however, the attenuation values can be variable and depend on the age of the clot. Values have been detected only slightly lower than those associated with calculi.[2] Calculi as small as 0.5 cm have been detected by CT.[8] It is crucial that the proper technique be used to obtain the CT scan. Contiguous sections of 5- to 10-mm collimation through the entire kidney are recommended.[3] Calculi are detected as high density areas and, therefore, scans should be obtained both before and after the infusion of contrast material in case the contrast agent obscures the calculus. Postinfusion scans are helpful in enhancing detection of soft tissue masses and in allowing assessment of whether the mass is intrinsic or extrinsic to the collecting system.[3] In addition to the detection of calculi, CT has been used to follow the size of the calculus during medical therapy directed at dissolution of the stone. CT has also been used for the preoperative localization of renal calculi.[9]

Ultrasound is a fast, reliable method of evaluating calculous disease. This technique can be used not only to evaluate radiolucent filling defects identified on the excretory urogram, but is also of value for the detection of suspected calculous disease in patients who are sensitive to contrast agents. Ultrasound can detect both radio-opaque and lucent stones and is independent of renal function. The characteristic ultrasound appearance is that of an echogenic structure which produces acoustic shadowing posteriorly secondary to attenuation of the sound beam. Soft tissue masses show no significant acoustical shadow. Calculi as small as 1.0 × 1.0 cm have been imaged.[10] Hydronephrosis can be detected, and the dilated proximal ureter may also be visualized. Intraoperative roentgenography has long been used to determine the presence and position of renal stones, but provides only a two-dimensional image. Ultrasound is capable of providing not only the two dimensions, but also may be used to indicate the depth of the stone from the surface of the kidney as well.[11] Following sonographic localization of the calculus, a fine blunt needle can be directed toward the stone under ultrasound guidance. Once the stone has been sounded, a small nephrotomy can be made to remove it. Calculi as small as 2 to 3 mm have been detected using the higher frequency transducers utilized for intraoperative renal scanning.

Both CT and ultrasound have been employed in an attempt to determine the chemical composition of calculus. At this time, there is no firm agreement among investigators on the value of this method for in vivo evaluation.[5,12–14]

Conclusion

While the radiolucent and relatively radiolucent filling defects seen on the excretory urogram remain a diagnostic problem, CT and ultrasound are useful noninvasive means of distinguishing soft tissue from calculous disease. These modalities have been useful in both the preoperative and intraoperative assessment of the position of renal calculi and are used for the follow-up evaluation of patients being treated to dissolve the stones.

Acknowledgment

We wish to thank Cathy Stine for help in preparing the manuscript.

Gregory P. Borkowski, M.D.
Department of Radiology
The Cleveland Clinic Foundation
9500 Euclid Ave.
Cleveland OH 44106

References

1. Malek RS, Aguilo JJ, Hattery RR. Radiolucent filling defects of the renal pelvis: classification and report of unusual cases. J Urol 1975; **114**:508–513.
2. Pollack HM, Arger PH, Banner MP, Mulhern CB Jr, Coleman BG. Computed tomography of renal pelvic filling defects. Radiology 1981; **138**:645–651.
3. Greenberg M, Falkowski WS, Sakowicz BA, Neiman HL,

Downloaded from www.ccjm.org on April 23, 2024. For personal use only. All other uses require permission.

Schaeffer AJ. Use of computerized tomography in the evaluation of filling defects of the renal pelvic. J Urol 1982; **127:** 1172–1176.
4. Brennan RE, Curtis JA, Kurtz AB, Dalton JR. Use of tomography and ultrasound in the diagnosis of nonopaque renal calculi. JAMA 1980; **244:**594–596.
5. Pollack HM, Arger PH, Goldberg BB, Mulholland SG. Ultrasonic detection of nonopaque renal calculi. Radiology 1978; **127:**233–237.
6. Prien EL Sr. Symposium on renal lithiasis. The analysis of urinary calculi. Urol Clin North Am 1974; **1:**229–240.
7. Ambos MA, Bosniak MA. Tomography of the kidney bed as an aid in differentiating renal pelvic tumor and stone. Radiology 1975; **125:** 331–336.
8. Segal AJ, Spataro RF, Linke CA, Frank IN, Rabinowitz R. Diagnosis of nonopaque calculi by computed tomography. Radiology 1978; **129:**447–450.
9. Wickham JEA, Fry IK, Wallace DMA. Computerised tomography localisation of intrarenal calculi prior to nephrolithotomy. Br Urol 1980; **52:**422–425.
10. Resnick MI, Kursh ED, Cohen AM. Use of computerized tomography in the delineation of uric acid calculi. J Urol 1984; **131:**9–10.
11. Lytton B. Intraoperative ultrasound for nephrolithotomy. J Urol 1983; **130:**213–217.
12. Cunningham JJ, Cunningham MA. Characterization of renal stone models with gray scale echography: in vitro studies with clinical correlation. Urology 1976; **7:**315–318.
13. Hillman BJ, Drach GW, Tracey P, Gaines JA. Computed tomographic analysis of renal calculi. AJR 1984; **142:**549–552.
14. Newhouse JH, Prien EL, Amis ES Jr, Dretler SP, Pfister RC. Computed tomographic analysis of urinary calculi. AJR 1984; **142:**545–548.

Downloaded from www.ccjm.org on April 23, 2024. For personal use only. All other uses require permission.