Intravenous digital subtraction angiography in the evaluation of systemic and pulmonary venous anomalies[1]

Dale L. Haggman, D.O.
Douglas S. Moodie, M.D.
Richard Sterba, M.D.
Carl C. Gill, M.D.

The authors studied 17 patients with systemic and pulmonary venous anomalies. Digital and analog systems with single or average multiple masks were used with two commercially available systems with radiographic or continuous modes. In all patients, contrast material was injected into a peripheral vein (usual dose, 0.5–1.0 mL/kg). Digital subtraction angiograms were compared with cardiac angiograms and echocardiograms. In all 17 patients, digital subtraction angiography (DSA) studies provided information that could have eliminated some or all of the routine cardiac catheterization procedure. There were no complications following any of the DSA studies. DSA is a safe and effective technique for the evaluation of patients with systemic and pulmonary venous anomalies.

Index terms: Angiography · Pulmonary veins, abnormalities · Subtraction technic

Cleve Clin Q 52:55–60, Spring 1985

Intravenous digital subtraction angiography (DSA) is ideally suited to the study and evaluation of the cardiovascular system. As a result, DSA is gaining wide acceptance and is being used with increasing frequency. It has been shown to be a useful technique for the evaluation of peripheral vessels, such as the abdominal aorta and renal arteries[1]; aortic arch anomalies[2]; and recently, congenital heart disease.[3] However, DSA has not been reported in the evaluation of systemic and pulmonary venous anomalies. We describe the results of our initial experience with DSA involving 17 patients with systemic and pulmonary venous anomalies.

[1] Departments of Cardiology (D.L.H., D.S.M., R.S.) and Thoracic and Cardiovascular Surgery (C.C.G), The Cleveland Clinic Foundation. Submitted for publication Aug 1984; revision accepted Jan 1985.

Winner of the 1984 18th annual Peskind Memorial Award of The Cleveland Clinic Educational Foundation.

0009-8787/85/01/0055/06/$2.50/0

Copyright © 1985, The Cleveland Clinic Foundation

Downloaded from www.ccjm.org on April 19, 2024. For personal use only. All other uses require permission.

A, B

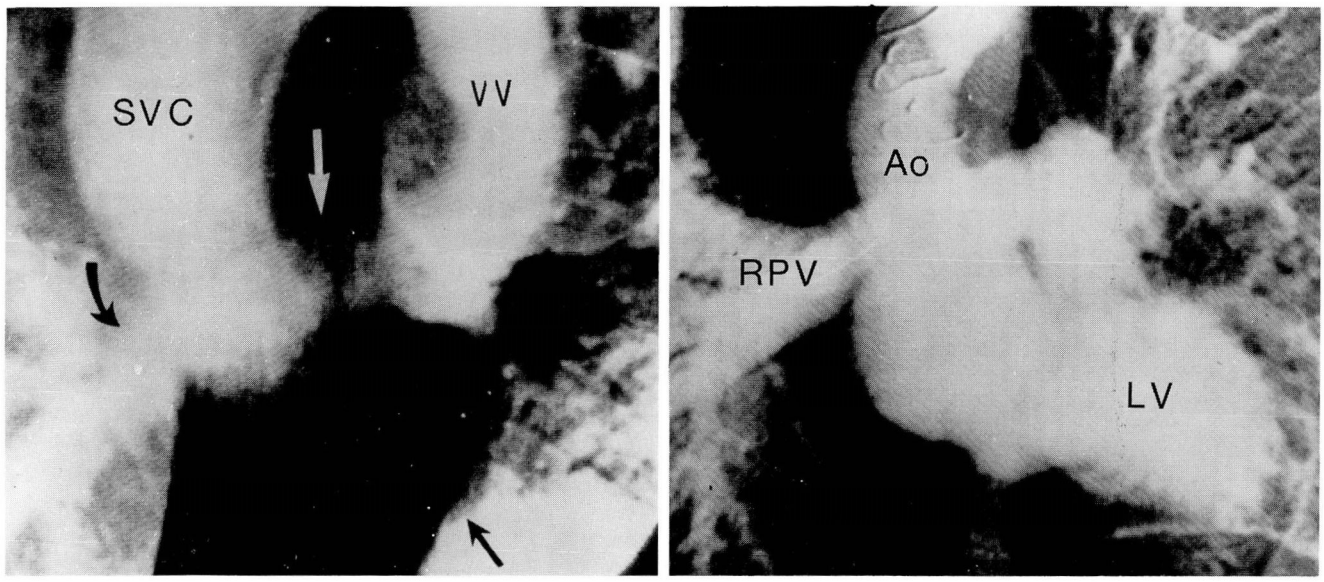

Fig. 1. Patient 3 (*Table 1*).

A. Preoperative DSA study of a 17-year-old boy, showing total anomalous pulmonary venous drainage into a common horizontal vein (white arrow), which empties first into a vertical vein and then into the right superior vena cava. The curved black arrow shows the right pulmonary veins draining to the common horizontal vein. The straight black arrow shows a subtracted left atrium demonstrating no relation of the venous return to the left atrium.

B. Postoperative DSA study eight days after surgical repair. The anomalous pulmonary veins are now draining normally into the left atrium. There is no evidence of a vertical vein.

Ao = aortic outflow tract, *LV* = left ventricle, *RPV* = right pulmonary vein, *SVC* = superior vena cava, and *VV* = vertical vein.

Materials and method

Imaging equipment and technique

Digital and analog systems with single or average multiple masks were used with two commercially available systems with radiographic or continuous modes. The dose of contrast material was 0.5–1.0 mL/kg with 5–30 mL of Renografin-76

Table 1. Patient population with total anomalous venous return

Patient Number	Sex	Age	Above Diaphragm	Below Diaphragm	Associated Findings
1	F	1 mo	Status after repair	Absent	ASD
2	M	1 yr	Absent	Status after repair	ASD
3	M	17 yrs	Present	Absent	Left SVC, ASD
4	F	19 yrs	Present	Absent	Left cardinal vein, ASD

ASD = atrial septal defect, and *SVC* = superior vena cava.

Table 2. Patient population with partial anomalous venous return

Patient Number	Sex	Age (yrs)	Venous Anomaly	Associated Findings
1	F	12	RPV to IVC	Hypoplastic right and left pulmonary arteries
2	M	13	LPV to CS	ASD, LSVC
3	F	21	LPV to CS	LSVC, ASD, hypoplastic left pulmonary artery
4	M	27	RPV to SVC	Mitral stenosis

ASD = atrial septal defect, *CS* = coronary sinus, *IVC* = inferior vena cava, *LPV* = left pulmonary vein, *LSVC* = left superior vena cava, *RPV* = right pulmonary vein, and *SVC* = superior vena cava.

Downloaded from www.ccjm.org on April 19, 2024. For personal use only. All other uses require permission.

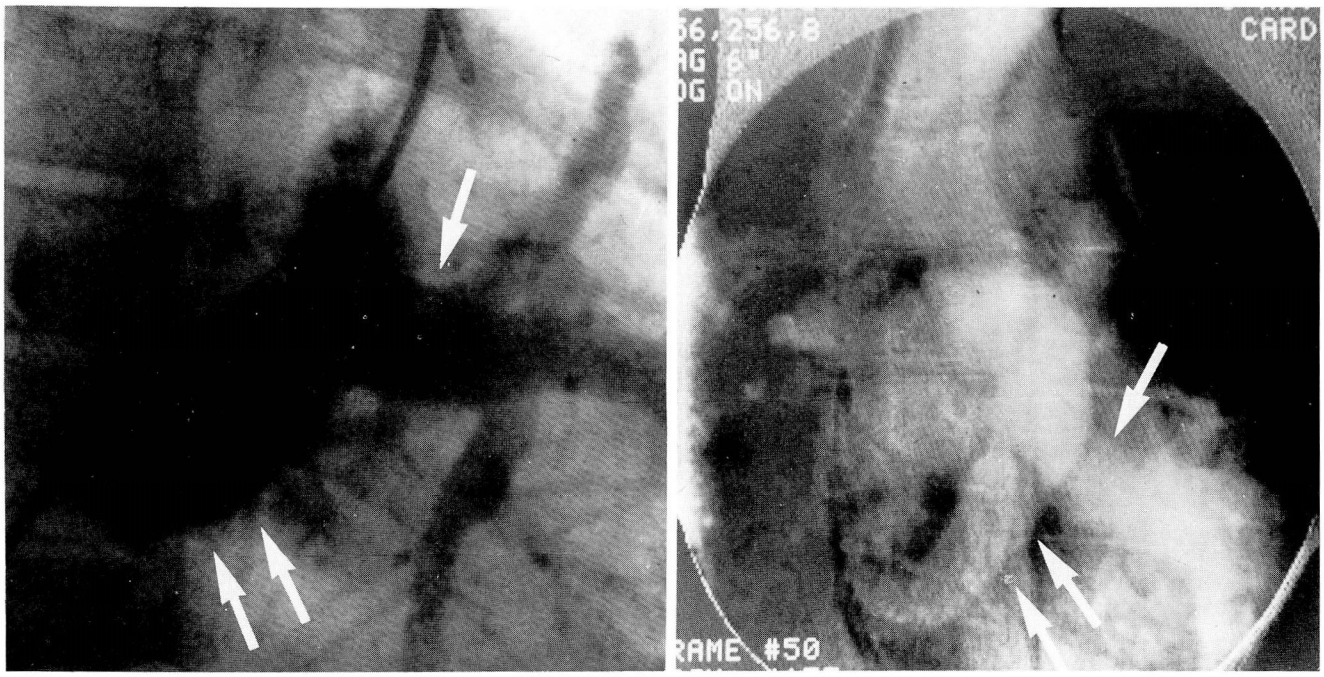

Fig. 2. Patient 3 (*Table 2*).
A. Levophase of the preoperative pulmonary angiogram of a 21-year-old woman with anomalous drainage of the left pulmonary vein (single arrow) to the coronary sinus (double arrows).
B. DSA study demonstrated similar anatomy when compared to the standard angiogram.

injected intravenously. Younger patients were sedated with meperidine (Demerol), promethazine (Phenergan), and chlorpromazine (Thorazine). Initial framing rates were one to six frames per second using a 256 × 256 matrix, and later studies were 30 frames per second.

Patient population

Seventeen patients with systemic and pulmonary venous anomalies were studied (8 males and 9 females; ranging in age from three days to 55 years, with a mean age of 19 years). Ten patients were less than 20 years of age, and 6 patients were less than 18 months of age. We studied 4 patients with total anomalous pulmonary venous return, 4 with partial anomalous venous return, 9 with persistent left superior vena cava, and 4 with various systemic venous anomalies.

Results

Digital subtraction angiograms of systemic and pulmonary venous anomalies were retrospectively compared with catheterization findings, echocardiograms, and clinical course. In all 17 patients, the DSA studies were of good quality and contained important angiographic and anatomic information so that part or all of the routine cardiac catheterization study could have been eliminated.

Total anomalous venous return

Table 1 and *Figure 1* describe the 4 patients studied with total anomalous venous return.

Partial anomalous venous return

Table 2 describes the patient population with partial anomalous venous return. *Figure 2* compares the preoperative results of the levophase of the pulmonary angiogram with the DSA study in a 21-year-old woman. *Figure 3* shows the levophase of the eight-day postoperative pulmonary angiogram and the two-year postoperative DSA study, respectively, of a 12-year-old girl.

Left superior vena cava

A left superior vena cava was the most common venous anomaly studied and appeared in 9 of our 17 patients (*Table 3*). It was associated with partial anomalous venous return in 2 patients and total anomalous pulmonary venous return in 1 patient. Other cardiovascular abnormalities are further described in *Table 3* in the remaining 6

Downloaded from www.ccjm.org on April 19, 2024. For personal use only. All other uses require permission.

A, B

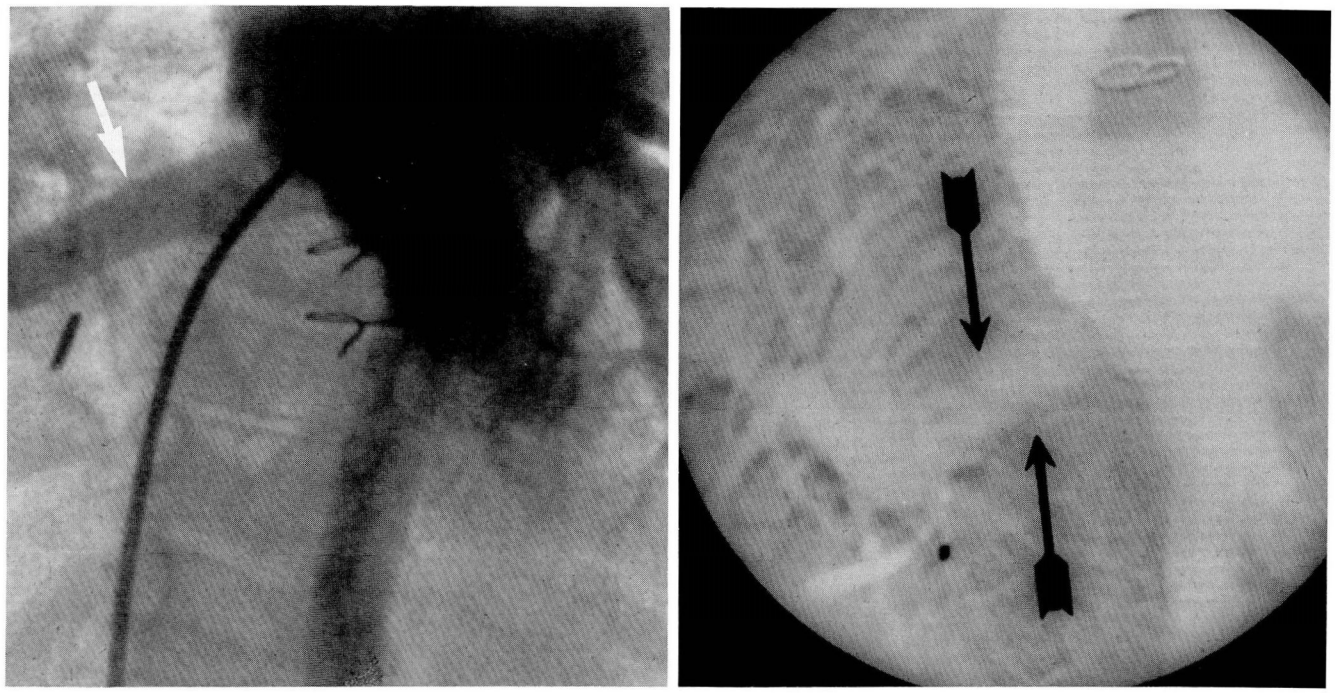

Fig. 3. Patient 1 (*Table 2*).

A. Levophase of the eight-day postoperative pulmonary angiogram of a 12-year-old girl who underwent ligation of the anomalous right pulmonary veins and insertion of a Gortex graft (arrow) from the anomalous pulmonary vein to the left atrial wall. The right middle and lower pulmonary veins drain into the left atrium via the patent Gortex conduit.

B. Postoperative DSA study two years after surgery. The surgical repair with the Gortex conduit is outlined by arrows.

Table 3. Patient population with left superior vena cava

Patient Number	Sex	Age	Associated Findings
1	F	5 days	Hypoplastic left heart, aortic and mitral valve atresia
2	F	17 mo	Subvalvular pulmonic stenosis
3	M	13 yrs	ASD, LPV to CS
4	M	17 yrs	ASD, TAVR (above diaphragm)
5	F	21 yrs	ASD, LPV to CS, hypoplastic LPA
6	F	27 yrs	ASD
7	F	40 yrs	ASD, pulmonic stenosis
8	M	41 yrs	Left vitelline vein
9	M	55 yrs	Totally obstructed RSVC

ASD = atrial septal defect, *CS* = coronary sinus, *LPA* = left pulmonary artery, *LPV* = left pulmonary vein, *RSVC* = right superior vena cava, and *TAVR* = total anomalous venous return.

Table 4. Patient population with other conditions

Patient Number	Sex	Age	Anomaly	Associated Findings
1	F	3 days	Azygous (IVC) to SVC	Valvular pulmonic stenosis
2	M	13 mo	Hemiazygous (IVC) to innominate vein to SVC	AV canal defect, cleft mitral valve
3	M	41 yrs	Left vitelline vein	LSVC (status after MVR)
4	M	54 yrs	Right SVC obstruction	

AV = atrioventricular, *IVC* = inferior vena cava, *LSVC* = left superior vena cava, *MVR* = mitral valve replacement, and *SVC* = superior vena cava.

Downloaded from www.ccjm.org on April 19, 2024. For personal use only. All other uses require permission.

patients. *Figure 4* is a DSA study showing the left superior vena cava draining into the coronary sinus in a 21-year-old woman.

Other conditions

The 4 patients in this category are described (*Table 4*). *Figure 5* is the DSA study of a three-day-old girl. *Figure 6* is the DSA study of a 13-month-old boy. *Figure 7* is the DSA study of a 41-year-old man 15 days after mitral valve replacement for mitral regurgitation.

Discussion

Using only a peripheral venous injection, we have been particularly impressed by the clear images produced by DSA studies. Dextrophase imaging with DSA is comparable to that obtained by direct cardiac catheterization. Evaluation of the pulmonary venous system during the levophase is similar to selective pulmonary angiograms. Retrospectively, we were able to compare cardiac angiograms and DSA studies in 13 of our 17 patients. Only 2 patients in our study did not undergo routine cardiac catheterization (patient 7 [*Table 3*] and patient 4 [*Table 4*]). In all 13 patients analyzed, the DSA studies provided angiographic information that could have eliminated part of the routine cardiac catheterization procedure.

Digital subtraction angiographic QP/QS studies were performed for shunt determination in 7 patients and correlated well with the QP/QS findings at catheterization ($r = 0.89$, $P < 0.0001$).[4]

Two-dimensional and M-mode echocardiograms were obtained preoperatively in 13 out of 15 patients and were examined retrospectively. Seven echocardiograms of 9 patients were obtained at the time of DSA and cardiac catheterization. The correct diagnosis was made preoperatively in only 1 patient (patient 2, [*Table 4*]). However, right ventricular volume overload was found in all the echocardiograms suggestive of a left-to-right atrial shunt. In only 2 patients was the diagnosis of a left superior vena cava made or suggested by the echocardiogram.

The safety of DSA is especially important when considering its use with small children. Radiation exposure during the DSA study was 2–3 rads. None of our patients had complications severe enough to warrant medical care.

Therefore, our preliminary evaluation of DSA involving 17 patients with systemic and pulmonary venous anomalies confirms that it is a safe and effective technique. DSA afforded the op-

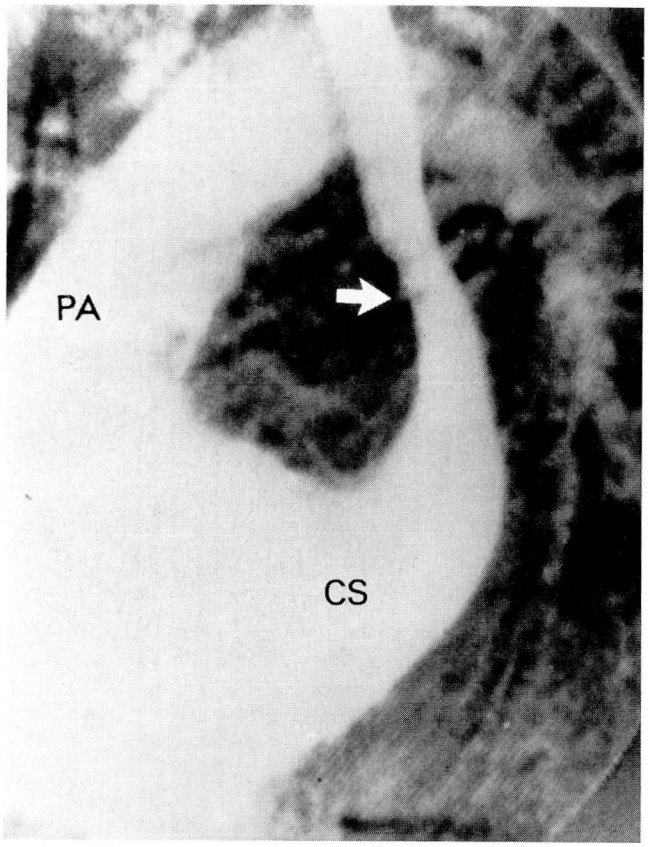

Fig. 4. Patient 5 (*Table 3*). DSA study via a peripheral intravenous injection of a 21-year-old woman who had a left superior vena cava (arrow) draining into the coronary sinus. The contrast material continues to flow from the right ventricle to the pulmonary artery. *CS* = coronary sinus, and *PA* = pulmonary artery.

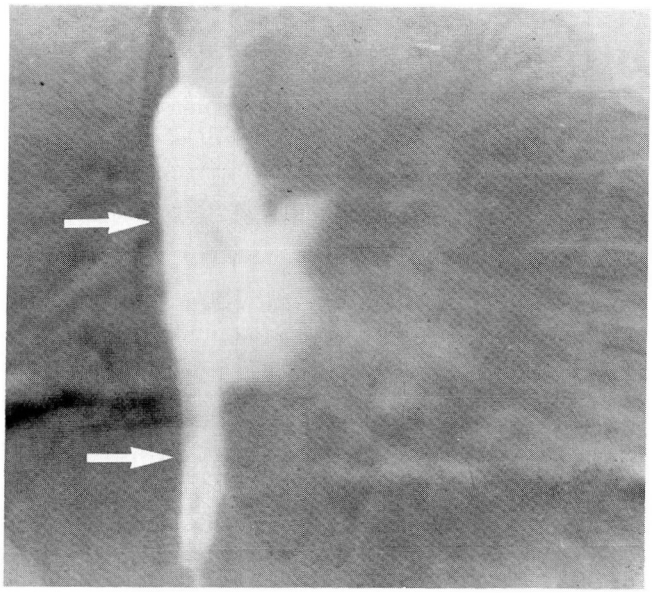

Fig. 5. Patient 1 (*Table 4*). DSA study of a three-day-old girl, demonstrating the azygous continuation (outlined by arrows) of the inferior vena cava as it drains to the base of the superior vena cava and then into the right atrium.

Downloaded from www.ccjm.org on April 19, 2024. For personal use only. All other uses require permission.

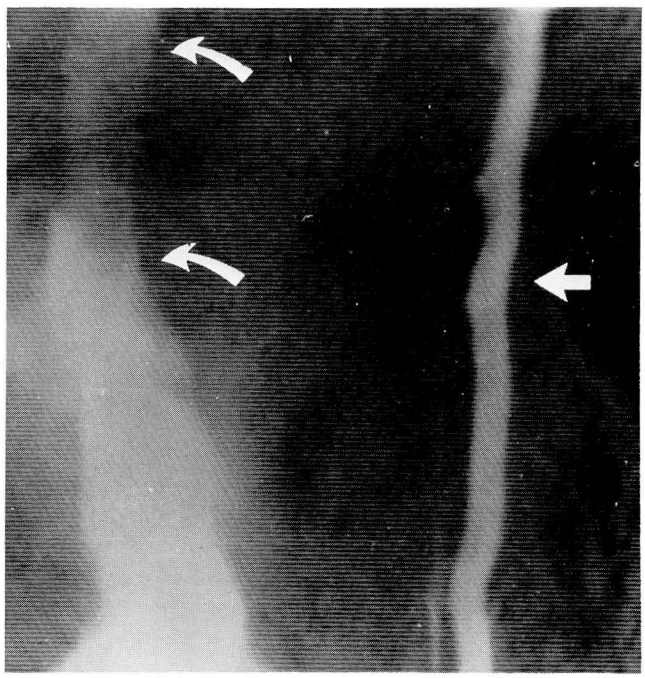

Fig. 6. Patient 2 (*Table 4*). DSA study of a 13-month-old boy, demonstrating the hemiazygous (single arrow) draining cephalad to the left innominate vein and on into the superior vena cava (outlined by curved arrows).

portunity for direct anatomic visualization of pulmonary and systemic venous anomalies and was superior to cardiac angiography and echocardiography for the evaluation of these defects. We believe that DSA may be the best method for postoperative outpatient evaluation of the results of surgery in patients who have partial or total anomalous venous return. Our investigation indicates that DSA provides significant anatomic information that is at least comparable to conventional angiography. It can be clinically useful in the diagnostic evaluation of patients with systemic and pulmonary venous anomalies.

Conclusions

Intravenous DSA is ideal for the evaluation of peripheral vessels. For all 17 patients described here, DSA studies provided significant information that could have eliminated some or all of the routine cardiac catheterization procedures. There were no complications following any of the DSA studies. We conclude that DSA is a safe and effective technique in the evaluation of systemic and pulmonary venous anomalies.

References

1. Buonocore E, Meaney TF, Borkowski GP, Pavlicek W, Gallagher J. Digital subtraction angiography of the abdominal aorta and renal arteries. Radiology 1981;**139:**281–286.
2. Moodie DS, Yiannikas J, Gill CC, Buonocore E, Pavlicek W. Intravenous digital subtraction angiography in the evaluation of congenital abnormalities of the aorta and aortic arch. Am Heart J 1982;**104:**628–634.
3. Moodie DS, Buonocore E, Yiannikas J, Gill CC, Pavlicek WA. Digital subtraction angiography in congenital heart disease in pediatric patients. Clev Clin Q 1982;**49:**159–171.
4. Yiannikas J, Moodie DS, Gill CC, Sterba R, McIntyre R, Buonocore F. Intravenous digital subtraction angiography in the assessment of patients with left to right shunts before and after surgical correction. JACC 1984;**3:**1507–1514.

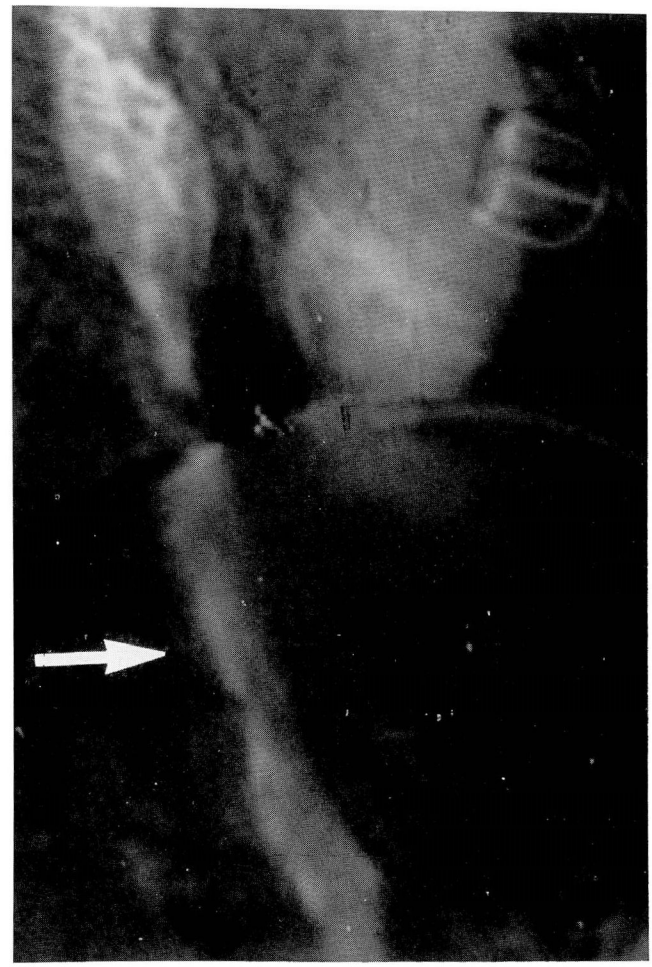

Fig. 7. DSA study of a 41-year-old man, performed 15 days after mitral valve replacement, shows a left vitelline vein (arrow) draining cephalad into a left superior vena cava, which continues into a large dilated coronary sinus. In addition, there is no direct communication between the inferior vena cava and right atrium.

Douglas S. Moodie, M.D.
Department of Cardiology
The Cleveland Clinic Foundation
9500 Euclid Ave.
Cleveland OH 44106

Downloaded from www.ccjm.org on April 19, 2024. For personal use only. All other uses require permission.