

Comparative accuracy of wall-motion analysis by digital subtraction and first-pass radionuclide ventriculography¹

Robert Detrano, M.D., Ph.D.
Conrad Simpfendorfer, M.D.
John Yiannikas, M.D.
Donald A. Underwood, M.D.
Ernest E. Salcedo, M.D.
Michael Rollins, M.D.

Forty-six patients referred for coronary angiography and direct contrast ventriculography were also examined using first-pass radionuclide and digital subtraction ventriculography for detection of wall motion abnormalities at rest. All three ventriculograms were reviewed by independent observers and the five wall segments graded on the right anterior oblique view as normal, mildly hypokinetic, moderately hypokinetic, severely hypokinetic, akinetic, or dyskinetic. Though the resting radionuclide ventriculogram was superior for identifying ventricles which were normal according to direct contrast ventriculography (89% versus 63%), digital subtraction ventriculography was more sensitive for identification of abnormal ventricles (100% versus 74%), particularly in identifying akinetic segments (77% versus 23%) and distinguishing segmental from diffuse ventricular dysfunction (100% versus 44%). Digital ventriculography caused overestimation of wall segment abnormality, while radionuclide ventriculography caused underestimation of segmental dysfunction. The authors conclude that digital subtraction ventriculography is more sensitive than radionuclide ventriculography but also less specific.

Index terms: Angiography • Coronary angiography • Subtraction technic

Cleve Clin Q 52:239-243, Summer 1985

¹ Departments of Cardiology and Nuclear Medicine, The Cleveland Clinic Foundation. Submitted for publication Oct 1984; accepted Feb 1985. sjh

0009-8787/85/02/0239/05/\$2.25/0

Copyright © 1985, The Cleveland Clinic Foundation

Both radionuclide and digital subtraction ventriculography (DSV) have been used to evaluate abnormal motion of the left ventricular wall at rest and during exercise.¹⁻⁴ While radionuclide studies are slightly less invasive, DSV gives high-resolution images which are comparable to direct contrast ventriculography (DCV).³ Initial reports indicate that DSV may be highly sensitive to significant coronary obstruction when performed during exercise,^{4,5}

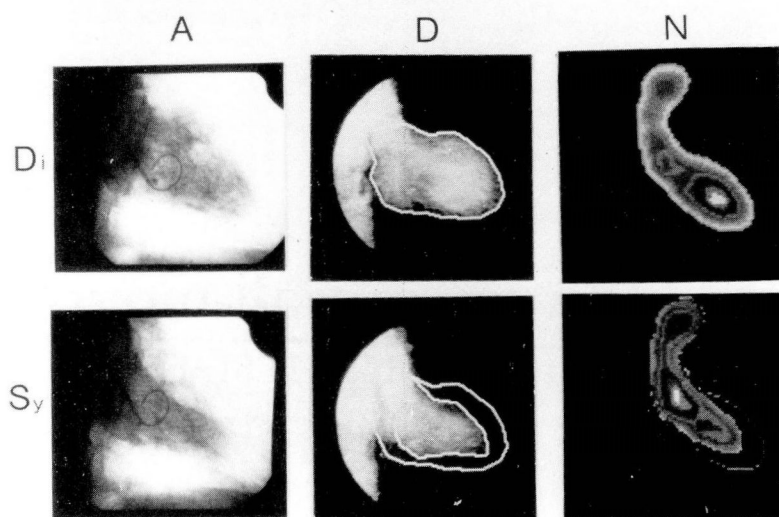


Fig. A 48-year-old man with a history of inferior infarction. A = direct contrast ventriculogram, D = digital subtraction ventriculogram, N = nuclear ventriculogram, Di = end-diastole; and Sy = end-systole.

and in fact its high spatial resolution may make it more sensitive than radionuclide imaging. We have compared digital and radionuclide ventriculography in 46 patients who were referred for coronary angiography and direct contrast ventriculography.

Materials and methods

Forty-one men and 5 women with a mean age of 58, weighing 58–93 kg (mean, 73), who were referred for coronary arteriography, consented to undergo both digital subtraction and first-pass radionuclide ventriculography. In order to obtain a homogeneous group of subjects with known or suspected coronary artery disease, patients with a history of other cardiac disorders were excluded. They were also excluded if they had kidney or heart failure or refused to give informed consent. Twenty-seven patients had a history of myocardial infarction and 21 had diagnostic Q waves on the electrocardiogram.

Digital imaging system

The digital imaging system we used (Philips Polydiagnost C and DVI 1) acquires, digitizes, logarithmically amplifies, and mask-subtracts at a rate of 30 frames per second. The resulting digitized and subtracted images are displayed in real time during acquisition and stored in analog form on videotape. Exposure factors are 65–80 mA and 60–90 kV, and the resolving power of the unit is 1.5 l.p./mm using a 512×512 matrix.

Digital subtraction ventriculography (DSV)

After first instructing the patient on the importance of breath-holding, the investigator inserted an 8-inch, 16-gauge catheter into an antecubital vein and connected it to a power injector loaded with methylglucamine diatrizoate (Renografin 76, Squibb). He then positioned the camera for a 30° right anterior oblique (RAO) view and told the patient to take a deep breath and hold it. The digital system acquired a 320-msec mask image and a brief run (1–2 sec) of visually satisfactory subtraction images, after which 0.5 ml/kg of contrast medium was injected at a rate of 10–15 mL/sec. Imaging continued until maximum left ventricle contrast was obtained.

Radionuclide ventriculography

On the day before or after DSV, first-pass radionuclide angiography was performed using a computerized multicrystal scintillation camera (Baird System-77). With the patient sitting upright and in the anterior position, 15 mCi of Tc-99m-diethylenetriaminepentaacetic acid (DTPA) dissolved in <1 mL of normal saline was rapidly injected into a right antecubital vein using a 20-gauge indwelling catheter. An additional 20 mL of saline was used to flush the tracer bolus into the central circulation. Data were recorded at a rate of 20 frames/sec for 30 seconds and stored on a magnetic disc. After correcting for crystal

uniformity and background activity, distinct left ventricular images could be identified and displayed.

Direct contrast ventriculography (DCV)

Within a week of radionuclide ventriculography and DSV, all 46 patients underwent selective coronary arteriography by the Sones or Judkins technique, taking several images of each vessel. During this procedure, DCV was performed with the patient in the 30° RAO position after injecting 40 mL of Renografin-76 directly into the left ventricle.

Image analysis

The ventriculograms produced by the three different methods (*Fig.*) were reviewed by two independent observers (six observers in all) without knowledge of the results of the other tests. The left ventricle was divided into five segments according to the qualitative reporting system of the American Heart Association: anterobasal, anterolateral, apical, diaphragmatic, and inferobasal.⁶ Each segment was graded from 1 to 6, with 1 = a normal contractile pattern, 2 = mild hypokinesis, 3 = moderate hypokinesis, 4 = severe hypokinesis, 5 = akinesis, and 6 = dyskinesis. (In analyzing the direct contrast images, premature and immediate post-premature beats were excluded.) Each of the 230 segments on the 46 radionuclide and 46 digital ventriculograms was compared with the corresponding segment on the 46 direct contrast ventriculograms, and the number of normal, hypokinetic, and akinetic segments correctly identified by either noninvasive technique was recorded. The direct contrast, radionuclide, and digital resting ventriculograms were also compared and categorized as normal (no wall motion abnormality) or abnormal (at least one abnormal segment). Ventricles assessed as abnormal on DCV were further classified as diffusely or segmentally abnormal. A ventriculogram without any normal segments, and in which no two abnormal segments differed by more than one grade, was considered diffusely abnormal. Abnormal ventricles with at least one normal segment, or two abnormal segments differing by more than one grade, were described as segmentally impaired. McNemar's test was used to compare the relative accuracy of radionuclide and digital ventriculography in identifying normal and abnormal ventricles and distinguishing diffuse from segmental abnormality. Because adja-

cent segments do not move independently, statistical testing was deemed inappropriate for comparison of individual segments.

Results

Of the 230 wall segments of the 46 direct contrast ventriculograms, 149 (65%) were judged to have a normal contractile pattern, 51 (22%) were hypokinetic (11 severe, 16 moderate, 24 mild), 30 (13%) were akinetic, and none were dyskinetic. *Table 1* shows the number of segments which were assessed correctly using resting radionuclide images and DSV. Of the 68 segments incorrectly assessed by at least one grade with DSV, 27 (40%) were off by at least two grades; on the other hand, on radionuclide ventriculography 77 segments were misjudged by at least one grade and 34 (44%) of these by at least two. On DSV segmental dysfunction was overestimated by an average of 0.11 grades per segment, compared with an overestimation of 0.20 grades per segment for radionuclide ventriculography. With DSV, overestimation was worse for the anterior and apical segments, averaging 0.20 grades per segment; with radionuclide ventriculography, underestimation was greater in the inferior segments (0.28 grades per segment) and apex (3) (0.54 grades per segment).

Nineteen of the 46 direct contrast ventriculograms were judged normal and 27 abnormal. All 27 were categorized as segmentally abnormal using our definition. *Table 2* lists the number of ventricles which were correctly identified as normal, abnormal, or segmentally abnormal. Digital ventriculography was significantly better for identifying abnormal ventricles ($P = 0.02$), particularly when it was segmental ($P < 0.001$). Though the radionuclide examination allowed correct identification of more normal ventricles than digital ventriculography, the difference was not significant ($P = 0.18$).

Discussion

Sensitivity

Sensitivity refers to the frequency of finding an abnormal contractile pattern when one is actually present. Subjective assessment of wall motion at rest with DSV was more sensitive to abnormality than subjective assessment of radionuclide ventriculograms: this is consistent with past observations^{3,7} and is not surprising given the higher spatial resolution of DSV. Assessment of wall motion with DSV also more accurately iden-

Table 1. Frequency of agreement between digital subtraction and radionuclide ventriculography for assessment of wall motion abnormalities

	Total	Digital subtraction ventriculography	Radionuclide ventriculography
Normal segments	149	123 (83%)	140 (94%)
Abnormal segments	81	71 (88%)	65 (80%)
Hypokinetic segments	51	34 (67%)	35 (69%)
Akinetic segments	30	23 (77%)	7 (23%)
Dyskinetic segments	0		
Total	230		

tified segmental abnormality as defined by direct contrast ventriculography. Though our definition was somewhat arbitrary, the results show that radionuclide ventriculography tended to "generalize" wall motion abnormalities. Since severe coronary artery disease more commonly produces segmental rather than diffuse ventricular dysfunction, this generalization might cause errors in diagnosis.

Specificity

Specificity refers to the frequency of finding a normal contractile pattern when one is actually present. *Tables 1 and 2* reveal that radionuclide ventriculography was more accurate with regard to classifying normal wall segments and ventricles at rest, though at the expense of decreased sensitivity: with it segmental abnormalities were underestimated by 0.20 grades per segment, while digital ventriculography led to overestimation by 0.11 grades per segment compared to DCV. In addition, digital ventriculography tended to lead to overestimation of anterior dysfunction, whereas insensitivity was primarily confined to the inferior segments with radionuclide ventriculography. The direction and magnitude of these errors might be helpful to clinicians in evaluating these noninvasive techniques.

Limitations of the study

Use of the anterior projection for first-pass radionuclide ventriculography and the 30° RAO

projection for digital ventriculography allowed a clear advantage for the latter technique, in that the projection was almost identical to that used for DCV. However, this cannot explain the poor performance of first-pass radionuclide ventriculography in detecting akinetic wall segments (23% versus 77%) nor the superiority of DSV in distinguishing segmental from diffuse dysfunction. More likely, these discrepancies are due to differences in spatial resolution with the two methods. The conclusion that DSV is more sensitive to wall motion abnormalities cannot be extrapolated to radionuclide ventriculography in general. The use of gated equilibrium rather than first-pass techniques might conceivably improve the sensitivity of the radionuclide method; until these speculations can be explored further our conclusions can be applied only to comparisons between digital and first-pass radionuclide ventriculography.

First-pass radionuclide ventriculography is particularly well suited to densitometry and other quantitative techniques for determination of regional ejection fractions and wall motion abnormalities.⁸ While these methods have been used for analysis in DSV,^{3,9} their accuracy has not been firmly established. We did not attempt to use these more objective and quantitative methods to assess the sensitivity of the two types of ventriculograms in the evaluation of wall motion abnormalities. Because of the rather high interobserver variability of subjective assessments, the

Table 2. Frequency of correct identification of normal, abnormal, and segmentally abnormal ventricles by digital and radionuclide ventriculography

	Total	Digital subtraction ventriculography	Radionuclide ventriculography	Significance level (P)
Normal	19	12 (63%)	17 (89%)	N.S.*
Abnormal	27	27 (100%)	20 (74%)	0.02
Segmentally abnormal	27	27 (100%)	12 (44%)	<0.001
Diffusely abnormal	0			

* N.S. = not significant.

results might have been different had we used more objective methods. However, subjective wall motion assessment is simple and rapid and enjoys widespread use in clinical settings; moreover, it has been shown to be fairly reproducible, at least for severely impaired segments.^{3,10,11}

Despite the evidence that digital ventriculography is more accurate for detection of wall motion abnormalities, it has some disadvantages and hazards that might favor first-pass radionuclide ventriculography in certain situations, including the greater difficulty of inserting a fairly large intravenous catheter into a peripheral vein and the occasional need to obtain access via the femoral or jugular vein. Renal impairment contraindicates injection of iodinated contrast media, but not radionuclides. While serious reactions to iodinated contrast agents are not common, they do occur; in contrast, we know of no reports of adverse reactions to Tc-99m-labeled-DTPA. Radiation doses during digital ventriculography are higher than those associated with first-pass radionuclide ventriculography, and digital ventriculography during exercise is also more difficult than first-pass radionuclide studies.

Acknowledgments

We owe our very deep appreciation to Paula LaManna for her secretarial assistance and to Judy Leatherman for the statistical calculations.

Conrad Simpfendorfer, M.D.
Department of Nuclear Medicine
The Cleveland Clinic Foundation
Cleveland OH 44106

References

1. Jones RH, McEwan P, Newman GE, et al. Accuracy of diagnosis of coronary artery disease by radionuclide measurement of left ventricular function during rest and exercise. *Circulation* 1981; **64**:586-601.
2. Jones RH, Floyd RD, Austin EH, Sabiston DC Jr. The role of radionuclide angiocardiology in the preoperative prediction of pain relief and prolonged survival following coronary artery bypass grafting. *Ann Surg* 1983; **197**:743-754.
3. Nissen SE, Booth D, Waters J, Fassas T, DeMaria AN. Evaluation of left ventricular contractile pattern by intravenous digital subtraction ventriculography: comparison with cineangiography and assessment of interobserver variability. *Am J Cardiol* 1983; **52**:1293-1298.
4. Yiannikas J, Simpfendorfer C, Detrano R, Salcedo EE, Sheldon WC. Stress digital subtraction angiography to assess presence of coronary artery disease in patients without myocardial infarction (abst). *Circulation* 1983; **68**:III-41.
5. Goldberg HL, Moses JW, Borer JS, et al. Exercise left ventriculography utilizing intravenous digital angiography. *J Am Coll Cardiol* 1983; **2**:1092-1098.
6. Gelberg HJ, Brundage BH, Glantz S, Parmley WW. Quantitative left ventricular wall motion analysis: a comparison of area, chord and radial methods. *Circulation* 1979; **59**:991-1000.
7. Low R, Nissen S, Booth D, Takeda P, DeMaria A. Evaluation of left ventricular function by digital subtraction ventriculography: comparison with cineangiography and assessment of interobserver variability (abst). *Circulation* 1982; **66**:II-228.
8. Maddox DE, Wynne J, Uren R, et al. Regional ejection fraction: a quantitative radionuclide index of regional left ventricular performance. *Circulation* 1979; **59**:1001-1009.
9. Mancini GBJ, Peterson KL, Gregoratos G, Higgins CB. Effects of atrial pacing on global and regional left ventricular function in coronary heart disease assessed by digital intravenous ventriculography. *Am J Cardiol* 1984; **53**:456-461.
10. Chaitman BR, DeMots H, Bristow JD, Rösch J, Rahimtoola SH. Objective and subjective analysis of left ventricular angiograms. *Circulation* 1975; **52**:420-425.
11. Dymond DS, Elliott A, Stone D, Hendrix G, Spurrell R. Factors that affect the reproducibility of measurements of left ventricular function from first-pass radionuclide ventriculograms. *Circulation* 1982; **65**:311-322.