

# Palliative treatment of malignant airway obstruction by Nd-YAG laser<sup>1</sup>

Atul C. Mehta, M.D.  
Joseph A. Golish, M.D.  
Muzaffar Ahmad, M.D.  
Andrew Zurick, M.D.  
Nilda Shanon Padua, M.D.  
James O'Donnell, M.D.

Photoresection using the neodymium-yttrium aluminum garnet (Nd-YAG) laser is an accepted modality for the treatment of unresectable symptomatic endobronchial lesions. The safety and efficacy of this technique when performed through a rigid bronchoscope have already been established. Forty-two such photoresection procedures were performed through a flexible fiberoptic bronchoscope at the Cleveland Clinic Foundation. The preoperative workup included sector computed tomography (CT) scanning of the mediastinum and/or magnetic resonance (MR) imaging of the chest. The results indicate that Nd-YAG laser photoresection can be safely performed using the flexible bronchoscope. Anatomic information provided by MR and sector CT may add to the safety of this procedure by allowing avoidance of major vessel perforation.

**Index terms:** Bronchial neoplasms • Laser coagulation

**Cleve Clin Q 52:513-524 Winter 1985**

<sup>1</sup> Departments of Pulmonary Medicine (A.C.M., J.A.G., M.A.), Cardiothoracic Anesthesiology (A.Z., N.S.P.), and Nuclear Medicine (J.O.), The Cleveland Clinic Foundation. Submitted for publication April 1985; accepted June 1985. ht

0009-8787/85/04/0513/12/\$4.00/0

Copyright © 1985, The Cleveland Clinic Foundation

Until very recently, treatment of unresectable malignant endobronchial lesions was limited to radiation therapy, chemotherapy, and, on rare occasions, cryotherapy or biopsy resection. Benefits were often unpredictable and results frustrating. Introduction of laser technology has added a new dimension in the management of such endobronchial lesions. Of the available laser systems, carbon dioxide, argon, and neodymium-yttrium aluminum garnet (Nd-YAG) lasers can be used to remove such obstructive lesions physically. This can be achieved by aiming precise laser energy at the target tissue via an endoscopic system, producing thermally induced dehydration, coagulation,

carbonization, or vaporization. When necessary, the coagulated tumor mass can be excised by forceps or removed by powerful suction. Palliation of the symptoms is thus achieved solely in closed fashion, without an incision or removal of functioning lung tissue.

Carbon dioxide laser light, because of its very long wavelength (10,600 nm), cannot be passed through a flexible quartz filament. Its use requires the rigid endoscopic system and is thus relegated only to central airway lesions. Even though argon laser light, with a shorter wavelength of 516 nm, can be transmitted via flexible quartz filaments, presently available commercial units generate relatively low power output. These units are unable to produce sufficient thermal energy to cause immediate effects, which are essential in the majority of the cases. The depth of tissue penetration of argon laser light is also limited due to its great absorption by tissue hemoglobin. These characteristics make the argon laser less than an ideal instant bulk-reducer.

The wavelength of Nd-YAG laser light is 1,050 nm, and it can be easily passed through a flexible quartz monofilament. Using the fiberoptic bronchoscope for direction, it can be aimed at lesions situated deep within the airways. Because of the poor affinity of both hemoglobin and water for that wavelength, Nd-YAG laser light penetrates tissue to a greater depth; therefore, of the currently available laser systems, the Nd-YAG one is the most efficient for coagulation of these lesions. If required, carbonization or vaporization of the tumor tissue can also be produced by setting the power output higher.

The thermal effect of Nd-YAG laser light was first used in the management of bleeding gastric lesions during 1977.<sup>1</sup> Animal experimentation by Rutgeerts et al<sup>2</sup> demonstrated the efficacy and safety of the Nd-YAG laser in the management of gastrointestinal hemorrhage. This prompted its application in the management of lesions of the lower respiratory tract. Following animal experimentation, Toty et al<sup>3</sup> and Dumon et al<sup>4</sup> outlined the methods for Nd-YAG laser photoresection of endobronchial lesions in humans. In the majority of their patients, the procedure was carried out through a rigid bronchoscope. During the early 1980s, McDougall and Cortese<sup>5</sup> reported successful use of Nd-YAG laser light through the fiberoptic bronchoscope in 20 patients with symptomatic unresectable malignant endobronchial lesions. Two other patients died

of massive hemorrhage from laser-induced damage to major vessels.

To study the efficacy and safety of the Nd-YAG laser system in the management of malignant endobronchial lesions, we carried out similar human experimentation under the guidelines approved by the Food and Drug Administration and the Institutional Review Board committee of the Cleveland Clinic Foundation. The following article presents our technique, results, and guidelines from our experience.

## Materials and methods

### *Indications*

Indications for Nd-YAG laser photoresection included presence of unresectable exophytic malignant endobronchial lesions involving the trachea or major bronchi. In all cases, these lesions were symptomatic, producing hemoptysis, dyspnea, asphyxiation, postobstructive pneumonitis, or collapse of one or more lobes of the lung (or the entire lung). These indications were established by initial history and physical examination, chest radiography, and fiberoptic bronchoscopy. Diagnosis of malignancy was established by endobronchial biopsy or by review of available pathology slides from previous procedures. All of these patients were considered to have unresectable disease, either because of the extent of the disease or due to cardiopulmonary limitations. Laser therapy was chosen only after failure of standard therapy, unless the patient's health was suspected to be in imminent danger. In that case, laser therapy was carried out prior to or during ongoing radiation or chemotherapy. Cell type of tumor did not affect the decision.

Detailed informed consent was obtained from each individual undergoing laser therapy.

### *Laboratory studies*

Routine pretherapy work-up included hemogram; kidney, liver, and nutritional profile (SMA-18); prothrombin time; activated partial thromboplastin time; arterial blood gases; chest radiography and screening spirometry with bronchodilators. Four units of typed and cross-matched whole blood were kept available for emergency use.

In all of the patients whose physical condition permitted, both contrast-enhanced sector CT scanning of the mediastinum and magnetic resonance (MR) imaging of the chest were performed

to study the proximity of each lesion to the major vascular structure of the thorax. This information was used to map out those areas where injury could lead to massive bleeding from the adjacent blood vessel. Complete pulmonary function studies (PFTs), including flow-volume loops, with and without bronchodilators were performed whenever possible.

Degree of impairment in overall pulmonary function was gauged by several different modalities, depending upon the site of the lesion, degree of airway obstruction, and chest radiographic findings. For example, flow volume loop studies were used in patients with tracheal lesions, while quantitative ventilation and perfusion lung scanning were used to assess regional lung function in patients with obstruction of a lobe or whole lung. These studies, along with chest radiography and PFT, were repeated following laser therapy to determine the degree of improvement.

Photographic bronchoscopic documentation of the lesion and airway patency was carried out before and after the therapy.

#### *Anesthesia*

Preanesthesia preparation included a preoperative visit and fasting for at least eight hours prior to the induction of anesthesia. Premedications included intramuscular administration of meperidine hydrochloride (HCl) 1 mg/kg of body weight, hydroxyzine HCl 20–50 mg, and atropine sulfate 0.3–0.6 mg one-half hour prior to the procedure if no contraindication existed. Subacute bacterial endocarditis prophylaxis was instituted based on the recommendations established by the American Heart Association.<sup>6</sup> Blood products were kept available based on the patient's preoperative hemogram and coagulation status.

The endoscopic procedure was performed with local, attended local, or general anesthesia. All patients were monitored with electrocardiography and received supplemental oxygen. Intravenous infusion of lactated Ringer's solution by large-bore intravenous catheter was carried out at the rate of 1–2 ml/kg body weight/hr in all patients. Local anesthesia was preferred for patients who tolerated the initial bronchoscopy without any significant discomfort or who were poor-risk candidates for general anesthesia and had relatively small lesions or a high tracheal lesion. If, at any point during the procedure,

patient discomfort or difficulties with the airway occurred, general anesthesia was available for use.

Local anesthesia was obtained by gargle with 2% lidocaine solution and application of 2% lidocaine jelly in the nostril, through which the flexible fiberoptic bronchoscope was introduced. Periodic endoscopic instillation of 2% lidocaine solution in boluses of 40 mg each was carried out as needed, but not exceeding 400 mg in any given 45-minute period.

When general anesthesia was used, all patients had an arterial line inserted. Patients with significant cardiovascular disease had a thermistor-tipped pulmonary artery catheter placed. General anesthesia was induced by pretreatment with a nondepolarizing muscle relaxant (pancuronium 1.5–2 mg intravenously or curare 3–5 mg intravenously) followed by slow intravenous administration of sodium pentothal 3–5 mg/kg or etomidate 0.2–0.3 mg/kg of body weight. With loss of the eyelash reflex, succinylcholine was given intravenously in the dosage of 1–1.5 mg/kg of body weight for muscle relaxation to facilitate endotracheal intubation or introduction of the rigid bronchoscope. A standard 9.5-mm polyvinyl chloride tube was used when the procedure was performed with the flexible scope. It was positioned such that the cuff site remained just below the vocal cords. This allowed a safe distance between the tumor site and the inflammable tip of the tube. For management of more proximal tracheal lesions, the portion of the tube distal to the cuff was cut off and the cuff channel was sealed with silicon cement. High tracheal lesions were treated with the rigid bronchoscopy system for laser therapy (R. Wolf Co.) of Dumon et al.<sup>7</sup> Patients were ventilated through the anesthesia port of the rigid bronchoscope, and the procedure was performed through a closed system.

Anesthesia was maintained by enflurane 0.5–3% in oxygen or room air. The fraction of inspired oxygen was kept below 50% during actual firing of the laser. The patients were allowed to breathe spontaneously throughout the procedure and ventilation was periodically assisted manually.

Topical lidocaine was used through the channel of the fiberoptic bronchoscope when coughing was encountered despite the general anesthesia. If this failed to control the cough, then a deeper level of general anesthesia was attempted.

**Table 1.** Major presenting symptoms

Symptom	No. Patients
Progressive dyspnea	26
Asphyxiation/stridor	6
Hemoptysis	4
Intractable cough	3

**Table 2.** Type of lung cancer

Type	No. Patients
Primary lung tumors	
Squamous-cell carcinoma	17
Large-cell carcinoma	8
Small-cell carcinoma	3
Adenocarcinoma	2
Metastatic lesions	
Renal-cell carcinoma	5
Follicular carcinoma of thyroid	1
Ciliary body tumor of the eye	1
Malignant-fibrous histiocytoma	1
Squamous-cell carcinoma of the cervix	1

**Table 3.** Location of lesion

Location	No. Patients
Trachea	12
Carina	1
Left main bronchus	11
Right main bronchus	10
Intermediate bronchus	5

However, if hypotension or myocardial depression occurred, nondepolarizing muscle relaxants were used and ventilation was mechanically controlled.

At the end of the procedure, residual neuromuscular blockage was reversed with prostigmine 0.08 mg/kg and atropine 0.02 mg/kg intravenously. Patients were extubated when they awoke and achieved negative inspiratory force of more than 25 ml of water and forced expiratory volume of 10 ml/kg. Oxygen supplementation was continued while the patient was in the postanesthesia recovery room.

#### *Procedure*

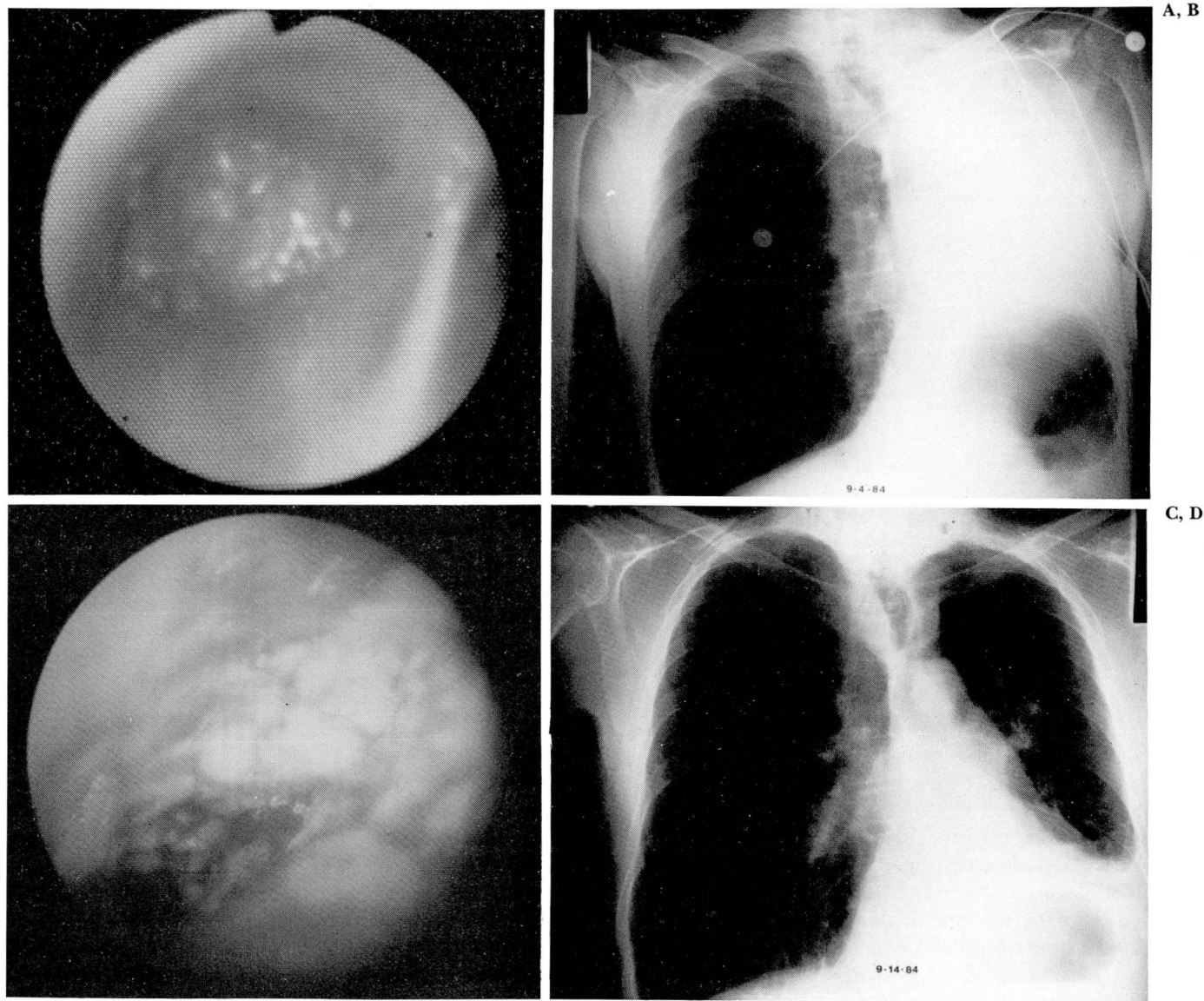
When local anesthesia was used the fiberoptic bronchoscope Olympus BF1TR was introduced transnasally or transorally. When the patient was

under general anesthesia the bronchoscope was passed through the endotracheal tube. When the rigid bronchoscope was used, the single common channel was used for ventilation, the laser fiber, and the suction catheter. The tumor was located and documented photographically.

A molelectron unit 8000 was used to generate Nd-YAG laser light. Light energy was transmitted via a flexible quartz monofilament 1.9 mm or 2.2 mm in diameter. This was introduced via the working channel of the fiberscope or through a special port on the rigid scope. Continuous coaxial flow of air through the plastic tubing surrounding the fiber kept its temperature cool and the tip clean. To preserve the cleanliness of the tip of the fiber, a distance of about 5 mm was kept between the tumor site and the tip of the fiber. When the fiber was not being used, the tip was periodically cleaned with hydrogen peroxide and alcohol solutions. The tip of the fiber was pushed out at least three-fourths to one cm away from that of the fiberscope as a precaution to prevent damage to the instrument. This was not a concern when the rigid scope was used.

Repeated pulses of light energy were generated by pressing the foot switch. Laser light was aimed at tumor tissue, keeping the beam parallel to the wall of involved airway. Dosage of energy varied from 40–65 watts/sec for 0.4–0.5 seconds, initially starting with the lower settings and increasing the output level as needed to get the desired tissue effect. In most instances, coagulation (pale discoloration) or carbonization (black discoloration) of the tissue was performed to produce vascular sclerosis and tumor shrinkage. Tumor was then excised piecemeal with the help of flexible forceps (universal forceps when the rigid scope was used). This sequence was repeated several times until total patency of the involved airway was achieved or as much endotracheal tissue as possible was removed. To maintain the efficiency of the surgeon, the procedure was terminated at five hours of operating time; if optimal results had not been obtained by then, the procedure was repeated two days later to remove remaining tissue. Obtaining multiple biopsy specimens with a single insertion of the forceps, use of a Dormia basket, snares, and flexible scissors all helped to remove large pieces of tumor tissue and thus shorten the duration of the procedure. Frequently high-wattage and long-duration pulses were fired repeatedly at the same target area to ablate tissue by vaporization.





**Fig. 1.** A 62-year-old man with squamous-cell carcinoma of the lung. Exophytic, hemorrhagic lesions produced total occlusion of the left main bronchus (A) and complete collapse of the left lung (B). Following Nd-YAG laser photoresection of the endobronchial lesion, a patent left main bronchus (C) and re-expansion of the left lung (D) are seen.

On occasion, the rigid scope itself was used to shear off lased tumor from the airway wall.

Small to moderate amounts of bleeding from the tumor site were often encountered during the procedure. This was successfully treated in the majority of instances by laser photocoagulation of the encircling area. Suctioning of blood through the working channel of the fiberoptic scope required removal of the laser fiber. Through this channel, 2-4 ml of epinephrine or norepinephrine, dilution 1:10,000, was instilled

endobronchially while cardiovascular parameters were monitored. The rigid bronchoscopy system permitted simultaneous use of the laser fiber and the suction catheter. When necessary, the body of the rigid scope was used directly for tamponade of the bleeding site.

**Results**

Thirty-nine patients, 28 men and 11 women, between the ages of 44 and 86 years (mean age 62) underwent 44 treatments. In five patients,



A, B

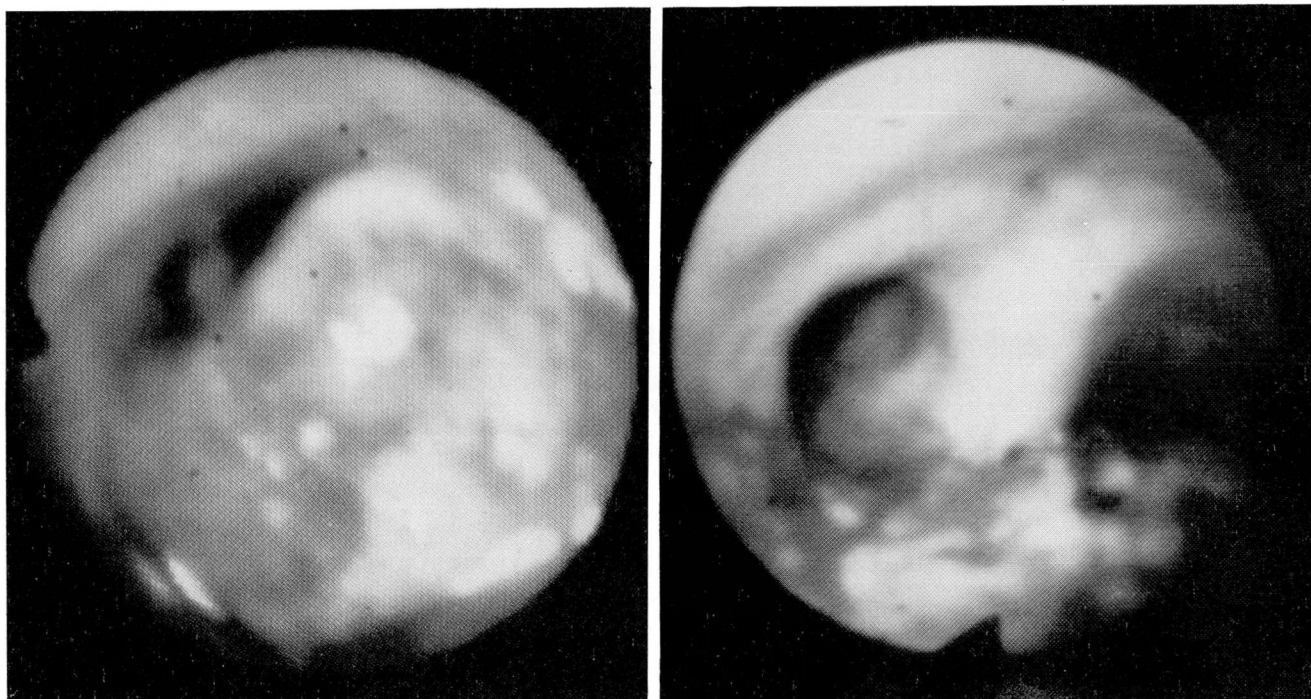


Fig. 2. Before laser treatment there was a 95% occlusion of the trachea by large-cell carcinoma of the lung (A); after photoresection by Nd-YAG laser total patency of the trachea is seen (B).

the initial treatment was terminated at five hours of operating time. In these patients, a second treatment was required to remove any residual endobronchial lesion. This was performed 48–72 hours after the initial treatment, but during the same hospitalization.

During periodic follow-up, any patient showing signs of recurrence of the endobronchial lesion and requiring repeat laser therapy was put into the category of new patients. There were five such patients, and one of them required three separate treatments. *Table 1* lists the chief complaints; the majority of the patients had more than a single complaint.

Radiographic findings varied from normal chest radiograph to total collapse of either of the lungs. All except five patients underwent sector CT of the mediastinum with contrast enhancement. Eighteen patients had both CT scanning and magnetic resonance (MR) imaging of the chest. Because of the continuous flow of blood, no signal is recorded from blood vessels with MR. This feature of MR helped to outline the relationship between the involved airway and the major blood vessels much better than CT in eight

(47%) patients. The MR and CT studies were equally diagnostic in seven (40%) cases. In three cases (13%) MR was not as diagnostic as CT because of patient motion degradation of images and partial-volume averaging due to section thickness.<sup>8</sup>

Incidence of lesions by cell type is listed in *Table 2*. *Table 3* lists sites of the lesions. Depending upon the endobronchial extent, lesions were divided into two categories, focal or multifocal. If the tumor process involved a single wall of the airway or extended contiguously to the adjacent wall, the lesion was labeled as focal disease. If the lesion involved more than one wall or the same wall but at different levels, in noncontiguous fashion, it was labeled multifocal disease. If the focal disease extended more than 4 cm in length, it was called “focal extensive” disease, while focal lesions shorter than 4 cm were labeled as “focal limited.” In all patients with multifocal disease, the disease was extensive. Twenty-two patients had focal limited disease, while nine patients had focal extensive disease. Eight patients had multifocal disease.

Degree of airway obstruction was expressed as



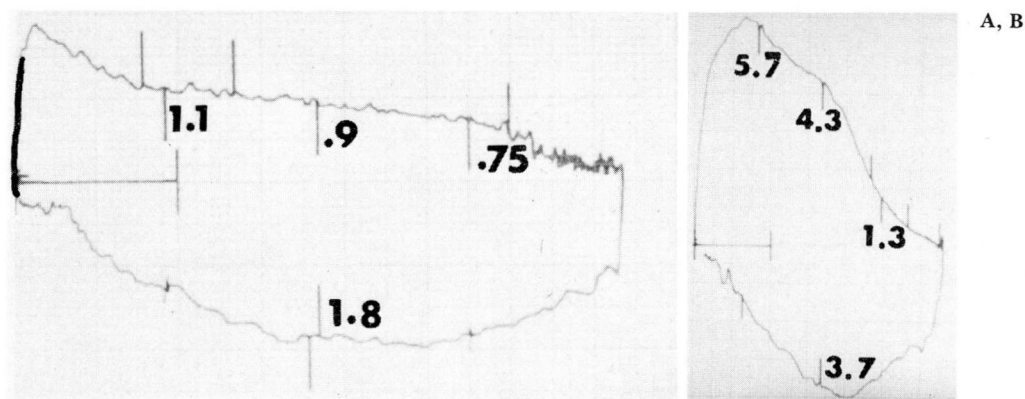


Fig. 3. Flow volume loop studies before (A) and after (B) laser therapy, same case as *Figure 2*.

percentage of airway lumen occupied by the lesion, and it was gauged before and after the procedure. In five patients, there was 100% occlusion of the involved airway (three right and two left main bronchus) prior to the procedure. In one of these patients, there was 90% occlusion of the right main bronchus by small-cell carcinoma at the time of initial bronchoscopic evaluation, but total occlusion was found 48 hours later when the laser therapy was done. In another patient with total occlusion of the left main bronchus, there was radiographic evidence of normal aeration of the left lung just two weeks prior to the procedure, and the sector CT study of the mediastinum demonstrated patency of the airway distal to the obstruction. In the remaining three patients, no distal lumen beyond the obstruction could be visualized endoscopically or by radiographic studies, but flexible forceps could be easily passed past the side of the lesion to the distal lumen.

Twenty patients had received radiation therapy, two patients had received chemotherapy, six had received both radiation and chemotherapy, and 11 had no prior chemotherapy or radiation therapy. This latter group of patients had asphyxiation, progressive hemoptysis, postobstructive pneumonitis, or total collapse of either lung. Their status was such that immediate palliation was required. Because of the delayed response of these non-small-cell carcinomas to standard radiation or chemotherapy, the laser was used as the initial therapeutic modality.

Thirty-nine procedures were performed using general anesthesia, 37 of them using the flexible bronchoscope introduced via conventional poly-

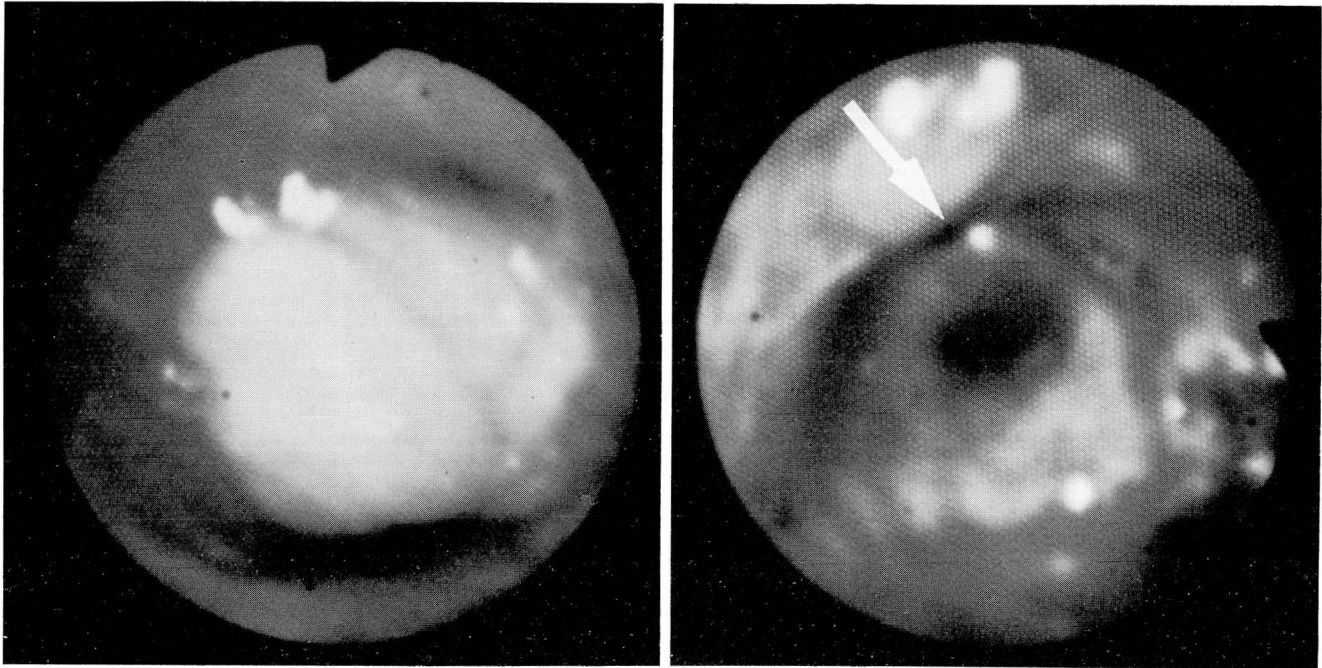
vinyl chloride endotracheal tube and the remaining two using the rigid bronchoscopy system of Dumon et al.<sup>7</sup> Of the latter two patients, one had a high tracheal lesion from metastatic follicular carcinoma of the thyroid and the other had recent total occlusion of left main bronchus by an extremely friable and hemorrhagic lesion (*Fig. 1*). In one other patient, pulmonary hemorrhage was encountered immediately following endotracheal intubation and a rigid bronchoscope was required to establish ventilation and remove large blood clots (*vide infra*). Five procedures were performed using local anesthesia and the transnasal route with the fiberoptic scope.

To study the outcome of the therapy, all patients were re-evaluated within 48 hours following the procedure by questioning about subjective improvement and obtaining posteroanterior and lateral radiographs of the chest. Additionally, flow volume loop studies or quantitative ventilation-perfusion lung scanning, whichever had been performed prior to the procedure, was repeated to study the degree of improvement.

In patients with presenting symptoms of intractable cough, hemoptysis, or asphyxiation resolution of symptoms so that cough suppressants, sedatives, or endobronchial intubation were not required was considered as an "excellent" result. If, along with symptomatic improvement, flow volume loop study (*Figs. 2 and 3*) or quantitative ventilation-perfusion lung scanning (*Figs. 4 and 5*) showed more than 20% improvement in flow rates or nuclear count, this was also considered an "excellent" result. Resolution of postobstructive pneumonia was also categorized as having an "excellent" result (*Fig. 6*). If patients reported



A, B



**Fig. 4.** Squamous-cell carcinoma arising from right upper lobe bronchus produces 80% occlusion of the intermediate bronchus (A). After photoresection of the endobronchial lesion, the right lower and middle lobe bronchi (arrow) are visualized (B).

remarkable improvement in the symptoms without significant change in above-mentioned objective parameters, results were considered "good." If there was no subjective or objective improvement following the procedure, then the results were considered "poor." These results are listed in *Table 4*. All patients with focal limited disease had either excellent or good results. Two of ten patients with focal extensive disease and four of eight patients with multifocal disease had excellent results. All three patients with poor results had focal extensive disease with 100% occlusion of the involved bronchus of unknown duration. Two other patients with total occlusion of the airway of less than two weeks duration had excellent results.

**Table 4.** Results\*

Results	Type of Lesion			%
	Focal Localized	Focal Extensive	Multifocal	
Excellent	15	3	4	58%
Good	7	3	3	34%
Poor		3†		8%

\* One patient died of a myocardial infarction.

† These patients had 100% occlusion of involved airway.

### Complications

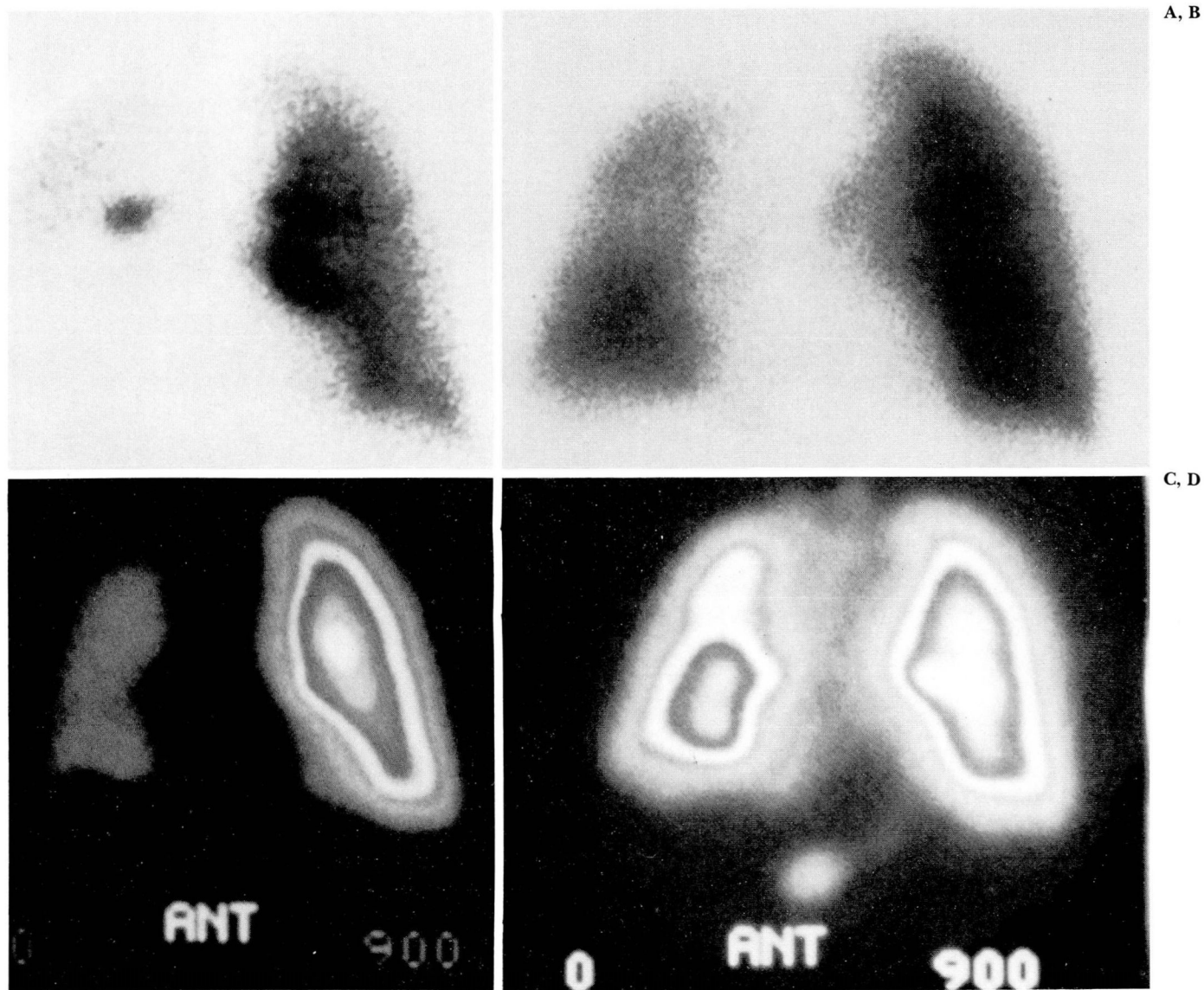
Out of the group of 39 patients, four patients encountered some ill effects from the procedure.

A 51-year-old white woman with squamous-cell carcinoma metastatic from cervix to the left main bronchus reacted to blood transfusion during laser photoresection with sudden hypotension ten minutes following the beginning of transfusion. The hypotension responded favorably to fluids, intravenous Benadryl (diphenhydramine hydrochloride), and an extra dose of steroids.

A 42-year-old white man with tracheal metastases from follicular carcinoma of the thyroid had laser therapy performed through the rigid scope; intubation was difficult because of previous extensive thyroid surgery. After laser therapy, this patient had sore throat and swelling of the vocal cords and epiglottis, requiring use of steroids.

A 75-year-old white man with large-cell carcinoma involving the trachea had pulmonary hemorrhage immediately following intubation. Endotracheal-tube-induced trauma to the lesion led to bleeding of 500 ml in five minutes. Rigid bronchoscopy was required to remove clots and establish ventilation. The Nd-YAG laser was used to cauterize the surface of the lesion, and was





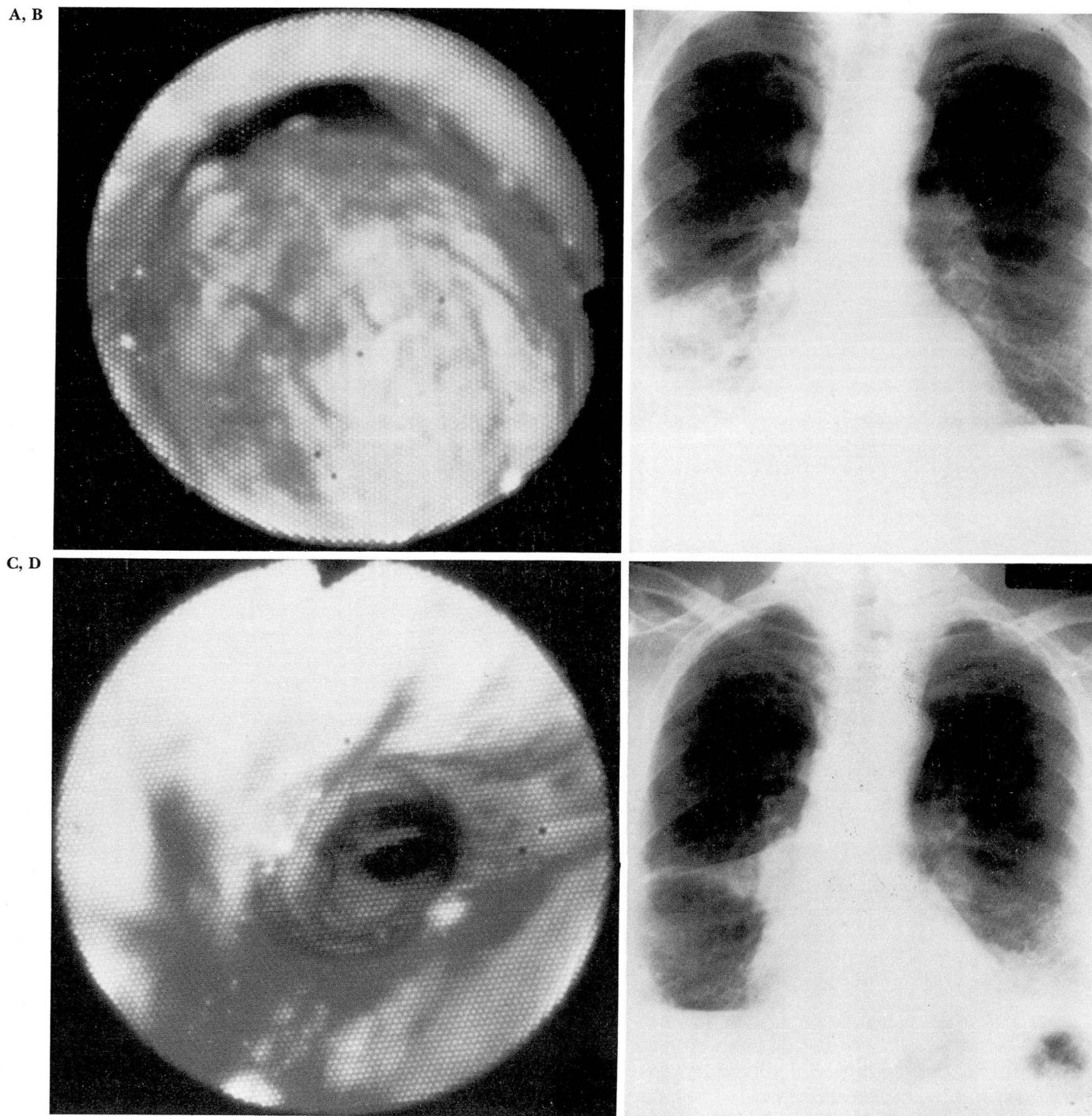
**Fig. 5.** Ventilation-perfusion scans before and after Nd-YAG laser photoresection, same case as *Figure 4*. Quantitative xenon ventilation lung scan before laser therapy (**A**) shows 0% ventilation to right lung and after therapy (**B**) shows 47% ventilation to right lung. Quantitative perfusion lung scan before laser therapy (**C**) shows 6% perfusion to right lung and after therapy (**D**) shows 32% perfusion to right lung.

successful in controlling the bleeding. After a three-day stable postoperative course, the patient died suddenly of massive hemoptysis and asphyxiation. Autopsy revealed invasion of pulmonary artery by tumor.

A 57-year-old man with known history of coronary artery disease and myocardial infarction was prepared, using nitrates, for surgery. He successfully underwent laser therapy, under general anesthesia, for squamous-cell carcinoma of the bronchus. Ten minutes following the comple-

tion of the procedure, while still intubated, hypotension, bradycardia, and eventually cardiopulmonary arrest developed. Efforts at resuscitation were unsuccessful. Autopsy findings were compatible with recent ischemic myocardial injury along with total occlusion of the diagonal, proximal, and distal left anterior descending artery, 75% stenosis of the left mainstem artery, 95% stenosis of the circumflex artery, and 50% stenosis of right coronary artery. Small left and right pneumothoraces were thought to be due to





**Fig. 6.** A 99% occlusion of the intermediate bronchus by squamous-cell carcinoma is seen (A), leading to postobstructive pneumonia (B) in the right middle and lower lobes. After Nd-YAG laser photoresection a patent intermediate bronchus is seen (C), leading to resolution of postobstructive pneumonia (D).



chest compression and prophylactic chest tube insertion, respectively.

In our series, no complications related to direct injury from the laser beam, *i.e.*, perforation of the major vessels, pneumothorax, or tracheoesophageal fistula, were noticed. The maximum amount of energy used for one single treatment was up to 22,000 watts-sec (joules). However, no heat-related damage to the endotracheal tube or fiberoptic bronchoscope were noticed.<sup>9</sup> In a case of benign tracheal stricture, not reported in this article, the metal tip was dislodged from the laser fiber. It was not recoverable from the peripheral bronchus in which it lodged, but no ill effects developed.<sup>10</sup>

### Conclusion

This study shows that Nd-YAG laser photoresection is valuable in the management of unresectable, symptomatic, malignant central airway lesions. The procedure can be repeated as many times as required and benefits are immediate. Data confirm that if due precautions are taken, laser therapy can be safely performed through the flexible fiberoptic bronchoscope.<sup>11</sup> We have followed the following safety procedures during each of our procedures performed with flexible endoscopy:

- (i) Studying mediastinal anatomy by sector CT or MR, outlining dangerous areas to be avoided.
- (ii) Keeping the maximum distance between the tip of the endotracheal tube and the tumor site.
- (iii) Extending the laser filament at least 5 mm beyond the tip of the fiberoptic scope during firing.
- (iv) Aiming the laser beam parallel to the wall of involved airway.
- (v) Using low-power (40–65 watts) short-duration (0.4–0.5 sec) pulses, in volleys of no more than 25–30, temporally spaced at least 5 seconds apart.
- (vi) Keeping the metal tip of the laser fiber free of any carbon particles or tissue deposits, which could ignite by absorbing laser energy.
- (vii) Keeping the fraction of supplemental oxygen as low as possible during the actual firing of the laser.

We recommend use of a rigid bronchoscopic system while treating high tracheal and very hemorrhagic lesions. This system allows the simultaneous use of a 3-mm suction catheter and laser

filament. In the event of massive endobronchial bleeding, the laser filament can be replaced by a second suction catheter and removal of larger blood clots facilitated. The body of the rigid scope can also be used for tamponade of the bleeding site and to establish an airway beyond the lesion or in the contralateral bronchus.<sup>7</sup> Even while performing this procedure through a fiberoptic scope, availability of the rigid scope as a backup is advisable.

In terms of patient selection, patients with focal limited disease are good to excellent candidates. Patients with focal extensive disease and 100% occlusion of the airway are poor candidates for the procedure unless the total occlusion is of less than two weeks duration. The majority of these patients have a heavy smoking history, and besides having chronic obstructive pulmonary disease are also likely to have coronary artery occlusion. This makes them poor candidates for general anesthesia and due precautions should be taken. The risk of general anesthesia can be minimized by close collaboration with an anesthesia team well versed in the complexities of obstructed airway management during laser therapy.

In conclusion, in selected cases of unresectable malignant endobronchial lesions, Nd-YAG laser therapy can palliate symptoms and prolong survival. However, it is difficult to determine long-term efficacy of this modality from this short-term study. Additional studies will be required to determine the laser's role relative to standard modalities such as external radiation and chemotherapy. Newer techniques, such as photodynamic therapy and brachytherapy, will also need to be evaluated to determine the particular role of each of these measures in therapeutic bronchology.

### Acknowledgement

We express our sincere thanks to Sandra Saunderson, R.N., (bronchoscopy room nurse), Nancy Marcina, R.N. (cardiothoracic operating room nurse), Evelyn Moya, C.R.N.A., and George Skipper (Biomedical Engineering), for their valuable help in making this project successful.

### References

1. Kieffhaber P, Nath G, Moritz K. Endoscopic control of massive gastrointestinal hemorrhage by irradiation with a high-power neodymium-YaG laser. *Prog Surg* 1977; 15:140–155.

2. Rutgeerts P, Vantrappen G, Geboes K, Broeckaert L. Safety and efficacy of neodymium-YAG laser photocoagulation: an experimental study in dogs. *Gut* 1981; **22**:38-48.
3. Toty L, Personne C, Colchen A, Vourc'h G. Bronchoscopic management of tracheal lesions using the neodymium yttrium aluminum garnet laser. *Thorax* 1981; **36**:175-178.
4. Dumon JF, Reboud E, Garbe L, Aucomte F, Meric B. Treatment of tracheobronchial lesions by laser photoresection. *Chest* 1982; **81**:278-284.
5. McDougall JC, Cortese DA. Neodymium-YAG laser therapy of malignant airway obstruction, a preliminary report. *Mayo Clin Proc* 1983; **58**:35-39.
6. Kaplan EL, Anthony BF, Bisno A, et al. Prevention of bacterial endocarditis. *Circulation* 1977; **56**:139A.
7. Dumon JF, Shapshay S, Bourcereau J, et al. Principles for safety in application of neodymium-YAG laser in bronchoscopy. *Chest* 1984; **86**:163-168.
8. Ross J, O'Donovan P, Mehta A, Golish J. Magnetic resonance vs CT in the preoperative evaluation of laser therapy for airway obstruction. (unpublished data).
9. Casey KR, Fairfax WR, Smith SJ, Dixon JA. Intratracheal fire ignited by the Nd-YAG laser during treatment of tracheal stenosis. *Chest* 1983; **84**:295-296.
10. Mehta A, Golish J, Livingston D. Loss of tip of laser fibre in the endobronchial tree—An unusual complication. Letter to the editor. *Chest* (In press).
11. Brutinel WM, Cortese DA, McDougall JC. Bronchoscopic phototherapy with the neodymium-YAG laser. Editorial. *Chest* 1984; **86**:158-159.

Department of Pulmonary Medicine  
The Cleveland Clinic Foundation  
9500 Euclid Avenue  
Cleveland, OH 44106