

# Endomyocardial fibrosis

## Diagnosis and surgical treatment of two cases occurring in the United States<sup>1</sup>

Douglas S. Moodie, M.D.  
Joan E. Baum, D.O.  
Carl C. Gill, M.D.  
Norman B. Ratliff, M.D.

Two cases of endomyocardial fibrosis seen in the state of Ohio are described and related to the incidence and prevalence of endomyocardial fibrosis throughout the world. The pathophysiology and clinical findings are reviewed, along with the various forms of medical and surgical therapy. The unique nature of this condition allowed a diagnosis prior to surgery in the second case. Endomyocardial biopsies might be useful not only to diagnose the disease, but also to stage its activity. This may be an important consideration in other countries where the disease is more common and earlier operation has been proposed.

**Index term:** Endomyocardial fibrosis

**Cleve Clin Q** 53:159-170, Summer 1986

Endomyocardial fibrosis was described by Davies<sup>1</sup> in 1948 and is a restrictive-obliterative cardiomyopathy of unknown etiology. It occurs particularly in tropical countries and is very common in parts of Central Africa, but has rarely been reported in North America. The natural history is one of progressive heart failure with a mean survival of only two years when treated with conventional medical therapy.<sup>2</sup> We report two cases of endomyocardial fibrosis that occurred in the United States and were treated surgically.

### Case reports

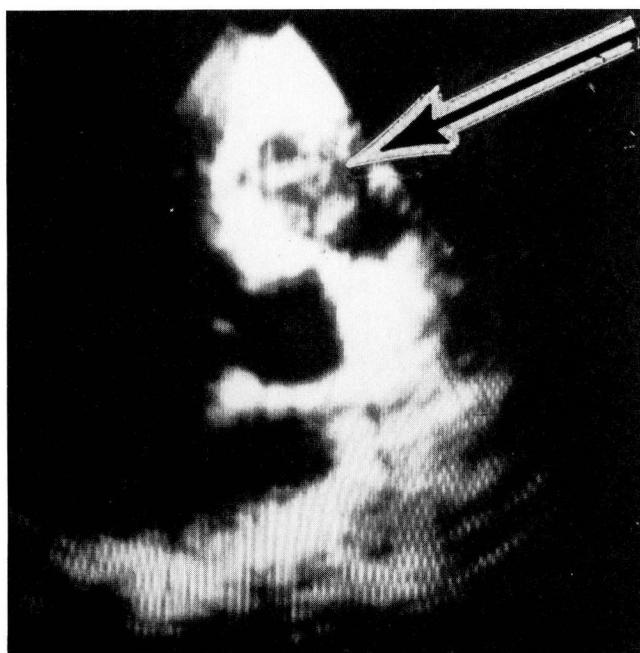
**Case 1.** A 19-year-old Ohio student was admitted to the hospital because of suspected endocarditis and aortic insufficiency. He had been an athlete in excellent health until three months prior to admission, when he noticed dyspnea on exertion, decreased exercise tolerance, and

<sup>1</sup> Department of Cardiology, The Cleveland Clinic Foundation. Submitted for publication Nov 1985; accepted Jan 1986.

ht

0009-8787/86/02/0159/12/\$4.00/0

Copyright © 1986, The Cleveland Clinic Foundation



**Fig. 1.** Case 1. Two-dimensional echocardiogram, apical view. The arrow points to a mass of echoes in the right ventricular apex.

lightheadedness. Three weeks prior to admission he had postnasal drip, pharyngitis, and a dry cough followed by night sweats associated with a fever of  $37.8^{\circ}\text{C}$  to  $38.3^{\circ}\text{C}$ . He had been raised on a farm and had worked stripping tobacco leaves the month preceding the onset of his symptoms. He had also had his teeth cleaned during that time. There was no history of drug abuse or travel outside the United States.

He was admitted to another hospital and blood cultures were negative, however, he had previously received several doses of penicillin as an outpatient. Systolic and diastolic heart murmurs were heard for the first time. Treatment of suspected bacterial endocarditis was begun with high-dose intravenous penicillin and streptomycin. Cardiac catheterization was performed; the right atrial, right ventricular, and pulmonary artery pressures were at the upper limits of normal. The pulmonary wedge pressure was normal, and no oxygen step-up was found. Aortography performed with an end-hole catheter appeared to show severe aortic insufficiency. Left ventricular contractility was normal. The patient was referred to this hospital.

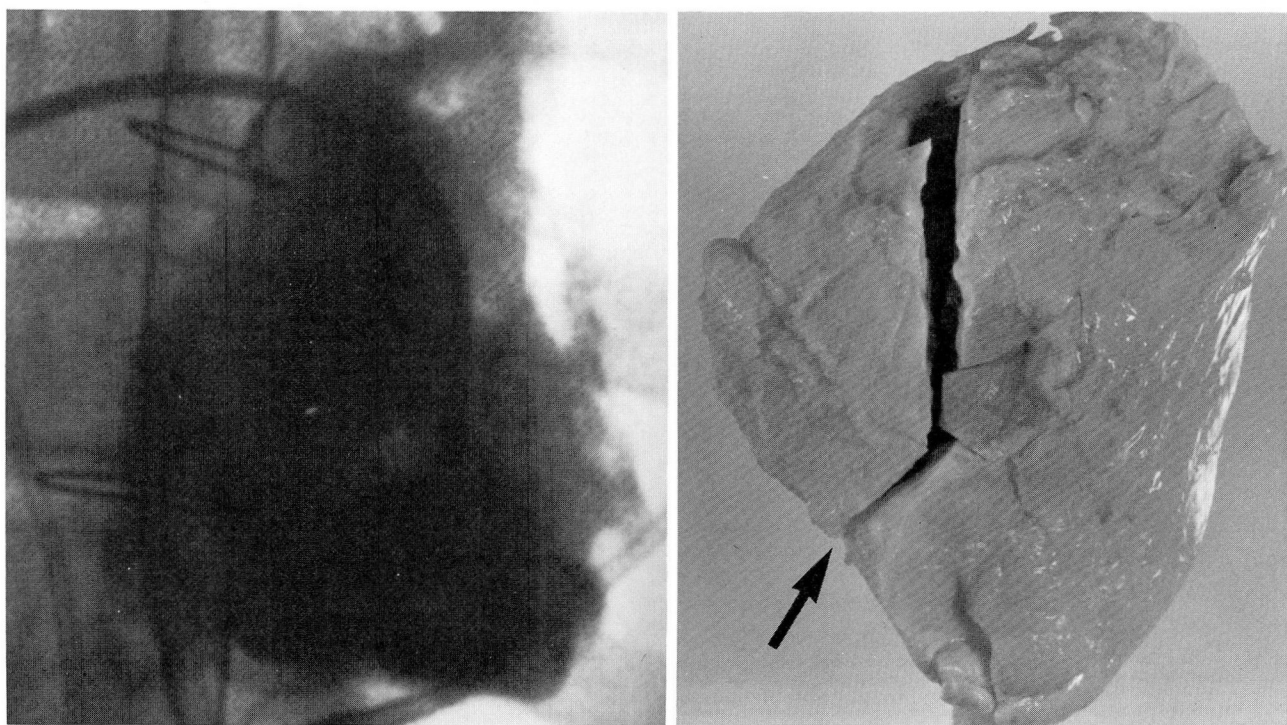
On admission, his temperature was  $36.4^{\circ}\text{C}$ , pulse 116, and blood pressure 110/80 mm Hg. Splinter hemorrhages were noted and the peripheral pulses were brisk. There was no jugular venous distention. The lungs were clear. S1 and S2 sounds were normal. S3 and S4 sounds were heard at the apex. There was a Grade II-III/VI systolic murmur at the right upper sternal border that radiated to the apex and a short Grade III/VI diastolic murmur at the right upper sternal border that radiated to the apex. There was no hepatosplenomegaly or edema.

The urine was normal. The hematocrit was 41.2%; the

white cell count was  $13,300/\mu\text{l}$  with 74% neutrophils, 21% lymphocytes, 3% monocytes, and 2% eosinophils. The platelet count was  $361,000/\mu\text{l}$  and the erythrocyte sedimentation rate was 28 mm per hour. Cultures, serum electrolytes, and a chemistry panel were normal except for an alkaline phosphatase level of 240 U/l. The electrocardiogram showed a normal sinus rhythm, a QRS axis of  $90^{\circ}$ , and evidence of right atrial enlargement. Radiographs of the chest were normal. An echocardiogram demonstrated mild prolapse of the mitral valve and fine fluttering of the posterior mitral valve leaflet. The tricuspid valve appeared displaced downward and the right atrium was enlarged. A gallium scan was negative. Stress ventriculography showed a left ventricular ejection fraction of 41% at rest that increased to 57% with exercise.

High-dose intravenous penicillin was continued and gentamicin was substituted for the streptomycin. Because bacterial endocarditis was suspected, antibiotics were given for six weeks. Two weeks following admission the patient underwent open heart surgery for suspected aortic insufficiency. The aortic valve was explored and found to be normal. The right ventricle appeared large and the right atrium was massively enlarged. The tricuspid valve was stenotic and its posterior leaflet nearly destroyed. Verrucose, caseous yellow debris was adherent to the right ventricular endocardium and protruded through the tricuspid valve and into the infundibulum. Extensive debridement of the right ventricle and infundibulum and commissurotomy and debridement of the tricuspid valve were performed. Microscopic examination of the surgical specimen showed many neutrophils and extension of the inflammatory response into the myocardium. All cultures were negative. The early postoperative course was complicated by sinus tachycardia, recurrence of fever, light-headedness, and a low exercise tolerance. A postoperative echocardiogram and cardiac digital subtraction angiogram showed persistent dilatation of the right atrium, thickening of the right ventricular endocardium, and a mass of echoes in the right ventricular apex (Fig. 1). Urinary levels of 5-hydroxyindoleacetic acid were normal. The patient improved slowly and was discharged one month following surgery.

Five weeks later, a low-grade fever recurred along with swelling of the face and neck. He was admitted for the second time. An echocardiogram showed a small to moderate-sized pericardial effusion and a possible mass involving the tricuspid valve and septum. During surgery 600 ml of purulent-appearing pericardial fluid was removed that was thought to have caused tamponade. Pericardial drainage tubes were left in place. The fluid showed lymphocyte-like forms, but no neutrophils. Cultures were negative. Following surgery he had two episodes of decreased cardiac output and extreme cyanosis of the head and neck. Right-sided heart catheterization on the following day showed obstruction of the superior vena cava, a mean right atrial pressure of 18 mm Hg, right ventricular pressure of 28/16 mm Hg, and pulmonary artery pressure of 24/16 mm Hg with a mean of 18 mm Hg. Mean left atrial pressure was 16 mm Hg. The right atrium was enlarged, the tricuspid valve was insufficient and displaced, the right ventricle was distorted (Fig. 2A), and the left ventricle appeared hyperdynamic. In view of the negative cultures (except those for acid-fast organisms, which were still pending), the patient was treated with isoniazid and rifampin for possible tuberculous disease.



A, B

**Fig. 2.** Case 1. **A.** Right ventricular angiogram, anteroposterior view, following cardiac surgery, demonstrating obliteration of the right ventricular apex and midcavity with an outflow tract remaining. Note the irregular trabeculations of the right ventricle.

**B.** Anatomic specimen, anteroposterior view, demonstrating retraction of the right ventricular apex (arrow). The right ventricle has been opened along the outflow tract.

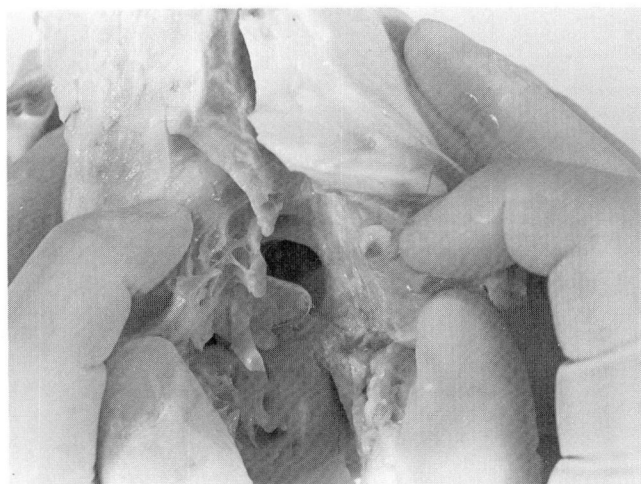
He was discharged three weeks following the pericardiocentesis.

One month later, he was admitted for the third time with symptoms of orthopnea, dyspnea on exertion, and fatigue. He had central cyanosis and pulsus paradox of 20 mm Hg. S3 and S4 sounds were present as well as a pericardial friction rub, a Grade II/VI systolic murmur, and a Grade I/VI diastolic murmur at the right sternal border. Arterial blood gases showed a pH of 7.52,  $p\text{CO}_2$  of 17 mm Hg,  $p\text{O}_2$  of 38 mm Hg,  $\text{HCO}_3^-$  of 14 mEq per liter, and  $\text{O}_2$  saturation of 79%. A lung scan was negative. An echocardiogram showed a mass of echoes in the right ventricle adjacent to the tricuspid valve. The patient again underwent open heart surgery with exploration of the tricuspid valve and right ventricle, which were found to be involved with the same adherent yellow caseous material as before. The right ventricle and outflow tract were debrided and the tricuspid valve was replaced with a #29 Carpentier bioprosthesis. A pericardial patch was used to enlarge the right ventricular outflow tract and a patent foramen ovale was closed. The patient improved slowly and was discharged two weeks postoperatively on a regimen of digoxin, furosemide, coumadin, a small dose of propranolol, and a potassium supplement, but he required readmission two weeks later for treatment of a venous thrombosis involving the left external iliac vein.

Three months later he was admitted for the fifth and final time and had progressive dyspnea, tachypnea, cough,

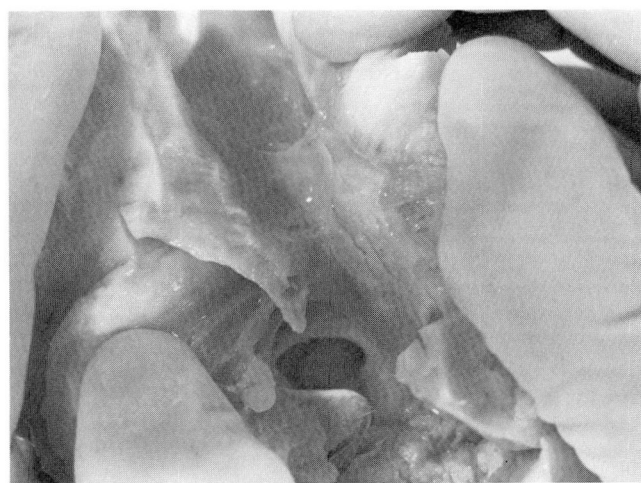fatigue, and edema. He was moderately cyanotic and mildly dyspneic at rest. His temperature was  $35.5^\circ\text{C}$ , pulse 100 and regular, and blood pressure 110/70 mm Hg without paradox. The jugular venous pressure was elevated. The apex was not palpable. Harsh systolic and diastolic sounds that varied with respiration were heard along the left sternal border. The lungs were dull to percussion at the bases and breath sounds were decreased. The liver edge was palpable 10 cm below the right costal margin. The spleen was not palpable. Minimal ascites was present, but no edema. Radiographs of the chest showed mild cardiomegaly and bilateral pleural effusions, and an echocardiogram showed a mass of echoes in the right ventricular inflow tract and adjacent to the right ventricular septum. The patient was anergic on skin testing. There was no evidence of autoimmune or collagen vascular disease. All cultures for aerobic and anaerobic bacteria, fungi, and acid-fast organisms had been repeatedly negative. No rickettsia could be isolated. Acute and chronic serologic tests for *Candida*, other fungi, Q fever, spotted fever, and typhus were negative. After careful review of the clinical, laboratory, and pathologic features of the case a diagnosis of endomyocardial fibrosis was considered. At no time had eosinophilia been noted. Treatment was begun with actinomycin D and vincristine. The patient's condition slowly deteriorated and he died at home in his sleep six weeks later.

Autopsy was restricted to the heart. The heart weighed 520 g but appeared normal in overall size. The apex of the

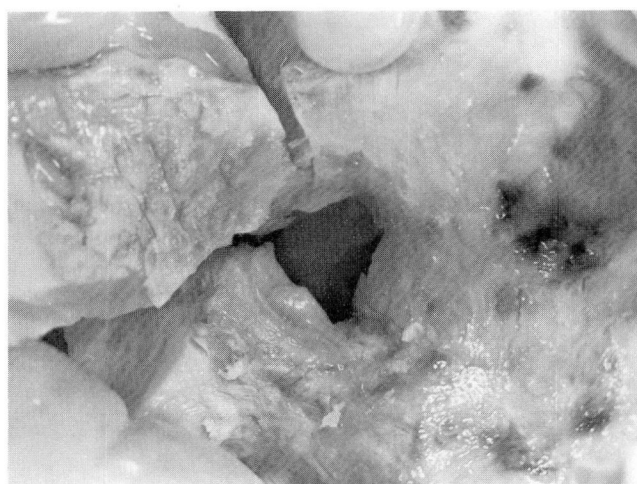

**Fig. 3.** Case 1. Anatomic specimen demonstrating the very small right ventricular cavity. The stent from the tricuspid valve prosthesis can be seen. The view is looking up from the apex toward the tricuspid valve.

right ventricle was retracted, forming a distinct notch at the junction of the right ventricle and interventricular septum (Fig. 2B). The right atrium was dilated and the right ventricle was very small and distorted (Figs. 3 and 4). The endocardial surface of both the right atrium and ventricle was covered by a rough, yellow-white acellular thrombus under which a layer of thick, dense white collagen with no elastic fibers replaced the normal endocardium and extended down into the subendocardial myocardium (Figs. 5 and 6). The inflow of the superior vena cava was constricted and the



**Fig. 4.** Case 1. Anatomic specimen demonstrating the small right ventricular cavity with the stent of the tricuspid prosthesis. The pulmonary valve is well seen and appears normal. The only remaining normal area of the right ventricle is the outflow tract immediately adjacent to the pulmonary valve.



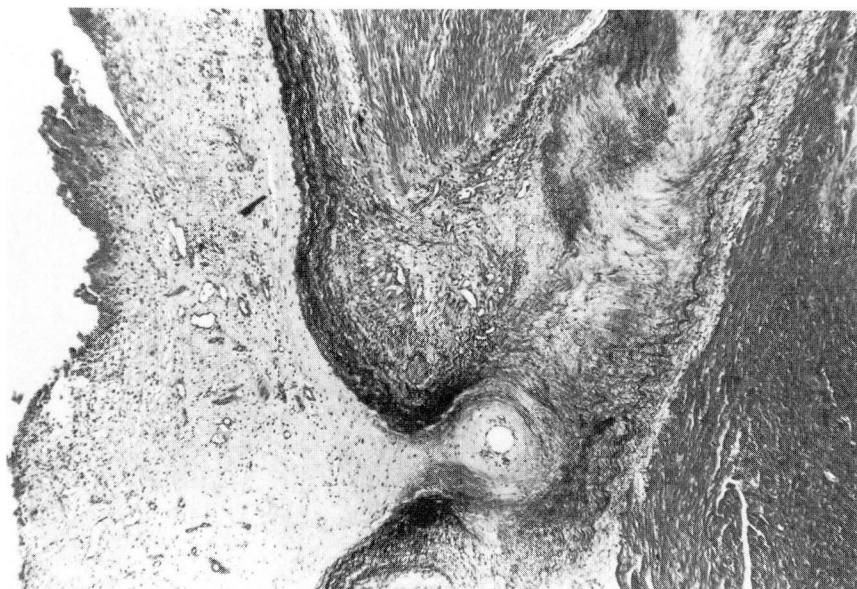**Fig. 5.** Case 1. Anatomic specimen as viewed from the right atrium looking down through the area of the tricuspid valve into the right ventricle. There is marked fibrosis not only in the ventricle but in the distal portion of the right atrium as well.

Carpentier valve in the tricuspid position and the papillary muscles were nearly obliterated by this process. The fibrosis in the right ventricle extended into the outflow tract, but ended below the pulmonary valve (Fig. 4). The left side of the heart was normal except for a slight whitish collagenous thickening of the endocardium of the inflow tract.

**Case 2.** A 53-year-old Ohio woman was admitted to the hospital because of heart failure. There was a history of hypertension treated with diuretics, Bell's palsy, and mild urticaria-angioedema. She was allergic to dairy products. She was 165 cm in height and weighed 79 kg. She attributed a 38-kg weight loss during the preceding year to dieting.

She felt well until three months prior to admission when she noted lightheadedness and fatigue. She was evaluated at another hospital where neurological testing and a 24-hour Holter monitor study disclosed no reason for her symptoms. At that time she was normotensive and had no symptoms or signs of heart failure nor did she complain of chest discomfort. A Grade II/VI systolic murmur was heard at the apex. A left-sided heart catheterization, performed because of questionable ischemic changes on several electrocardiograms, showed marked thickening of the myocardial wall with obliteration of the apex (Fig. 7). A 60-90 mm Hg gradient was measured between the apical region and the middle portion of the ventricular cavity (Fig. 7). Left ventricular contractility was well preserved and there was no mitral insufficiency. The coronary arteries were normal. A diagnosis of hypertrophic cardiomyopathy was made. Diuretics were discontinued and verapamil was begun.

Three weeks prior to admission the patient had marked dyspnea, orthopnea, paroxysmal nocturnal dyspnea, ascites, and edema. Her weight had increased 11 kg. The verapamil was stopped and diuretics were started, and some improvement was noted. Mild leukocytosis and eosinophilia with 950 eosinophils/mm<sup>3</sup> were noted for the first time. Bone marrow aspiration and biopsy showed erythroid hyperplasia,



**Fig. 6.** Case 1. Histologic section of the right ventricle demonstrating a severely fibrotic, thick endocardium. Adherent thrombus can be seen on the edge of the endocardium with organization progressing to dense fibrosis adjacent to the myocardium.

eosinophilia, and decreased iron stores. There was no evidence of parasitic infection, leukemia, polyarteritis, Hodgkin's disease, carcinoma, or asthma to account for the eosinophilia. There was no history of fever or travel outside the United States. The patient was referred to this hospital.

On admission her blood pressure was 110/80 mm Hg and her pulse was 84 and regular. The jugular venous pulse was elevated above the angle of the mandible at 90°. The apex was slightly displaced lateral to the midclavicular line in the fifth intercostal space. S1 and S2 sounds were normal; S3 and S4 sounds were present at the apex. A Grade I-II/VI systolic murmur was heard at the apex. The right base was dull to percussion and breath sounds were diminished. There was evidence of hepatomegaly, ascites, and marked dependent edema.

The urine showed a few red and white cells and a trace of protein. The hematocrit was 41%; the white cell count was 14,100/ $\mu$ l with 46% neutrophils, 24% lymphocytes, 5% monocytes, and 23% eosinophils. The platelet count was 274,000/ $\mu$ l and the erythrocyte sedimentation rate was 23 mm per hour. Cultures, serum electrolytes, and a chemistry panel were normal except for an albumin level of 3.1 g/100 ml, a lactic dehydrogenase (LDH) level of 357 U/l, a urea nitrogen level of 37 mg/100 ml, a creatinine level of 1.6 mg/100 ml, and a uric acid level of 14.5 mg/100 ml. Antinuclear antibodies were present in titer of 1:40, CH50 and C3 were normal, and C1q binding was slightly increased at 51 U/ml.

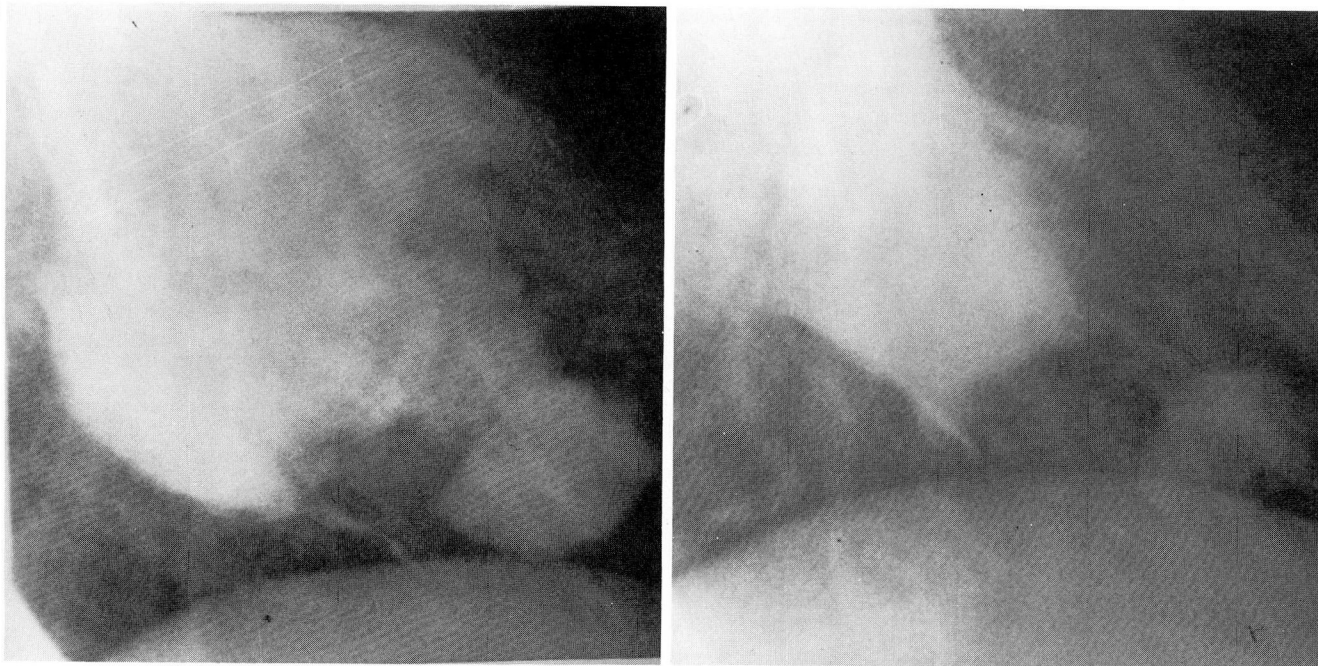
The electrocardiogram showed slight right axis deviation, poor progression of the precordial R wave, and nonspecific ST segment and T wave abnormalities. Radiographs of the chest revealed mild cardiomegaly and a right pleural effusion. An echocardiogram showed paradoxical septal motion and a large mass adjacent to the left ventricular septum (Fig. 8). Right-sided heart catheterization confirmed elevated

right atrial, right ventricular, pulmonary artery, and pulmonary wedge pressures. The right ventricular tracing showed a diastolic "dip and plateau" configuration. The cardiac index was 1.5 l/min/m<sup>2</sup>. An intravenous digital subtraction angiographic study demonstrated dilatation of the right atrium, loss of right ventricular trabeculations, obliteration of the right ventricular apex, and prominence of the right ventricular outflow tract (Fig. 9). Right ventricular biopsies yielded findings compatible with endomyocardial fibrosis. A diagnosis of endomyocardial fibrosis was considered based on the characteristic angiograms, which bore a similarity to those of the first patient.

The patient underwent open heart surgery, at which time the right and left ventricular cavities were found to be nearly obliterated by a yellow caseous and fibrous material that was densely adherent to the endocardial surface, papillary muscles, and chordae tendineae. It was also adherent to the posterior leaflet of the tricuspid valve. The atria were not involved. Extensive debridement of the right and left ventricular endocardium and a De Vega annuloplasty of the tricuspid valve were accomplished. Complete heart block ensued and right atrial and ventricular epicardial pacing wires were placed. Cardiopulmonary bypass was discontinued and inotropic support was given. On the following day the patient had a permanent pacemaker implanted and programmed in the DDD mode. The immediate postoperative course was uneventful and she showed improvement in hemodynamic parameters, including an increase in the cardiac index to 2.77 l/min/m<sup>2</sup> when inotropic drugs were discontinued.

Stains and cultures of the surgical specimen for bacteria, fungi, and acid-fast organisms were negative. Microscopic examination showed thrombus and some inflammatory reaction involving lymphocytes and plasma cells, some macrophages and degranulating basophils, and a few eosinophils

A, B



**Fig. 7.** Case 2. **A.** Left ventricular angiogram, right anterior oblique view, diastolic frame, demonstrating obliteration of the left ventricular apex and the formation of an "ace of hearts" configuration.

**B.** Left ventricular angiogram, right anterior oblique view, systolic frame, demonstrating the almost complete obliteration of the left ventricular apex at systole and the continued presence of the "ace of hearts" configuration.

(Figs. 10–12). Electron microscopy showed atrophy of myocytes immediately adjacent to the involved endocardium. There was no evidence of immune complex deposition. The immunoperoxidase reaction demonstrated polyclonal IgG and C3 in the walls of the blood vessels. A pathologic diagnosis of endomyocardial fibrosis with eosinophilia was made (Figs. 10–12).

The patient was treated with digoxin, diuretics, steroids, and hydroxyurea. The hydroxyurea was stopped after two weeks when urticaria, stomatitis, and difficulty with fine hand movements developed. These symptoms subsequently resolved. At that time her hematocrit was 32.6%; the white cell count was 18,300/ $\mu$ l with 50% neutrophils, 7% lymphocytes, 1% monocytes, 41% eosinophils, and 1% basophils. Some eosinophils appeared hypogranular. During a trial of alternate-day steroids she noted facial edema on days when steroids were not used; therefore she has continued to take prednisone, 30 mg daily. The white-cell count has remained elevated at 17–19,000/ $\mu$ l with predominant neutrophilia and variable eosinophilia. Nucleated red cells and occasional late erythroblasts have been present on peripheral smears.

She has continued to do well as of 18 months postoperatively, without orthopnea, paroxysmal nocturnal dyspnea, dyspnea on exertion, or dependent edema, and is able to walk up to four miles per day. Postoperative echocardiograms and cardiac digital subtraction angiography show sustained improvement of left ventricular configuration and contractility (Fig. 13) with lesser change in the right ventricular configuration (Fig. 14) over the past 18 months.

## Discussion

### *Incidence and prevalence of endomyocardial fibrosis*

Statistics on the incidence and prevalence of endomyocardial fibrosis are difficult to obtain. The occurrence of the disease is highest in Africa. In Uganda, it is responsible for 25% of the deaths due to intrinsic heart disease,<sup>3</sup> second only to rheumatic carditis. In Nigeria it represents 10% of all cardiovascular diseases encountered.<sup>4</sup> The disease does appear to be more frequent in tropical countries.<sup>4</sup> On the Ivory Coast it is common and very severe; 20% of the deaths there due to cardiac failure in children have been reported to be due to endomyocardial fibrosis.<sup>5</sup> There appear to be less than a dozen cases reported in North America and a number of these cases were described in North American blacks who had lived in Africa.<sup>6,7</sup> Thus, our two cases in white North American adults who had not traveled outside the United States and who were seen at one institution over a short period of time appears unique.

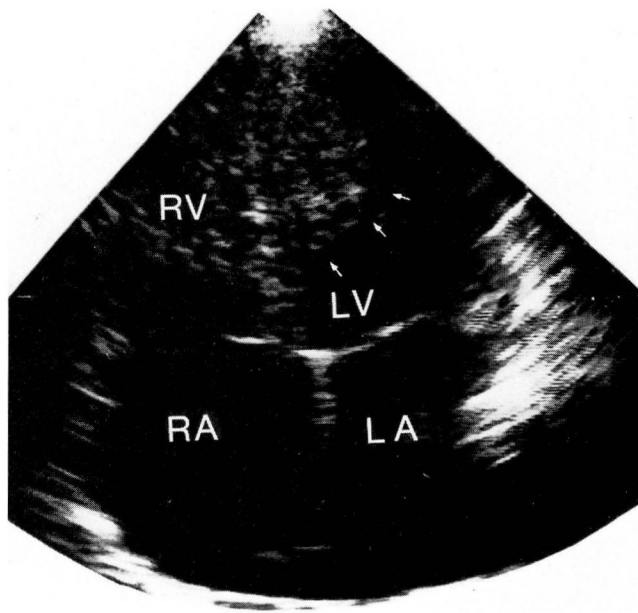
*Relationship of endomyocardial fibrosis to Löffler's endocarditis*

The association of endocardial fibrosis and eosinophilia as observed in Case 2 was described by Löffler<sup>8</sup> in 1936 and has most commonly been referred to as Löffler's endocarditis. Olsen<sup>9</sup> described three stages of Löffler's endocarditis: a "necrotic stage" characterized by inflammatory infiltration of the inner layers of the myocardium, a "thrombotic stage," and a "fibrotic stage." Löffler's endocarditis and endomyocardial fibrosis are indistinguishable in the "fibrotic stage."<sup>10</sup> Roberts et al<sup>11</sup> have suggested that endomyocardial fibrosis may be a late or inactive stage of Löffler's endocarditis.

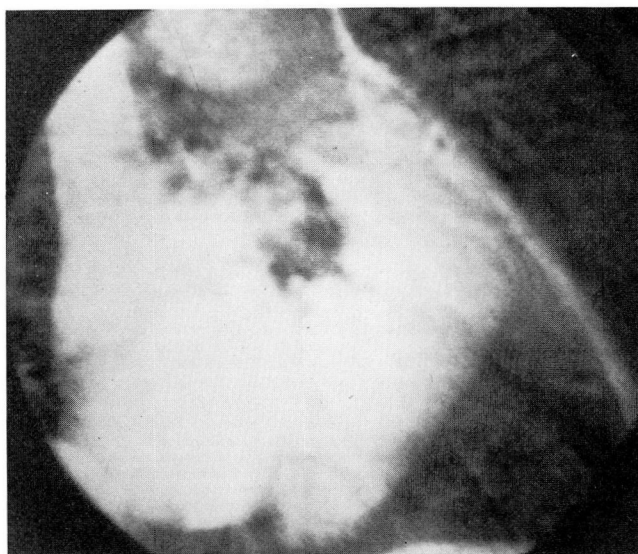
In patients with hypereosinophilic syndrome a number of noncardiovascular factors have been shown to influence the risk of endomyocardial fibrosis. The patient presented in Case 2 had characteristics suggesting both high and low risk of endomyocardial fibrosis. Those factors associated with increased risk of endomyocardial fibrosis include male sex, HLA-Bw44 haplotype, splenomegaly, thrombocytopenia, elevated B12, hypogranular or vacuolated eosinophils, and early myeloid precursors in the peripheral blood. In general, factors associated with a lower risk for endomyocardial fibrosis include female sex, angioedema, hypergammaglobulinemia, elevated immunoglobulin E, and circulating immune factors.<sup>12</sup>

*Pathophysiology*

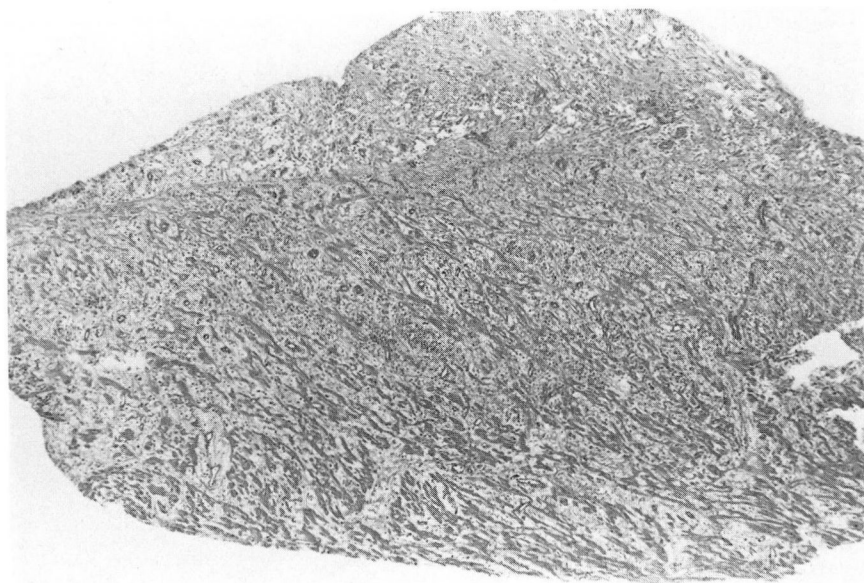
Endomyocardial fibrosis may affect either the right (Case 1) or the left ventricle, or both ventricles (Case 2). Symptoms are caused by endocardial stiffness with resistance to ventricular filling, fibrosis of the papillary muscles producing atrioventricular valve insufficiency, and by obliteration of the ventricular apex and inflow tract causing obstruction and decreased ventricular volume. Involvement of the right ventricle leads to signs of right-sided heart failure (jugular venous distention, hepatomegaly, ascites, and edema) whereas involvement of the left ventricle initially causes left-sided heart failure (dyspnea, orthopnea, and pulmonary edema). Right ventricular endomyocardial fibrosis has been associated with pericardial effusions and tamponade. Rarely the endocardial process obliterates an atrioventricular valve, producing stenosis as in Case 1.<sup>13</sup>



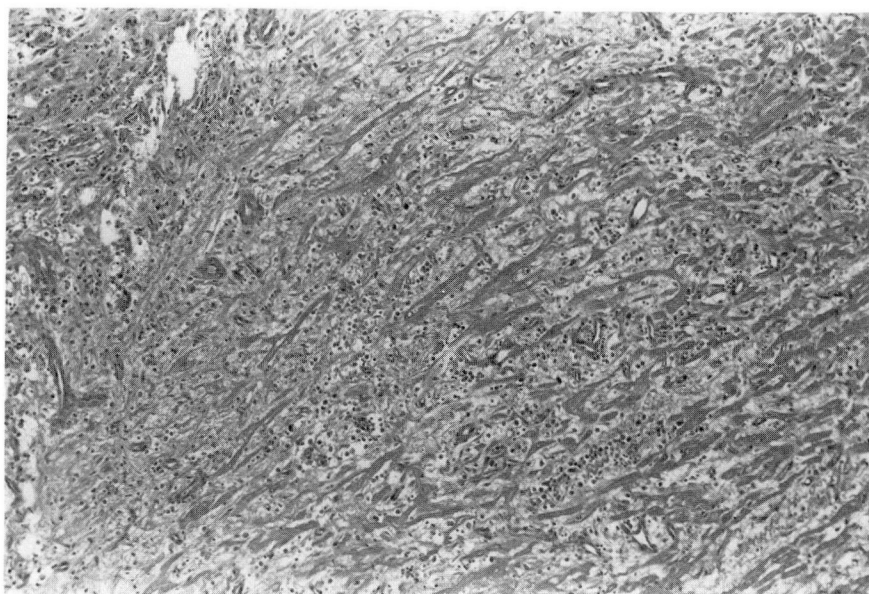
**Fig. 8.** Case 2. Two-dimensional echocardiogram, four-chamber view, demonstrating a mass of echoes outlined by the arrows at the left ventricular apex. RA = right atrium; LA = left atrium; RV = right ventricle; LV = left ventricle.



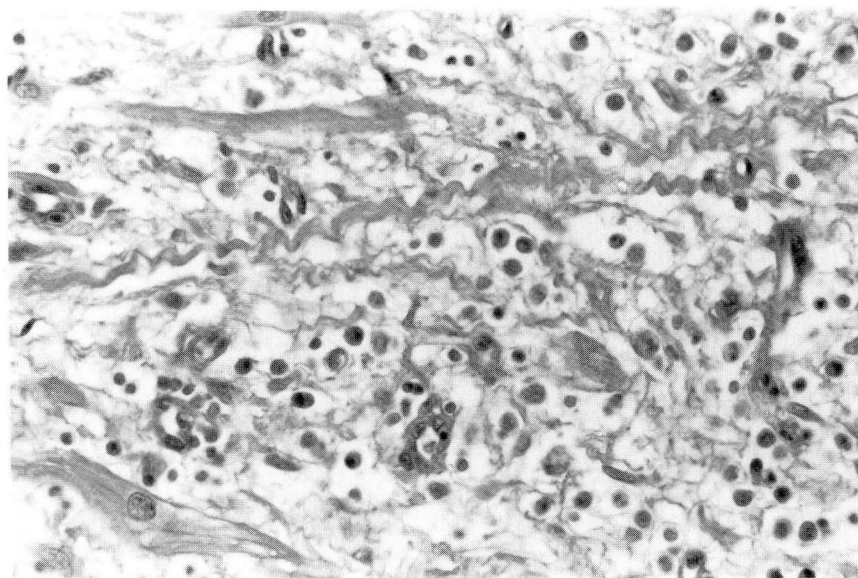
**Fig. 9.** Case 2. Preoperative intravenous digital subtraction angiography demonstrating right atrial enlargement, loss of right ventricular trabeculations, amputation of the right ventricular apex, and a prominent, dilated, and hyperdynamic outflow track producing a tube-like formation.



**Fig. 10.** Case 2. Anatomic specimen, low-power view, demonstrating endomyocardial fibrosis. The endocardial surface is toward the top. The normal endocardium is replaced by an organizing inflammatory reaction that impinges on the myocardium at the bottom.



**Fig. 11.** Case 2. Higher-power view of *Figure 10* showing the inflammatory cells separating degenerating and necrotic myocytes.



**Fig. 12.** Case 2. Histologic section, high-power view, demonstrating some myocyte necrosis. There is collagenation and fibrosis. The inflammatory cells are a mixture of lymphocytes, histiocytes, plasma cells, and eosinophils.

### *Cardiac examination*

The cardiac examination in patients with endomyocardial fibrosis varies according to the ventricle involved. The apical pulse is usually quiet. An increased P2 and a right ventricular lift are found when left ventricular endomyocardial fibrosis causes pulmonary hypertension. Systolic murmurs are caused by atrioventricular valve insufficiency and are often accompanied by diastolic flow murmurs. An S3 sound is a nearly constant finding in either right- or left-sided endomyocardial fibrosis.

### *Electrocardiography and radiography*

Electrocardiograms are almost always abnormal but nonspecific. Atrial fibrillation and low voltages are occasionally noted. Chest radiographs are likewise nonspecific, but frequently show moderate cardiomegaly. In right ventricular endomyocardial fibrosis a prominent right atrium is often seen.

### *Echocardiography*

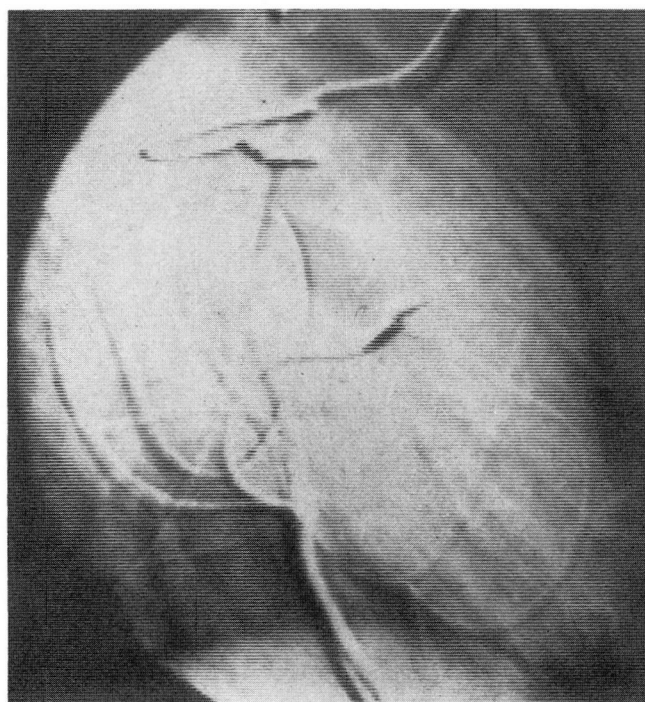
Echocardiography may be useful if high-quality images can be obtained. The echocardiograms were abnormal in both of our cases. Abnormalities found in right ventricular endomyocardial fibrosis include paradoxical septal motion, the

appearance of downward displacement of the tricuspid valve, enlargement of the right atrium, and most commonly echogenic material in the right ventricular apex and inflow tract (*Fig. 1*). Intense specular echoes, possibly caused by calcium, are occasionally noted on the surface of the thrombotic-fibrotic endocardium.<sup>14,15</sup> In left ventricular endomyocardial fibrosis echogenic material is found within the left ventricular apex and inflow tract (*Fig. 8*). Fine flutter of the atrioventricular valves has been attributed to distortion of the inflow tract or valve apparatus.<sup>14</sup>

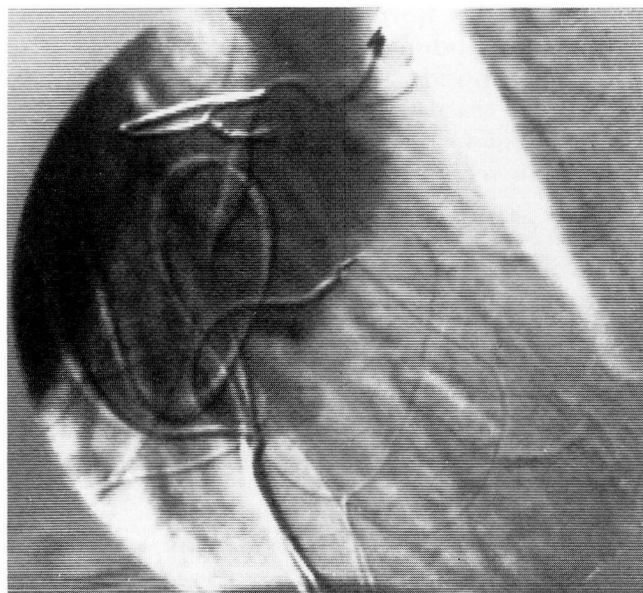
### *Cardiac catheterization*

Cardiac catheterization is a useful diagnostic procedure in endomyocardial fibrosis. In right ventricular endomyocardial fibrosis hemodynamic tracings often show a restrictive pattern with elevated right atrial and ventricular pressures and a diastolic "dip and plateau" configuration due to impedance of ventricular filling. In severe cases with functional destruction of the tricuspid valve, the right atrial and ventricular tracings may be identical.<sup>16</sup> In left ventricular endomyocardial fibrosis there is elevation of the left ventricular end-diastolic pressure and eventually the pulmonary wedge and pulmonary artery pressure.

Angiography in right ventricular endomyocar-



**Fig. 13.** Case 2. Postoperative intravenous digital subtraction angiography of the left ventricle, right anterior oblique view, diastolic frame, demonstrating a much more normal configuration of the left ventricle than the preoperative study.



**Fig. 14.** Case 2. Postoperative intravenous digital subtraction angiography, right anterior oblique view, demonstrating the continued unusual tube-like appearance of the right ventricle.

dial fibrosis is usually characteristic and shows right atrial enlargement, tricuspid insufficiency, loss of right ventricular trabeculations, amputation of the right ventricular apex, and a prominent, dilated, hyperdynamic outflow tract producing a tube-like formation that conducts dye from the right atrium to the pulmonary artery (Figs. 2A and 9). In left ventricular endomyocardial fibrosis angiography shows obliteration of the left ventricular apex, sometimes with an "ace of hearts" configuration<sup>17</sup> (Fig. 7).

#### *Endomyocardial biopsy*

Endomyocardial biopsy has been reported to be useful in the diagnosis of endomyocardial fibrosis. In our experience, endomyocardial biopsy coupled with careful clinical pathologic correlation was diagnostic.<sup>18</sup>

#### *Differential diagnosis*

The differential diagnosis of endomyocardial fibrosis includes constrictive pericarditis, which may mimic right-sided endomyocardial fibrosis; isolated valvular lesions, most often mitral or tricuspid insufficiency; mural or valvular vegetations, thrombi, or tumor; and Ebstein's disease due to downward retraction of the tricuspid valve by the fibrotic process. Aortic insufficiency was suspected preoperatively in Case 1 because of an artifactually abnormal aortogram, which probably occurred because an end-hole catheter was used and positioned immediately above the aortic valve.

#### *Medical therapy*

Conventional treatment for endomyocardial fibrosis includes diuretics and digoxin. Coumadin is sometimes used because of the mural thrombus and the possibility of pulmonary or systemic emboli. Endocarditis has been reported with endomyocardial fibrosis, so prophylaxis for bacterial endocarditis should be considered. Corticosteroids, hydroxyurea, cyclophosphamide, and vincristine have been used with variable and limited response. Parrillo et al<sup>19</sup> described a marked increase in survival in patients with hypereosinophilic syndrome and evidence of cardiac involvement when they were treated with corticosteroids and hydroxyurea. The same benefit has not been reported in endomyocardial fibrosis without eosinophilia.

### *Surgical therapy*

Because of the generally poor prognosis of medically treated endomyocardial fibrosis, Dubost et al<sup>20</sup> performed the first endocardial debridement in 1971. The surgery, sometimes described as an endocardectomy, is performed through a median sternotomy during complete cardiopulmonary bypass. A cleavage plane is located between the fibrotic ventricular endocardium and the underlying myocardium, and fibrous connecting bands are sharply dissected. The decortication is sometimes performed entirely through an atriotomy; however, on occasion a ventriculotomy is also required. Frequently the ipsilateral atrioventricular valve must be replaced to correct atrioventricular valve insufficiency.

Since 1971 the results of several surgical series have been reported.<sup>20-28</sup> The early surgical mortality has been 13.5% to 20%.<sup>24-26</sup> Inotropic support in the immediate postoperative period appears important to lessen the severity of the low cardiac output syndrome that is an early cause of mortality. Complete heart block has been described as a complication of right-sided endocardectomy and it developed intraoperatively in the patient described in Case 2. Metras et al<sup>5</sup> have attributed the avoidance of complete heart block in 12 right-sided endocardectomies to preservation of a thin juxta-annular rim of fibrosis in the right ventricle. In the patient described in Case 2, epicardial pacing leads were placed to avoid the potential problems of transvenous pacing in the presence of a diseased and partly resected endocardium.

The published results of surgical series suggest favorable survival in endomyocardial fibrosis compared with survival following medical therapy, with follow-up in some cases for at least seven years.<sup>23</sup> Postoperative functional class has most often been considerably improved, as in the patient described in Case 2.

The patient described in Case 1 had right ventricular endomyocardial fibrosis. He died of relentless, recurrent progression of the endocardial process in spite of very aggressive therapy, including two endocardectomies and replacement of the tricuspid valve. Documented reports of death secondary to postoperative recurrence of endomyocardial fibrosis are almost unknown. The absence of postoperative recurrence has

been partly responsible for making surgery a viable treatment alternative. The right-sided cardiac involvement in the patient described in Case 1 was unusually extensive, with involvement across the tricuspid valve into the right atrium and into the right ventricular outflow tract already present at the first endocardectomy. In addition, the disease was in a very active inflammatory stage at that time and progressed to the fibrotic stage by the time of autopsy one year following onset of the illness.

It is possible that recurrence in this case was related to the acute stage of the illness, with continued activity of the inciting factor at the time of the endocardectomies. It is interesting to speculate that the timing of the surgery may be important to prevent recurrence. Endomyocardial biopsies might be useful not only to diagnose the disease but to stage its activity. This may be an important consideration in other countries where the disease is more common and earlier operation has been proposed for right ventricular endomyocardial fibrosis<sup>19</sup> to decrease surgical mortality and to prevent severe right atrial enlargement and chronic hepatic disease.

Douglas S. Moodie, M.D.  
Department of Cardiology  
The Cleveland Clinic Foundation  
9500 Euclid Avenue  
Cleveland, OH 44106

### References

1. Davies JNP. Endocardial fibrosis in Uganda. *East Afr Med J* 1948; **25**:228-235.
2. D'Arbela PG, Mutazindwa T, Patel AK, Somers K. Survival after first presentation with endomyocardial fibrosis. *Br Heart J* 1972; **34**:403-407.
3. Connor DH, Somers K, Hutt MSR, Manion WC, D'Arbela PG. Endomyocardial fibrosis in Uganda (Davies' disease). Part 1. *Am Heart J* 1967; **74**:687-709.
4. Andrade ZA, Guimarães AC. Endomyocardial fibrosis in Bahia, Brazil. *Br Heart J* 1964; **26**:813-820.
5. Metras D, Coulibaly AO, Ouattara K, et al. Endomyocardial fibrosis. *J Thorac Cardiovasc Surg* 1982; **83**:52-64.
6. Bishop MB, Bousvaros G, Cunningham TJ, Jain AC, Davies JNP. Endomyocardial fibrosis in a North American Negro. *Lancet* 1968; **2**:750-751.
7. McKusick VA, Cochran TH. Constrictive endocarditis. *Bull Johns Hopkins Hosp* 1952; **90**:90-97.

8. Löffler W. Endocarditis parietalis fibroplastica mit Bluteosinophilie. *Schweiz med Wchnschr* 1936; **66**:817-820.
9. Olsen EGJ. Endomyocardial fibrosis and Löffler's endocarditis parietalis fibroplastica. *Postgrad Med J* 1977; **53**:538-540.
10. Brockington IF, Olsen EGJ. Löffler's endocarditis and Davies' endomyocardial fibrosis. *Am Heart J* 1973; **85**:308-322.
11. Roberts WC, Liegler DG, Carbone PP. Endomyocardial disease and eosinophilia. *Am J Med* 1969; **46**:28-42.
12. Harley JB, Fauci AS, Gralnick HR. Noncardiovascular findings associated with heart disease in the idiopathic hypereosinophilic syndrome. *Am J Cardiol* 1983; **52**:321-324.
13. Weyman AE, Rankin R, King H. Loeffler's endocarditis presenting as mitral and tricuspid stenosis. *Am J Cardiol* 1977; **40**:438-444.
14. George BO, Gaba FE, Talabi AI. M-mode echocardiographic features of endomyocardial fibrosis. *Br Heart J* 1982; **48**:222-228.
15. Acquatella H, Schiller NB, Puigbó JJ, Gómez-Mancebo JR, Suarez C, Acquatella G. Value of two-dimensional echocardiography in endomyocardial disease with and without eosinophilia. *Circulation* 1983; **67**:1219-1226.
16. Brockington IF, Ikeme AC, Bohrer SP. Contributions to the diagnosis of endomyocardial fibrosis. *Acta Cardiol (Brux)* 1973; **28**:255-272.
17. Dubost C. Surgery for constrictive fibrous endocarditis. *Compr Ther* 1979; **5**:28-32.
18. Bell JA, Jenkins BS, Webb-Peploe MM. Clinical, haemodynamic, and angiographic findings in Löffler's eosinophilic endocarditis. *Br Heart J* 1976; **38**:541-548.
19. Parrillo JE, Fauci AS, Wolff SM. Therapy of the hypereosinophilic syndrome. *Ann Intern Med* 1978; **89**:167-172.
20. Dubost C, Maurice P, Gerbaux A, et al. The surgical treatment of constrictive fibrous endocarditis. *Ann Surg* 1976; **184**:303-307.
21. Hess OM, Turina M, Senning Å, Goebel NH, Scholer Y, Krayenbuehl HP. Pre- and postoperative findings in patients with endomyocardial fibrosis. *Br Heart J* 1978; **40**:406-415.
22. Moraes CR, Buffolo E, Victor E, et al. Endomyocardial fibrosis: report of 6 patients and review of the surgical literature. *Ann Thorac Surg* 1980; **29**:243-248.
23. Davies J, Sapsford R, Brooksby I, et al. Successful surgical treatment of two patients with eosinophilic endomyocardial disease. *Br Heart J* 1981; **46**:438-445.
24. Moraes CR, Buffolo E, Lima R, et al. Surgical treatment of endomyocardial fibrosis. *J Thorac Cardiovasc Surg* 1983; **85**:738-745.
25. Cherian G, Vijayaraghavan G, Krishnaswami S, et al. Endomyocardial fibrosis: report on the hemodynamic data in 29 patients and review of the results of surgery. *Am Heart J* 1983; **105**:659-665.
26. Gonzalez-Lavin L, Friedman JP, Hecker SP, McFadden PM. Endomyocardial fibrosis: diagnosis and treatment. *Am Heart J* 1983; **105**:699-704.
27. Lepley D, Aris A, Korn ME, Walker JA, D'Cunha RM. Endomyocardial fibrosis: a surgical approach. *Ann Thor Surg* 1974; **18**:626-633.
28. Eterovic I, Angelini P, Leachman R, Cooley DA. Obliterative endomyocardial fibrosis and surgical approach. *Bull Texas Heart Inst* 1979; **6**:66-75.