

Endogenous *Pseudoallescheria boydii* endophthalmitis

A clinicopathologic report¹

Robert M. Stern, M.D.
Z. Nicholas Zakov, M.D.
David M. Meisler, M.D.
Geraldine S. Hall, Ph.D.
Amy Martin, M.D.

The authors describe the clinicopathologic findings in a case of endogenous *Pseudoallescheria boydii* endophthalmitis that developed in a 31-year-old man following aortic valve replacement and aortic prosthetic graft insertion. The patient died from disseminated *P boydii* infection. The fungus was resistant to amphotericin B in vitro. Postmortem histologic and microbiologic studies suggested that the combination of pars plana vitrectomy and intravitreal instillation of miconazole (40 µg) had eradicated the organism from the vitreous cavity. In other instances of fungal endophthalmitis where isolates are resistant to amphotericin B, intravitreal miconazole and vitrectomy may be useful.

Index terms: Case reports • Ophthalmia
Cleve Clin Q 53:197–203, Summer 1986

Endogenous fungal endophthalmitis is a clinical entity whose incidence has markedly increased in recent years.^{1,2} Factors commonly associated with this hematogenously spread infection include hemodialysis; parenteral hyperali-

mentation; intravenous drug abuse; immunosuppression; indwelling catheters; extensive, broad-spectrum antibiotic therapy; abdominal surgery; and prosthetic heart valves. The most frequent fungal organism isolated is *Candida albicans*. Other *Candida* sp, *Aspergillus* sp, *Coccidioides* sp, *Cryptococcus* sp, and *Blastomyces* sp are less commonly responsible agents.^{2,3}

Pseudoallescheria boydii (formerly known as *Petriellidium boydii*) and its asexual form, *Monosporium apiospermum*, are found ubiquitously in the environment. They are the most frequent cause of maduromycosis in this country; however, ocular infections are rare.⁴ To our knowledge, there only are two reports of endogenous *P boydii* endophthalmitis in the literature.^{5,6} This clinicopathologic study describes a case of endogenous *P boydii* endophthalmitis treated with vitrectomy and intravitreal miconazole.

Case report

A 31-year-old white man with a history of congenital aortic stenosis was referred to The Cleveland Clinic Foundation on September 17, 1984, for evaluation of worsening congestive heart failure. An aortic valvuloplasty had been performed when he was 12 years old. Over the prior seven months, he had noted orthopnea, paroxysmal nocturnal dyspnea, and progressive dyspnea on exertion.

Cardiac catheterization and echocardiography revealed combined aortic stenosis and aortic insufficiency. There was an 8-cm aneurysm in the ascending aorta. On September 21, the patient underwent a thoracotomy for aortic valve

¹ Departments of Ophthalmology (R.M.S., Z.N.Z., D.M.M.), Microbiology (G.S.H.), and Pathology (A.M.), The Cleveland Clinic Foundation. Submitted for publication Sept 1985; accepted Feb 1986.

0009-8787/86/02/0197/07/\$2.75/0

Copyright © 1986, The Cleveland Clinic Foundation

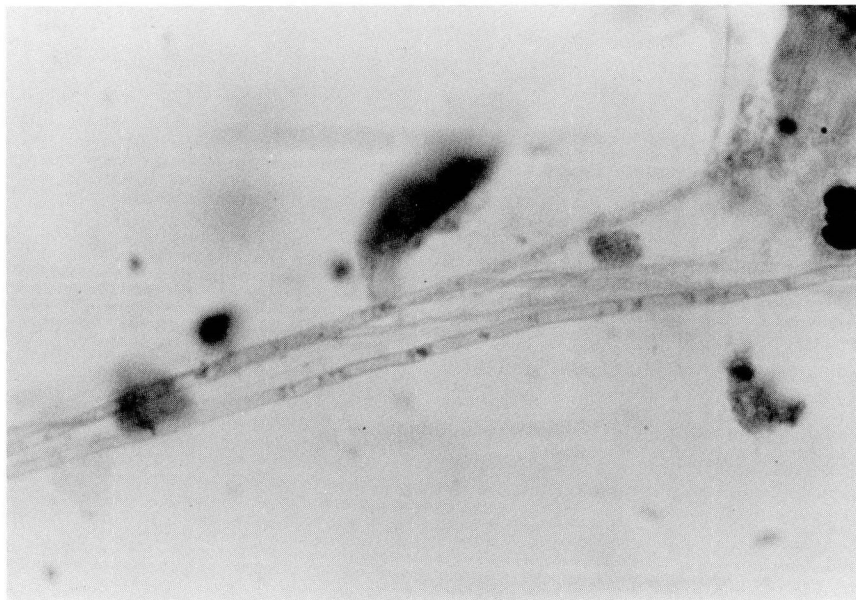

Fig. 1. Septate hyphae in vitreous smear (Gomori methenamine silver, $\times 1,000$).

replacement with a porcine bioprosthetic valve and placement of a prosthetic graft in the ascending aorta. Persistent postoperative bleeding required reexploration and repair of a leak at the distal aortic graft-aorta anastomotic site. A total of 31 U of various blood products was transfused. The patient's postoperative course was complicated by bilateral diaphragmatic paralysis necessitating intermittent ventilator support and a tracheostomy.

Following a prolonged convalescence, the patient was discharged on intermittent home ventilatory support on November 3. During that evening, the patient's wife noticed that the color of his right eye had changed from blue to green. He denied visual symptoms initially, but awoke the next morning with blurred vision in his right eye and a fever of 103° F. On November 5, a private ophthalmologist made a tentative diagnosis of "herpetic endophthalmitis." Topical prednisolone acetate 1% and cyclopentolate hydrochloride 2% therapy was initiated.

By November 7, the vision in his right eye had further deteriorated. On ophthalmic evaluation, his visual acuity was: R.E., hand motion at four feet, and L.E., 20/15. The right pupil was irregular in shape but reactive to light. There was no relative afferent pupillary defect. Heterochromia was evident. The right eye had moderate bulbar conjunctival hyperemia. Slit lamp examination of the right eye revealed diffuse fine white keratic precipitates. The anterior

chamber was deep with 4+ cells, 1+ flare, and a small (10%) hypopyon. Fibrin strands were evident at the pupillary border. The lens was clear and there was 1+ cells in the vitreous. Slit lamp examination of the left eye was normal. Applanation tonometry revealed the following intraocular pressures: R.E., 9 mm Hg, and L.E., 18 mm Hg. Funduscopy examination of the right eye revealed an intraretinal fluffy white exudative lesion in the temporal macular region. A serous retinal detachment extended inferotemporally from the lesion. There was diffuse arteriolar narrowing. Examination of the left eye was unremarkable. A diagnosis of acute retinal necrosis was proposed. Other causative pathogens considered included cytomegalovirus, herpes simplex, *Candida* sp, or *Toxoplasmosis* sp. Systemic acyclovir therapy was initiated empirically. Topical steroids and cycloplegics were continued.

Systemic laboratory studies on admission were remarkable for an elevated white blood count of 10,100 with 77% polys, 3% bands, 14% lymphs, 4% monos, and 2% eosinophils.

Over the next 10 days, the vision in his right eye deteriorated to vague hand motions in the temporal field only. The hypopyon remained unchanged, but a dense vitritis developed which limited fundus examination to a small peripheral nasal region. His fever persisted despite the systemic acyclovir, and intravenous therapy was changed to nafcillin and tobramycin. Blood cultures and viral studies remained negative. An echocardiogram revealed no evidence of valvular vegetations.

On November 17, a lensectomy-vitreectomy was performed. An intraoperative vitreous smear revealed septate hyphae (Fig. 1), and cultures initially grew a mold. The instillation of intravitreal antibiotics was deferred until a precise organism could be identified. *P boydii* was isolated and minimum inhibitory concentrations were determined with use of a macrotube broth dilution. Results of the sensitivity testing are shown (Table). On November 21,

Table. Sensitivity results of *P boydii* isolate

Drug	Minimal inhibitory concentration ($\mu\text{g/mL}$)
Amphotericin B	>128
5-fluorocytosine	>128
Ketoconazole	>64
Miconazole	2

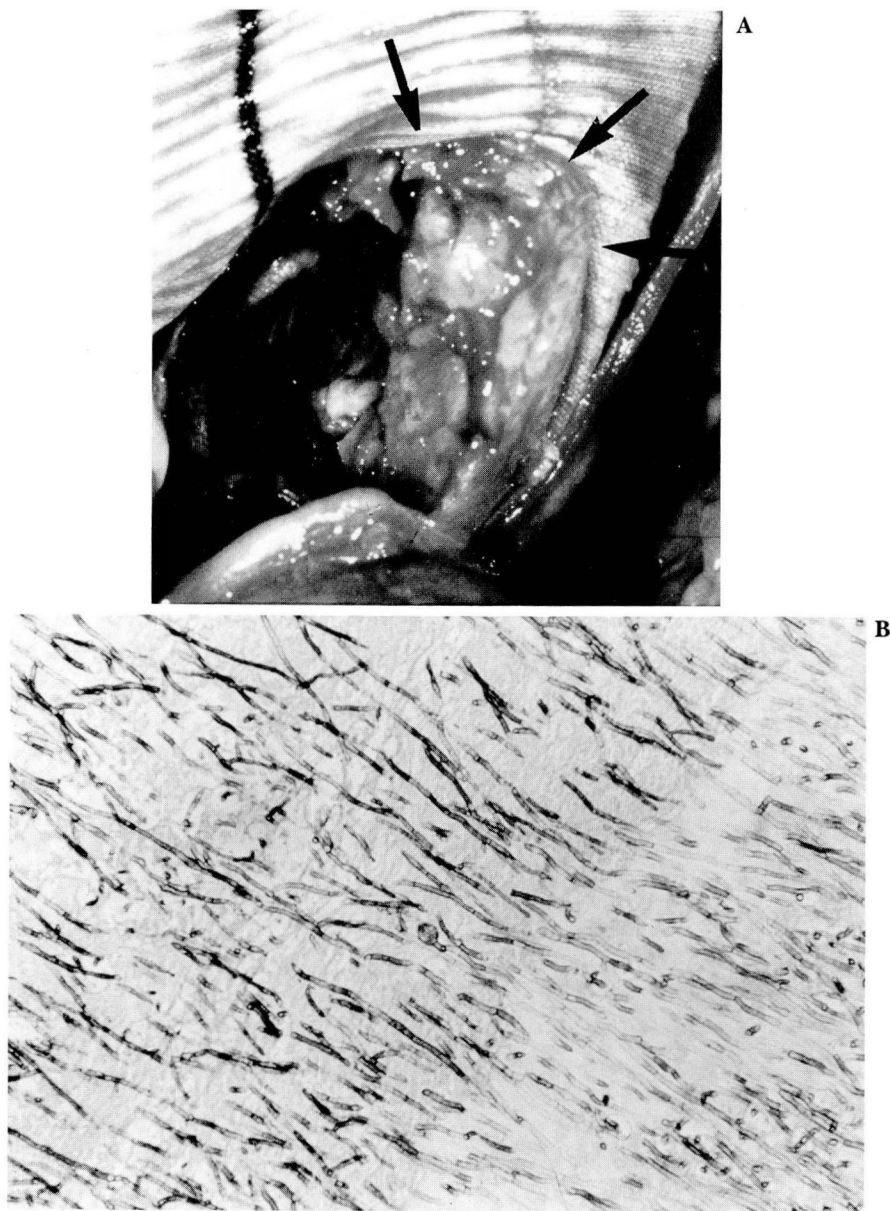


Fig. 2. A. Fungal vegetations (arrows) at junction of the aortic conduit graft and prosthetic aortic valve.

B. Light microscopy of fungal vegetation, revealing multiple septate hyphae (Gomori methenamine silver, $\times 100$).

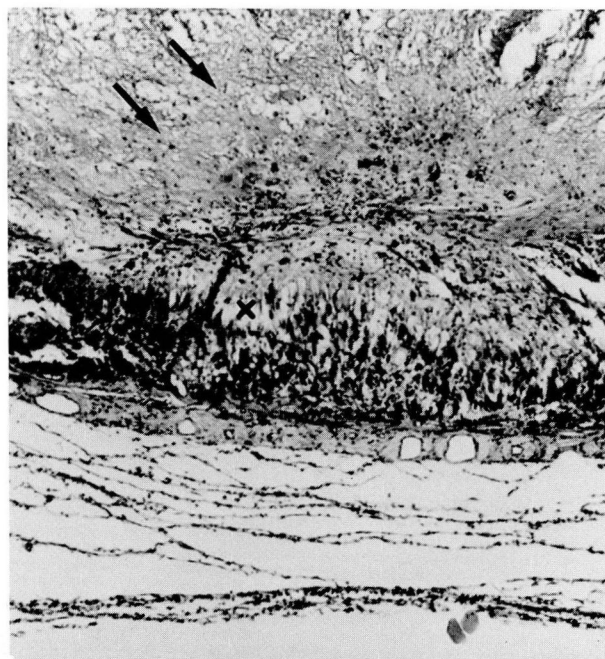
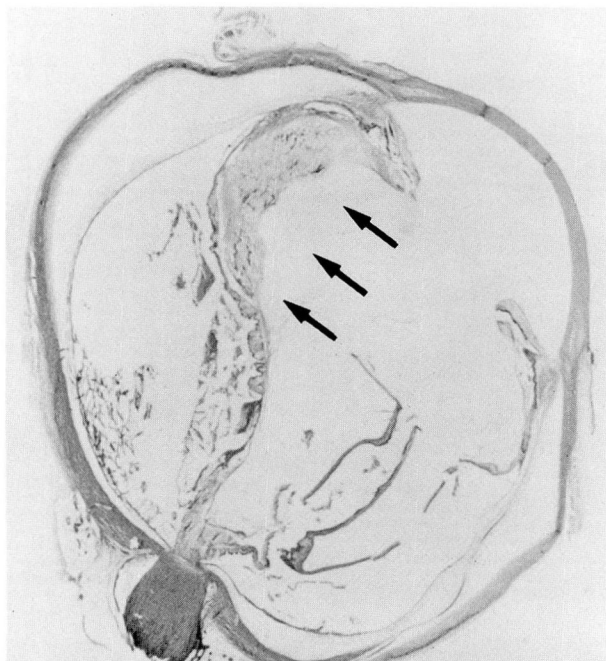miconazole (40 μg) was instilled intravitreally. Intravenous miconazole therapy was also initiated. The first dose of 800 mg was slowly infused over one hour and completed by 7 PM. At 10 PM, the patient was found in bed unresponsive and pulseless. Resuscitation efforts resulted in restoration of pulse and blood pressure after approximately 15 minutes. Due to concern that the systemic miconazole possibly could have precipitated an arrhythmia, a reported side effect of rapid intravenous infusion,⁷ it was discontinued.

The patient never recovered neurologic function, remaining comatose and unresponsive. A blood culture drawn on November 8 subsequently turned positive in one of two bottles for *P boydii* on November 28, confirming a fungemia. The patient died on November 29.

Histopathologic findings

Autopsy revealed fungal vegetations at the

A, B



C

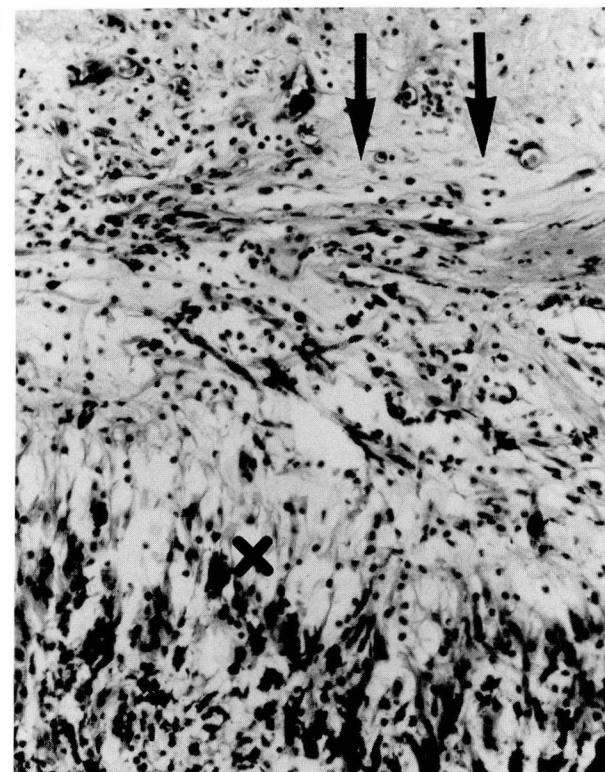

Fig. 3. A. Right-globe postlensectomy-vitrectomy, displaying area of focal retinitis with dense vitreous adhesion (arrows) (hematoxylin-eosin).

B. Degenerative changes in the retina (X) with adherent vitreal fibrovascular proliferation (arrows) (hematoxylin-eosin, $\times 10$).

C. Higher-power magnification shows mononuclear and polymorphonuclear cellular infiltration in the retina (X). A similar cellular reaction with fibrovascular proliferation (arrows) involved the vitreous (hematoxylin-eosin, $\times 20$).

junction of the prosthetic aortic valve and aortic conduit graft, the distal aortic conduit graft, and the aneurysmal sac itself (*Fig. 2*). Gross and microscopic inspection of the porcine valve leaflets

failed to reveal fungal invasion. The basal ganglia of the brain contained a single fungal microabscess. There was no histologic confirmation of fungus in the lungs, liver, or spleen, but post-

mortem culture of these organs resulted in heavy growth of *P boydii*.

Grossly, the right eye was intact, measuring 23.0 mm (horizontal) × 23.0 mm (vertical) × 24.0 mm (anteroposterior). The cornea was clear and measured 12.0 mm (horizontal) × 11.0 mm (vertical). The iris was green. A 3-mm section of optic nerve remained attached to the globe. A diffuse white exudate covered the entire retina, including the ora serrata, producing a transillumination defect. This exudate was thickest temporally with fine projections extending into the vitreal cavity.

Microscopically, the right eye displayed a normal cornea. The trabecular meshwork, ciliary body, iris, and choroid were diffusely infiltrated with a mild mononuclear cellular reaction. The lens remnants contained a few mononuclear cells. The temporal peripheral retina displayed an area of focal retinitis with mononuclear and polymorphonuclear cellular infiltration. Vitreous remnants were densely adherent in this region with evidence of preretinal fibrovascular proliferation (Fig. 3). In addition, the vitreous cavity contained residual vitreous containing necrotic debris, large numbers of polymorphonuclear and mononuclear cells, and a small amount of hemorrhage. The remainder of the retina showed mononuclear cell infiltration and focal hemorrhages in the inner retinal layers with maximal involvement temporally. Fungal hyphae were absent in all sections studied. A postmortem vitreal aspirate culture failed to grow *P boydii*. Ocular pathology of the left eye was unremarkable. Fungal involvement was not evident.

Discussion

Pseudoallescheria boydii is classified among the Ascomycetes fungi—those with septate hyphae having known sexual reproduction. It grows rapidly on most fungal media, characterized by a fluffy white colony that turns gray with age. The distinguishing microscopic feature of *P boydii* is the manner in which the conidia, or asexual spores, are attached to the hyphae. These are usually isolated either singly or in small groups at the tips and sides of single conidiophores. Sexual reproduction is a homothallic process in which ascospores (sexual spores) are derived from the fusion of cells from the same hyphae.⁴

Clinically, the traumatic implantation of *P boydii* into soft tissues causes mycetoma formation. This local pyogenic abscess commonly occurs in

the lower extremities, causing Madura's foot, but may involve the trunk, neck, or scalp. The stages of this infectious process include granule formation, soft tissue invasion, and drainage of pus and granules through multiple sinus tracts. If clinically suspected, the diagnosis of mycetoma can be made by performing a search for granules in the pus or exudate. Examination of the granules for size, morphology, texture, and color will indicate either a bacterial or fungal origin. Confirmation by culture techniques should not delay therapy. Treatment consists of multiple surgical debridements.⁸

P boydii is an infrequent opportunistic pathogen. Descriptions of visceral involvement include pulmonary,⁹ prostatic,¹⁰ otitic,¹¹ and meningeal lesions.¹² Surgery and other invasive therapeutic modalities can introduce or disseminate the organism.⁴ Roberts et al¹³ reported a case of *P boydii* endocarditis associated with a porcine mitral valve replacement.

Ocular infections associated with *P boydii* are uncommon. Corneal involvement with isolation of the organism has been reported.¹⁴⁻²³ There have been three previous descriptions of *P boydii* endophthalmitis in the literature. Glassman et al²⁴ reported the infection in a diabetic patient following cataract extraction. This endophthalmitis was anterior in location and responded successfully to topical amphotericin B. Lutwick et al⁵ detailed the first endogenous case involving a lupus erythematosus patient with a suspected primary pulmonary lesion. A partial vitrectomy with instillation of amphotericin B and intravenous miconazole therapy was not successful. The eye was eviscerated. From the vitreal specimen, the organism was cultured and histologically identified despite intravitreal miconazole levels greater than the minimal inhibitory concentration of the *P boydii* isolate. Meadow et al⁶ described a case of endogenous *P boydii* endophthalmitis following antibiotic and corticosteroid therapy for a severe pneumonia secondary to the aspiration of muddy water. Vitrectomy and intravenous miconazole therapy was instituted. The patient succumbed to a persistent widespread visceral *P boydii* infection revealed at postmortem examination. The histopathologic status of the eye was not disclosed.

Our patient was presumably placed at risk for visceral *P boydii* infection by the systemic stress of multiple surgical interventions necessitated by his cardiovascular status. Although clinical ocular

involvement was evident, systemic examination and laboratory studies failed to reveal a source for hematogenous mycotic dissemination. The portal of entry of the organism remains unknown. Intraoperative introduction, perhaps with a contaminated porcine valve and/or graft, is a possibility. One of us (G.S.H.) has demonstrated that *P boydii* growth was not inhibited by the valve and graft disinfecting solution (0.35% glutaraldehyde) used preoperatively.

The postmortem examination demonstrated a systemic *P boydii* infection. The tracheostomy site was histologically free of fungal involvement and was therefore an unlikely site of invasion. The large fungal vegetations in the region of the valve-graft anastomosis site raises the possibility of a valvular origin. The existence of an aneurysmal hematoma at the anastomosis of the valve and graft could have provided an excellent culture medium.

The management of endophthalmitis involving virulent species includes pars plana vitrectomy and intravitreal instillation of antibiotics. Intraocular delivery of antibiotics is preferred because the permeability of the retinal pigment epithelium to systemic antibiotics is variable, possibly limiting the bactericidal effect of systemic therapy.²⁵ Diamond et al²⁶ state that systemic antibiotics simply protect the patient from other infections and are not effective in treating endophthalmitis. The suspected etiology of the endophthalmitis dictates the initial intravitreal antibiotics instilled. Cultures determine the most efficacious agent.

In vitro and in vivo experience with *P boydii* have shown this organism to be relatively resistant to amphotericin B as well as to other common antifungal agents.^{5,27} Lutwick et al²⁸ reported the successful treatment of patients with deep visceral *P boydii* infections using intravenous miconazole. Miconazole is a phenethyl imidazole derivative with broad-spectrum activity against most pathogenic fungi.²⁹ At low concentrations, miconazole increases cell wall and plasma membrane permeability, and at higher levels, structurally damages the endoplasmic reticulum resulting in decreases in protein and cell wall synthesis.³⁰

In vitro and in vivo studies of the ocular penetration of intravenous miconazole have found variability in vitreous concentrations achieved and differences in efficacy.^{5,31-34} Tolentino et al³⁵

found intravitreal instillation of 10 to 80 μg of miconazole to cause no significant histopathologic or electroretinographic changes in monkey eyes. Doses of 40 μg or less were recommended for desperate fungal cases. Because of the antifungal sensitivities of our isolate, the known variable response to intravenous miconazole, and the worsening endophthalmitis, both intravitreal and systemic miconazole were administered. Clinically, the ocular infection appeared to be resolving following the vitrectomy and intravitreal miconazole therapy. The absence of the organism on all histopathologic sections studied and its failure to grow from postmortem vitreal aspirate cultures suggests that these therapeutic modalities were responsible for eradication of the organism.

Conclusion

This is the third reported case of endogenous endophthalmitis caused by *P boydii*. The combination of pars plana vitrectomy and intravitreal instillation of miconazole appeared to eradicate the organism, *P boydii*, from the vitreous cavity. Intravitreal miconazole and vitrectomy may be useful in other instances in which fungal isolates are resistant to amphotericin B.

Acknowledgment

We gratefully acknowledge the assistance of Alice Good, Roberta Abram, and Susan Nalepa in preparing this manuscript.

Z. Nicholas Zakov, M.D.
Department of Ophthalmology
The Cleveland Clinic Foundation
9500 Euclid Ave.
Cleveland, OH 44106

References

- Schlaegel TF Jr, O'Connor GR. Fungal uveitis. *Int Ophthalmol Clin* 1977; 17:121-161.
- Davidorf FH, Fannin EA, Chambers RB. Endogenous endophthalmitis. *Ophthalmic Forum* 1985; 3:81-85.
- Edwards JE Jr. *Candida* endophthalmitis. [In] Bodey GP, Fainstein V, eds. *Candidiasis*. New York, Raven Press, 1985, pp 211-225.
- Braude AI. Miscellaneous fungi: the agents of mycetoma and rhinosporidium. [In] Braude AI, Davis CE, Fierer J, eds. *Medical Microbiology and Infectious Diseases*. Philadelphia, WB Saunders, 1981, pp 684-685.
- Lutwick LI, Galgiani JN, Johnson RH, Stevens DA. Visceral fungal infections due to *Petriellidium boydii* (*Allescheria boydii*): in vitro drug sensitivity studies. *Am J Med* 1976; 61:632-640.

6. Meadow WL, Tipple MA, Rippon JW. Endophthalmitis caused by *Petriellidium boydii* (clinical memorandum). *Am J Dis Child* 1981; **135**:378-380.
7. Stevens DA. Miconazole in the treatment of systemic fungal infections (editorial). *Am Rev Respir Dis* 1977; **116**:801-806.
8. Green WO Jr, Adams TE. Mycetoma in the United States. *Am J Clin Pathol* 1964; **42**:75-91.
9. Creitz J, Harris HW. Isolation of *Allescheria boydii* from sputum. *Am Rev Tuberc* 1955; **71**:126-130.
10. Meyer E, Herrold RD. *Allescheria boydii* isolated from a patient with chronic prostatitis. *Am J Clin Pathol* 1961; **35**:155-159.
11. Blank F, Stuart EA. *Monosporium apiospermum* Sacc., 1911, associated with otomycosis. *Can Med Assoc J* 1955; **72**:601.
12. Benham RW, Georg LK. *Allescheria boydii*, causative agent in a case of meningitis. *J Invest Dermatol* 1948; **10**:99-110.
13. Roberts FJ, Allen P, Maybee TK. *Petriellidium boydii* (*Allescheria boydii*) endocarditis associated with porcine valve replacement. *Can Med Assoc J* 1977; **117**:1250-1252.
14. Pautler EE, Roberts RW, Beamer PR. Mycotic infection of the eye: *Monosporium apiospermum* associated with corneal ulcer. *Arch Ophthalmol* 1955; **53**:385-389.
15. Gordon MA, Vallotton WW, Croffead GS. Corneal allescheriosis: a case of keratomycosis treated successfully with nystatin and amphotericin B. *Arch Ophthalmol* 1959; **62**:758-763.
16. Casero L. [Keratomycosis. Its recently increased incidence and its treatment with new antifungal antibiotics.] *Arch Soc Oftalmol Hisp Am* 1962; **22**:293-300. (Spanish)
17. Zimmerman LE. Keratomycosis. *Surv Ophthalmol* 1963; **8**:1-25.
18. Ernest JT, Rippon JW. Keratitis due to *Allescheria boydii* (*Monosporium apiospermum*). *Am J Ophthalmol* 1966; **62**:1202-1204.
19. Hairstone MA, De Voe AG. Keratomycosis. An ultrastructural study. *Ophthalmologica* 1966; **152**:197-206.
20. Persaud V, Holroyd JBM. Mycetoma of the palpebral conjunctiva caused by *Allescheria boydii* (*Monosporium apiospermum*). *Br J Ophthalmol* 1968; **52**:857-859.
21. Levitt JM, Goldstein J. Keratomycosis due to *Allescheria boydii*. *Am J Ophthalmol* 1971; **71**:1190-1191.
22. Bakerspigel A. Fungi isolated from keratomycosis in Ontario, Canada. 1. *Monosporium apiospermum* (*Allescheria boydii*). *Sabouraudia* 1971; **9**:109-112.
23. Elliot ID, Halde C, Shapiro J. Keratitis and endophthalmitis caused by *Petriellidium boydii*. *Am J Ophthalmol* 1977; **83**:16-18.
24. Glassman MI, Henkind P, Altire-Werber E. *Monosporium apiospermum* endophthalmitis. *Am J Ophthalmol* 1973; **76**:821-824.
25. Diamond JG. Changing concepts in treatment of endophthalmitis. *Ophthalmic Forum* 1985; **3**:65-66.
26. Diamond JG, Forster RK, Peyman G, Rowsey JJ. Round table discussion: endophthalmitis. *Ophthalmic Forum* 1985; **3**:86-92.
27. Nielsen HS Jr. Effects of amphotericin B in vitro on perfect and imperfect strains of *Allescheria boydii*. *Appl Microbiol* 1967; **15**:86-91.
28. Lutwick LI, Rytel MW, Pena Yanez J, et al. Deep infections from *Petriellidium boydii* treated with miconazole. *JAMA* 1979; **241**:272-273.
29. Van Cutsem JM, Thienpont D. Miconazole, a broad spectrum antimycotic agent with antibacterial activity. *Chemotherapy* 1972; **17**:392-404.
30. Swamy KHS, Sirsi M, Rao GR. Studies on the mechanism of action of miconazole: effect of miconazole on respiration and cell permeability of *Candida albicans*. *Antimicrob Agents Chemother* 1974; **5**:420-425.
31. Foster CS, Stefanyszyn M. Intraocular penetration of miconazole in rabbits. *Arch Ophthalmol* 1979; **97**:1703-1706.
32. Miller GR, Rebell G, Magoon RC, et al. Intravitreal antimycotic therapy and cure of mycotic endophthalmitis caused by a *Paecilomyces lilacinus* contaminated pseudophakos. *Ophthalmic Surg* 1978; **9**:54-63.
33. Blumenkranz MS, Stevens DA. Therapy of endogenous fungal endophthalmitis: miconazole or amphotericin B for coccidioidal and candidal infection. *Arch Ophthalmol* 1980; **98**:1216-1220.
34. Fitzsimons RB, Nicholls MD, Billson FA, Robertson TI, Hersey P. Fungal retinitis: a case of *Torulopsis glabrata* infection treated with miconazole. *Br J Ophthalmol* 1980; **64**:672-675.
35. Tolentino FI, Foster CS, Lahav M, Liv LHS, Rabin AR. Toxicity of intravitreal miconazole. *Arch Ophthalmol* 1982; **100**:1504-1509.