

Large-cell lymphoma with diffuse sclerosis

A B-cell neoplasm of late-secretory, preplasma cells¹

Michael D. Linden, M.D.
Raymond R. Tubbs, D.O.
James K. Weick, M.D.

Malignant lymphoma with diffuse sclerosis and bulky disease is a relatively rare tumor characterized by an aggressive mediastinal mass with superior vena cava obstruction. The tumor is resistant to radiation or chemotherapy, and the prognosis is poor. To better understand the nature of the proliferating cell in aggressive large-cell lymphoma with diffuse sclerosis, we used frozen-section immunohistologic techniques to study tissue from a 24-year-old man who died of the disease. Immunotyping demonstrated a B-cell neoplasm (T11-, Leu5-, B1+, Leu14+). B-cell-subset immunotyping disclosed an absence of markers expressed earlier in B-cell maturation (B2-, LN2-, J5-, I2-), but uniform expression of later, preplasma-cell, secretory blast-stage antigens (IgG+, kappa+, LN1+, PCA+). These immunohistologic observations may be helpful in interpreting biopsies of sclerosing lymphomas with mediastinal presentations.

Index terms: Histology · Immunologic technics · Lymphoma

Cleve Clin Q 53:319-322, Fall 1986

Sclerosis accompanies some non-Hodgkin's lymphomas. Follicular center cell, sclerosing lymphomas are indolent.¹ However, some lym-

phomas with diffuse sclerosis are high-grade, aggressive neoplasms, relatively resistant to radiation or chemotherapy. These are often bulky, mediastinal tumors that obstruct the superior vena cava.²⁻⁵ To our knowledge, the immunotype of this relatively rare tumor has not previously been elucidated. We recently had the opportunity to study the proliferating cell in an autopsy case of large-cell lymphoma with diffuse sclerosis. We report this case including our immunohistologic observations along with a review of the pertinent literature.

Case Report

A 24-year-old white man was referred to the Cleveland Clinic in 1985 for consideration of autologous bone marrow grafting. He had been well until December 1983 when superior vena cava syndrome developed. A clinical work-up disclosed a mediastinal tumor mass. Following biopsy, a mixed lymphocytic-histiocytic-type non-Hodgkin's lymphoma was diagnosed. Initially, he was treated with cyclophosphamide, vincristine, prednisone, bleomycin, doxorubicin, and procarbazine (COP-BALM) for 26 weeks. In September 1984 the tumor recurred with a symptomatic pericardial effusion. At that time, the patient was treated with three cycles of prednisone, methotrexate, doxorubicin, cyclophosphamide, and epipodophyllotoxin-methchloroethamine, vincristine, procarbazine, and prednisone (ProMACE-MOPP). In January 1985 the patient's superior vena cava syndrome recurred, and he was treated with radiation therapy (2,984 rad [29.84 Gy]). The patient returned in April 1985 with a symptomatic, right-pleural effusion and dyspnea. In early May, he received a three-day course of epipodophyllotoxin (VP-16) and was then referred to the Clinic for autologous bone marrow transplantation. On admission,

¹ Departments of Pathology (M.D.L., R.R.T.) and Hematology/Oncology (J.K.W.), The Cleveland Clinic Foundation. Submitted for publication Dec 1985; accepted Feb 86. pa

0009-8787/86/03/0319/04/\$2.00/0

Copyright © 1986, The Cleveland Clinic Foundation

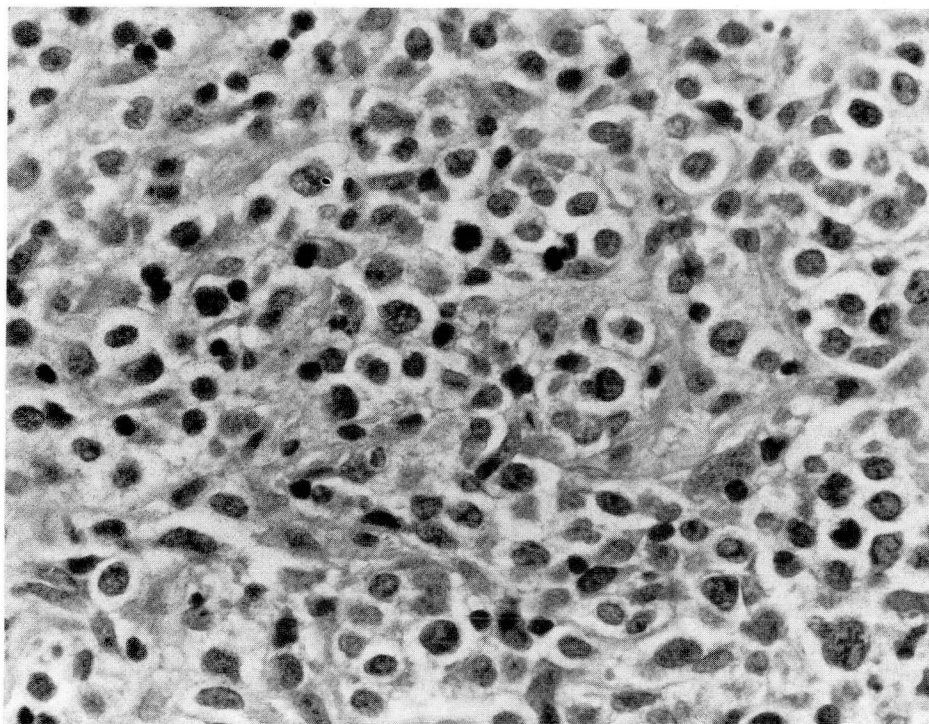


Fig. Photomicrograph of original mediastinal biopsy specimen demonstrates a diffuse, large-cell lymphoma with prominent component of uneven, compartmentalizing sclerosis (hematoxylin and eosin $\times 400$).

the patient complained of increasing shortness of breath, chest pain, and cough. He underwent bone marrow harvesting on May 29 and on June 1 began receiving VP-16. The next day he became acutely dyspneic with cough and hemoptysis. A right thoracentesis was performed without return of fluid. Shortly thereafter he became acutely hypotensive. Aggressive cardiopulmonary resuscitation did not change his condition, and he was pronounced dead a short time later.

Postmortem findings

At autopsy there was widespread lymphoma. The neoplasm extensively involved the mediastinum and pericardium: The tumor mass surrounded and compressed the heart and encased the arch of the aorta, thoracic aorta, superior vena cava, and main pulmonary artery and branches. There was marked extrinsic stenosis, but all vessels were patent. There was extensive pulmonary and pleural involvement: The diaphragm was encased and markedly thickened by tumor and fibrosis. An infradiaphragmatic tumor mass was also present and caused extrinsic stenosis of the inferior vena cava, with hepatic metastases. In addition, the tumor mass surrounded and compressed the gallbladder and right adrenal gland. The left adrenal gland was partially replaced by lymphoma. Both kidneys and perirenal tissue were also extensively involved.

Light microscopy of tumor tissue from a number of sites demonstrated a diffuse, large-cell lymphoma with prominent sclerosis (*Fig.*). Coarse, interanastomosing, collagenous

bands compartmentalized the lymphomatous infiltrate into irregular groups of cells. This prominent stromal network produced an uneven pattern of compartmentalizing sclerosis, with tumor cells unevenly spaced and poorly demarcated from the stroma. The predominant tumor cells were large and round to ovoid, with scant, indistinct cytoplasm. Nuclei were large and round to oval and predominantly noncleaved. The chromatin pattern was variable, with some nuclei having a cleared appearance, whereas others had a more condensed chromatin pattern. Mitoses and necrosis were focally present.

Immunotyping (*Table*) performed using frozen-section immunohistology⁶ demonstrated a B-cell neoplasm (T11-, Leu5-, B1+, Leu14+). B-cell-subset immunotyping disclosed an absence of markers expressed earlier in B-cell maturation (B2-, LN2-, J5-, I2-), but uniform expression of later, preplasma-cell, secretory blast-stage antigens (IgG+, kappa+, LN1+, PCA+).⁷

Discussion

The prognostic value of sclerosis in diffuse, large-cell (histiocytic) lymphomas has been controversial. In 1972 Rosas-Urbe and Rappaport⁸ studied nine patients with diffuse, histiocytic lymphomas with sclerosis. Of their nine patients, four survived five years or longer, even though therapy consisted only of local irradiation of the involved lymph nodes. In 1975 Bennett⁹ studied

Table. Lymphocyte/lymphoma antigen immunotypes

Antigen	Our case	T-cells	Pre-B, virginal, & immature B-cells	Secretory B-cells/blast stage	Preplasma cells	Plasma cells
T11	-	+	-	-	-	-
Leu5	-	+	-	-	-	-
B1	+	-	+	+	+	-
Leu14	+	-	+	+	+	-
B2	-	-	+	-	-	-
LN2	-	-	+	+	-	-
J5	-	-	+	-	-	-
I2	-	+/-	+	+	-	-
IgG	+	-	-	+	+	+
CIg†	+	-	-	+	+	+
LN1	+	-	+/-	+	+	-
PCA	+	-	-	+	+	+

+ = present; - = absent; +/- = variable; *CIg* = cytoplasmic immunoglobulin.

* Pre-B and virginal only.

† Monoclonal IgG kappa *CIg*.

242 cases of non-Hodgkin's lymphomas. In 47 cases subgrouped as diffuse, undifferentiated, large-cell type or diffuse histiocytic, 14 patients had sclerosis. More patients with sclerosis than without survived five years or longer. Furthermore, the presence of sclerosis was correlated with an improved survival in all histologic subgroups studied. Bennett⁹ proposed that the subset of patients with sclerosis had a better prognosis because of a slower rate of tumor progression. Although both these studies found a better prognosis for the subset of patients with sclerosis, these investigations were performed before the current era of effective combination-chemotherapy protocols for diffuse, large-cell lymphomas.

In contrast, Patchefsky et al.¹⁰ in 1974 studied 293 cases of non-Hodgkin's lymphomas, 50 of which had a component of fibrosis. No survival advantage was found for that subgroup. Ree et al.⁴ subdivided their patients with "compartmentalizing" sclerosis into two groups—even and uneven patterns. Patients with the uneven pattern of sclerosis had a consistently poorer prognosis. Recent results of therapy for diffuse, large-cell lymphomas have shown dramatic improvements with combination and sequential chemotherapy for diffuse, histiocytic lymphomas that are advanced and aggressive radiotherapy for more localized lymphomas.¹¹⁻¹⁴ Based on these studies, both localized and advanced, diffuse, histiocytic lymphomas can be treated and possibly cured. However, for our patient and others in recent studies,²⁻⁵ results of therapy have been poor.

The appearance and progress of our patient's sclerosing, large-cell lymphoma was similar to that of patients studied by other groups²⁻⁵; these patients often have bulky, mediastinal tumors and superior vena cava syndrome. In these cases the tumors were aggressive, with an inexorable clinical deterioration relatively resistant to radiation therapy or chemotherapy when compared with other large-cell lymphomas. Commonly, those patients whose therapy failed had mediastinal recurrences. New multiagent chemotherapy regimens, which have proved successful in other patients with advanced, large-cell lymphomas, have not produced dramatic improvements in patients with sclerosing, diffuse, large-cell lymphomas.¹² Our case is consistent with previous reports²⁻⁵ that patients with large-cell lymphomas with diffuse sclerosis have poor prognoses. These patients commonly have bulky, mediastinal tumors and superior vena cava syndrome. Their condition deteriorates rapidly, despite radiation therapy and/or chemotherapy.

A number of studies have documented the immunohistology of diffuse, large-cell lymphomas.^{6,7} The majority of diffuse, large-cell lymphomas are composed of B lymphocytes, corresponding to "transformed" B cells or the blast stage of B-cell maturation. Most diffuse, large-cell lymphomas (60% to 85%) express cell-surface immunoglobulin, I2, and B1, but do not express B2 and plasma-cell antigens. Previous studies of large-cell lymphomas with sclerosis have not included immunohistology. To better understand

the nature of the proliferating cells in these aggressive, large-cell lymphomas with diffuse sclerosis we used frozen-section immunohistologic techniques to study tissue from this 24-year-old man. Immunotyping in our case demonstrated a B-cell neoplasm (T11-, Leu5-, B1+, Leu14+). B-cell-subset immunotyping disclosed an absence of markers expressed earlier in B-cell maturation (B2-, LN2-, J5-, I2-), but uniform expression of later, preplasma-cell, secretory blast-stage antigens (IgG+, kappa+, LN1+, PCA+). These immunohistologic observations may be helpful in the overall interpretation of biopsies of large-cell lymphomas with diffuse sclerosis that appear in the mediastinum.

Raymond R. Tubbs, D.O.
Department of Pathology
The Cleveland Clinic Foundation
9500 Euclid Ave.
Cleveland, OH 44106

References

1. Waldron JA Jr, Newcomer LN, Katz ME, Cadman E. Sclerosing variants of follicular center cell lymphomas presenting in the retroperitoneum. *Cancer* 1983; **52**:712-720.
2. Miller JB, Variakojis D, Bitran JD, et al. Diffuse histiocytic lymphoma with sclerosis: a clinicopathologic entity frequently causing superior venacaval obstruction. *Cancer* 1981; **47**:748-756.
3. Trump DL, Mann RB. Diffuse large cell and undifferentiated lymphomas with prominent mediastinal involvement: a poor prognostic subset of patients with non-Hodgkin's lymphoma. *Cancer* 1982; **50**:277-282.
4. Ree HJ, Leone LA, Crowley JP. Sclerosis in diffuse histiocytic lymphoma: a clinicopathologic study of 25 cases. *Cancer* 1982; **49**:1636-1648.
5. Lichtenstein AK, Levine A, Taylor CR, et al. Primary mediastinal lymphoma in adults. *Am J Med* 1980; **68**:509-514.
6. Tubbs RR, Fishleder A, Weiss RA, Savage RA, Sebek BA, Weick JK. Immunohistologic cellular phenotypes of lymphoproliferative disorders: comprehensive evaluation of 564 cases including 257 non-Hodgkin's lymphomas classified by the International Working Formulation. *Am J Pathol* 1983; **113**:207-221.
7. Tubbs RR, Sheibani K. Immunohistology of lymphoproliferative disorders. *Semin Diagn Pathol* 1984; **1**:272-284.
8. Rosas-Urbe A, Rappaport H. Malignant lymphoma, histiocytic type with sclerosis (sclerosing reticulum cell sarcoma). *Cancer* 1972; **29**:946-953.
9. Bennett MH. Sclerosis in non-Hodgkin's lymphomata. *Br J Cancer* 1975; **31** (Suppl. II):44-52.
10. Patchefsky AS, Brodovsky HS, Menduke H, et al. Non-Hodgkin's lymphomas: a clinicopathologic study of 293 cases. *Cancer* 1974; **34**:1173-1186.
11. Bitran JD, Kinzie J, Sweet DL, et al. Survival of patients with localized histiocytic lymphoma. *Cancer* 1977; **39**:342-346.
12. Sweet DL, Golomb HM, Ulmann JE, et al. Cyclophosphamide, vincristine, methotrexate with leucovorin rescue, and cytarabine (COMLA) combination sequential chemotherapy for advanced diffuse histiocytic lymphoma. *Ann Intern Med* 1980; **92**:785-790.
13. Schein PS, DeVita VT, Hubbard S, et al. Bleomycin, adriamycin, cyclophosphamide, vincristine, and prednisone (BACOP) combination chemotherapy in the treatment of advanced diffuse histiocytic lymphoma. *Ann Intern Med* 1976; **85**:417-422.
14. Rodriguez V, Cabanillas F, Burgass MA, et al. Combination chemotherapy ("CHOP-Bleo") in advanced (non-Hodgkin) malignant lymphoma. *Blood* 1977; **49**:325-333.