

Secretory villous tumor of the ampulla of Vater¹

Sharon Grundfest-Broniatowski, M.D.

An unusual case of a malignant villous tumor of the ampulla of Vater is presented. This tumor caused a sodium- and chloride-rich secretion into the biliary tree. A percutaneous transhepatic drainage tube was inserted, and the resultant fluid loss caused hyponatremia, hypochloremia, and oliguric renal failure. Villous tumors of the ampulla may sometimes secrete large quantities of fluid in a manner analogous to rectal villous tumors.

Index terms: Case reports • Vater's ampulla
Cleve Clin Q 53:357-361, Winter 1986

Villous tumors of the duodenum are rare lesions. They characteristically are small and usually papillary. Ampullary tumors frequently obstruct the bile duct at a relatively early stage, resulting in early diagnosis compared to carcinoma of the pancreas.¹ In general, these tumors do not exhibit any active secretion, and percutaneous transhepatic cholangiography and percutaneous drainage are considered to be safe. A patient with a secretory tumor in which percutaneous transhepatic decompression resulted in hypovolemia and renal failure is described here.

Case report

A 54-year-old woman presented to her local physician in February 1980 for evaluation of possible renal stones. She

was scheduled to undergo retrograde nephrography, but the procedure was cancelled when her alkaline phosphatase level was found to be 1,500 IU/L (normal, 79-259 IU/L). She was not jaundiced at that time and had no symptoms of right upper quadrant pain. She had no symptoms of hepatitis or alcohol abuse. A remote cholecystectomy was performed 32 years earlier, without complications. A percutaneous liver biopsy was performed and findings were interpreted as showing micronodular cirrhosis. A tentative diagnosis of primary biliary cirrhosis was made; however, both antimitochondrial and smooth muscle antibodies were within normal limits. A subsequent hepatitis screen was positive for convalescent phase IgG antibody to hepatitis A virus.

In September 1981, painless jaundice and dark-colored urine developed. Her bilirubin level at that time was 8.8 mg/dL (normal, 0-1 mg/dL), and her alkaline phosphatase value was 1,224 IU/L (normal, 79-258 IU/L). An upper gastrointestinal endoscopy was performed and revealed a 3 × 3-cm mass at the ampulla of Vater. The lesion was biopsied and interpreted as a villous adenoma with focally severe dysplasia. A percutaneous transhepatic cholangiogram showed a large dilated common bile duct with an irregular filling defect in its distal portion. A catheter was left in the bile duct for percutaneous drainage. This catheter drained over 4,000 mL in the first 12 hours and continued to drain so copiously that the patient became hypovolemic, azotemia developed, and intravenous hydration was required. She was transferred to the Cleveland Clinic four days following insertion of the catheter for further management.

During the transfer, her percutaneous catheter became dislodged. On arrival at the hospital, her laboratory values were as follows: bilirubin, 3.7 mg/dL (normal, 0.2-1.0 mg/dL); creatinine, 3.0 mg/dL (normal, 0.7-1.4 mg/dL); and BUN, 23 mg/dL (normal, 10-20 mg/dL). Serum electrolytes were abnormal with a sodium value of 122 mEq/L (normal, 135-148 mEq/L); chloride, 92 mEq/L (normal 98-105 mEq/L); potassium, 4.3 mEq/L (normal, 3.5-5.5 mEq/L), and carbon dioxide, 19 mEq/L (normal, 25-29 mEq/L). The patient was given hydration and antibiotics intravenously. A repeat cholangiogram again revealed an obstructing lesion of the distal common bile duct (Fig. 1), and a new percutaneous catheter was inserted. In the first 16 hours, it drained 4,000 mL of a clear, light, yellow fluid.

¹ Department of General Surgery, The Cleveland Clinic Foundation. Submitted for publication July 1985; accepted April 1986.

0009-8787/86/04/0357/05/\$2.25/0

Copyright © 1986, The Cleveland Clinic Foundation

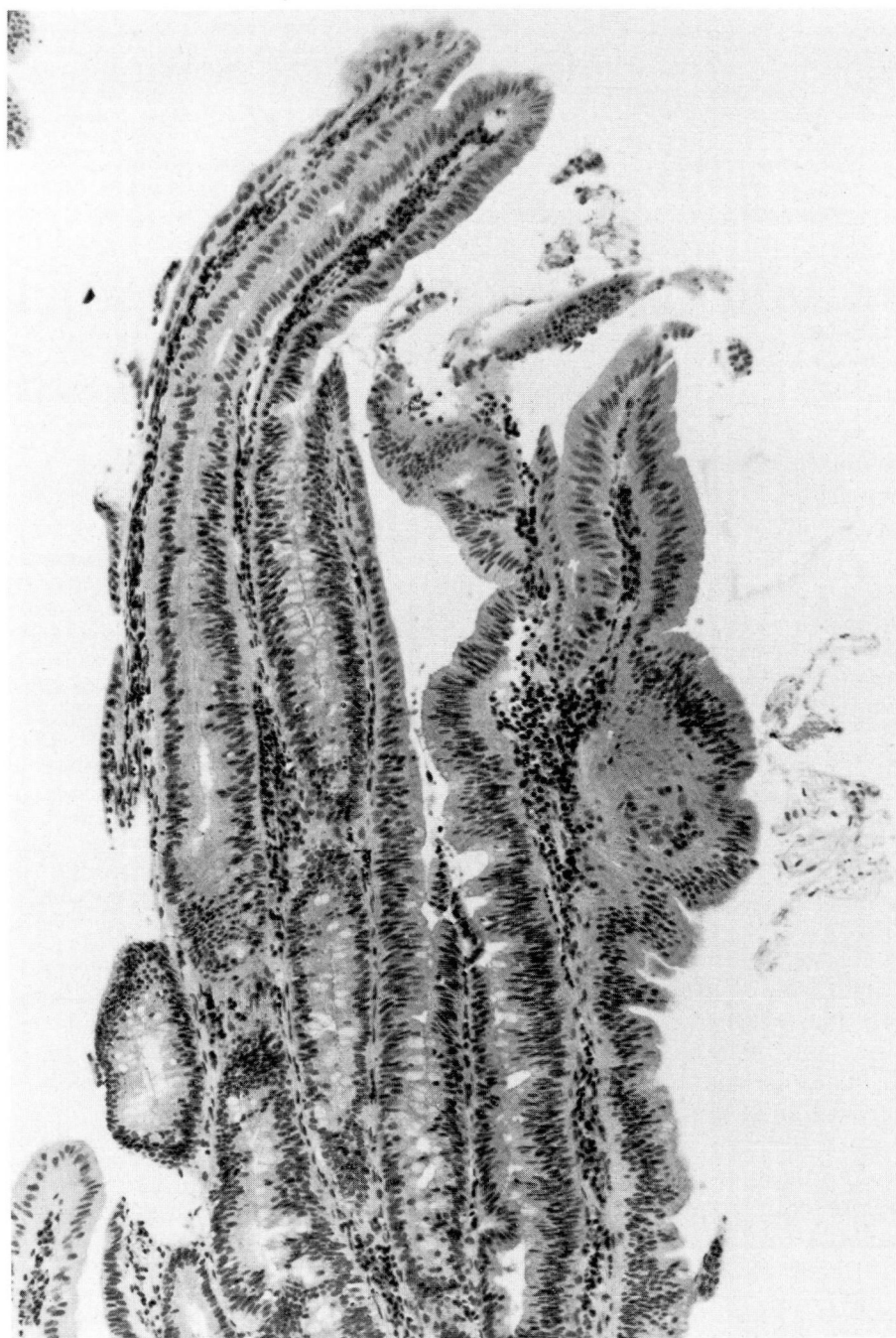


Fig. 1. Villous adenoma of the duodenum (hematoxylin-eosin, $\times 100$).

On the second day, 5,470 mL was recorded, and on the third day, the total was 10,415 mL. Because the fluid coming out of the percutaneous catheter appeared to be the same color as urine or ascites, a sample of the fluid was sent for an evaluation which disclosed the following values: biliary sodium, 131 mEq/L (normal, 131–164 mEq/L) and potassium, 4.2 mEq/L (normal, 3–12 mEq/L). Her urine sodium

at that time measured 21 mEq/L, and the urine potassium was 13 mEq/L. A gastric analysis performed on the same day showed a gastric fluid sodium level of 121 mEq/L and a potassium level of 3.8 mEq/L. A repeat analysis of the biliary drainage on September 8 showed the following values: sodium, 145 mEq/L; potassium, 4.5 mEq/L; carbon dioxide, 13 mEq/L; albumin, 0.1 gm/dL; and glucose, 4

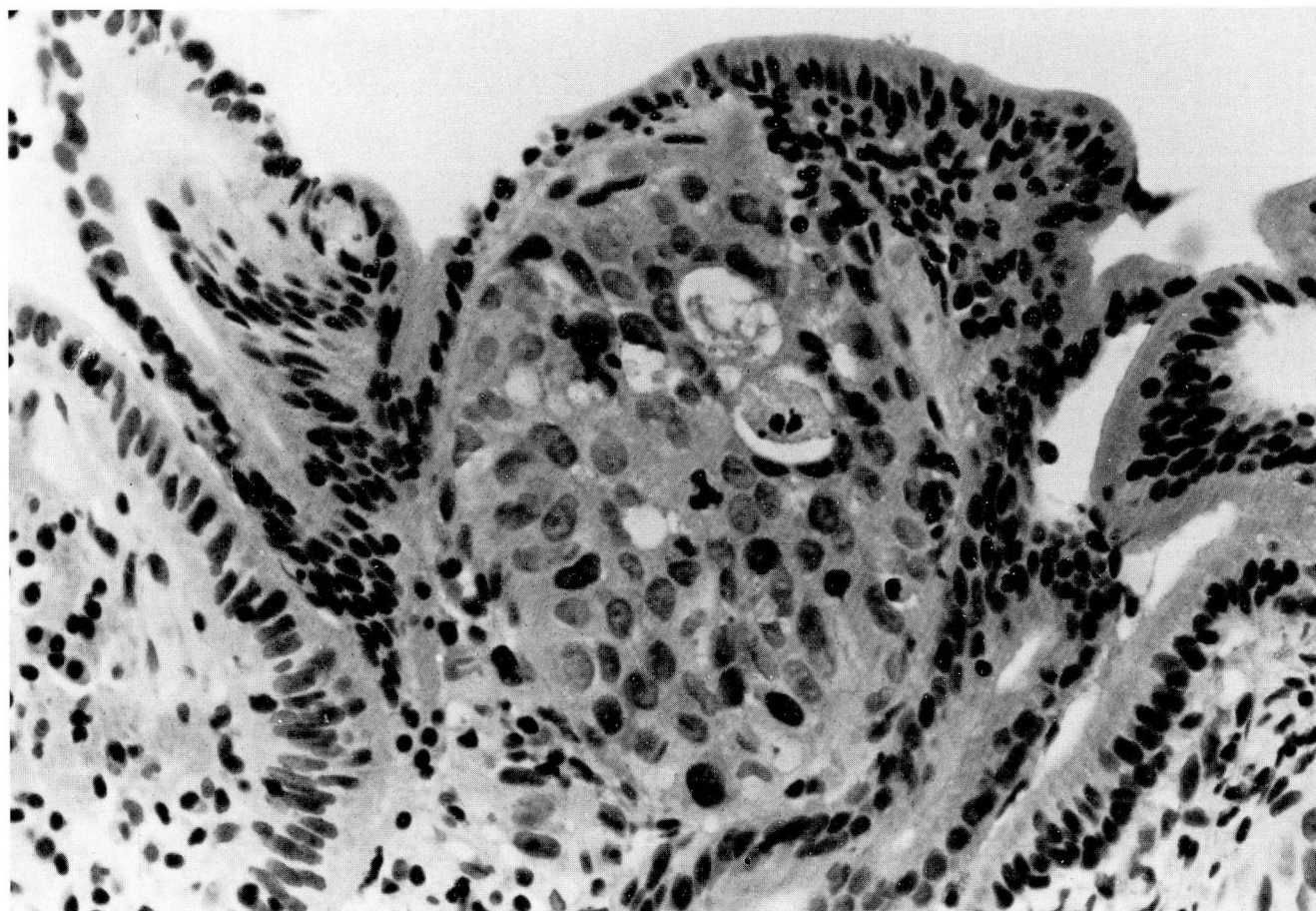


Fig. 2. Adenocarcinoma within the lamina propria of villous adenoma. The tumor is solid in growth pattern with only focal gland differentiation with mucin production (hematoxylin-eosin, $\times 400$).

mg/dL. Interestingly, although the patient's serum bilirubin level was 3.8 mg/dL (normal, 0.2–1.0 mg/dL) and her serum alkaline phosphatase value was 313 IU/L (normal, 20–110 IU/L), the bilirubin and alkaline phosphatase levels during biliary drainage were 3.6 mg/dL and 8 IU/L, respectively. If one assumes that the normal bilirubin production is in the range of 250 to 350 mg/day,³ it is clear that the total bilirubin production was only minimally elevated in this patient, if at all. A repeat cholangiogram confirmed that the catheter was indeed positioned in the biliary tree.

A Swan-Ganz catheter was inserted into the pulmonary artery for assistance in fluid management. Drainage continued from the hepatic tube (3–9 L daily), and over the next week, 7–9 L of intravenous fluids per day was required to maintain adequate urine output. A repeat endoscopy revealed the villous lesion in the ampulla. Biopsy findings showed only chronic inflammation, but a review of the outside biopsy slides revealed a villous adenoma with foci of adenocarcinoma (Fig. 2). Blood was obtained for serum secretin, vasoactive intestinal polypeptide, and gastrointestinal inhibitory polypeptide evaluations. Measurements were 13 pg/mL (normal values not established), 19 pg/mL (normal, <75 pg/mL), and <60 pg/mL (normal, 150 to 350 pg/mL), respectively.

With hydration, the patient's urine outputs gradually improved, but the serum creatinine level remained at 5.2 mg/dL, and the BUN remained at 62 mg/mL. Unfortunately, upper gastrointestinal bleeding developed. Repeat endoscopy showed a bleeding duodenal tumor and non-bleeding esophageal varices. A laparotomy was performed, and the patient was found to have multiple metastases to the liver, peritoneum, and porta hepatis. There was a large amount of malignant ascites and extensive varices. The tumor around the porta hepatis and the varices precluded any palliative bypass of the bile duct. One of the metastatic lesions in the liver was biopsied (Fig. 3), and the abdomen was closed. The patient was transferred back to her local hospital at the family's request, and she died two weeks later.

Discussion

The normal amount of bile produced daily is estimated to vary from 500 to more than 1,200 mL, depending on the method of collection, amount and type of diet, state of hydration, and influence of other stimuli such as vagal stimulation, secretin, and reabsorption of bile acids.⁴

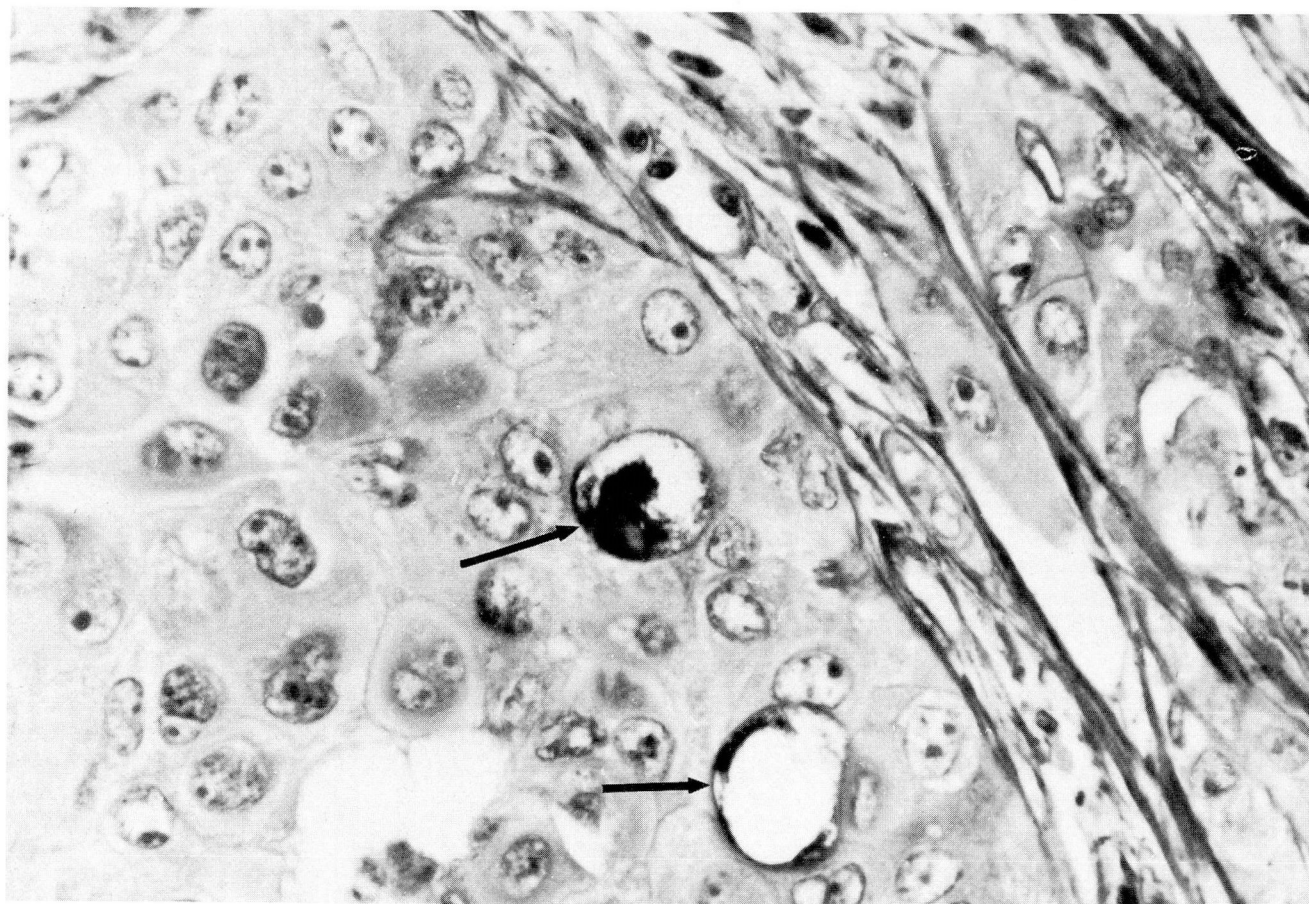


Fig. 3. Metastatic adenocarcinoma in the liver. Only focal mucin production is identified (arrows) (hematoxylin-eosin, $\times 400$).

Bile formation is a complex process and is comprised of four separate physiologic mechanisms. Bile production begins in the hepatocytes or at the bile canaliculus. At this level, there is both a bile salt-dependent and a bile salt-independent secretion. The canalicular bile then moves into the biliary ducts where secretion is further modified by addition of water and electrolytes from the biliary ductular epithelium or, in some cases, by absorption of water and electrolytes.⁵ During the process of digestion, bile secretion varies with the secretion of neurohumoral factors. A variety of hormones has been shown to augment biliary secretion in experimental animals and in man. These include secretin, cholecystokinin, cholecystokinin octapeptide, glycocholate, taurocholate, sodium dehydrocholate, and magnesium ferulate.⁶⁻⁸ None of these stimulants has been associated with the enormous outputs seen in the patient described here. Furthermore, the amount of bilirubin within the biliary fluid was low. Thus,

the fluid appeared to be consistent with a secretory process other than that produced by the hepatocytes.

Complete biliary obstruction has been shown to be associated with a postcholestatic choleresis both in the rat and in man.^{9,10} Rat studies have shown increased bile flow of approximately five times normal following the release of biliary obstruction. However, this effect was transient and disappeared after approximately 90 minutes. Preisig et al¹⁰ found that nonobstructed bile flows were approximately one half of obstructed flows, with the average postoperative choleresis measuring 0.53 mL/min. However, postoperative choleresis does not explain the large volume of fluid seen in the patient described here since biliary outputs following relief from the obstruction rarely exceed more than 1.5 L/day, even when the bile duct is completely obstructed distally.

Many authors have described patients with mu-

cus-producing tumors of the biliary tree.¹¹⁻¹³ These patients complained preoperatively of "glairy" diarrhea, and their cholangiograms revealed diffuse papillomatosis of the biliary tree. By contrast, the patient described here had only one well-defined villous tumor in the distal common bile duct and ampulla and no diarrhea. Furthermore, the fluid was not mucoid in character, although a mucicarmine stain did demonstrate small amounts of mucus in the hepatic metastasis.

This tumor could have either secreted a large amount of fluid itself or caused a large amount of biliary secretion from the liver by means of hormonal stimulation. Certainly, villous tumors of the colon are well known for producing sodium- and potassium-rich secretion which can occasionally produce severe dehydration, hypokalemia, and occasionally hyponatremia.¹⁴⁻¹⁸ The patient had no complaints of pain or nausea. A tumor secreting large amounts of fluid into the duodenum could theoretically be expected to cause diarrhea, as in the Zollinger-Ellison syndrome; however, if the fluid is osmotically similar to extracellular fluid, the jejunum should be capable of absorbing these excess secretions and preventing an electrolyte imbalance. A lack of any significant amount of protein in the fluid also suggests that there is no enzymatic component involved in this fluid secretion.

With the advent of internal biliary stents, such a case could now be handled with internal drainage via a percutaneously placed or endoscopically placed catheter. This might avoid the large fluid losses which were responsible for the electrolyte imbalance, as described here. Alternatively, one could ablate such a tumor with laser. It is clear, however, that in this instance, the cause of death was widespread metastases and local control would not have prolonged survival.

Acknowledgment

I am indebted to Dr. Ralph Tuthill in the Department of Pathology for the photomicrographs of the pathological material.

References

- Cooperman AM, Hoerr SO. Cancer of the pancreatic region. [In] Cooperman AM, Hoerr SO, eds. Surgery of the Pancreas: A Text and Atlas. St. Louis, CV Mosby, 1978, pp 153-197.
- Shires GT, Kanazaro PC. Fluid and electrolyte management of the surgical patient. [In] Sabiston DC, ed. Textbook of Surgery. Philadelphia, WB Saunders, 1986, pp 64-86.
- Berk PD, Howe RB, Bloomer JR, Berlin NI. Studies of bilirubin kinetics in normal adults. *J Clin Invest* 1969; **48**:2176-2190.
- Holzbach RT. Physiology of bile production and storage. [In] Herman RE, ed. Manual of Surgery of the Gallbladder, Bile Ducts, and Exocrine Pancreas. New York, Springer-Verlag, 1978, p 16.
- Jones RS, Meyers WC. Regulation of hepatic biliary secretion. *Annu Rev Physiol* 1979; **41**:67-82.
- Jansson R, Steen G, Svanvik J. A comparison of glucagon, gastric inhibitory peptide, and secretin on gallbladder function, formation of bile, and pancreatic secretion in the cat. *Scand J Gastroenterol* 1978; **13**:919-925.
- Shaw RA, Jones RS. The choleretic action of cholecystokinin and cholecystokinin octapeptide in dogs. *Surgery* 1978; **84**:622-625.
- Chevreil B. Cholereses et choleretiques. *Med Chir Dig* 1979; **8**:479-482.
- Accatino L, Contreras A, Fernández S, Quintana C. The effect of complete biliary obstruction on bile flow and bile acid excretion: postcholestatic cholerisis in the rat. *J Lab Clin Med* 1979; **93**: 706-717.
- Preisig R, Bucher H, Stirnemann H, Tauber J. Postoperative cholerisis following bile duct obstruction in man. *Rev Franc Etud Clin Biol* 1969; **14**: 151-158.
- Mercadier M, Bodard M, Fingerhut A, Chigot JP. Papillomatosis of the intrahepatic bile ducts. *World J Surg* 1984; **8**:30-35.
- Eiss S, DiMaio D, Caedo JP. Multiple papillomas of the entire biliary tract: case report. *Ann Surg* 1960; **152**:320-324.
- Cattell RB, Braasch JW, Kahn F. Polypoid epithelial tumors of the bile ducts. *N Engl J Med* 1962; **266**:57-61.
- Davis JE, Seavey PW, Sessions JT Jr. Villous adenomas of the rectum and sigmoid colon with severe fluid and electrolyte depletion. *Ann Surg* 1962; **155**:806-816.
- Gjöres JE, Örndahl B. Villous adenoma with severe fluid imbalance. *Acta Chir Scand* 1974; **140**:82-84.
- Jahadi MR, Bailey W. Papillary adenomas of the colon and rectum: a twelve-year review. *Dis Colon Rectum* 1975; **18**: 249-253.
- Jeanneret-Grosjean AJ, Thompson WG. Villous adenoma with hyponatremia and syncope: report of a case. *Dis Colon Rectum* 1978; **21**:118-119.
- Roy AD, Ellis H. Potassium-secreting tumours of the large intestine. *Lancet* 1959; **1**:759-760.

Sharon Grundfest-Broniatowski, M.D.
Department of General Surgery
The Cleveland Clinic Foundation
9500 Euclid Ave.
Cleveland, OH 44106

ERRATUM

Fouad FM, Tarazi RC, Bravo EL. Orthostatic hypotension: clinical experience with diagnostic tests. *Cleve Clin Q* 52:561-568, Winter 1985.

The last word in the twelfth line of the first complete paragraph on page 564 should be **hypervolemia**.