

Spontaneous cholecystocutaneous fistulas¹

A. G. Hakaim, M.Sc., M.D.
David P. Vogt, M.D.

Spontaneous cholecystocutaneous fistula is rarely seen today because of the increased frequency and relative safety of biliary surgery. Chronic gallbladder inflammation secondary to calculous disease is the most frequent cause. Initial therapy consists of local drainage; a contrast-enhanced study of the fistulous tract should then be obtained. Definitive therapy consists of excision of the fistula, cholecystectomy, and intraoperative cholangiography. This problem occurs more frequently in the stoical, elderly patient with neglected biliary disease. A case is presented, along with a review of the literature.

Index term: Biliary fistula

Cleve Clin Q 53:363-365, Winter 1986

Spontaneous external biliary fistulas have long been known to occur. In 1890, Courvoisier published a series of 169 cases among 499 spontaneous gallbladder perforations.¹ Although the incidence of this condition has declined since the increase in surgical intervention, it remains a possible complication of neglected biliary disease. We report a case of cholecystocutaneous fistula, its management, and a review of the various clinical presentations and underlying biliary disease processes.

Case report

An 81-year-old Russian man presented to the emergency room because of a tender, draining, right upper quadrant

mass. He related a two- to three-month history of anorexia, a 20-pound (9-kg) weight loss, fever and chills, and a three- to four-week history of a mass on the right side of the abdomen. The abdominal wall mass had begun spontaneously draining a thick, foul-smelling liquid one day prior to presentation. The patient's medical history included two ulcer operations done in Russia in 1930 and 1957, the details of which were not known.

Physical examination revealed an anicteric white man in moderate distress. Vital signs were stable, and the temperature was 37.2° C orally. Abdominal examination revealed a midline scar and an erythematous area of approximately 5 cm diameter in the right upper quadrant. At the center of this area was an indurated opening with a small amount of whitish purulent drainage. Mild tenderness to palpation was noted in the right upper quadrant, but no organomegaly was found.

A plain abdominal radiograph revealed a moderate amount of gas throughout the large and small bowel, normal soft-tissue structures, and no free air under the diaphragm. A chest radiograph was unremarkable, and an electrocardiogram revealed an old inferior myocardial infarct. Admission laboratory data demonstrated a white cell count of 12,700/mm³, hemoglobin level of 12.9 g/dL, amylase level of 34 U/L, and normal liver function studies.

In the emergency room, an 8-F rubber catheter was inserted into the draining site, with use of local anesthesia. Approximately 50 mL of purulent fluid was immediately evacuated. Gram staining revealed many gram-positive cocci in pairs and clusters. Cultures of the fluid grew *Escherichia coli*, *Klebsiella* sp, and alpha *Streptococcus* non-Group D. The patient was admitted to the hospital with the provisional diagnosis of either an enterocutaneous or cholecystocutaneous fistula. Appropriate antibiotic therapy was begun. He remained afebrile and 40 to 60 mL of fluid was drained daily from the fistulous tract. A sinogram (Fig. 1) revealed a large, irregular cavity of 9 cm in its greatest dimension communicating with the gallbladder and biliary tree. Computed tomography failed to demonstrate an intra-abdominal abscess or suggest the presence of a tumor mass.

The patient was discharged after ten days of antibiotic therapy. The volume of daily drainage had decreased dramatically. One month after discharge, a sinogram showed that both the fistulous tract and cavity had healed. The drain was therefore removed.

¹ Department of General Surgery, The Cleveland Clinic Foundation. Submitted for publication April 1986; accepted Aug 1986.

ht

0009-8787/86/04/0363/03/\$1.75/0

Copyright © 1986, The Cleveland Clinic Foundation

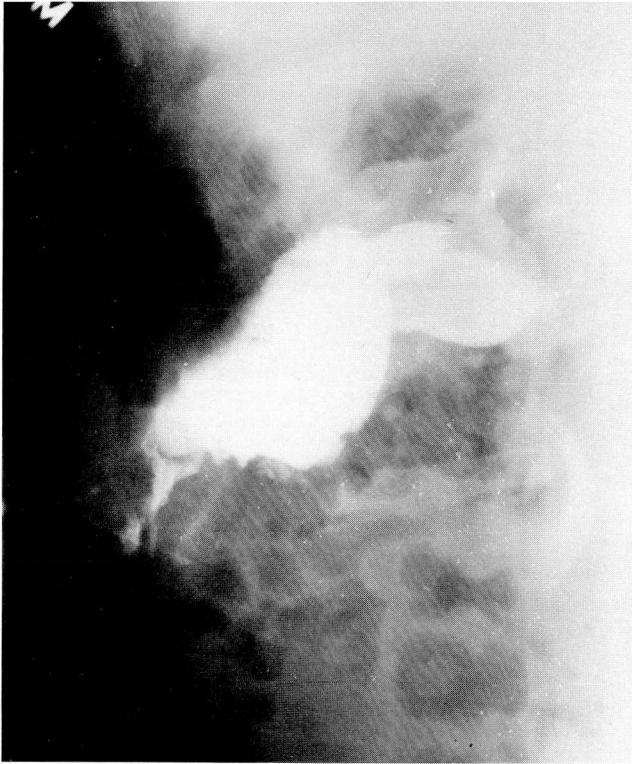


Fig. 1. Fistulogram demonstrating abscess cavity, gallbladder, and bile ducts.

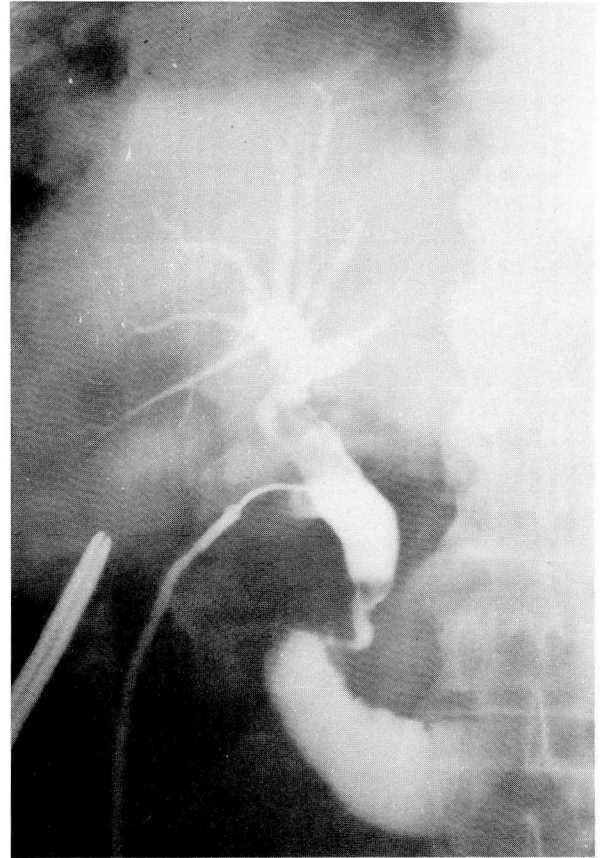


Fig. 2. Operative cholangiogram demonstrating common bile duct stones.

The patient was scheduled for an elective cholecystectomy. At the time of surgery, the fistulous tract was excised. The gallbladder was chronically diseased and contained several stones. The operative cholangiogram demonstrated common bile duct stones, requiring a duct exploration (*Fig. 2*). The postoperative course was uneventful, and no residual stones were seen when a T-tube cholangiogram was obtained one week later. The T-tube was removed, and the patient was discharged from the hospital. When he returned one month later for follow-up, he was doing well.

Discussion

Cholecystocutaneous fistula was recognized long before 1900.¹ In the older accounts, healing of the fistula was associated with either passage of a large gallstone through the fistulous tract or performance of a cholecystectomy. Although the incidence of spontaneous cholecystocutaneous fistula has fallen dramatically in the twentieth century (*Table*), one should keep this entity in mind when examining the elderly, especially reticent, stoical patients too ashamed to complain about symptoms.

The majority of patients who present with a spontaneous cholecystocutaneous fistula will have had biliary symptoms for several years.⁵ Our patient had been ill for several months and had been aware of the right upper quadrant mass for approximately two to three weeks prior to presentation. An occasional patient may be completely asymptomatic except for the draining fistulous tract.⁶ In our patient, the fistulous tract opened in the right hypochondrium, which occurs in approximately 50% of cases. Occasionally, the fistula may be directed by the falciform ligament to the region of the umbilicus.⁷ Fistulous openings in the right iliac fossa, right groin, left costophrenic margin, and the back have been reported.⁶

Chronic inflammation or infection of the gallbladder is necessary for the development of a cholecystocutaneous fistula. The chronically inflamed gallbladder adheres to the overlying peritoneum and subsequently perforates the abdominal wall.⁷ Although the majority of cholecysto-

cutaneous fistulas result from calculous biliary disease, this entity may also result from a carcinoma of the gallbladder.^{7,8} In a few reports, neither stones nor tumor were demonstrated.⁶ The cystic duct may be obstructed, but jaundice is uncommon. In our patient, the fistulogram demonstrated a normal biliary tree. The differential diagnosis for cholecystocutaneous fistula includes enterocutaneous fistula, suture granuloma, and various cutaneous conditions such as pyogenic granuloma, infected epidermal inclusion cyst, or metastatic skin disease.⁴ The cutaneous state that precedes rupture was termed *empyema necessitatis* by Nayman.⁹

The initial therapy for a cholecystocutaneous fistula is conservative. Adequate drainage is established by unroofing the fistulous tract with the aid of local anesthesia. Broad-spectrum antibiotic coverage is instituted until culture results are available. In most cases, antibiotics may be discontinued after seven to ten days. The diagnosis is confirmed by fistulography. In our patient, a portion of the gallbladder, abscess cavity, and biliary tree was clearly outlined. Drainage should be maintained until either the flow ceases or inflammation and induration subside. In our patient, the fistulous tract healed completely.

The definitive therapy for spontaneous cholecystocutaneous fistula is excision of the fistulous tract, cholecystectomy, and intraoperative cholangiography.⁵ In 1955, the overall operative mortality associated with cholecystectomy in patients more than 65 years of age was 6.7%; for elective cholecystectomy, the mortality was 4.4%.¹⁰ In recent years, the operative mortality in this elderly age group has been reduced to 2.3%.¹⁰ This low mortality justifies an aggressive approach to biliary disease, even in patients more than 65 years of age.

Table. Reported cases of spontaneous external biliary fistula

Author	Year	No. of cases reported
Courvoisier ¹	1890	169
Sturniolo et al ²	1979	13
Leonardi et al ³	1974	3
Callen ⁴	1979	1
Hoffmann et al ⁵	1982	2

References

1. Courvoisier L. Beiträge zur Pathologie und Chirurgie der Gallenwege. Leipzig, 1890.
2. Sturniolo G, Carditello A, Cavallaro G. La fistola colecistico-cutanea spontanea. *Minerva Chir* 1981; **36**:175-178.
3. Leonardi LS, Raposo de Medeiros R, Brandalise NA, et al. Fistulas biliares espontâneas. *Rev Paul Med* 1974; **83**:49-56.
4. Callen JP. Cholecystocutaneous fistula. *Int J Dermatol* 1979; **18**:63-64.
5. Hoffman L, Beaton H, Wantz G. Spontaneous cholecystocutaneous fistula. A complication of neglected biliary tract disease. *Am J Geriat Soc* 1982; **14**:632-634.
6. Henry CL, Orr TG Jr. Spontaneous external biliary fistulas. *Surgery* 1949; **26**:641-646.
7. Abril A, Ulfohn A. Spontaneous cholecystocutaneous fistula. *South Med J* 1984; **77**:1192-1193.
8. Davis AA. Passage of gallstones through the abdominal wall. *Br Med J* 1930; **2**:471.
9. Nayman J. Empyema necessitatis of the gallbladder. *Med J Aust* 1963; **1**:429-430.
10. Glenn F. Surgical management of acute cholecystitis in patients 65 years of age and older. *Ann Surg* 1981; **193**:56.

David P. Vogt, M.D.
 Department of General Surgery
 The Cleveland Clinic Foundation
 9500 Euclid Avenue
 Cleveland, Ohio 44106

ERRATUM

Collins GB, Kotz M, Messina M, Ferguson T. Affective disorder in bulimic anorexics and their families. *Cleve Clin Q* 52:399-401, Fall 1985.

The first two sentences in the Results section should read as follows:

Of the 43 bulimic anorexic probands, there were 29 adult patients (age 18 years and older) and 14 juvenile patients (under age 18). Twenty-one of the 43 patients (48.8%) were designated as having affective disorder.