

Use of thallium-technetium parathyroid scans¹

Thomas A. Broughan, M.D.
James K. O'Donnell, M.D.
Michael D. Kropilak, M.D.
Caldwell B. Esselstyn, Jr., M.D.

Localization of parathyroid pathology prior to reoperative neck exploration for hyperparathyroidism decreases operating time and potential morbidity. A color-graded nuclear scan using computer subtraction of technetium 99m from thallium-201 images is an accurate means of locating the parathyroid tissue in patients who have previously had one or more neck explorations.

Index terms: Parathyroid glands, radionuclide studies
Cleve Clin J Med 54:179-183, May/June 1987

Preoperative localization of parathyroid glands can be a great asset. An experienced endocrine surgeon will successfully treat 97% of hyperparathyroid cases at the first neck operation.¹ Previous thyroid or parathyroid surgery reduces the success of operations for recurrent or persistent hyperparathyroidism to the 72% range.² It is in these reoperative cases that preoperative parathyroid localization is useful.

The use of nuclear medicine scans to identify parathyroid glands is appealing because of their noninvasive nature. Many radiolabeled compounds have previously been used for parathyroid localization including radiocyanocobalamine,³ I-131-tagged toluidene blue,³ selenomethionine 75,³ gallium 67,⁴ cesium 131,⁴ and thallium 201.⁵ Double-tracer computer subtraction techniques were then developed to improve the accuracy of nuclear scans.⁴ Currently, thallium 201 and technetium 99m are paired.⁶ We are reporting our experience with color-graded, thallium-tech-

¹ Departments of Surgery (T.A.B., M.D.K., C.B.E.) and Nuclear Medicine (J.K.O.), The Cleveland Clinic Foundation. Submitted for publication Oct 1986; accepted Feb 1987.

0891-1150/87/03/0179/05/\$2.25/0

Copyright © 1987, The Cleveland Clinic Foundation

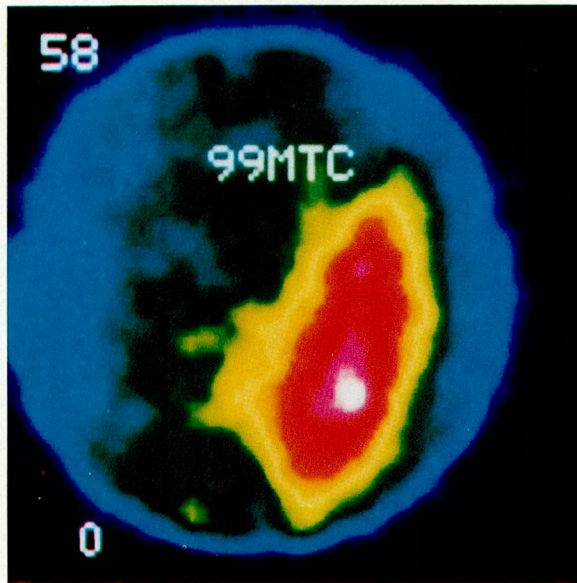


Fig. 1. Thyroid image after injection of Tc 99m.

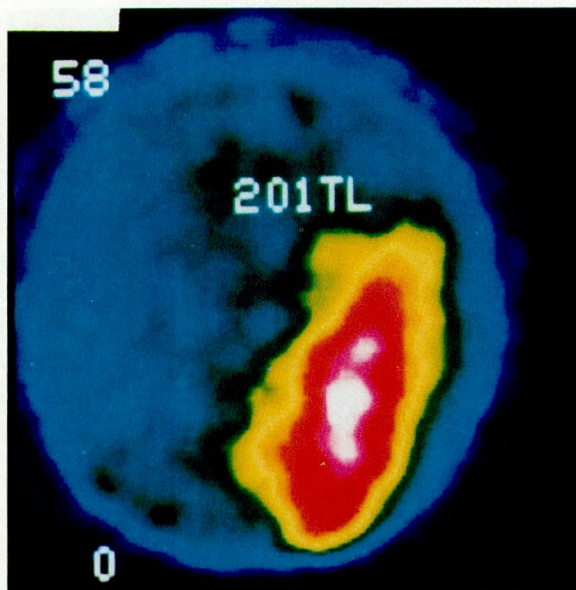


Fig. 2. Image of thyroid and parathyroids after injection of Tl 201.

netium computer subtraction scanning, particularly as it pertains to reoperative parathyroid surgery.

Materials and methods

Parathyroid imaging is performed with a standard gamma camera equipped with pinhole collimation and interfaced to a minicomputer for digital image acquisition. The patient receives an intravenous dose of Tc-99m pertechnetate

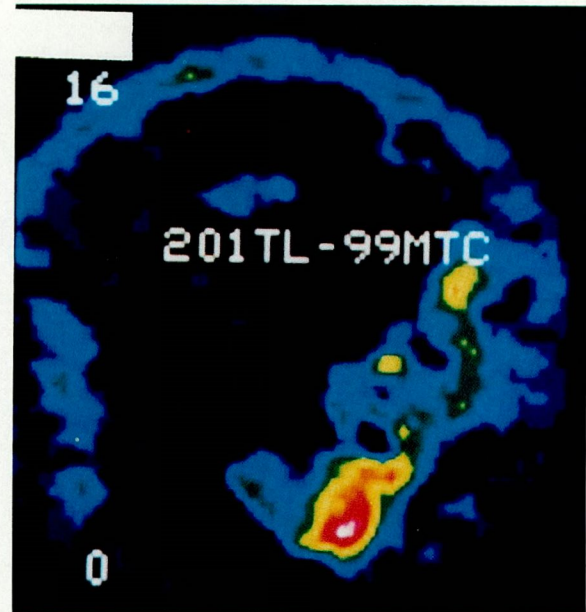


Fig. 3. Computer subtraction image of the parathyroid adenoma.

(TcO₄, 1 mCi) approximately 15 minutes prior to the imaging study. After positioning the patient supine for anterior views of the neck, a 50,000-count static image of the thyroid gland area is acquired (Fig. 1). Next, a dose of Tl-201 thallos chloride (1 mCi) is injected, and a series of images are acquired for 30 minutes at 30 seconds per image (Fig. 2).

The raw data undergo a spatial smoothing followed by sequential additions of the thallium-image frames until enough frames are combined to equal the maximal counts per pixel of the technetium thyroid image. A digital subtraction image of the technetium image from the normalized thallium composite image is then made. The final image represents residual thallium activity minus background activity from the thyroid (Fig. 3). In other words, thyroid plus parathyroid (i.e., the thallium image) minus thyroid (i.e., the technetium image) equals parathyroid. The patient is required to lie motionless for 30 to 40 minutes. The total cost for the scan is \$152.

Between March 1984 and July 1985, 86 patients (28 men, 58 women; age range, 17–83 years [mean, 55]) with primary hyperparathyroidism underwent computer subtraction scanning with thallium and technetium. Each patient subsequently underwent parathyroid surgery.

The patients were assessed for preoperative symptoms and blood chemistries, as well as parathyroid hormone. The operative reports and pa-

thology of previous neck operations were always investigated and confirmed by a review of the pathology slides. Scan results were recorded as were intraoperative findings. The position of the abnormal glands, their overlap with the thyroid, the presence of thyroid nodules, and parathyroid gland volumes were tabulated.

Results

Preoperative symptoms are listed (*Table 1*). Of the 86 patients, 36% were asymptomatic and 64% were symptomatic. Sixty-nine patients had a single adenoma, 16 patients had hyperplasia, and 1 patient had no parathyroid pathology demonstrated.

The blood chemistries included calcium, phosphate, and chloride. The values from these tests could not be used to predict successful localization on the thallium-technetium scan.

Parathyroid hormone levels were known for 42 patients. Nine patients had parathyroid pathology discovered at neck exploration, but they had normal parathyroid hormone levels preoperatively. Too many different methods for parathyroid hormone determination were used to allow analysis of the predictive value of this test.

Fourteen patients had had previous neck surgery (10 for hyperparathyroidism and 4 for thyroid disease). Twelve of these 14 patients (86%) had the parathyroid pathology accurately localized by preoperative scanning: 8 patients had a single adenoma, 3 had a single hyperplastic gland, and 1 had two hyperplastic glands. Two reoperative cases did not have accurate localization. One such patient had a false-positive localization in the neck. Four glands had been found previously. The fifth gland was later identified in the anterior mediastinum by computed tomography (CT). The other patient had no localization on the thallium-technetium scan, but a large left upper adenoma was found on re-exploration.

Single adenomas were present in 60 patients having their first neck exploration. These were successfully localized in 42 patients for a localization rate of 70%. Included in the analysis was 1 patient who did not have the adenoma localized because it was in the thymus in the anterior mediastinum and outside the field of view for the scanning camera.

Hyperplastic glands were present in 12 previously unoperated patients who had a total of 45 glands present for localization. Only 16 of the possible 45 glands (36%) were successfully localized. One patient had one hyperplastic gland and

Table 1. Preoperative symptoms (N = 86)

Symptom	Number (%)
Urolithiasis	30 (34.9)
Bone pain	7 (8.1)
Lethargy	15 (17.4)
Peptic ulcer disease	10 (11.6)
Pancreatitis	3 (3.5)

Table 2. Location of parathyroid pathology*

<u>Right upper</u>	
Adenoma	18
Hyperplasia	13
<u>Right lower</u>	
Adenoma	13
Hyperplasia	12
<u>Left upper</u>	
Adenoma	25
Hyperplasia	11
<u>Left lower</u>	
Adenoma	12
Hyperplasia	14

* One patient had no parathyroid tissue found at neck exploration. One left-sided intrathyroidal adenoma could not be identified as upper or lower.

another patient had two hyperplastic glands which were located in the thymus in the anterior mediastinum and outside the field of view for the scanning camera. These patients were also included in the localization analysis. None of the patients with four gland hyperplasia had all four glands successfully localized. Two patients had three of four located. All patients with only one (3 patients) or two (1 patient) hyperplastic glands remaining in the neck had successful localizations.

The position and pathology of the excised parathyroid glands are shown (*Table 2*). Only 1 patient underwent neck exploration and had no parathyroid tissue found. This patient had an enlarged gland eventually located by CT in the anterior mediastinum.

The thyroid overlapped the abnormal parathyroid gland in 49 of 65 patients in which these data were available. Overlap did not interfere with localization. Four of five intrathyroidal

glands were successfully localized with the thallium-technetium scan. The false-positive rate was 35% (30/86 patients). Thyroid nodules were responsible for false-positive scans in 5 patients. Other causes for false-positive scans were not identified, although motion artifact during the long scanning period may be an important consideration.

Volumes were calculated from the pathology reports of the excised parathyroid glands. Parathyroid gland volume did not correlate with a positive scan. Localization by the thallium-technetium scan did not correlate statistically with parathyroid size.

Discussion

Many methods have been used to locate missing parathyroid tissue. Methylene blue,⁷ high resolution ultrasound and CT,^{8,9} digital subtraction angiography,¹⁰ selective venous catheterization with parathyroid hormone radioimmunoassay,^{2,9} and selective arteriography^{2,9} have been tried. Their main limitation is accuracy which, at very best, is limited to the range of 50% to 75%. Cost and invasiveness with complications can be added as drawbacks to the techniques requiring angiography. The accuracy of these tests may be even less if one considers only reoperative cases.¹¹

Reoperative parathyroid surgery is a challenge to even the most seasoned endocrine surgeon. Whether the previous surgery involved the thyroid or parathyroid glands, the scar tissue and distorted anatomy remain. It is the only situation in which we believe preoperative parathyroid localization should be done. The large majority of reoperative cases will have the missing gland in the neck as demonstrated by our experience and by Edis et al.² The hope of localization is to decrease the 18% morbidity,¹² increase the 72% success rate,² and decrease the operating time.

The accuracy of thallium-technetium parathyroid scanning varies from 88%¹³ for adenomas in previously unoperated cases to 52%¹⁴ for reoperative cases. Our success rate in reoperative situations was 86% (12/14 patients). The intensity of thallium uptake in the mediastinum limits the ability to locate mediastinal glands. We do not include the mediastinum in the field of view of the scanning camera. If a missing parathyroid gland is not located in the neck by thallium-technetium scanning, a CT of the chest, a digital subtraction angiogram of the neck and chest, or venous parathormone sampling is indicated. Pa-

tients must lie motionless through the injection and scanning of two tracers lasting 30 to 45 minutes and motion artifact is often a problem. False-positive scans were produced by five thyroid nodules and factors as yet unknown.

The total cost for a thallium-technetium parathyroid scan in our institution is \$152. The skilled endocrine surgeon, at most, fails to find the parathyroid pathology in 1 or 2 patients per 100. This means that 98 to 99 patients out of every 100 will be unnecessarily subjected to this study. By scanning reoperative cases only, a cost savings of \$15,000 could be realized which would more than offset the cost of reoperative surgery and hospitalization.

Conclusion

Thallium-technetium subtraction parathyroid scanning was employed in 86 patients. In 72 patients without previous neck exploration, 70% of the adenomas and 36% of the hyperplastic glands were successfully localized. Parathyroid gland volume and blood chemistries did not correlate statistically with positive scans. Twelve of 14 patients (86%) having reoperative neck surgery had successful localization. The extremely low rate of unsuccessful neck explorations for primary hyperparathyroidism makes thallium-technetium scanning unnecessary prior to the initial neck exploration. Their accuracy in reoperative cases, however, indicates that they should be the first localization test performed in these situations. Simultaneous injection and scanning of both thallium and technetium are currently being investigated. This will accelerate the procedure and reduce motion artifact. The quest continues for the perfect method to localize pathological parathyroid glands.

Thomas A. Broughan, M.D.
Department of Surgery
The Cleveland Clinic Foundation
9500 Euclid Ave.
Cleveland, OH 44106

References

1. Broughan TA, Jaroch MT, Esselstyn CB Jr. Parathyroid hormone assay: unreliable and overused. *Arch Surg* 1986; 121:841-842.

2. Edis AJ, Sheedy PF II, Behrns OH, van Heerden JA. Results of reoperation for hyperparathyroidism, with evaluation of preoperative localization studies. *Surgery* 1978; **84**:384-393.
3. MacFarlane SD, Hanelin LG, Taft DA, Ryan JA Jr, Fredlund PN. Localization of abnormal parathyroid glands using thallium-201. *Am J Surg* 1984; **148**:7-13.
4. Ferlin G, Borsato N, Camerani M, Conte N, Zotti D. New perspectives in localizing enlarged parathyroids by technetium-thallium subtraction scan. *J Nucl Med* 1983; **24**:438-441.
5. Fukunaga M, Morita R, Yonekura Y, et al. Accumulation of ²⁰¹Tl-chloride in a parathyroid adenoma. *Clin Nucl Med* 1979; **4**:229-230.
6. Young AE, Gaunt JI, Croft DN, Collins RE, Wells CP, Coakley AJ. Location of parathyroid adenomas by thallium-201 and technetium-99m subtraction scanning. *Br Med J* 1983; **286**:1384-1386.
7. Devine RM, van Heerden JA, Grant CS, Muir JJ. The role of methylene blue infusion in the management of persistent or recurrent hyperparathyroidism. *Surgery* 1983; **94**:916-918.
8. Stark DD, Gooding GAW, Moss AA, Clark OH, Ovenfors C-O. Parathyroid imaging: comparison of high-resolution CT and high-resolution sonography. *AJR* 1983; **141**:633-638.
9. Brennan MF, Doppman JL, Kurdy AG, Marx SJ, Spiegel AM, Aurbach GD. Assessment of techniques for preoperative parathyroid gland localization in patients undergoing reoperation for hyperparathyroidism. *Surgery* 1982; **91**:6-11.
10. Esselstyn CB Jr, Buonocore E. The use of digital subtraction angiography and computed tomography scanning in localization of parathyroid adenomas in secondary parathyroid operations: preliminary observations. *Surgery* 1983; **94**:869-872.
11. Clark OH, Okerlund MD, Moss AA, et al. Localization studies in patients with persistent or recurrent hyperparathyroidism. *Surgery* 1985; **98**:1083-1094.
12. Wang C. Parathyroid reexploration. A clinical and pathological study of 112 cases. *Ann Surg* 1977; **186**:140-145.
13. Okerlund MD, Sheldon K, Corpuz S, et al. A new method with high sensitivity and specificity for localization of abnormal parathyroid glands. *Ann Surg* 1984; **200**:381-388.
14. Skibber JM, Reynolds JC, Spiegel AM, et al. Computerized technetium/thallium scans and parathyroid reoperation. *Surgery* 1985; **98**:1077-1082.