

# ACHOO syndrome

## Prevalence and inheritance<sup>1</sup>

Harold H. Morris III, M.D.

In a questionnaire, four of 20 (20%) neurologists indicated they had a photic sneeze reflex. Two kindreds are presented that demonstrate the reflex is inherited in an autosomal dominant mode, but with variable expressivity manifested by sneezing after eyebrow plucking and/or hair pulling. The reflex may result from stimulation of the trigeminal nerve.

**Index term:** Sneezing

**Cleve Clin J Med** 54:431-433, Sep/Oct 1987

The symptom of sneezing on exposure to bright light has been previously reported in the medical literature,<sup>1-9</sup> but evidently, little attention has been paid to these reports because most physicians are ignorant of the condition. Ophthalmologists are probably most aware because of sneezing provoked by ophthalmoscopy<sup>1</sup> or the slit-lamp examination.<sup>2</sup> Standard texts<sup>1,3,4</sup> only briefly mention the "photic sneeze reflex." In this study, two kindreds with the reflex are presented along with the prevalence of photic sneezing in a group of neurologists.

### Case reports

**Case 1.** A 43-year-old male neurologist presented with the complaint of sneezing when moving suddenly from a dark to a bright environment. The symptom had been present for as long as he could remember. Characteristically,

he would sneeze one to three times several seconds after bright light exposure. No other unusual occurrences provoked sneezing. The phenomenon could be prevented by wearing dark glasses. There was no history of vasomotor rhinitis or allergy. One of three sisters sneezed on light exposure. Also, one daughter from a previous marriage and his only child of a second marriage sneezed on exposure to bright light. The symptom was noted at an age of <1 month in his youngest daughter (*Fig. 1*). One child and one sister sneezed with hair pulling or eyebrow plucking, but not with bright light exposure.

**Case 2.** A 31-year-old female neurologist noted the symptom of sneezing immediately following light exposure. She also would sneeze usually three times immediately following exposure to bright light. Her father and her only sibling (a sister) also had the same symptom. Her sister's only child, an infant female, also sneezed on exposure to bright light (*Fig. 2*).

**NOTE:** The first patient (Case 1) diagnosed the second patient's (Case 2's) problem when they walked out the door together into bright sunlight.

### Methods and Results

To study the prevalence of the photic sneeze reflex, a written questionnaire was distributed at a random Neurology Grand Rounds. Four of 20 neurologists who responded (20%) indicated they exhibited the photic sneeze reflex and two claimed that the reflex was present in other family members (*Table*).

### Discussion

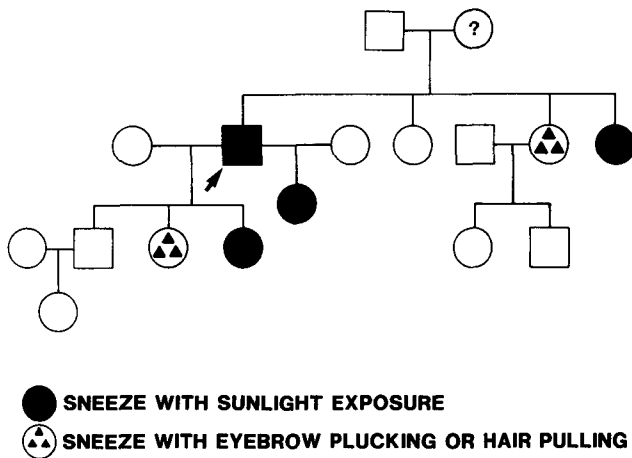
Everett<sup>5</sup> gave the first major review of the photic sneeze reflex in 1964. He reported a prevalence of 33% in male psychiatry residents,

<sup>1</sup> Department of Neurology, The Cleveland Clinic Foundation. Submitted for publication Feb 1987; accepted May 1987.

0891-1150/87/05/0431/03/\$1.75/0

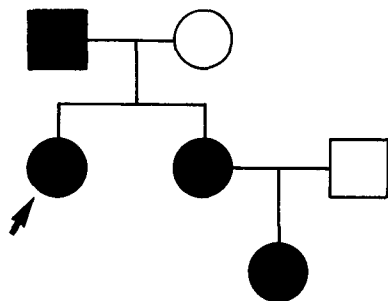
Copyright © 1987, The Cleveland Clinic Foundation

**CASE 1**



**Fig. 1.** The proband (arrow) has two daughters (by different marriages) with the photic sneeze reflex. A third daughter and one of his sisters sneeze with hair pulling or eyebrow plucking. Another of his sisters also has the reflex. It is unclear whether the proband's mother was a photic sneezer, but she was an "easy sneezer."

**CASE 2**



**● SNEEZE WITH SUNLIGHT EXPOSURE**

**Table.** Prevalence of the photic sneeze reflex in selected Cleveland neurologists

Sex	Number	Photic sneeze reflex	Positive family history
Male	15	2	1
Female	5	2	1

28% in male medical students, and 16% in female medical students. In black college-students, the prevalence was only 2% in either sex. There was a definite tendency for the reflex to be present within family members of those affected, but it did not correlate with hay fever or other allergies. Everett believed that the photic sneeze reflex was due to either "optic trigeminal summation" ("stimulating one of these cranial nerves enhances the irritability of the other") or "parasympathetic generalization" ("generalized enhancement of the parasympathetic system secondary to stimulation of parts of the system"). Collie et al<sup>6</sup> suggested an autosomal dominant mode of inheritance or, as they coined it, the ACHOO (Autosomal dominant Compelling Helio-Ophthalmic Outburst) syndrome. They also commented on the benign nature of the reflex and the absence of known sneeze complications such as vaginal tears, conductive hearing loss, or mediastinal hemorrhage. Fortunately, the kindreds in this current study are also free of these complications.

Beckman and Nordenson<sup>7</sup> found a 24% prevalence of the "sneezer trait" in the Swedish population and reaffirmed the view that it was inherited in the autosomal dominant mode. They speculated that "the proximity of certain nuclei in the medulla oblongata in some individuals may cause visual stimuli to interfere with the sneezing reflex." They also wondered if the photic sneeze reflex might not be of selective advantage in certain situations. (For example, to be a "good sneezer" in an arctic population with frequent exposures to respiratory infectious agents would be beneficial.) Forrester<sup>8</sup> reported a 25% prevalence of the photic sneeze reflex in the English population and the data supported an autosomal dominant means of transmission. He found the latency of the response to be 2.5 to 15 seconds and suggested the mechanism might be increased tearing secondary to bright light followed by stimulation of the nasal mucosa by tears through the lacrimal duct. The finding of a prevalence of 20% in the present study is in agreement with reports from Sweden and England,<sup>7,8</sup> but is lower than the 36% found among Baltimore neurologists.<sup>9</sup>

The phenomenon is probably not due to reflex activity mediated by pregeniculate branches from the optic nerve to the brainstem tectal region because of the long latency. More likely, the reflex is secondary to stimulation of the trigeminal nerve by indirect means such as lacrimation

or squinting. Light activation of the corneal branches of the first division of the trigeminal nerve is a less likely explanation. The hypothesis of trigeminal stimulation is also supported by the observation that hair pulling or eyebrow plucking may also provide sneezing in individuals within the kindred exhibiting the photic sneeze reflex.

Although there is no cure for the affliction, symptomatic relief is possible by wearing dark glasses.

### References

1. Moses RA. The eyelids. [In] Moses RA, ed. *Adlers Physiology of the Eye*. St. Louis, Mosby, 1981, pp 1-15.
2. Lewkonia I. An infrequent response to slit-lamp examination. *Br J Ophthalmology* 1969; **53**:493-495.
3. Walsh FB, Hoyt WF. Sensory innervation of the eye and orbit: trigeminal nerve, facial pain, and headache. [In] *Clinical Neuroophthalmology*. Baltimore, Williams & Wilkins, 1969, pp 350-433.
4. DeJong RN. *The Neurologic Examination*. Hagerstown, Md., Harper & Row, 1979, p 172.
5. Everett HC. Sneezing in response to light. *Neurology* 1964; **14**:483-490.
6. Collie WR, Pagon RA, Hall JG, Shokeir MHK. ACHOO syndrome (autosomal dominant compelling helio-ophthalmic outburst syndrome). *Birth Defects* 1978; **14**:361-363.
7. Beckman L, Nordenson I. Individual differences with respect to the sneezing reflex: an inherited physiological trait in man? *Hum Hered* 1983; **33**:390-391.
8. Forrester JM. Sneezing on exposure to bright light as an inherited response. *Hum Hered* 1985; **35**:113-114.
9. Peroutka SJ, Peroutka LA. Autosomal dominant transmission of the "photic sneeze reflex" (letter). *New Engl J Med* 1984; **310**:599-600.

Department of Neurology  
The Cleveland Clinic Foundation  
9500 Euclid Avenue  
Cleveland, OH 44106