

Nonalcoholic fatty liver

Structural and clinical implications

R. Thomas Holzbach, MD

Nonalcoholic fatty liver is a frequently encountered clinical entity. It may be found as an apparently spontaneous phenomenon having no discernible cause or significance, or it may be iatrogenically induced. Advanced forms of fatty liver can lead to liver cell necrosis and ultimately to severe cirrhosis. In addition to the more common forms of fatty liver, a less frequent and morphologically distinct subcategory, microvesicular fatty liver, can be identified in certain clinical settings. This disease is generally more acute and potentially more reversible, but the prognosis is more ominous if it is not quickly recognized and appropriately treated.

Index terms: Liver, diseases • Liver, fatty

Cleve Clin J Med 1988; 55:136–144

Fatty liver is most commonly identified by either detection of hepatomegaly or unexplained abnormal liver function tests. A liver biopsy specimen will show a prominent degree of fat accumulation in the hepatocytes, and there will be (with few exceptions) coexisting cell necrosis with some degree of inflammatory response. The degree to which the latter lesions coexist with steatosis varies with clinical circumstances and etiological factors, but this combination has led to the preferred and common designation of the hepatic steatosis lesion as *steatonecrosis*. Several questions then arise when this condition is found: What is the underlying problem accounting for the fat accumulation? What are the potential complications? What treatment, if any, is indicated?

The classical steatonecrosis lesion is most commonly

Department of Gastroenterology, The Cleveland Clinic Foundation. Submitted for publication April 1987; accepted July 1987.

Table 1. Disease processes associated with nonalcohol-related classical hepatic steatosis (steatonecrosis)

Clinical Setting	Associated Condition
Spontaneously occurring processes	Normal variant, miscellaneous etiologies ^{5,6} Obesity ⁷⁻⁹ Hyperlipoproteinemias Diabetes mellitus ⁹⁻¹³ Nutritional ^{14,15}
Iatrogenically induced	Intestinal bypass surgery ¹⁶⁻²² Drug administration ²³ Methotrexate ²⁴ Perihexiline maleate ²⁵

Table 2. Abnormal hepatic histologic findings in diabetes mellitus

Abnormality	Frequency
Glycogen—infiltration of the nucleus	50% (20–80%)
Steatosis (as solitary abnormality)	50% (30–75%)
Steatonecrosis	?
Cirrhosis—micronodular (various stages)	15% (1–30%)

Table 3. Disease processes associated with microvesicular hepatic steatosis

Clinical Setting	Associated Condition
Spontaneously occurring process	Acute fatty liver of pregnancy ²⁶⁻³⁷ Reye syndrome ³⁸⁻⁴⁰ Vomiting disease of Jamaica
Iatrogenically induced	Drug administration Valproic acid ⁴¹⁻⁴⁵ Tetracycline ²⁸

associated with alcoholism. Indeed, this lesion is considered a phase in the pathway of two serious alcohol-related lesions, acute alcoholic hepatitis and chronic liver cirrhosis. Intracellular eosinophilic inclusions of Mallory and granulocytic infiltrates are frequently associated with this histologic pattern.¹⁻³ In the more chronic lesions, a combination of necrosis and inflammation leads to fibrosis. This may serve to connect central veins to portal triads, providing the structural configuration for eventual micronodular cirrhosis. The same evolutionary events may also produce a similar lesion that occurs in several metabolic disorders *without* significant alcohol exposure.⁴ This paper will review the clinical features

of the classical steatonecrosis lesion characteristic of these less common, nonalcohol-related metabolic disorders (*Table 1*).

One of these abnormal states is an ill-defined condition that can be designated “normal-variant” steatosis. Also included is the steatosis associated with obesity and with certain hyperlipoproteinemic states; the two are often interrelated. In diabetes mellitus, steatonecrosis is also often present, and may in turn be related to obesity and/or hyperlipoproteinemia. A striking form of steatonecrosis may occur following intestinal bypass surgery for morbid obesity, and a similar lesion occurs in susceptible individuals in association with certain drugs.

Lastly, a highly interesting, albeit far less common, form of hepatic steatosis displays a unique microvesicular form of lipid distribution within hepatocytes. In the more common intracellular globular lipid deposition, single, large coalesced lipid inclusions are observed in such abundance that fatty “cysts” are said to be present. This latter type of lesion often displaces hepatocytic organelles into a ring-like peripheral distribution near the plasma membrane.³ In the microvesicular form of hepatic steatosis, this aggregation of lipid never seems to occur, and there is no dramatic organelle displacement. The clinical problems associated with microvesicular lesions tend to be both more acute and more severe than with the more typical steatonecrotic lesions. Among diseases in this group are acute fatty liver of pregnancy, Reye syndrome, and recently identified forms of drug toxicity, most notably that associated with valproic acid administration in susceptible patients.

Classical hepatic steatosis

Spontaneous

Normal variant hepatic steatosis: Two recently published necropsy studies of relatively young (ages 18–58 years; mean age 29) and “healthy” male adults after accidental death found an incidence of histologically “abnormal” fatty liver of about 15–20%.^{5,6} All of the subjects included in the study were gainfully employed and there was no reason to believe that selection bias had affected the observations. In those affected, the degree of fatty infiltration was of more than moderate severity in only 3%, and about half had coexisting histopathology consistent with steatonecrosis.⁶ This study is not easy to interpret since there is no way to know to what degree the

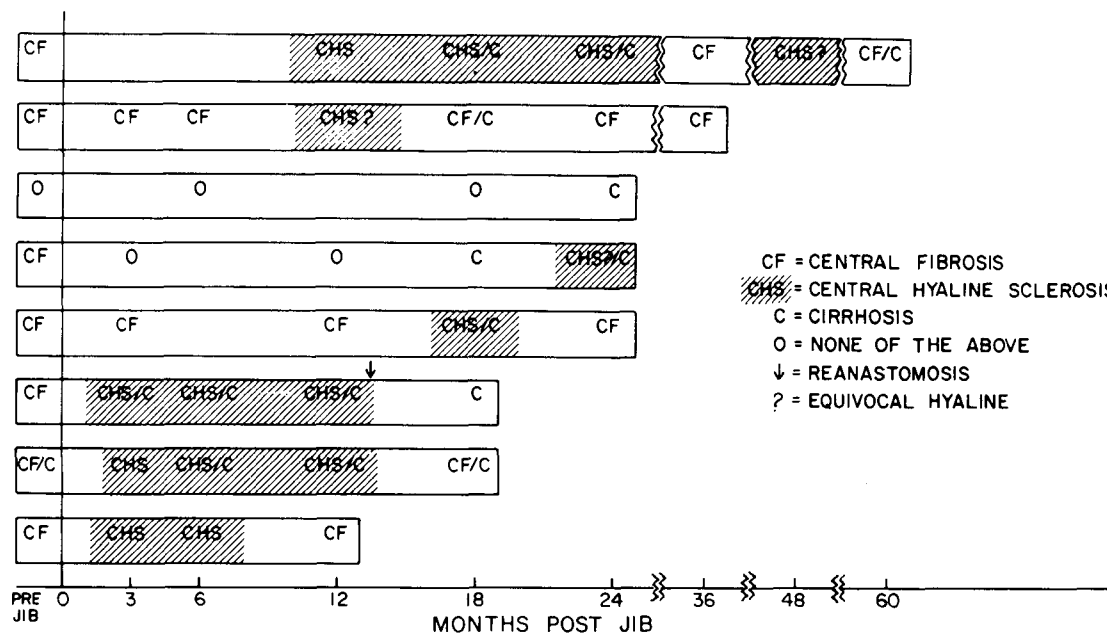


Fig. 1. Evolution of steatonecrosis and cirrhosis in eight patients following early steatosis associated with jejunoileal bypass (JIB) surgery for morbid obesity. Reprinted from Haines et al²⁰ with permission.

population could have been previously exposed to alcohol, drugs, or other environmental hepatotoxins. Nevertheless, the findings provide perspective for other similar studies.

Obesity: Fatty infiltration of the liver has been described in up to 90% of patients with marked obesity (>75% above ideal body weight) before surgery. In most patients the quantity of fat is small, but occasionally virtually every hepatocyte may be involved. No clear correlation has been found between the degree of obesity and quantity of fat in the liver. In the majority of patients, the fat is distributed at random throughout the hepatic lobules, but in up to a third the distribution is primarily pericentral. The exact pathogenesis of this fatty infiltration is uncertain.⁷⁻⁹

A nonspecific triaditis is also present in most markedly obese patients. However, bile duct number and morphology are normal. The mild inflammatory infiltrate is composed largely of lymphocytes, and the limiting plate is intact. The cause of the portal lesion is unknown.⁸ Standard liver function tests are normal in most patients.

Diabetes mellitus: Even in the absence of recognizable pathogenetic risk factors, liver disease, and in particular fatty liver, has been considered common in patients with diabetes mellitus (Table 2).¹⁰⁻¹³ Large-droplet hepatic steatosis has been reported in 30-75% of diabetics; about 50% have elevated serum levels of one or more of the

standard substances (aminotransferases, alkaline phosphatase, and γ -glutamyl transpeptidase) that reflect liver injury. Moreover, tests of hepatic function, such as BSP and ICG clearances and serum bilirubin level, are abnormal in approximately 80% of diabetics with fatty liver. Even in the absence of histologic demonstration of fatty liver, glycogen infiltration of hepatocyte cytoplasm and nuclei is common in diabetics. This finding has been reported to occur in about 50% of all diabetics.¹⁰⁻¹³

Despite these earlier correlative necropsy studies, observations regarding liver histology in diabetes must be interpreted with considerable caution. A recent carefully executed study⁹ attempted to disentangle the confounding factors. The most clearly observable correlation was with obesity, which is notoriously common in the adult-onset diabetic patient. In its absence, no correlation could be discerned between fatty changes in the liver and the presence of diabetes mellitus.

Iatrogenic

Intestinal bypass surgery: Jejunoileal bypass was the initial surgical treatment for refractory morbid obesity, but, as early as 1967, liver complications and sometimes failure were recognized as major complications. Subsequently, jejunoileal bypass, which had been previously investigated

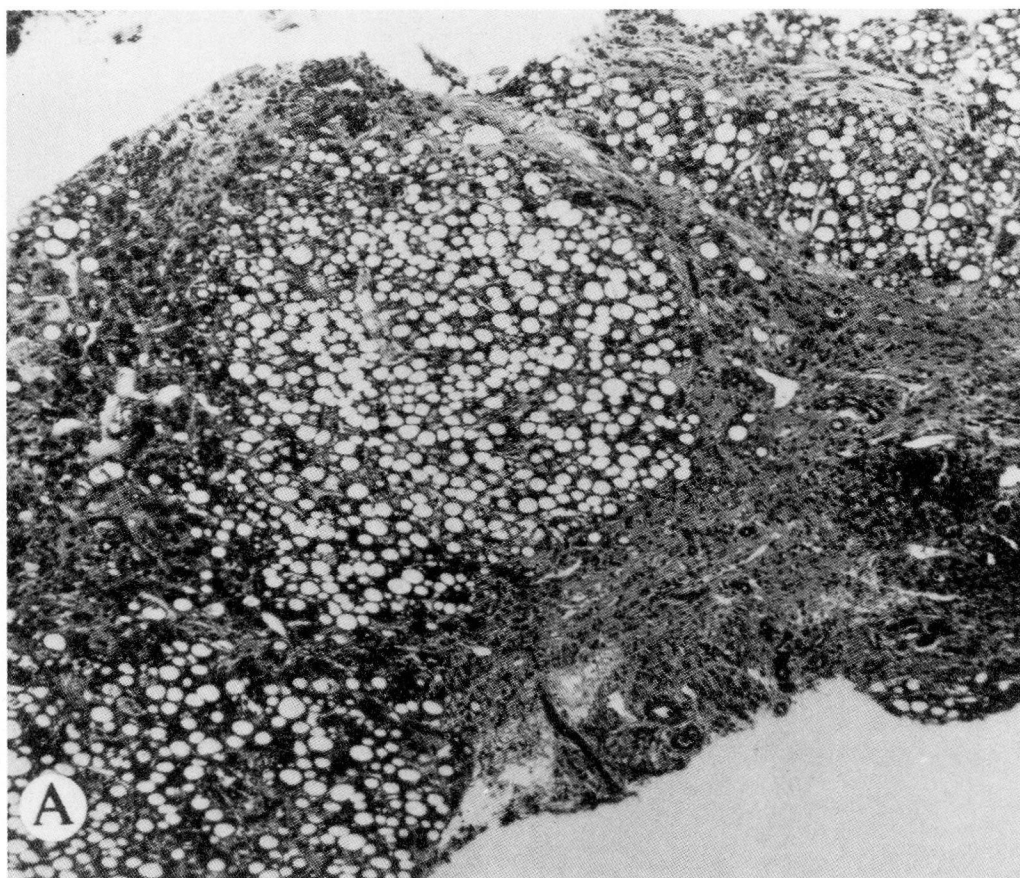


Fig. 2. A. Photomicrograph at low magnification of a percutaneous liver biopsy specimen obtained 12 months following intestinal bypass, demonstrating a combination of steatonecrosis and early cirrhosis in an asymptomatic patient with only slight biochemical liver function abnormalities.

in animals, was applied to patients. A longer absorptive surface and the ileocecal valve were left intact, in the expectation that hepatic failure would not occur. Experience over the past 20 years indicates that approximately 2% of patients undergoing jejunioileal bypass die of complications attributable to the procedure, and the major cause of the mortality is liver failure (*Fig. 1*).¹⁶⁻²² Almost all of these patients have been found to have histopathologic evidence of steatonecrosis (*Fig. 2*).¹⁸ Hepatic lipid accumulation is markedly increased in these patients subsequent to surgery (*Fig. 3*).¹⁷

The role of a specific nutritional deficiency remains unestablished. Studies following jejunioileal bypass have demonstrated an amino acid pattern that resembles kwashiorkor, suggesting that protein-calorie malnutrition may be important. However, this abnormality is also seen in patients with fatty infiltration of the liver alone,

as well as in patients with steatonecrosis. Numerous vitamin and trace-metal deficiencies, including folate, vitamin C, vitamin D, zinc, and copper, have been described in patients after intestinal bypass, but deficiencies of these nutrients do not produce steatonecrosis.

Drug administration: The typical drug-induced hepatotoxic lesions fall into the categories of either "cholestatic" lesions or "hepatic" (necrosis-inducing) lesions. The latter are often associated with variable degrees of steatosis or steatonecrosis. Drugs commonly associated with this category of lesion include isoniazid, diphenylhydantoin, phenylbutazone, and methyldopa.²³ Only rarely have drugs been reported to cause the classical steatotic lesion in the absence of extensive necrosis and inflammatory response. One well-known example of this, however, is the early-stage lesion associated with chronic methotrexate administration.²⁴ Since this agent is a

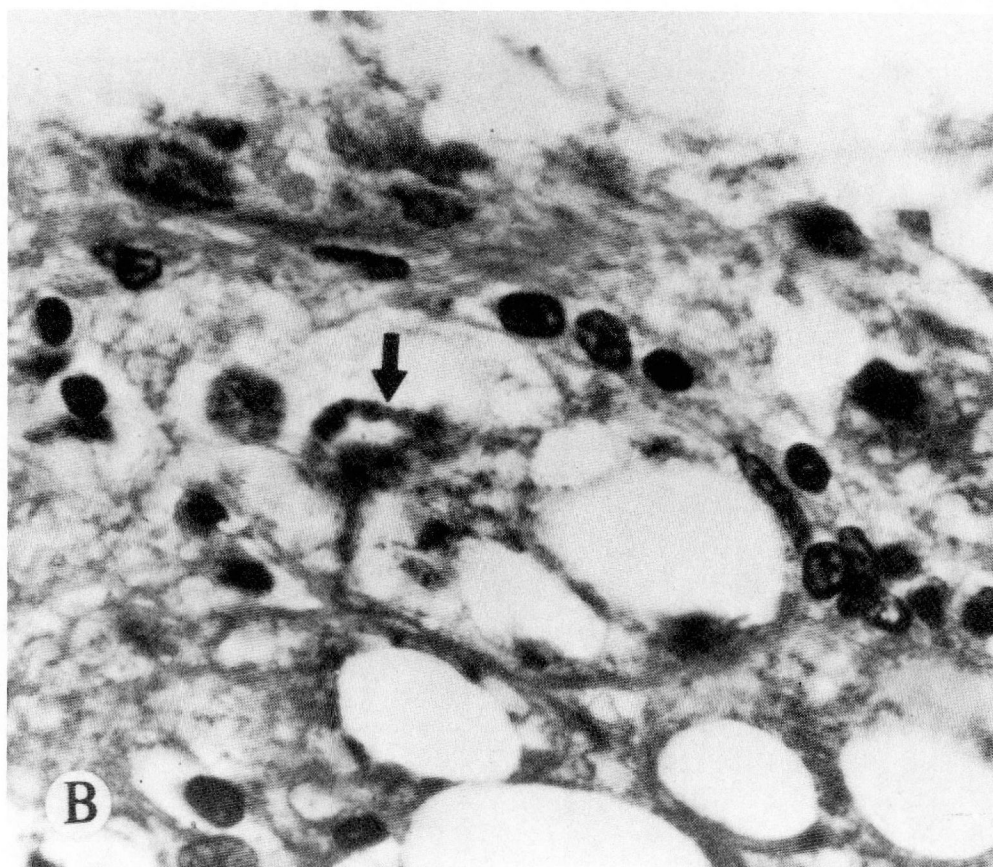


Fig. 2. B. Photomicrograph at higher magnification of same biopsy specimen, demonstrating presence of a typical Mallory body (black arrow). Reprinted from Haines et al²⁰ with permission.

known folic acid antagonist, one view is that the associated steatosis is at least partly mediated through induced nutritional deficiency.

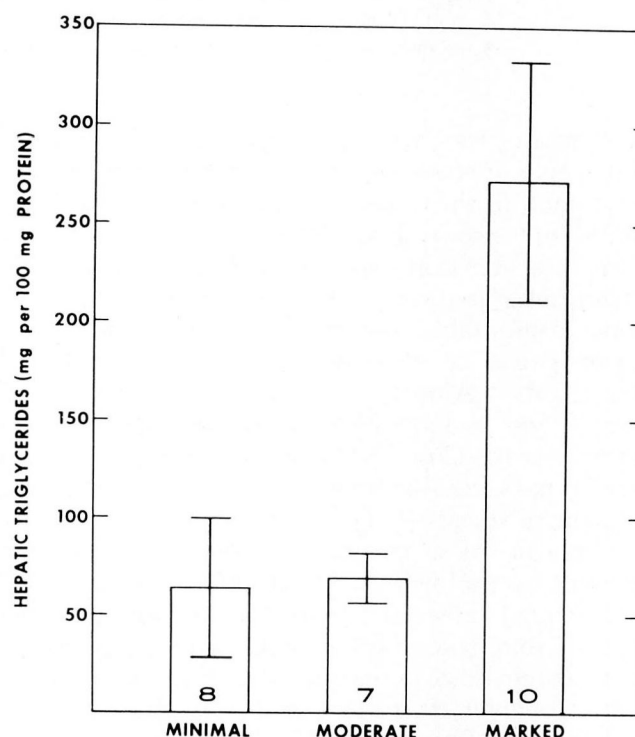
Microvesicular hepatic steatosis (Table 3)

Spontaneous

Acute fatty liver of pregnancy: There have been several confusing and misleading misconceptions concerning acute fatty liver of pregnancy (AFLP). First, AFLP has been artificially separated or excluded from a “wastebasket” group of pregnancy syndromes variously termed eclampsia or toxemia. Arbitrary definitions state that renal manifestations, including hypertension, are requisite and exclusive hallmarks of toxemia. This had led to the common practice of categorizing

→

Fig. 3. Mean hepatic triglycerides (\pm SEM) from intraoperative and postoperative biopsy tissue following jejunioileal bypass surgery for morbid obesity. Number of patients in each group is indicated at the base of the histogram. Reprinted from Holzbach et al¹⁷ with permission.



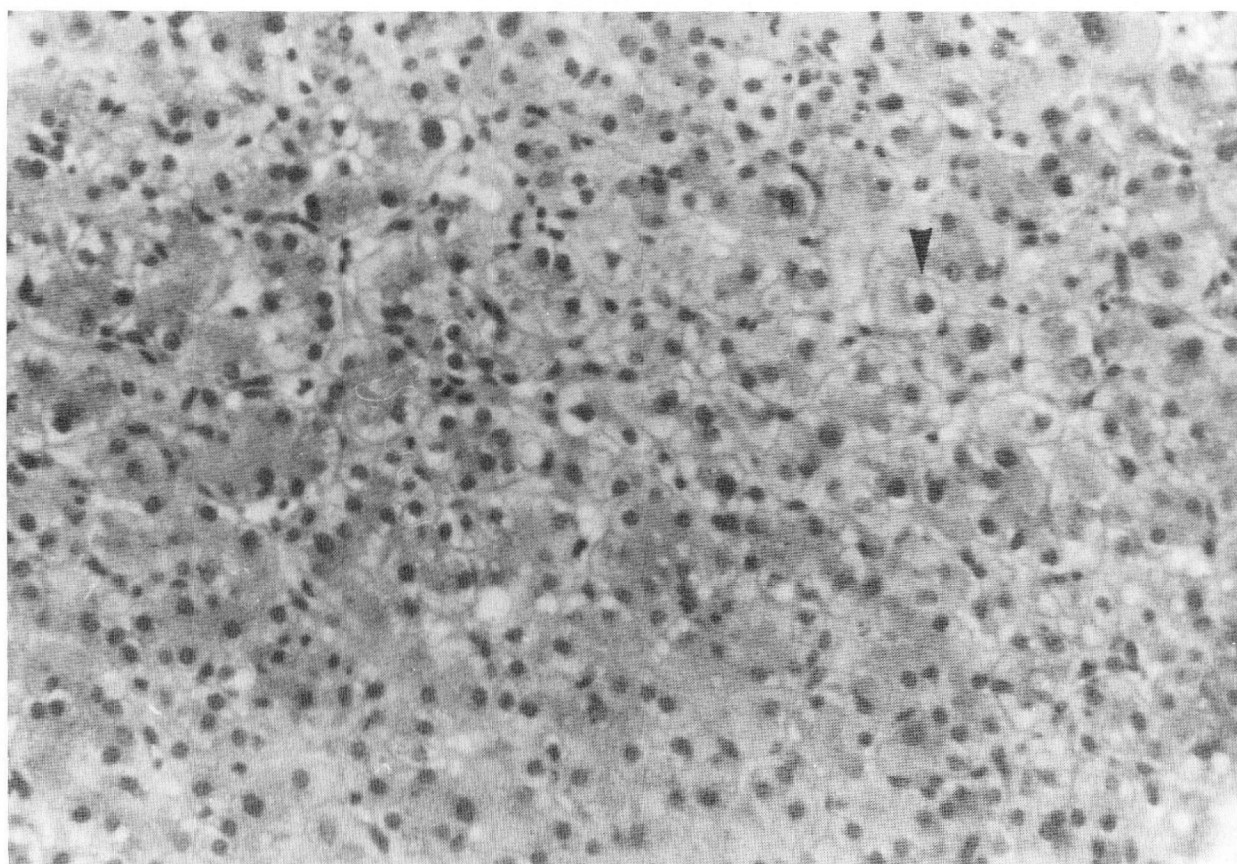


Fig. 4. A. Percutaneous liver biopsy specimen from patient with acute fatty liver of pregnancy (AFLP) at low magnification, showing multiple discrete intracytoplasmic vacuoles of nearly uniform size with preservation of almost normal lobular structure but obscuring anatomic relationships, i.e., portal triad vs. central venule.

almost all middle to late gestational multiorgan disorders as “toxemic” states. It is now increasingly accepted that many of these clinical syndromes of unknown etiology can more accurately and appropriately be considered part of the clinical spectrum of AFLP. Second, confusion has also arisen in the past decade from recognition of a disseminated intravascular coagulation (DIC) disorder that commonly complicates AFLP, leading to serious multiorgan manifestations. Third, AFLP until only recently has been mistakenly considered an entirely unique diagnostic entity, separate from the toxemias. Thus regarded, the view of AFLP has been one of both rare occurrence and high fatality. Recent reports indicate, however, that AFLP is neither rare nor usually fatal.²⁶ Rather, these patients may survive their hepatic complications; in severe cases they may succumb to complications related to some other organ system such as the kidneys or pancreas, or to uncontrolled gastrointestinal hemorrhage.²⁷

In AFLP, the liver histology is typical of microvesicular fatty infiltration (*Fig. 4*) and not morphologically distinguishable from that seen in Reye syndrome or following administration of oral valproic acid or intravenous tetracycline.^{28–30} The findings of one study indicate that in AFLP the increased hepatic lipids consist primarily of free fatty acids.³¹ This observation stands in striking contrast to findings in nutritional and alcoholic fatty liver. In the latter, triglyceride accumulation alone constitutes the biochemical lesion. This provocative observation about hepatic lipids in AFLP was made almost a decade ago, but remains to be confirmed or refuted. *Table 4* summarizes the dominant clinical features of the AFLP syndrome from two recent, comparatively large studies.^{32,33} While the entire spectrum of the clinical syndrome cannot be described here, at present it is clearly more frequently recognized at earlier stages. Abrupt termination of the pregnancy is the only appropriate

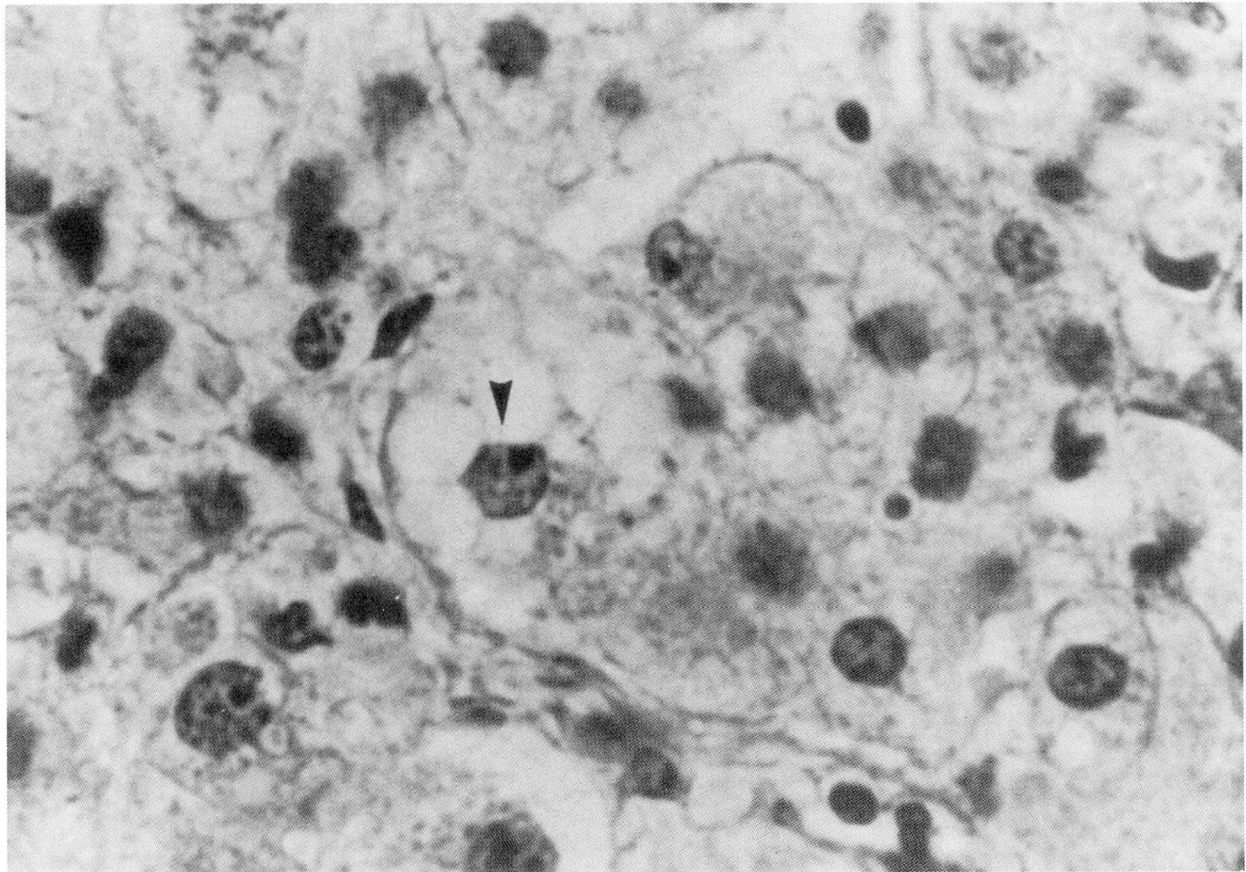


Fig. 4. B. View of same specimen as **A** at higher magnification, demonstrating the hepatocyte vacuolization pattern of AFLP that is also typical of other forms of microvesicular forms of steatosis; note normal appearance and pericentral localization of cell nucleus. Reprinted from Holzbach²⁹ with permission.

therapy for the more severe form of the AFLP syndrome. Since the syndrome has become better diagnosed and treated, its earlier reputation for having a high fatality rate has become drastically, favorably altered.³⁴⁻³⁷

Reye syndrome: Like AFLP, Reye syndrome also has had a reputation for a high fatality rate; however, earlier and more frequent diagnosis in mild cases has been associated with a more favorable outcome. Although the disorder is clearly not of recent vintage, it was accurately described for the first time only 20 years ago.³⁸ In severe cases, the patient, typically a child under 18 years of age (mean age of occurrence: 6 years), is recovering from an apparent viral illness when vomiting begins. The vomiting is protracted. In severe cases (above grade 1), lethargy, disorientation, and eventually coma with decerebrate and decorticate rigidity ensue. At any stage, the symptoms may recede and the child may return to

normal or may progress to a marked increase in intracranial pressure, brain stem herniation, and brain death. Deaths occur due to marked neurological impairment rather than to liver failure, although significant alteration of liver function almost invariably occurs. The liver enlarges moderately during the vomiting phase of the disease but is not tender. The child is not jaundiced.

A number of laboratory findings are abnormal. Serum aminotransferases (SGOT and SGPT) are elevated, often to very significant degrees. Serum creatine, phosphokinase, and lactic dehydrogenase levels are all elevated. The blood ammonia level is elevated in severe cases, and correlates with outcome.³⁹ The levels of blood ammonia found in this condition are comparable to those seen in patients with congenital urea-cycle enzyme deficiencies. Plasma free fatty acids are significantly increased, as is the serum uric acid level. Hypoprothrombinemia is present but with-

Table 4. Acute fatty liver of pregnancy complication rate

	No. Cases	No. Cases with Hypertension or Proteinuria	No. Cases with Thrombocytopenia	Maternal Deaths	Fetal Deaths
Burroughs et al ³²	12	11	12	4	8
Davies et al ³³	6	5	3	1	4
TOTAL	18	16 (89%)	15 (83%)	5 (28%)	12 (67%)

out evidence of disseminated intravascular coagulation.

Histologically, the hepatic lesion demonstrates uniform microvesicular fat distribution in each hepatocyte. The primary ultrastructural organelle abnormality seen with electron microscopy is mitochondrial.⁴⁰ There is a combination of progressive swelling of the mitochondria, pleomorphism, decrease in mitochondrial matrix density, loss of the matrix dense body, and occasionally outer membrane rupture. Glycogen depletion occurs irregularly from cell to cell.

Iatrogenic

Typical microvesicular hepatic steatotic lesions have been described in connection with intravenous administration of tetracycline, particularly in association with therapy for AFLP,²⁸ and more recently with chronic oral valproic acid therapy for epilepsy. Few fatalities have been reported, although significant abnormalities in liver function tests have been observed. The histologic

lesions and abnormalities in liver function tests usually revert to normal following withdrawal of the drug. The mechanism of the toxic effect with those drugs is not clear in all instances.

Vomiting disease of Jamaica is a rare but often fatal malady featuring a microvesicular form of steatosis similar to the other diseases in this category; the culpable agent in this disease is considered to be a toxic metabolite of hypoglycin A derived from an indigenous fruit (Ackee apples).²³ In valproate hepatotoxicity, current evidence suggests that a similar toxic metabolite is at work, in this case derived from an oxidative product of the parent compound (valproate) in susceptible individuals.⁴¹⁻⁴⁵ A summary of the various disease processes and common clinical manifestations of the heterogeneous group of conditions associated with the microvesicular form of hepatic steatosis (steatonecrosis) is provided in *Table 5*.

Table 5. Microvesicular hepatic steatosis: associated disease processes and manifestations

Disease processes
Acute fatty liver of pregnancy
Reye syndrome
Vomiting disease of Jamaica
Sodium valproate toxicity
Congenital defects of urea cycle enzymes
Clinical manifestations (variably present)
Vomiting
Variable jaundice
Coma
Disseminated intravascular coagulation
Renal failure
Raised blood ammonia levels
Hypoglycemia
Raised serum fatty acids
Liver biopsy
microvesicular fat
necrosis and cellular infiltration not prominent
Electron microscopy
mitochondrial abnormalities

Adapted from Sherlock.⁴⁶

R. Thomas Holzbach, M.D.
Department of Gastroenterology
The Cleveland Clinic Foundation
9500 Euclid Avenue
Cleveland, Ohio 44106

References

1. Harinasuta V, Chomet B, Ishak K, Zimmerman HJ. Steatonecrosis—Mallory body type. *Medicine* 1967; **46**:141-162.
2. Thaler H. Relation of steatosis to cirrhosis. *Clinics in Gastroenterology* 1975; **4**:273-280.
3. Hoyumpa AM, Greene HL, Dunn GK, Schenker S. Fatty liver: Biochemical and clinical considerations. *Dig Dis Sci* 1975; **20**:1142-1170.
4. Ludwig J, Viggiano TR, McGill DB, Ott BJ. Nonalcoholic steatohepatitis: Mayo Clinic experience with a hitherto unnamed disease. *Mayo Clin Proc* 1980; **55**:434-438.
5. Underwood Ground KE. Liver pathology in aircrew. *Aviat Space Environ Med* 1982; **53**:14-18.
6. Underwood Ground KE. Prevalence of fatty liver in healthy male adults accidentally killed. *Aviat Space Environ Med* 1984; **55**:59-61.

7. Galambos JT, Willis CE. Relationship between 505 paired liver tests and biopsies in 242 obese patients. *Gastroenterology* 1978; **74**:1191-1195.
8. Adler R, Schaffner F. Fatty liver hepatitis and cirrhosis in obese patients. *Am J Med* 1979; **67**:811-816.
9. Hornbøll P, Olsen TS. Fatty changes in the liver. The relation to age, overweight and diabetes mellitus. *Acta Path Microbiol Immunol Scand* 1982; **A 90**:199-205.
10. Zimmerman HJ, MacMurray FG, Rappaport H, Alpert LK. Studies of the liver in diabetes mellitus. I. Structural and functional abnormalities. *J Lab Clin Med* 1950; **36**:912-921.
11. Cruetefeld W, Frerichs H, Sickinger K. Liver diseases and diabetes. [In] Popper H, Schaffner F, eds. *Progress in Liver Diseases*. Vol. 3. New York, Grune and Stratton, 1970, pp 371-407.
12. Foster KJ, Griffith AH, Dewbury K, Price CP, Wright R. Liver disease in patients with diabetes mellitus. *Postgrad Med J* 1980; **56**:767-772.
13. Falchuk KR, Fiske SC, Haggitt RC, Federman M, Trey C. Pericentral hepatic fibrosis and intracellular hyaline in diabetes mellitus. *Gastroenterology* 1980; **78**:535-541.
14. Cook GC, Hutt MSR. The liver after kwashiorkor. *Br Med J* 1967; **3**:454-457.
15. Capron JP, Delamarre J, Dupas J-L, Braillon A, Degott C, Quenum C. Fasting in obesity: Another cause of liver injury with alcoholic hyaline? *Dig Dis Sci* 1982; **27**:265-268.
16. Drenick EJ, Simmons F, Murphy JF. Effect on hepatic morphology of treatment of obesity by fasting, reducing diets, and small bowel bypass. *N Engl J Med* 1970; **282**:829-834.
17. Holzbach RT, Wieland RG, Lieber CS, DeCarli LM, Koepke KR, Green SG. Hepatic lipid in morbid obesity: Assessment at and subsequent to jejunoileal bypass. *N Engl J Med* 1974; **290**:296-299.
18. Peters RL. Hepatic morphologic changes after jejunoileal bypass. [In] Popper H, Schaffner F, eds. *Progress in Liver Diseases*. Vol. 6. New York, Grune and Stratton, 1979, pp 581-594.
19. Craig RM, Neumann T, Jeejeebhoy KN, Yokoo H. Severe hepatocellular reaction resembling alcoholic hepatitis with cirrhosis after massive small bowel resection and prolonged total parenteral nutrition. *Gastroenterology* 1980; **79**:131-137.
20. Haines NW, Baker AL, Boyer JL, et al. Prognostic indicators of hepatic injury following jejunoileal bypass performed for refractory obesity. *Hepatology* 1981; **1**:161-167.
21. Drenick EJ, Fidler J, Johnson D. Hepatic steatosis after intestinal bypass—prevention and reversal by metronidazole, irrespective of protein-calorie malnutrition. *Gastroenterology* 1982; **82**:535-548.
22. Adibi SA, Stanko RT. Perspectives on gastrointestinal surgery for treatment of morbid obesity: The lesson learned. *Gastroenterology* 1984; **87**:1381-1391.
23. Zimmerman HJ. Drug-induced liver disease. [In] *Hepatotoxicity: The Adverse Effects of Drugs and Other Chemicals on the Liver*. New York, Appleton Century Crofts, 1978, pp 349-369.
24. Dahl MG, Gregory MM, Scheuer PJ. Liver damage due to methotrexate in patients with psoriasis. *Br Med J* 1971; **1**:625-630.
25. Pessayre D, Bichara M, Feldman G, Degott, Potet F, Benhamou J-P. Perhexiline maleate-induced cirrhosis. *Gastroenterology* 1979; **76**:170-177.
26. Pockros PJ, Peters RL, Reynolds TF. Idiopathic fatty liver of pregnancy: Findings in ten cases. *Medicine* 1984; **63**:1-11.
27. Holzbach RT. Jaundice in pregnancy—1976. *Am J Med* 1976; **61**:367-376.
28. Kunelis CT, Peters RL, Edmondson HA. Fatty liver of pregnancy and its relationship to tetracycline therapy. *Am J Med* 1965; **38**:359-377.
29. Holzbach RT. Acute fatty liver of pregnancy with disseminated intravascular coagulation. *Obstetrics-Gynecology* 1974; **43**:740-744.
30. Weber FL Jr., Snodgrass PJ, Powell DE, Rao P, Huffman SL, Brady PG. Abnormalities of hepatic mitochondrial urea-cycle activities and hepatic ultrastructure in acute fatty liver of pregnancy. *J Lab Clin Med* 1979; **94**:27-41.
31. Eisele JW, Barker EA, Smuckler EA. Lipid content in the liver of fatty metamorphosis of pregnancy. *Am J Pathol* 1975; **81**:545-555.
32. Burroughs AK, Seong NH, Dojcinov DM, Scheuer PJ, Sherlock S. Idiopathic acute fatty liver of pregnancy in 12 patients. *Quart J Med* 1982; **51**:481-497.
33. Davies MH, Wilkinson SP, Hanid MA, et al. Acute liver disease with encephalopathy and renal failure in late pregnancy and the early puerperium. A study of fourteen patients. *Brit J Obstet Gynecol* 1980; **87**:1005-1014.
34. Bernuau J, Degott C, Naulé O, Rueff B, Benhamou J-P. Non-fatal acute fatty liver of pregnancy. *Gut* 1983; **24**:340-344.
35. Hou SH, Levin S, Ahola S, et al. Acute fatty liver of pregnancy. Survival with early caesarian section. *Dig Dis Sci* 1984; **29**:449-452.
36. Ebert EC, Sun EA, Wright SH, et al. Does early diagnosis and delivery in acute fatty liver of pregnancy lead to improvement in maternal and infant survival? *Dig Dis Sci* 1984; **29**:453-455.
37. Reilly CA. Acute fatty liver of pregnancy—1984 (editorial). *Dig Dis Sci* 1984; **29**:456-457.
38. Lead article. Reye's syndrome—epidemiological considerations. *Lancet* 1982; **1**:941-943.
39. Snodgrass PJ, DeLong GR. Urea-cycle enzyme deficiencies and an increased nitrogen load producing hyperammonemia in Reye syndrome. *N Engl J Med* 1976; **294**:855-860.
40. Bove KE, McAdams AJ, Partin JC, Partin JS, Hug G, Schubert, WK. The hepatic lesion in Reye's syndrome. *Gastroenterology* 1975; **69**:685-697.
41. Zimmerman HJ, Ishak KG. Valproate-induced hepatic injury: Analysis of 23 fatal cases. *Hepatology* 1982; **2**:591-597.
42. Suchy FJ, Balistreri WF, Buchino JJ, et al. Acute hepatic failure associated with the use of sodium valproate. Report of two fatal cases. *N Engl J Med* 1979; **300**:962-966.
43. Gerber N, Dickenson RG, Harland RC. Reye-like syndrome associated with valproic acid therapy. *J Pediatr* 1979; **95**:142-144.
44. Wilson JT, Brown RD. Reye syndrome and aspirin use: The role of prodromal illness severity in the assessment of relative risk. *Pediatrics* 1982; **69**:822-825.
45. Zafrani ES, Berthelot P. Sodium valproate in the induction of unusual hepatotoxicity. *Hepatology* 1982; **2**:648-649.
46. Sherlock S. Acute fatty liver of pregnancy and the microvesicular fat diseases. *Gut* 1983; **24**:265-269.