

The effects of central venous catheter location on waveform and results

James P. Orlowski, M.D.

The author describes two cases in which central venous catheter line placement was technically and functionally good, but subsequent data were misleading and resulted in inappropriate treatment decisions. Postoperative radiographs demonstrated malposition of the central venous catheters, despite good waveforms and function. Repositioning the catheter into a central vein resulted in dramatically different central venous pressure readings. Consequently, before a central venous catheter is used for monitoring and therapeutic access, its position should be checked radiographically.

Index terms: Case reports • Catheterization, adverse effects

Cleve Clin J Med 1988; 55:171-174

Central venous pressure (CVP) catheter placement is not routinely checked radiographically after the line is placed intraoperatively. If positioning is smooth and uncomplicated and results in good blood return and a good waveform with respiratory variation, the catheter is usually assumed to be properly placed and the subsequent data obtained are used to guide management and therapy decisions. This report details two cases of CVP line placement in which catheter placement was technically and functionally good, but the data were misleading and resulted in inappropriate treatment decisions.

Case reports

Case 1. A 60-year-old man underwent a transurethral resection of the prostate. Because of poor arterial blood-gas data and an apparent change in pulmonary compliance, the possibility of fluid overload and pulmonary edema was con-

sidered. A right external jugular CVP catheter was positioned according to the Seldinger technique using a standard kit with a J wire. The catheter advanced easily, resulting in good blood return and good waveform (*Fig. 1A*). The initial CVP readings were 12–14 mmHg, so the patient was given furosemide. A chest radiograph was obtained and showed the catheter tip in the right internal jugular vein, having traveled from the right external jugular via the subclavian to the right internal jugular vein (*Fig. 1B*). The catheter was repositioned over a guide wire into the superior vena cava (*Fig. 1C*); subsequent CVP readings were 0–2 mmHg (*Fig. 1D*).


Case 2. A 68-year-old man underwent a radical neck dissection for a laryngeal carcinoma. He had a history of two remote myocardial infarctions and coronary artery disease. A left brachiocephalic 15-gauge (1.7-mm), 24-inch (61-cm) catheter-through-needle CVP line was positioned after administration of anesthesia. The catheter advanced easily to its full length with subsequent good blood return and good waveform (*Fig. 2A*). The CVP readings were consistently 14–16 mmHg, and because of borderline arterial blood-gas data and low blood pressure, the diagnosis of congestive heart failure was suggested. A chest radiograph obtained in the recovery room demonstrated that the tip of the CVP catheter was in the left internal jugular vein (*Fig. 2B*). Repositioning the CVP line into the subclavian vein (*Fig. 2C*) resulted in a significantly altered waveform tracing and a mean CVP of 8 mmHg (*Fig. 2D*).

Discussion

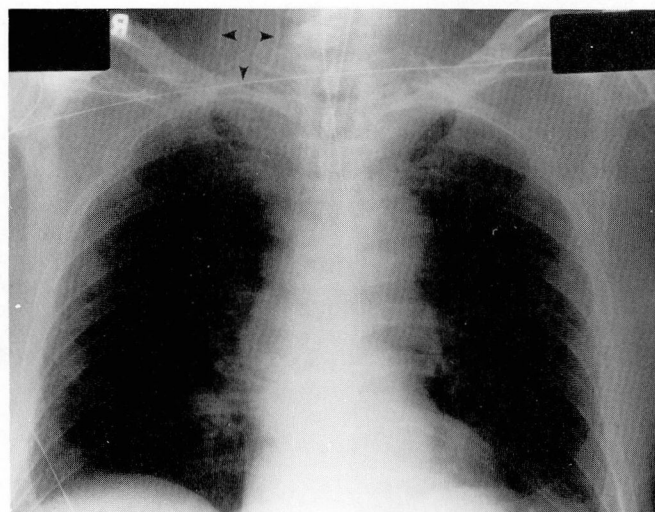
CVP readings are a dynamic assessment of right-sided heart function and adequacy of circulating intravascular volume, an invaluable guide to therapy in cases of intravascular volume depletion or overload, and useful for dynamic monitoring of right-sided heart function. When followed over time and in response to therapy, they are a time-honored and valuable guide to

Division of Anesthesiology, The Cleveland Clinic Foundation. Submitted for publication March 1987; accepted July 1987.


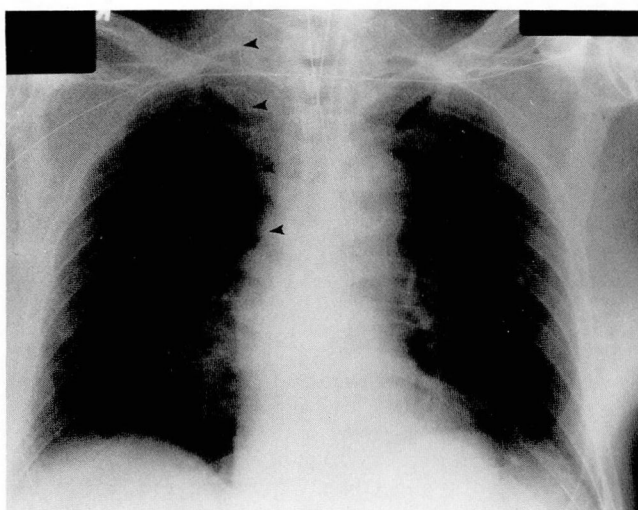
A, B



RIGHT EXTERNAL JUGULAR CATHETER
WITH TIP IN RIGHT INTERNAL JUGULAR VEIN
MEAN CVP 12 - 14 mmHg



C, D



RIGHT EXTERNAL JUGULAR CATHETER
WITH TIP IN SVC
MEAN CVP 0 - 2 mmHg

Fig. 1. Case 1. **A.** Right external jugular CVP catheter with tip in right internal jugular vein. Tracing demonstrates good waveform with presence of "a," "v," and even "c" waves, and normal respiratory variation. The mean CVP reading is 12–14 mmHg.

B. Chest radiograph (anteroposterior view), showing that the right external jugular CVP catheter has traveled into the right internal jugular vein (arrows).

C. The right external jugular CVP catheter has been repositioned over a guide wire, and the tip now lies in the SVC.

D. The CVP tracing after the catheter has been repositioned in the SVC. The mean CVP reading is 0–2 mmHg.

management.^{1,2} Isolated single CVP readings, however, can be misleading.

As reported in a number of standard textbooks of physiology,³⁻⁶ normal right atrial pressure or CVP, using the right atrium as the reference point, is 0–5 mmHg in normal supine patients.

From a standpoint of physics and fluid dynamics, pressure monitoring in the external or internal jugular vein is related to CVP readings measured in the superior vena cava or right atrium. According to Pascal's law, the pressure exerted at any point upon a confined liquid is transmitted undiminished in all directions.⁷ Likewise, Ber-

noulli's theorem states that at any point in a tube through which a liquid is flowing, the sum of pressure energy, potential energy, and kinetic energy is a constant.⁷ Attempting to indiscriminately apply principles of physics to humans is problematic because physical science properties are based on uniform fluids in rigid tubes. For a number of reasons, the behavior of the human body defies simple physics, not the least of which are the rheologic properties of blood and the dynamic aspects of blood vessels. Additionally, the pressure changes from extrathoracic to intrathoracic blood vessels and possibly the presence

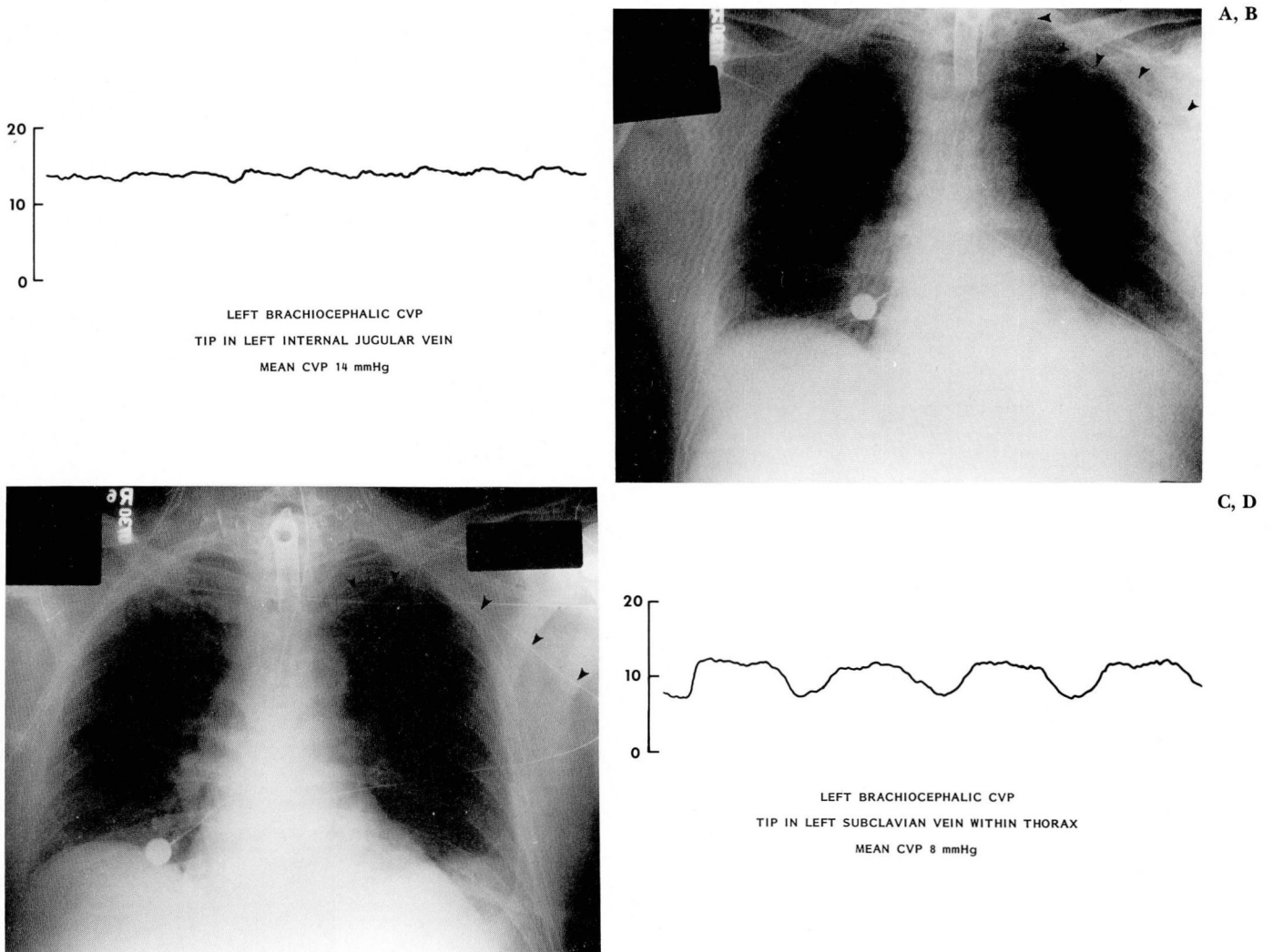


Fig. 2. Case 2. **A.** Left brachiocephalic CVP catheter with tip in the left internal jugular vein. The mean CVP reading is 14 mmHg. **B.** Chest radiograph (anteroposterior view), demonstrating the left brachiocephalic CVP catheter with its tip in the left internal jugular vein (arrows). **C.** Repeat chest radiograph after repositioning the CVP catheter so that the tip of the catheter is intrathoracic in the subclavian vein. **D.** The CVP tracing after the catheter has been repositioned. The mean CVP reading is 8 mmHg.

of jugular venous valves⁸ all contribute to important differences in pressures recorded in extrathoracic versus intrathoracic blood vessels.

In the cases presented in this report, the pressure readings were obtained with the same equipment using the same sensitivity settings and same calibration factor. There were clearcut pressure differences between supposed CVP readings from the internal jugular vein and true CVP readings from the superior vena cava or subclavian vein. In both cases, the internal jugular vein readings were 6–12 mmHg higher than the CVP readings from the superior vena cava or intrathoracic vein. Such pressure differences could have

important misleading influences on the management of the patients. In both cases, the placement of the catheter was technically uneventful, and the presence of good blood return and a good waveform with respiratory variations misled the physician to assume that he was monitoring an accurate CVP reading. It was not until the position of the catheter was checked on a postoperative radiograph that the malposition of the catheter in the internal jugular vein was discovered. Repositioning the catheter into the superior vena cava resulted in significantly different pressure readings and important changes in therapy. It would appear prudent to check the position of

CVP catheters radiographically before employing them for monitoring and therapeutic access during anesthesia. This is especially true when the readings are abnormally high and would influence a therapy decision. The cost of radiographic verification should be balanced against the risk of not being certain of the catheter's position.

Division of Anesthesiology
The Cleveland Clinic Foundation
9500 Euclid Avenue
Cleveland, Ohio 44106

References

1. Landis EM, Hortenstine JC. Functional significance of venous blood pressure. *Physiol Rev* 1950; **30**:1-32.
2. Hughes RE, Magovern GJ. The relationship between right atrial pressure and blood volume. *Arch Surg* 1959; **79**:238-243.
3. Guyton AC. *Textbook of Medical Physiology*. Philadelphia, Saunders, 1986, p 221.
4. West JB. *Best and Taylor's Physiologic Basis of Medical Practice*. Baltimore, Williams & Wilkins, 1985, p 145.
5. Berne RM, Levy MN. *Physiology*. St. Louis, Mosby, 1983, pp 578-582.
6. Ganong WF. *Review of Medical Physiology*. Los Altos, California, Lange Medical Publications, 1983, p 475.
7. Weast RC. *CRC Handbook of Chemistry and Physics*. Cleveland, Ohio, CRC, 1969, pp F-69, F-88.
8. Fisher J, Vaghaiwalla F, Tsitlik J, et al. Determinants and clinical significance of jugular venous valve competence. *Circulation* 1982; **65**:188-196.