



## Foot problems in the diabetic patient

JESS R. YOUNG, MD

■ The most prevalent of the common foot problems of the diabetic patient are arterial insufficiency, neurotrophic disease, and infections. It is important to identify the lesion type because the treatment and prognosis of each is different. With proper examination, the extent of involvement of each type of lesion can usually be delineated. Effective patient education in prevention of injuries and infections is critical.

□ INDEX TERMS: DIABETES MELLITUS; FOOT DISEASES □ CLEVE CLIN J MED 1988; 55:458-463

**T**HE FREQUENCY of foot involvement in the diabetic patient is well recognized. Bell<sup>1</sup> reported that gangrene was 53 times more frequent in diabetic men compared with nondiabetic men over age 40 and 71 times more frequent in diabetic women in the same age group.

The increased incidence of gangrene in the "diabetic foot" apparently is due to a combination of three factors: arterial insufficiency, neuropathy, and infection. Elements of all three are found in almost every case. The approach, therapy, and prognosis depends on the relative significance of each factor in the individual patient.

### ETIOLOGY

**Arterial insufficiency.** The extent of arteriosclerotic involvement is the most important factor determining whether the diabetic foot can be salvaged. Although there is no histopathologic difference between arteriosclerosis in the diabetic as compared with the nondiabetic patient, arteriosclerosis occurs more frequently, progresses more rapidly, and is more widespread in the

diabetic than in the nondiabetic patient.<sup>2</sup> Another important difference in the diabetic population is that arteriosclerosis is not more predominant in men, as it is in the nondiabetic population.

Patients with arterial insufficiency usually have a history of intermittent claudication. As the arterial occlusive disease becomes more severe, the patient may experience pain at rest. The patient often describes pain that is worse at night and is often relieved by dangling the foot from the bedside, in a dependent position.

Physical findings typically include absent leg pulses, pallor on elevation of the legs, rubor on dependency of the legs, and prolonged venous filling time. Deformities of toenails and absence of hair growth on the dorsum of the foot and toes are not good indicators of arterial insufficiency.

For physicians unskilled in vascular examinations, use of a Doppler ultrasonic velocity detector for recording blood pressure at the ankle and at the brachial artery may provide valuable information. However, in the diabetic patient, because of the frequency of vascular calcification or increased arterial stiffness, ankle pressures may be falsely elevated. More complex measurements such as pulse volume recordings at various levels of the leg, foot, and toes, and ultrasonography of blood velocity require the services of a vascular laboratory. Arteriography is not necessary unless arterial surgery or angioplasty is contemplated.

From the Department of Peripheral Vascular Disease, The Cleveland Clinic Foundation. Submitted for publication Jan 1987; accepted Apr 1988.

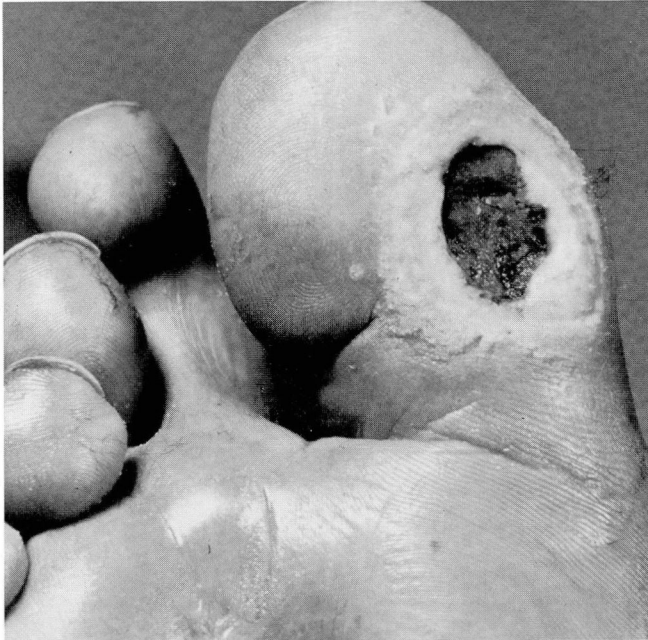


FIGURE 1. Painless, nonhealing neurotrophic ulcer surrounded by typical thick-hard callus.

**Neuropathy.** Neuropathy is the most prominent characteristic of the diabetic foot. Burning, pain, hypesthesia, paresthesia, and loss of ankle jerks may be present in the patient with diabetic neuropathy. Impairment of autonomic nerve response, pain conduction, and temperature perception predispose to lowered resistance of tissues to trauma and infection. Impaired sensation, ill-fitting shoes, protruding nails or other foreign bodies in shoes, curled threads in socks, thermal burns, or improper trimming of corns and calluses often cause trauma that the patient fails to recognize.

The neuropathic ulcer (plantar ulcer, mal perforans) results from the stress of walking on a foot that has reduced nerve supply and impaired sensation. The neuropathic disturbance also results in weakness and atrophy of the intrinsic foot muscles, which may produce characteristic deformities with the toes held dorsiflexed at the metatarsal-phalangeal joints. The toes are drawn up into a cocked-up position, called claw-toes, by simultaneous contraction of the long flexors and extensors, since the normal balancing force of the intrinsic muscles is removed. This in turn uncovers the metatarsal heads and leads to thinning of the normal fat pads. The areas over the metatarsal heads become covered with thick hard calluses. Persistent trauma to these areas results in the

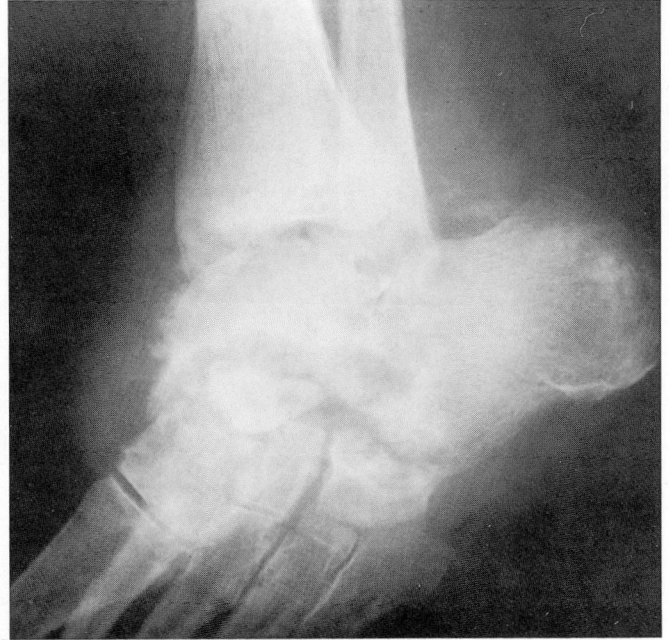

FIGURE 2. Diabetic neuropathic (Charcot's) ankle joint with joint destruction, eburnation of bone, and calcification around the joints.

typical circular "punched out," nonhealing painless ulcer surrounded by callus (*Figure 1*).

Another highly characteristic foot disorder associated with diabetic neuropathy is the neuropathic (Charcot) joint. The pathogenesis involves a sequence of events that starts with injury to a ligament (e.g., sprain) or fracture of a small bone, which is completely painless to the patient and therefore is not detected. Instead of protecting the injured joint or foot as happens with normal pain perception, the diabetic patient continues to walk on the injured foot, leading to further deterioration of alignment. Eventually multiple fractures occur, with marked destruction of bone, loss of ligament structure, and a completely deformed foot. The foot becomes shorter and wider with a tendency to eversion and external rotation, and the longitudinal arch is flattened. The gait becomes abnormal, and the markedly disturbed configuration and gait often lead to neurotrophic ulcers at sites of abnormal pressure.

Bone lysis with marked fragmentation and eburnation (*Figure 2*) is a classic radiographic feature. The joint space is decreased, the articulating bony margins are irregular and deformed, and osteophytes and bone resorption may be seen. There may be a tendency to disarticulation and dissolution of the joints and calcifica-

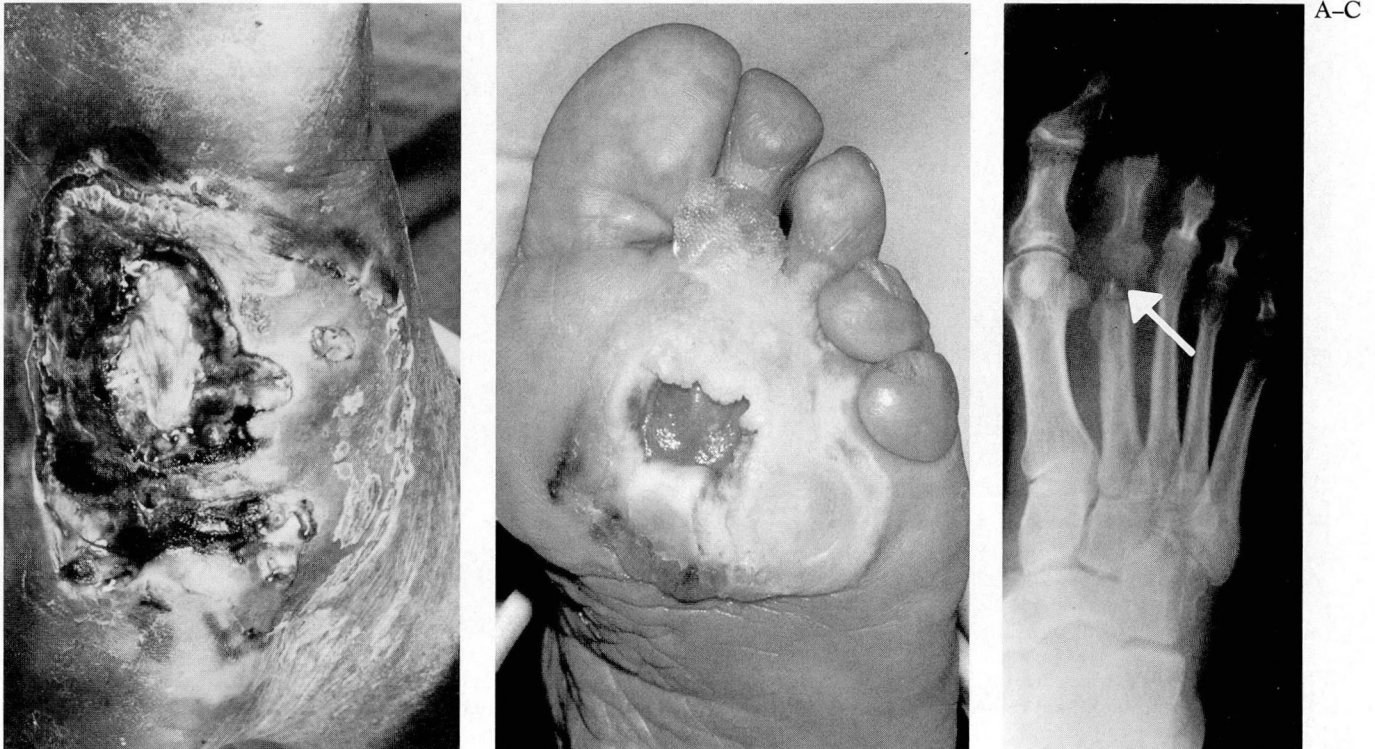


FIGURE 3A. Deep foot infection with draining sinus tracts in a patient with diabetes mellitus. FIGURE 3B. Neurotrophic ulcer with typical callus formation. FIGURE 3C. Osteomyelitis of the head of the second metatarsal in a patient with diabetic neurotrophic ulcer.

tion in and around the involved joints.

**Infection.** Infection is an important element in the components of the diabetic foot but often is secondary to neuropathic and vascular involvement. The traumatized area that results from diabetic neuropathy often becomes secondarily infected, and extensive cellulitis (Figure 3A) and osteomyelitis (Figure 3B and C) can result. A little known fact is that osteomyelitis usually requires an adequate blood supply, and therefore osteomyelitis is often a favorable prognostic sign as far as status of arterial circulation is concerned. Osteomyelitis associated with ischemia of the foot is a poor prognostic sign for avoiding amputation.

#### TREATMENT

Recognition of the concept that diabetic foot problems involve the interplay of vascular, neurologic, and infectious factors provides a guide to therapy and prognosis. In general, if the vascular aspect is predominant, a more radical approach is necessary and the prognosis is

TABLE 1  
FOOT CARE FOR THE DIABETIC PATIENT

#### DO NOT

- Cut corns, calluses, or hangnails.
- Trim toenails with fingernail clippers or scissors.
- Put talcum or baby powder in shoes.
- Rub between toes with rough towel.
- Put strong chemicals on feet.
- Walk barefoot at any time.

#### DO

- Contact your podiatrist for care of corns, calluses and ingrown toenails.
- Cut toenails straight across with toenail clippers.
- Use a good foot powder daily in your shoes.
- Bathe feet daily in lukewarm water with mild soap.
- Dry carefully between toes.
- Use a good foot cream daily before retiring.
- Inspect feet daily (bottom, top, and between toes).
- Contact your physician if leg becomes red, hard, or swollen.

poor. If the chief problem is neuropathic or infectious, conservative efforts are to be stressed and the prognosis for saving the limb is better.

**Arterial insufficiency.** All patients with arterioscle-

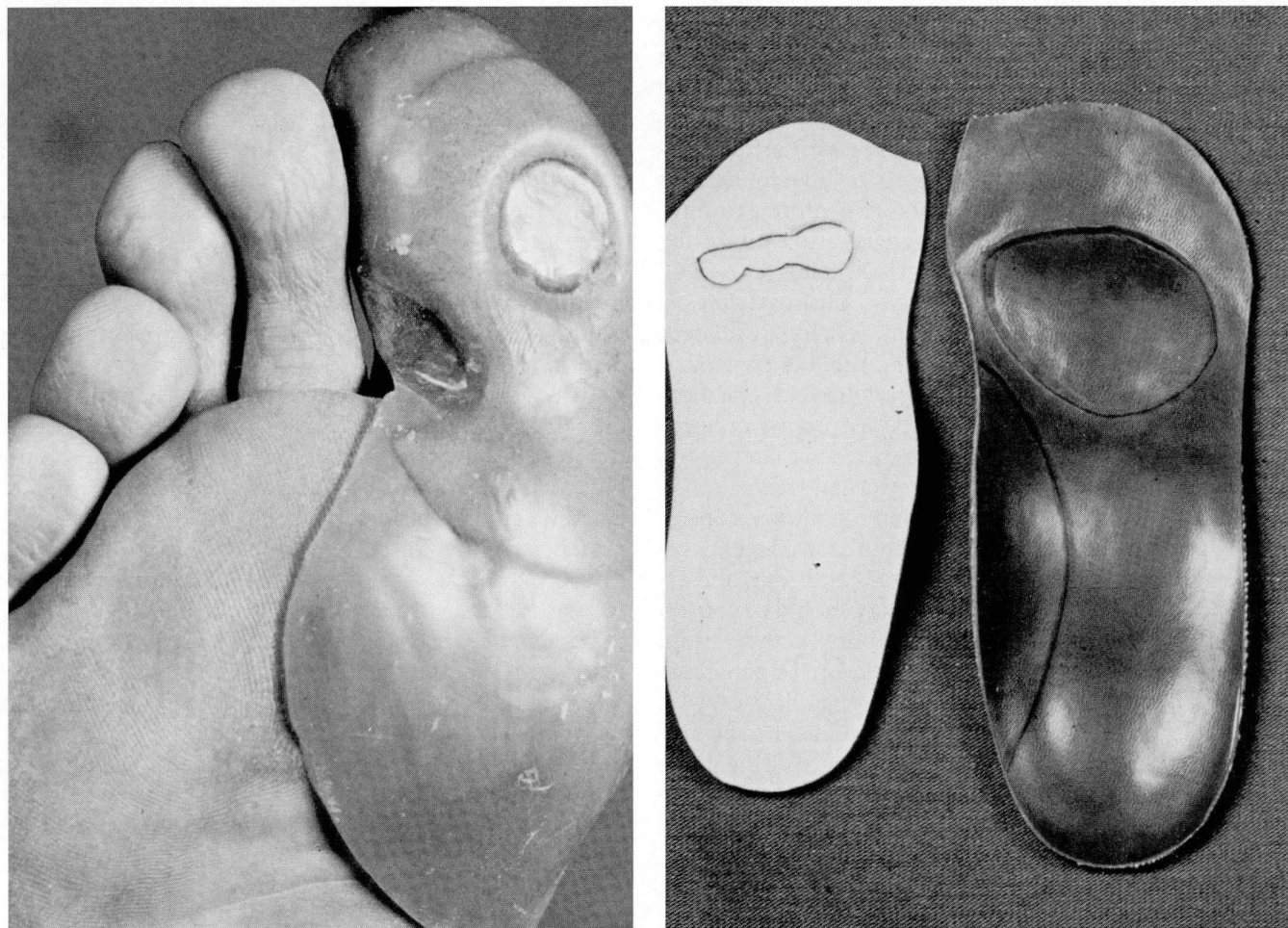


FIGURE 4. Orthotic devices to redistribute weight-bearing in patients with neuropathic lesions.

rosis should be instructed regarding a medical treatment program. Although some patients will require surgical treatment to improve circulation, surgery in itself has no beneficial effect on atherogenesis, either locally or in other arterial beds.

The cornerstone of medical therapy consists of, in probable order of importance: 1) smoking cessation, 2) exercise, 3) foot care, and 4) proper diet.

Stopping smoking is probably the most important factor in decreasing the progression of atherosclerosis over which the patient has control. Smoking reduces the development of collateral circulation and causes vasoconstriction.

A good exercise program is also important. The patient should be encouraged to walk as much as possible, and to walk at least an hour daily. He should not stop walking at the first sign of claudication, but should

continue walking as far as possible until the discomfort makes him stop.

The precipitating cause of many ischemic ulcers and gangrene is trauma from mechanical, chemical, or thermal sources. Each patient should be given detailed instructions on care of extremities (*Table 1*). The patient should be carefully advised on care of the nails, avoidance of extremes of heat and cold, and proper care of athlete's foot. The patient should be made aware that ingrown toenails, corns, and calluses should be treated by a physician or a podiatrist who is informed that the patient has arterial insufficiency.

The benefits of lowering the level of low-density lipoprotein cholesterol with diet and drugs are becoming clearer. Recent data<sup>4,5</sup> suggest that appropriate drug therapy of hyperlipidemia may help arrest and possibly help reverse the pathologic changes of atherosclerosis. The

introduction of inhibitors of cholesterol biosynthesis,<sup>6</sup> which are well tolerated and effective agents for the treatment of hypercholesterolemia, offers an even more promising approach to treatment.

In recent years, a number of new drugs have been introduced for the treatment of patients with arteriosclerotic vascular disease. Most authorities have found that oral vasodilators are ineffective. The prostaglandins, potent vasodilating and platelet-aggregation inhibiting agents, have not lived up to their earlier promise and claims on randomized trials.<sup>7</sup> A new antihypertensive and antiserotonin agent, ketanserin, is being evaluated<sup>8</sup> and holds promise of decreasing the number of strokes, heart attacks, and amputations in patients with claudication. Pentoxifylline, which acts by increasing erythrocyte flexibility and improving the microcirculation, has produced moderate benefits in controlled trials.

A decision as to whether a patient should be considered for surgical improvement of circulation depends on the symptoms of the patient, general condition, and arteriographic pattern of disease. Surgery should be considered if there is economically disabling claudication, severe ischemia with rest pain, ulceration, or gangrene. For patients with milder intermittent claudication who can work but are unable to follow their hobbies or activities such as jogging, golf, tennis, or hunting, non-surgical interventional therapy can be considered. These procedures include balloon angioplasty, laser angioplasty, and atherectomy.

**Neuropathy.** Treatment of the diabetic neuropathic ulcer is conditioned by the fact that two elements are involved in pathogenesis: neuropathic and mechanical. At present no therapy exists for removing or reversing the neurologic component. All effort must therefore be directed toward eliminating or alleviating the mechanical factors. Weight bearing must be eliminated or sharply curtailed. Orthopedic and orthotic appliances may help to prevent weight bearing on the affected site (*Figure 4*). In addition, debridement, trimming of the callus, and antibiotics for infected ulcers may produce healing. In stubborn cases, various procedures with varying success rates have been suggested, such as a total contact short leg plaster cast,<sup>10</sup> metatarsal osteotomy to relieve the

pressure of the metatarsal head on the surrounding tissues,<sup>11</sup> saucerization of bony prominences combined with excision of the neurotrophic ulcer and primary closure of the skin,<sup>12</sup> single metatarsal head resection, and resection of all the metatarsal heads.<sup>13</sup> Proper shoes are necessary after the ulcer has healed in order to prevent further difficulty.

Therapy of Charcot joint is often of help. Although there is no cure for this condition, the use of orthopedic appliances such as short leg braces, especially built on molded shoes, sponge-rubber arch supports, prostheses, walking casts, and crutches may help prevent further deformity.

**Infection.** When infection is the predominant element in the diabetic foot, conservative measures include rest, protection of the foot, and the use of the proper antibiotics as determined by culture and sensitivity studies. Diabetic control becomes particularly important in the presence of infection. Should the infection be a widespread, deep-seated cellulitis, prompt action is necessary to save the foot with wide incision and drainage and local debridement. Infecting bacteria are usually multiple, with both aerobic and anaerobic microorganisms.<sup>14</sup> Specimens for culture should be obtained from infected tissue that does not communicate directly with a foot ulcer or draining sinus if possible. If such specimens are not available, cultures of purulent exudate within the foot ulcer or sinus may provide useful information on which to base decisions about antibiotic therapy. Broad-spectrum  $\beta$ -lactamase antibiotics or a combination of antibiotics active against facultatively anaerobic cocci and bacilli as well as aerobes provide the best empirical coverage in these patients. If osteomyelitis is present, the involved bone may have to be removed. If it cannot be removed, cultures of bone biopsy samples should be treated with a four- to six-week course of the appropriate intravenous antibiotic or antibiotics.<sup>16</sup>

Department of Peripheral Vascular Disease  
The Cleveland Clinic Foundation  
One Clinic Center  
9500 Euclid Avenue  
Cleveland, Ohio 44195

## REFERENCES

1. Bell ET. Atherosclerotic gangrene of the lower extremities in diabetic and nondiabetic persons. *Am J Clin Pathol* 1957; 28:27-36.
2. Haimovici H. Peripheral arterial disease in diabetes. *New York J Med* 1961; 61:2988-2999.
3. Gibbons GW, Wheelock FC Jr, Hoar CS Jr, et al. Predicting success of forefoot amputations in diabetics by noninvasive testing. *Arch Surg* 1979; 114:1034-1036.
4. The Lipid Research Clinics Coronary Primary Prevention Trial Results: I. Reduction in incidence of coronary heart disease. *JAMA* 1984; 251:351-364.
5. The Lipid Research Clinics Coronary Primary Prevention Trial Results: II. The relationship of reduction in incidence of coronary heart disease to cholesterol lowering. *JAMA* 1984; 254:365-374.

6. Lovastatin Study Grup II. Therapeutic response to lovastatin (mevinolin) in nonfamilial hypercholesterolemia: a multicenter study. *JAMA* 1986; **256**:2829-2834.
7. Cronenwett JL. The use of prostaglandins PGE1 and PGI2 in peripheral arterial ischemia. *J Vasc Surg* 1986; **3**:370-374.
8. De Cree J, Leempoels J, Geukens H, Verhaegen H. Placebo-controlled double-blind trial of ketanserine in treatment of intermittent claudication. *Lancet* 1984; **2**:775-778.
9. Rossner M, Muller R. On the assessment of the efficacy of pentoxifylline (Trental). *J Med Clin Exp Theor* 1987; **18**:1-15.
10. Walker SC, Helm PA, Pullium G. Total contact casting and chronic diabetic neuropathic foot ulcerations: healing rates by wound location. *Arch Phys Med Rehabil* 1987; **68**:217-221.
11. Frykberg RG. Podiatric problems in diabetes. [In] Kozak GP, Hoar CS Jr, Rowbotham JL, eds. *Management of Diabetic Foot Problems*. Philadelphia, WB Saunders, 1984, pp 5-67.
12. Leventen EO. Charcot foot—a technique for treatment of chronic plantar ulcer by saucerization and primary closure. *Foot Ankle* 1986; **6**:295-299.
13. Jacobs RL. Hoffman procedure in the ulcerated diabetic neuropathic foot. *Foot Ankle* 1982; **3**:142-149.
14. Livingston R, Jacobs RL, Karmody A. Plantar abscess in the diabetic patient. *Foot Ankle* 1985; **5**:205-213.
15. Wheat LJ, Allen SD, Henry M, et al. Diabetic foot infections: bacteriologic analysis. *Arch Intern Med* 1986; **146**:1935-1940.
16. Sugarman B, Hawes S, Musher DM, Klima M, Young EJ, Pircher F. Osteomyelitis beneath pressure sores. *Arch Intern Med* 1983; **143**:683-688.