

Coronary artery spasm during balloon angioplasty in a patient receiving dopamine infusion

PAUL T. MCENIERY, MB, BS, FRACP AND JAY HOLLMAN, MD, FACC

■ A case of severe diffuse coronary artery spasm following percutaneous transluminal coronary angioplasty (PTCA) during an infusion of dopamine at 12 $\mu\text{g/kg/min}$ is reported. Although the incidence is low (0.1% of women undergoing PTCA), the condition required prompt reversal with intraaortic balloon counterpulsation and intravenous nitroglycerin.

□ INDEX TERMS: ANGIOPLASTY, TRANSLUMINAL; CORONARY VASOSPASM □ CLEVE CLIN J MED 1988; 55:464-466

LOCAL coronary spasm at the site of balloon dilatation is a known complication of percutaneous transluminal coronary angioplasty (PTCA).¹ We report a PTCA procedure complicated by diffuse coronary artery spasm distant from the site of dilatation, while the patient was receiving infusions of dopamine.

CASE REPORT

A 64-year-old woman presented with angina pectoris six years following coronary artery bypass grafting (saphenous vein graft to left anterior descending artery and saphenous vein graft to the right coronary artery) and three weeks following an inferoposterior myocardial infarction. Coronary angiography revealed a subtotal obstruction of the left anterior descending artery and a patent but diffusely diseased saphenous vein graft to the left anterior descending artery. The right coronary graft was occluded. The proximal diaphragmatic wall was akinetic; the rest of the ventricle contracted normally.

From the Department of Cardiology, The Cleveland Clinic Foundation. Submitted for publication May 1987; accepted March 1988.

Ejection fraction was estimated at 50%. In view of the continuing angina and the disease in the vein graft, PTCA of the left anterior descending artery was undertaken and was successful.

Prior to and during PTCA, the patient had been receiving an infusion of dopamine at 12 $\mu\text{g/kg/minute}$ to maintain systemic blood pressure, since she had had earlier episodes of chest pain associated with hypotension (systolic blood pressure <70 mmHg). The patient had been premedicated with diltiazem 90 mg q 6 h, heparin 700 units/hour, aspirin 325 mg t.i.d., and a nitroglycerin infusion at 17 $\mu\text{g/minute}$. Propranolol therapy had been stopped two days prior to angioplasty.

Immediately following the procedure, chest pain and anterior ST segment depression developed. Repeat angiography revealed diffuse spasm of the proximal half of the now-patent left anterior descending artery and the proximal part of the large circumflex system (*Figure 1*). The patient was treated by inserting an intraaortic balloon pump, increasing infusion of intravenous nitroglycerin, continuing diltiazem 90 mg q 6 h, and ceasing the dopamine infusion. After balloon pump placement, arterial access was impossible via the other femoral artery. The exact spasm duration could not be determined. Over the next 24 hours, she recovered completely, and had a small rise in enzyme levels (CPK = 736 IU/L with MB CK

A, B

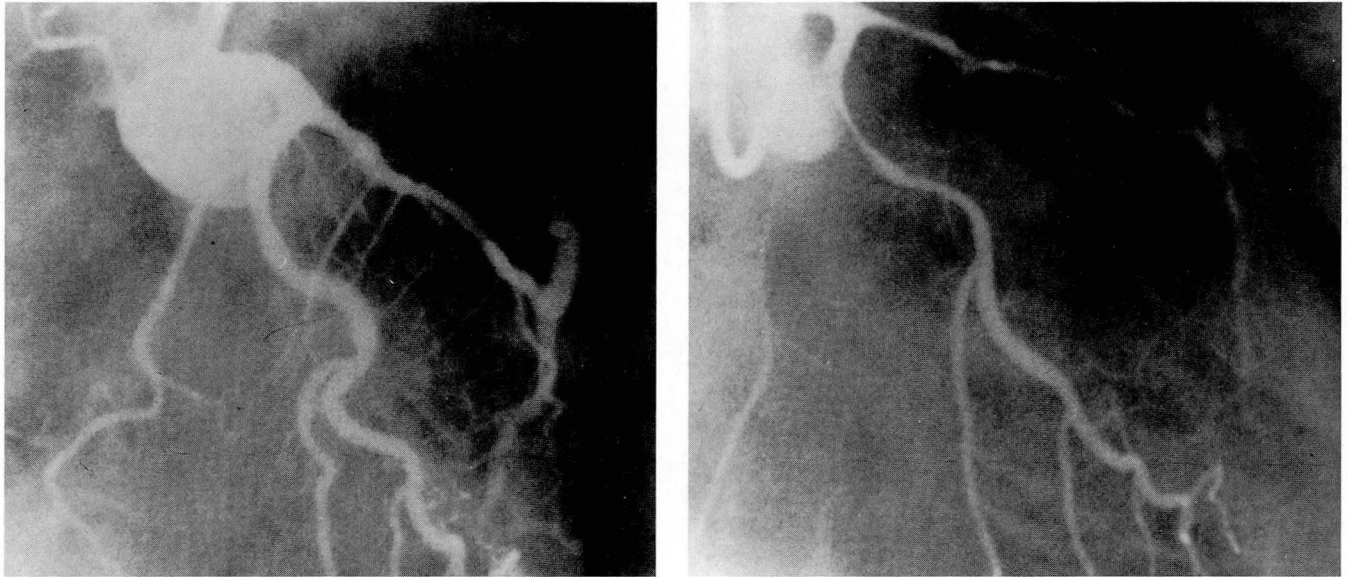


Figure 1. Right anterior oblique caudal projection of the left coronary artery (A) after angioplasty of the left anterior descending artery proximal to the insertion of the diseased saphenous vein graft, and (B) after development of severe spasm in the left anterior descending and circumflex arteries.

19%, LDH = 387 IU/L with LDH 1 peaking at 35%, and SGOT = 76 IU/L). The coronary spasm occurred six hours following the last dose of diltiazem.

DISCUSSION

This case illustrates the possibility of diffuse coronary artery spasm in patients undergoing PTCA while receiving an infusion of dopamine. The coronary artery spasm that occurred in this patient differed from acute occlusion syndrome² because in acute occlusion syndrome the vessel totally closes at the site of balloon inflation, while in this case spasm was more diffuse and involved areas proximal to the dilatation site. An artery not entered with the balloon catheter showed coronary artery spasm. The mechanism of this diffuse, proximal coronary spasm is unknown. However, Crea et al³ recently described coronary spasm in patients receiving dopamine infusion of as little as 5 µg/kg/min, and Dai et al⁴ have found evidence for dopamine constrictor effect on alpha-2 receptors in dogs. Our patient was receiving dopamine infusion for hypotension. Prompt intraaortic balloon counterpulsation reversed the hypotension and allowed nitroglycerin infusion to be increased and dopamine to be decreased.

Hypotension is a common complication of coronary angioplasty. Since hypotension predisposes to acute

occlusion syndrome,² it is routinely treated aggressively, first with intravenous fluids and then with intravenous vasopressors such as dopamine. In our laboratory, dopamine infusion for hypotension is required in 2% of women undergoing PTCA. We have so far observed coronary artery spasm associated with dopamine infusion in only this one woman, of 969 women undergoing PTCA. Of the approximate 20 female PTCA patients receiving dopamine infusions, this has been the only patient to show this type of diffuse spasm. Clear dosage information has not been available on all patients but in 14 female patients who received dopamine and who had a dosage recorded, only one other patient received 12 µg/kg/min. We conclude that dopamine used for hypotension during PTCA may be associated with the development of diffuse coronary spasm. It should be used with caution, particularly if higher doses are required.

JAY HOLLMAN, MD
Department of Cardiology
Cleveland Clinic Foundation
One Clinic Center
9500 Euclid Avenue
Cleveland, Ohio 44195

ACKNOWLEDGMENTS

We wish to thank Beverly Kane and Kathy Konrad for their assistance in preparing this manuscript.

REFERENCES

1. Cowley MJ, Dorros G, Kelsey SF, Van Raden M, Detre KM. Acute coronary events associated with percutaneous transluminal coronary angioplasty. *Am J Cardiol* 1984; **53**:12C-16C.
2. Hollman J, Gruentzig AR, Douglas JS Jr, King SB III, Ischinger T, Meier B. Acute occlusion after percutaneous transluminal coronary angioplasty — a new approach. *Circulation* 1983; **68**:725-732.
3. Crea F, Chierchia S, Kaski JC, et al. Provocation of coronary spasm by dopamine in patients with active variant angina pectoris. *Circulation* 1986; **74**:262-269.
4. Dai X-Z, Chen D-G, Homans DC, Schwartz JS, Bache RJ. Mechanism of dopamine-induced coronary vasoconstriction (abstr). *Circulation* 1986; **74**(suppl):115.

