

# Malignant vasovagal syncope: prolonged asystole provoked by head-up tilt

Case report and review of diagnosis, pathophysiology, and therapy

JAMES D. MALONEY, MD; FREDRICK J. JAEGER, DO; FETNAT M. FOUAD-TARAZI, MD; HAROLD H. MORRIS, MD

■ Vasovagal syncope is a common clinical disorder that often escapes diagnosis; if the syncope is recurrent and severe (malignant vasovagal syncope), it can be a source of morbidity and possibly mortality. The authors report a 39-year-old patient with recurrent, unexplained syncope who underwent provocative head-up tilt testing that resulted in asystole for 73 seconds. In addition to vasovagal syncope, head-up tilt test also aids in the diagnosis and management of disorders of blood pressure and heart rate regulation. Management of recurrent vasovagal syncope is based upon the underlying pathophysiology and includes transdermal scopolamine, volume expansion, biofeedback, support stockings, and pacemakers (preferably AV sequential).

□ INDEX TERM: SYNCOPE □ CLEVE CLIN J MED 1988; 55:542-548

**V**ASOVAGAL SYNCOPE, a common and pervasive disorder, is often a therapeutic and diagnostic dilemma. Although by its nature vasovagal syncope is always a nuisance and an inconvenience to the patient, rarely has either its occurrence or its consequences been considered disabling or life-threatening.

dangerous because of its singular nature and circumstances (prolonged duration of asystole). We propose the term "malignant vasovagal syncope" to encompass a disabling clinical syndrome that can drastically and dramatically alter lifestyle and well-being and can represent a significant threat to health.

■ See also the editorial by Scheinman (pp 503-504)

We describe a case in which recurrent vasovagal syncope eluded diagnosis prior to provocative head-up tilt testing. The syncope in this case was particularly

## CASE REPORT

A 39-year-old man had increasingly frequent spells of loss of consciousness despite prior medical evaluation and presumptive anticonvulsive therapy. He was examined at the Neurology Department of The Cleveland Clinic Foundation in August 1985. His syncopal episodes had first appeared in early childhood and had varied greatly in frequency over the years, but the clinical characteristics had remained constant. Most recently, these episodes were occurring one to two times per week and had caused injuries. Twice, spells had occurred while the man was operating his semitractor

From the Departments of Cardiology (J.D.M.), Heart and Hypertension Research (F.J.J., M.F.T.), and Neurology (H.H.M.), The Cleveland Clinic Foundation. Submitted for publication Jan 1988; accepted Mar 1988.

Address reprint requests to J.D.M., Department of Cardiology, The Cleveland Clinic Foundation, One Clinic Center, 9500 Euclid Avenue, Cleveland, Ohio 44195.

trailer and had resulted in serious motor-vehicle accidents. This necessitated a change in employment, which resulted in a major reduction in income.

No family member had a history of syncope; however, an uncle had epilepsy. Other than a splenectomy performed for uncertain reasons at age one year, the medical history was unremarkable. There was no history of alcohol or drug abuse. Prior evaluations for these episodes of recurrent loss of consciousness, resulting in no clear diagnosis, had included CT scans, multiple Holter recordings, several electroencephalograms, and laboratory chemistry and hematology determinations. In 1978, an abnormal electroencephalogram led to therapeutic trials of anticonvulsant medications.

The patient, his wife, and other observers characterized a typical spell as a brief prodrome of dizziness, nausea, diaphoresis, pallor, and vague abdominal discomfort. This was usually followed by sudden complete loss of consciousness for 30 seconds to two minutes. Weakness and fatigue persisted for several minutes after he regained consciousness. These episodes were not accompanied by palpitations or other cardiac signs, focal neurologic deficits, or incontinence, but myoclonic movements were described. The spells occurred during sitting or standing and occasionally appeared to be provoked by stress or pain; one spell had occurred during a dental procedure. The patient's wife reported inability to palpate her husband's radial pulse during one spell.

During the initial evaluation period, we performed multiple physical examinations, with special attention to neurologic and cardiovascular function. All examination findings were normal. Findings included: weight, 82 kg; resting blood pressure, 115/76 mmHg; absence of orthostatic hypotension; and resting heart rate, 65 beats per minute. The heart rhythm was regular, there were no murmurs, and response to the Valsalva maneuver was normal. All peripheral pulses were normal and there were no bruits. The heart rate and blood pressure responses to carotid sinus massage were normal. The electrocardiogram demonstrated normal sinus rhythm, normal PR interval, normal QRS morphology and duration, and normal ST-T waves. The chest radiograph, blood hematology, and chemistry analysis were all within normal limits.

Additional diagnostic and provocative tests were ordered and included:

1. Ambulatory EEG monitoring,
2. Treadmill exercise testing,
3. Repeat ambulatory 48-hour ECG monitoring,
4. Provocative head-up tilt testing, and
5. Intracardiac electrophysiologic recording and

stimulation.

The first head-up tilt test was performed while the patient was fortuitously undergoing ambulatory EEG monitoring. The initial portion of the tilt-table test demonstrated a normal heart rate and blood pressure response. The control heart rate was 57 beats per minute and blood pressure was 115/76 mmHg, which changed to 74 beats per minute and 110/80 mmHg after several minutes of 60° tilt.

At eight minutes of 60° tilt, the patient noted the onset of his usual prodromal symptoms, and the systolic blood pressure was recorded at 60 mmHg. With the onset of prodromal symptoms, the sinus rate slowed to approximately 54 beats per minute. As the patient was being returned to the supine position, he lost consciousness. The ECG demonstrated several nonconducted atrial depolarizations and junctional escape beats followed by a 73-second interval of atrial and ventricular asystole (Figure 1). The prodromal period lasted approximately 20 seconds prior to asystole. Brief myoclonic jerks were noted during the first few seconds of unconsciousness. After approximately 30 seconds of asystole, external chest compression was initiated and atropine was administered intravenously. The prolonged asystolic episode was terminated by several junctional escape beats. This was followed in seconds by sinus rhythm, effective blood pressure, and return of consciousness.

Subsequent analysis of the simultaneous EEG recordings documented the onset and resolution of global cerebral hypoxemia with the blood pressure and heart rate changes. Blood volume (RISA), serum catecholamines, serum aldosterone, and plasma renin activity measurements were obtained prior to the induction of the syncope episode. All of these values were subsequently determined to be normal.

The patient demonstrated normal continuous ambulatory ECG telemetry monitoring over the next 24 hours. The following day, a diagnostic three-catheter intracardiac electrophysiologic test was performed. After local anesthesia and during placement of the femoral catheters, the patient experienced his typical vasovagal attack, with hypotension and mild bradycardia. This resulted in loss of consciousness while supine and simultaneous development of 19 seconds of cardiac asystole. Since intravenously administered atropine was used as an emergency intervention for this dramatic episode, the subsequent electrophysiologic observations were obtained with the patient under the influence of atropine. All subsequent parameters measured were normal and included sinus node recovery times, AV nodal conduc-

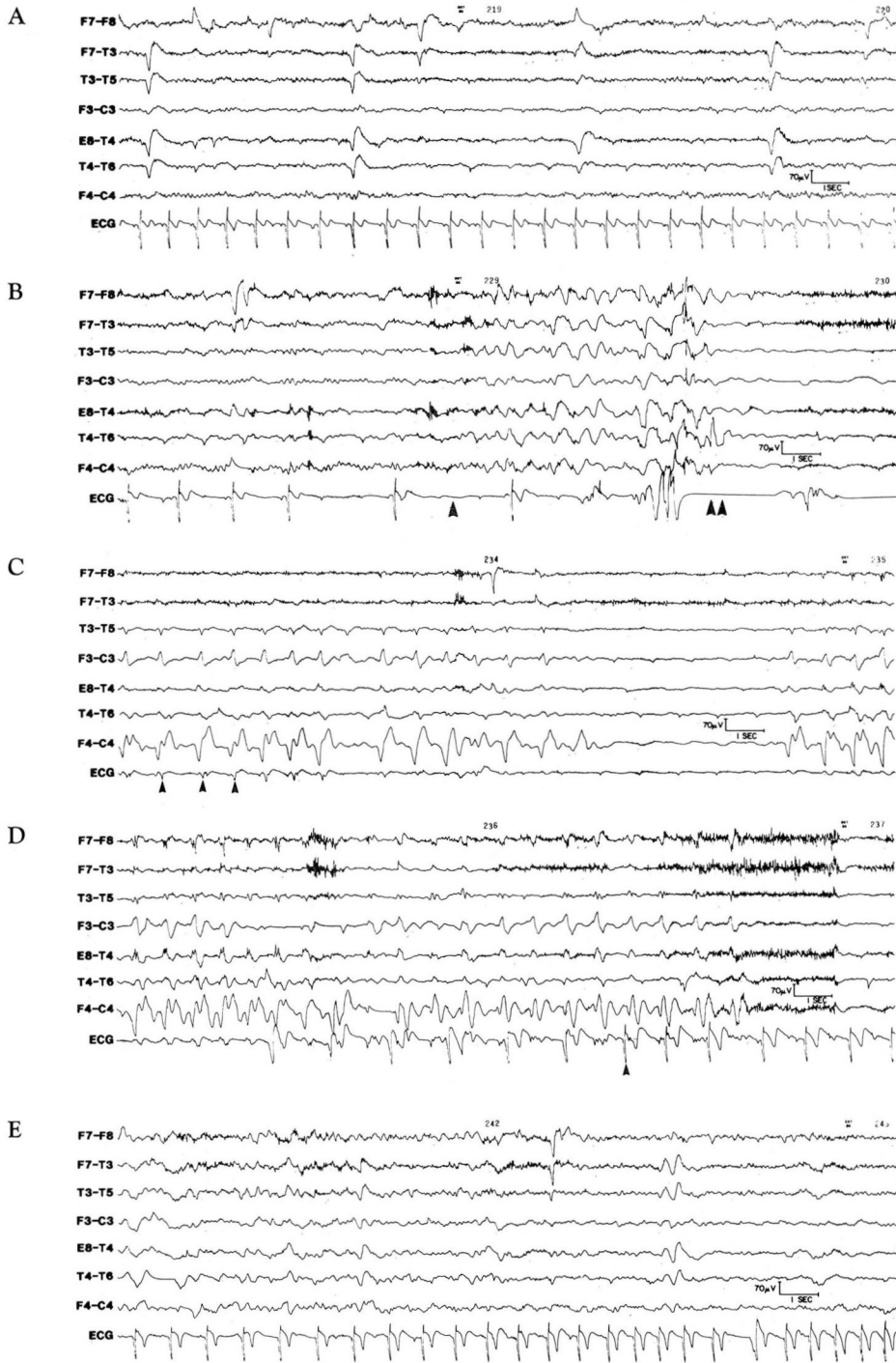


FIGURE 1A. Normal ECG and EEG during head-up tilt prior to syncope. FIGURE 1B. ECG demonstrates sinus bradycardia, nonconducted atrial depolarizations, and onset of asystole. EEG shows onset of generalized EEG showing (single arrowhead) progressing to absence of EEG background (double arrowhead). FIGURE 1C. Continued asystole and absence of EEG background with CPR artifact in EEG and ECG leads (arrowheads). FIGURE 1D. After 73 seconds of asystole, onset of junctional rhythm. FIGURE 1E. Resumption of normal ECG.

tion, and H-V intervals. Programmed stimulation failed to induce any abnormal supraventricular or ventricular tachyarrhythmias. The response to carotid sinus massage, before and after atropine, was normal.

The observations obtained during head-up tilt and electrophysiologic testing supported the clinical diagnosis of severe vasovagal syncope and vasodepressor syncope with a malignant degree of reflex asystole. Therefore, a dual-chamber bipolar pacing system was implanted to control the cardiac manifestations (bradycardia and asystole). We recognized that other interventions were likely to be necessary for managing the peripheral aspects of this disorder.

One day following pacemaker implantation, the patient underwent repeat head-up tilt test with the DDD pacing system initially programmed to a low rate of 50 beats per minute. The test was then repeated with the device reprogrammed to a low rate of 70 beats per minute. At both pacemaker rates, the stress of the tilt-table test induced severe symptomatic hypotension despite prevention of asystole and maintenance of AV synchrony with the DDD pacing system. The transdermal formulation of scopolamine (Transderm-Scop) was then administered in combination with hydroflurocortisone (Florinef) and liberal dietary salt. One day after

these measures were instituted, the head-up tilt test was repeated; heart rate and blood pressure response were normal and there were no syncopal or presyncopal symptoms.

During the last two years, the patient has returned to full activity and has been free of syncopal or near syncopal symptoms. The anticonvulsant therapy was discontinued at the time of hospital discharge and Florinef was discontinued several months later. The demand low rate of the pacing system was decreased to 50 beats per minute; however, Transderm-Scop (one patch every two days) has been continued throughout this follow-up period. There have been no side effects associated with the scopolamine patch. A repeat head-up tilt test was performed in July 1987. The test was performed while the patient was on scopolamine (his only therapy other than the pacing system in a demand mode). His head-up tilt test demonstrated resting heart rates above 60 beats per minute, a normal heart rate and blood pressure response to tilt, and no evidence of symptoms or hemodynamic changes suggestive of vasovagal syncope. He has returned to his previous employment as an operator of a semitractor trailer.

#### DISCUSSION

Several unique and important aspects in the presentation, diagnosis, and management of vasovagal syncope are illustrated in this case. They include:

1. The long duration of the asystolic episode,
2. The use of head-up tilt as a provocative test,
3. The malignant nature of vasovagal and vasodepressor syncope, and
4. Controversies and uncertainties about pathophysiology and therapy.

#### Asystole

The literature identifies several reports of prolonged reflex ventricular asystole accompanying vasovagal syncope.<sup>1-5</sup> To our knowledge, the case reported by Brahm et al involving 58 seconds of reflex cardiac arrest appears to be the longest ECG documented asystole previously reported.<sup>1</sup> Our patient's 73 seconds of ventricular asystole was preceded by approximately 20 seconds of bradycardia and hypotension and is clearly unique in its duration as well as in its relationship to provocation by the head-up tilt test and simultaneous EEG recordings demonstrating evolving global cerebral hypoxemia. However, during the last three months of 1987 alone, we observed at least five cases of prolonged ventricular and atrial reflex asystole (five to 51 seconds) in patients

with suspected vasovagal syncope undergoing head-up tilt testing. These dramatic asystolic episodes appear to be more frequent and more prolonged than those observed during routine ambulatory monitoring. They appear to be a response to provocative head-up tilt testing, but further investigation is required.

#### Head-up tilt

This case supports our previous observations about the utility of a provocative head-up tilt test in establishing the diagnosis of vasovagal syncope, vasodepressor syncope, and other abnormalities of blood pressure control that may be responsible for loss of consciousness.<sup>6-12</sup> This test has been employed at the Cleveland Clinic for more than two decades, initially as a research tool and subsequently as a clinical modality in the management of these disorders. Traditionally, the diagnosis of syncope has been presumptive. It has been based on the identification of abnormal findings, such as intermittent complete heart block or paroxysmal ventricular tachycardia, which have a high association with syncope but are not necessarily recorded during a clinical episode. Furthermore, the presumptive diagnosis of vasovagal syncope has been one of exclusion, frequently made only after extensive diagnostic investigation has ruled out other presumptive causes. Just as invasive electrophysiologic testing has proved to be a valuable provocative tool for the diagnosis of syncope in carefully selected patients (usually patients with organic heart disease), head-up tilt testing has proved to be a valuable provocative tool for reproducing syncope in many patients with vasovagal-mediated spells or other disorders of blood pressure regulation.

As previously described,<sup>12</sup> the tilt-table test is performed as follows: after an overnight fast, the patient is placed supine on a tilt-table at 0°. Venous access is established, and the patient is observed for approximately 30 minutes. During this control period, blood pressure and heart rate measurements are obtained. The patient is then tilted 15°, 30°, and 45° for two minutes at each stage. Blood pressure and heart rate determinations are recorded every minute throughout the entire test. If the patient tolerates each elevation for two minutes, the tilt is advanced to 60° and maintained for a minimum of 20 minutes or as tolerated. During the control period and after 10 minutes at 60° elevation, venous blood samples are obtained through the previously placed heparin lock and tested for plasma renin activity, aldosterone, and catecholamines. The patient is monitored for symptoms or vital sign changes. The test is terminated at the end of 20 minutes of 60° elevation or sooner if severe hypoten-

sion, syncope, or other limiting reactions develop. If the patient becomes symptomatic, it is important to consider immediately whether this closely reproduces the clinical problem.

Tilt-table testing is relatively noninvasive and appears to be valuable, safe, and inexpensive for identifying patients with recurrent syncope due to disorders of blood pressure regulation. In addition to identifying patients with vasovagal and vasodepressor syncope, the test can aid in the management of orthostatic hypotension,<sup>9</sup> autonomic neuropathy,<sup>13,14</sup> hyperdynamic beta-adrenergic circulatory state,<sup>15</sup> pacemaker syndrome,<sup>12</sup> idiopathic hypovolemia,<sup>11</sup> vestibular disorders,<sup>16</sup> and carotid sinus hypersensitivity.<sup>17</sup> Head-up tilt testing in conjunction with intracardiac electrophysiologic testing may enhance the induction of cardiac arrhythmias, such as supraventricular tachycardia, and the evaluation of their hemodynamic consequences.<sup>18</sup>

Additional complementary information can be obtained when the tilt-table test is performed in conjunction with plasma volume determinations by the RISA method.<sup>19</sup> This relatively noninvasive test measures the patient's blood volume status and is helpful in determining if significant hypovolemia exists. The patient can also subsequently undergo a radionuclide (Tc-99m) hemodynamic study while supine or sitting. This test provides measurements of cardiac output, cardiac index, ejection fraction, total peripheral resistance, and the ratio of cardiopulmonary blood volume to total blood volume in the supine position and in response to postural change.<sup>20</sup> These parameters can identify significant peripheral venous pooling as well as other conditions that predispose to orthostatic hypotension, vasovagal syncope, and other disorders.

### Malignant syncope

Vasovagal syncope, also known as "the common faint," is a frequent cause of transient loss of consciousness.<sup>21-23</sup> Vasovagal syncope is usually assumed to be a benign disorder with a benign prognosis; however, this case illustrates that it can cause major disability and possibly death. To describe this clinical situation, we have chosen the phrase "malignant vasovagal syncope." As in this case, patients with recurrent vasovagal syncope may be prevented from driving, and consequently can lose their primary employment and independence, and incur considerable financial loss. Patients, their families, and their physicians may also impose other restrictions, and major psychological problems arising from uncertainty and fear of further syncopal episodes may develop.

Additional rationale for the term malignant vasovagal syncope becomes evident when one considers the actual cerebral consequences of recurrent prolonged asystole and the possible effects of severe hypotension and asystole on cardiac vulnerability. As illustrated in our case, recurrent vasovagal syncope with an ill-defined prodromal period can be extremely dangerous to the ill person and to bystanders if that person is operating a car, truck, plane, or other dangerous machinery.

Aside from the injuries that may be sustained with loss of consciousness, there are suggestions that vasovagal syncope may be directly responsible for increased mortality in certain patients.<sup>24</sup> It is presumed that normal sinus rhythm and blood pressure control will return spontaneously in patients with syncopal episodes like these; however, extreme autonomic imbalance and dual autonomic stimulation have been associated with sudden death in patients with otherwise normal hearts.<sup>25</sup> Although irreversible neurologic injury is unlikely, prolonged asystole, when associated with coexisting cardiac structural disease, may lower the threshold for ventricular fibrillation.

### Controversies in therapy and pathophysiology

We hypothesize that vasovagal and vasodepressor syncope are not diseases but merely the product of exaggerated reflexes and that they are often modulated, augmented, or manifested by underlying hemodynamic disorders such as hypovolemia, venous pooling, vigorous contraction of a nearly empty ventricle, and psychic stress. This report describes a malignant form of the typical common faint, combining vasovagal and vasodepressor responses. Hypovolemia or exaggerated venous pooling were not present during sitting; however, the history was positive for modulation of symptoms by psychic stress.

Head-up tilt testing can reproduce these hemodynamic and neuroreflex changes, thus provoking a vasovagal-vasodepressor episode in vulnerable patients. The pathophysiologic mechanisms for hypotension, bradycardia, and subsequent asystole can be explained by stimulation of afferent C-fibers that reside in the base of the left and right ventricle. Activation of these afferent nonmyelinated C-fibers through vigorous contraction of a relatively empty ventricle induces bradycardia and vasodilatation (Bezold-Jarisch reflex).<sup>26</sup> There is associated baroreceptor unloading resulting in inhibition of baroreceptor-mediated vasoconstriction and further hypotension.<sup>27</sup> The head-up tilt test may provoke vasovagal syncope by initiation of this reflex through maximal venous pooling. Afferent C-fiber traffic, in the ab-

sense of baroreceptor function, also activates the vomiting center. The combination of these effects in some individuals results in markedly exaggerated vasodilatation and bradycardia.

From this conceptual framework, a logical approach to therapy for patients presenting with recurrent vasovagal-vasodepressor syncope can be synthesized as follows:

1. Alter the frontocortical trigger to autonomic imbalance through behavioral adaptation with education, with medication such as scopolamine or beta blockers, and with behavioral modification.
2. Override or block afferent vagal cardioinhibitory responses with medication.
3. Artificially prevent significant bradycardia and optimize cardiac hemodynamics by maintaining AV synchrony with dual-chambered pacing devices.

The initial step to therapy is patient education, which attempts to alter the influence of psychic stress. If the episodes of loss of consciousness are preceded by pathognomonic warning signs that last for at least 30 seconds, the patient can be instructed in methods to abort the attacks by assuming the supine position and initiating vigorous repetitive coughing. Education can also improve the patient's ability to recognize the premonitory symptoms and modulate vasovagal attacks using breathing exercise, mental conditioning, and other biofeedback techniques. Unfortunately, in the malignant form of vasovagal syncope, the prodrome is too short and the subsequent syncopal episode may be too dangerous to depend on these techniques.

Management of hypovolemia and exaggerated venous pooling can also decrease vulnerability to vasovagal and vasodepressor syncope.<sup>10</sup> This patient did not have these problems; however, even patients with normovolemia and absence of exaggerated venous pooling may improve with measures to increase blood volume, such as a generous salt diet, support stockings, or salt-retaining mineralocorticoids (hydrofluorocortisone). Waist-high support stockings and a high salt intake are often advised as initial therapy for patients presenting primarily with vasodepressor syncope.

Atropine-like drugs have been useful for patients with vasovagal syncope without preceding exaggerated sympathetic overstimulation or blood volume abnormalities. Clinically, we have used multiple anticholinergic agents including sublingual and orally administered atropine-like drugs such as glycopyrrolate (Robinul) and methscopolamine bromide (Pamine). However, we have been most impressed with our experience with Transderm-Scop.<sup>10</sup>

The exact mechanism of action of scopolamine is un-

clear. Although its parasympatholytic effects are probably significant, administration does not induce a significant change in baseline heart rate. Scopolamine may cause some exaggerated chronotropic response to head-up tilt.<sup>28</sup> Possibly its major pharmacologic effect relates to its central depressant effect on central nervous system transmission to the autonomic nervous system. This appears to be scopolamine's most likely therapeutic mechanism for managing motion sickness. It is of interest that afferent C-fiber traffic from the ventricle also activates the vomiting center in a way similar to that occurring with motion sickness.

Our clinical observation combined with follow-up tilt test supports the possible beneficial effects of scopolamine for patients with recurrent vasovagal-vasodepressor syncope, even in the absence of permanent pacing. We have recently reported a series of patients undergoing head-up tilt before and during scopolamine treatment.<sup>10</sup> Scopolamine was administered as a transcutaneous patch to be changed every other day. As Transderm-Scop does not have FDA approval for this use, patients are informed of the investigational nature of their therapy. The beneficial effects of scopolamine as assessed by head-up tilt data correlated well with the clinical results in these patients.

Nonpharmacologic modalities have also been used in the management of this disorder. Our patient received a permanent dual-chamber pacing system because of the severity of his asystolic episodes. Two subsequent tilt-table tests in the absence of scopolamine demonstrated persistence of vasovagal and vasodepressor syncope despite normal dual-chamber pacing at rates of 50 and 70 beats per minute. The efficacy of artificial pacing and the prevention of vasovagal syncope is a matter of controversy, as published clinical results are quite variable.<sup>29-31</sup> Similar controversy relates to permanent pacing for patients with syncope and carotid sinus hypersensitivity.<sup>32</sup> Our observations in this patient and others demonstrate that bradycardia is usually preceded by hypotension and presyncope in patients with vasovagal-vasodepressor syncope. However, severe bradycardia clearly makes symptoms worse. The efficacy of single- or dual-chamber pacing systems would thus be limited to the contribution of bradycardia to the patient's hypotension.

In patients with malignant vasovagal syncope, as demonstrated by this case, we recommend permanent pacing as adjunctive therapy. It should be emphasized to each patient that permanent pacing is designed to prevent bradycardia only and should not be expected to prevent the presyncopal symptoms associated with hy-

potension in the vasodepressor aspects of this syndrome. Currently, we limit the use of pacemakers to patients in whom other forms of therapy have failed or as adjunctive therapy in patients who develop frighteningly long periods of cardiac standstill during their vagal episodes.

Dual-chamber pacing systems are preferred for several reasons. First, maintenance of AV synchrony during the bradycardia episode enhances ventricular filling by maintaining a properly timed atrial kick. Second, maintenance of normal AV synchrony should decrease the likelihood of augmented vasodepressor responses from

atrial stretch receptors due to atrial contraction against closed AV valves, as occurs with ventricular pacing and the pacemaker syndrome. Third, if symptoms persist following implantation of a standard VVI pacing system, the diagnostic possibility of pacemaker syndrome being responsible for the symptoms exists. This may lead to difficult and expensive diagnostic studies as well as reoperation for upgrading the single-chamber system to a dual-chamber unit. Finally, single-chamber atrial pacing should be avoided because vagally mediated AV block may occur during vasovagal syncope.

## REFERENCES

- Braham J, Hertzeanu H, Yahini JH, Neufeld HN. Reflex cardiac arrest presenting as epilepsy. *Ann Neurol* 1981; **10**:277-278.
- Herlevsen P, Andersen PT. Constitutional predisposition to vasovagal syncope: an additional risk factor in patients exposed to electrical injuries? *Br Heart J* 1987; **57**:284-285.
- Tizes R. Cardiac arrest following routine venipuncture. *JAMA* 1976; **236**:1846-1847.
- Schlesinger Z, Barzilay J, Stryker D, Almog CH. Life-threatening "vagal reaction" to emotional stimuli. *Isr J Med Sci* 1977; **13**:59-61.
- Schlesinger Z. Life threatening "vagal reaction" to physical fitness test. *JAMA* 1973; **226**:1119.
- Frohlich ED, Tarazi RC, Ulrych M, Dustan HP, Page IH. Tilt test for investigating a neural component in hypertension. Its correlation with clinical characteristics. *Circulation* 1967; **36**:387-393.
- Abi-Samra FM, Maloney JD, Fouad FM, Castle LW. Vasovagal and vasodepressor syncope: abnormalities in blood volume and its distribution (abstr). *Circulation* 1985; **72** (suppl III):251.
- Abi-Samra FM, Fouad FM, Bravo EL, Maloney JD, Castle LW. Vasovagal syncope: vagal overtone or lack of sympathetic stimulation? (abstr). *Circulation* 1986; **74** (suppl II):182.
- Fouad FM, Tarazi RC, Bravo EL. Orthostatic hypotension: clinical experience with diagnostic tests. *Cleve Clin Q* 1985; **52**:561-568.
- Abi-Samra FM, Fouad FM, Sweeney PJ, Maloney JD. Syncope: a practical diagnostic approach. [In] Furlan AJ, ed. *The Heart and Stroke: Exploring Mutual Cerebrovascular and Cardiovascular Issues*. New York, Springer-Verlag, 1987, pp 249-283.
- Fouad FM, Tadena-Thome L, Bravo EL, Tarazi RC. Idiopathic hypovolemia. *Ann Int Med* 1986; **104**:298-303.
- Fouad FM, Maloney JD. Orthostatic hypotension: circulatory dynamics and clinical spectrum. [In] Furlan AJ, ed. *The Heart and Stroke: Exploring Mutual Cerebrovascular and Cardiovascular Issues*. New York, Springer-Verlag, 1987, pp 235-248.
- Sundkvist G, Lilja B, Almér LO. Deep breathing, Valsalva, and tilt table tests in diabetics with and without symptoms of autonomic neuropathy. *Acta Med Scand* 1982; **211**:369-372.
- Sundkvist G, Almér LO, Lilja B. A sensitive orthostatic test on tilt table, useful in the detection of diabetic autonomic neuropathy. *Acta Med Scand* 1981; **656** (suppl):43-45.
- Frohlich ED, Tarazi RC, Dustan HP. Hyperdynamic beta-adrenergic circulatory state: increased beta-receptor responsiveness. *Arch Int Med* 1969; **123**:1-7.
- Kearney RE, Hunter IW, Weiss PL, Spring K. Tilt table/ankle-actuator system for the study of vestibulospinal reflexes. *Med Biol Eng Comput* 1983; **21**:301-305.
- Kenny RA, Lyon C, Ingram A, Morley C, Lightman SL, Sutton R. Enhanced vagal activity and normal AVP response in carotid sinus syndrome (abstr). *Clin Prog Electrophysiol Pacing* 1986; **4**(suppl):61.
- Hammill SC, Holmes DR Jr, Wood DL, et al. Electrophysiologic testing in the upright position: improved evaluation of patients with rhythm disturbances using a tilt table. *J Am Coll Cardiol* 1984; **4**:65-71.
- Tarazi RC, Frohlich ED, Dustan HP. Plasma volume in men with essential hypertension. *New Engl J Med* 1968; **278**:762-765.
- Fouad FM, MacIntyre WJ, Tarazi RC. Noninvasive measurement of cardiopulmonary blood volume. Evaluation of the centroid method. *J Nucl Med* 1981; **22**:205-211.
- Eagle KA, Black HR, Cook EF, Goldman L. Evaluation of prognostic classifications for patients with syncope. *Am J Med* 1985; **79**:455-460.
- Kapoor WN, Karpf M, Wieand S, Peterson JR, Levey GS. A prospective evaluation and follow-up of patients with syncope. *New Engl J Med* 1983; **309**:197-204.
- Day SC, Cook EF, Funkenstein H, Goldman L. The evaluation and outcome of emergency room patients with transient loss of consciousness. *Am J Med* 1982; **73**:15-23.
- Engle GL. Psychologic stress, vasodepressor (vasovagal) syncope, and sudden death. *Ann Int Med* 1978; **89**:403-412.
- Levine SR, Patel VM, Welch KMA, Skinner JE. Are heart attacks really brain attacks? [In] Furlan AJ, ed. *The Heart and Stroke: Exploring Mutual Cerebrovascular and Cardiovascular Issues*. New York, Springer-Verlag, 1986, pp 185-216.
- Mark AL. The Bezold-Jarisch reflex revisited: clinical implications of inhibitory reflexes originating in the heart. *J Am Coll Cardiol* 1983; **1**:90-102.
- Thoren P. Vagal depressor reflexes elicited by left ventricular C-fibers during myocardial ischemia in cats. [In] Schwartz PJ, Brown AM, Malliani A, Zanchetti A, eds. *Neural Mechanisms in Cardiac Arrhythmias*. New York, Raven Press, 1978, pp 179-190.
- Jaeger FJ, Fouad-Tarazi FM, Abi-Samra FM, Cruse RF, Castle LW, Maloney JD. Transdermal scopolamine for the treatment of vasovagal syncope (abstr). *Clin Res* 1987; **35**:832A.
- Kenny RA, Bayliss J, Ingram A, Sutton R. Head-up tilt: a useful test for investigating unexplained syncope. *Lancet* 1986; **1**:1352-1355.
- McLaran CJ, Gersh BJ, Osborn MJ, et al. Increased vagal tone as an isolated finding in patients undergoing electrophysiologic testing for recurrent syncope: response to long term anticholinergic agents. *Br Heart J* 1986; **55**:53-57.
- Sapire DW, Casta A, Safley W, O'Riordan AC, Balsara RK. Vasovagal syncope in children requiring pacemaker implantation. *Am Heart J* 1983; **106**:1406-1411.
- Hartzler GO, Maloney JD. Cardioinhibitory carotid sinus hypersensitivity: intracardiac recordings and clinical assessment. *Arch Intern Med* 1977; **137**:727-731.