

The captopril tests: a new concept in detecting renovascular hypertension?

JOSEPH V. NALLY, MD

■ An undetermined percentage of the 60 million hypertensive Americans have potentially correctable renovascular hypertension (RVHT). Conventional plasma renin activity (PRA) determinations and radionuclide renography have limited sensitivity and specificity as screening tests for RVHT. Angiotensin-converting enzyme inhibition with captopril stimulates renin secretion and causes transient decreases in glomerular filtration rate and effective renal plasma flow within the stenotic kidney. Review of recent studies in hypertensive patients suggests that captopril stimulation of both PRA determinations and conventional renography may enhance the sensitivity and specificity of these studies in detecting RVHT.

□ INDEX TERM: CAPTOPRIL □ CLEVE CLIN J MED 1989; 56:395-401

RENOVASCULAR hypertension (RVHT) is the leading cause of potentially correctable hypertension, aside from oral contraceptive use and excessive alcohol consumption. Recent advances in percutaneous renal angioplasty and surgery have stimulated renewed interest in noninvasive ways to screen for this form of hypertension. This discussion focuses on diagnostic uses of angiotensin-converting enzyme (ACE) inhibition coupled with either measurements of plasma renin activity (PRA) or conventional renal scans in the diagnosis of RVHT.

The true prevalence of RVHT is controversial, ranging from <1% in the general hypertensive population to 4%–20% in a subset of patients referred to specialty centers for evaluation of hypertension.¹ One must be extremely careful in distinguishing between renal artery

stenosis (RAS) and RVHT. By definition, RAS is simply the anatomic abnormality of the renovascular bed, which is not particularly uncommon in our aging population or in those with generalized vascular disease. In contrast, RVHT is defined as the anatomical lesion of RAS (either due to atherosclerosis or fibromuscular hyperplasia) coupled with evidence of renin-dependency of the hypertension.

Dating back to the pivotal experiments of Goldblatt et al,² studies in experimental models and in patients have provided compelling evidence for the important pathophysiologic role of the renin-angiotensin-aldosterone system (RAAS) in the development and maintenance of RVHT. The development of pharmacologic inhibitors of the renin-angiotensin system has provided insights into the pathophysiology and diagnosis of RVHT. Application of these concepts is now available to today's clinician for diagnostic use in evaluating the hypertensive patient.

From the Department of Hypertension and Nephrology, The Cleveland Clinic Foundation. Submitted Jan 1989; accepted Feb 1989.

Address reprint requests to Department of Hypertension and Nephrology, The Cleveland Clinic Foundation, One Clinic Center, 9500 Euclid Avenue, Cleveland, Ohio 44195.

GENERAL SCREENING

Tools available to the clinician for the diagnosis of

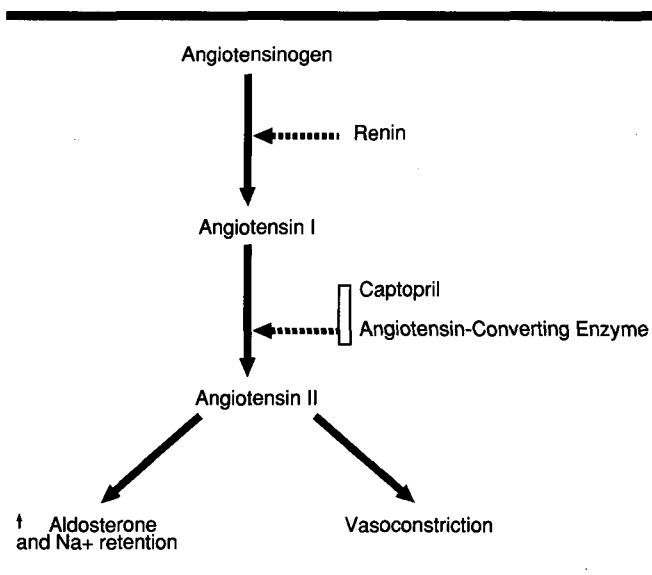


FIGURE 1. The renin-angiotensin system.

TABLE 1
INDICATIONS FOR MORE EXTENSIVE HYPERTENSIVE
EVALUATION

Age <30 years
Diastolic blood pressure >130 mmHg
Abrupt onset or exacerbation of hypertension
Resistant hypertension
Hypertensive retinopathy Grade III or IV
Systolic-diastolic bruit in the epigastrium
Onset of diastolic hypertension after age 55

RVHT include a thorough medical history and physical examination, routine laboratory studies, and more specialized technology to image the kidneys and the renovascular bed.¹ The medical history and physical examination remain the keystones in developing an index of suspicion for RVHT. The clinician must give special attention to the patient's age at onset of hypertension, abrupt onset or accelerated hypertension, and resistant hypertension on an appropriate medical regimen, as well as to indicative signs in the optic fundi and target organs, and to vascular bruits (Table 1).

Routine laboratory testing is often nondiagnostic. The absence of renal parenchymal disease and the presence of unprovoked hypokalemia may be diagnostic clues. A determination of baseline PRA indexed against urinary sodium excretion was initially touted as a potentially helpful tool in the diagnosis of renin-dependent hypertension; however, because of the significant percentage (15%–20%) of patients with essential hypertension who had elevated PRA, the sensitivity and speci-

ficity of the test has been found to be suboptimal. Similarly, imaging the kidneys with either the hypertensive intravenous pyelogram (IVP) or conventional Hippuran (sodium *o*-iodohippurate) renogram also suffered from a limited sensitivity and specificity of approximately 75% to 85%.^{3,4} A recent review of intravenous digital subtraction angiography suggested that this new, more invasive technology did not improve the diagnostic ability or cost-effectiveness over the hypertensive IVP.⁵

More recently, the pharmacological challenge of ACE inhibition with captopril has been coupled with determinations of peripheral PRA and conventional renography in an effort to enhance the sensitivity and specificity of these studies in detecting RVHT.

RESPONSE TO ACE INHIBITION IN RVHT

ACE inhibition with captopril acts to interrupt the RAAS, as depicted in Figure 1. The consequences of this pharmacological blockade can be viewed from two perspectives—either hormonal or hemodynamic. First, captopril may result in an elevation of renin concentration that is active proximal to the site of blockade. This response forms the basis of the captopril-stimulated peripheral and renal vein PRA tests. Second, captopril also blocks the conversion of angiotensin I to angiotensin II and thereby blunts the powerful vasoconstrictor actions of angiotensin II. A clinical clue to the presence of RVHT may be a pronounced antihypertensive response to ACE inhibition in selected hypertensive patients.

Additionally, attenuation of the intrarenal effects of angiotensin II may alter resistance and renal function within the affected kidney. This latter pathophysiologic response to ACE inhibition may explain the acute renal insufficiency observed in patients with bilateral RAS or stenosis of a solitary kidney, who are given ACE inhibitors.^{6–8} This same intrarenal response to ACE inhibition also forms the basis for the captopril-stimulated renograms in the diagnosis of RVHT.

CAPTAPRIL PRA TEST

The rationale for this test is to assess the hyperreninemic response to the pharmacologic challenge of ACE inhibition, to identify patients with RVHT v essential hypertension or other forms of secondary hypertension. The early studies of Case and Laragh⁹ demonstrated that intravenous ACE inhibition with teprotide (or the A II-competitive antagonist saralasin) distinguished between patients with RVHT v essential hyper-

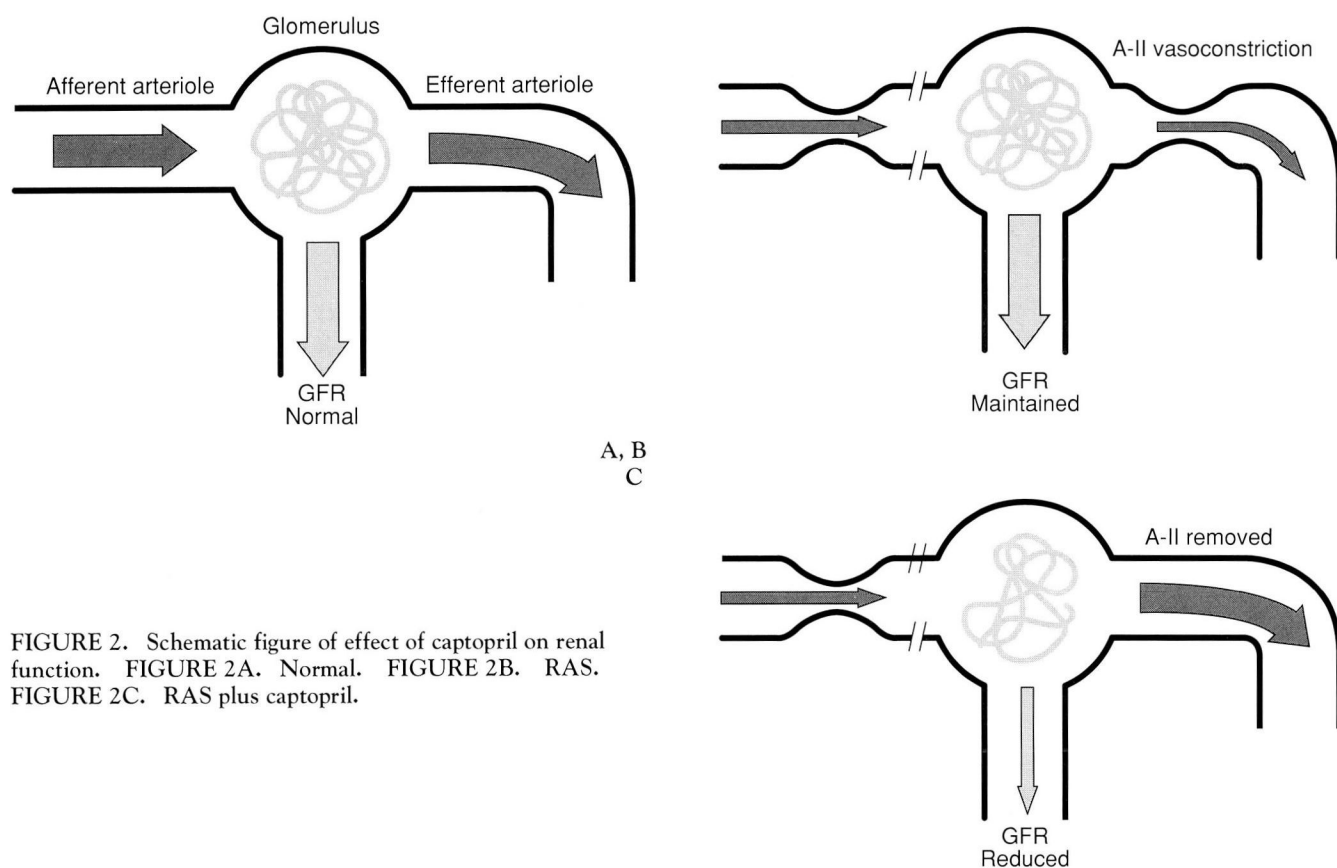


FIGURE 2. Schematic figure of effect of captopril on renal function. FIGURE 2A. Normal. FIGURE 2B. RAS. FIGURE 2C. RAS plus captopril.

tension. It appeared that the hyper-reninemic response to captopril was a better discriminator than an exaggerated fall in blood pressure in separating these two groups. In fact, captopril stimulation appeared to enhance the diagnostic value over baseline PRA values. A subsequent study suggested that oral captopril could result in a similar diagnostic response with high degrees of sensitivity and specificity, although the same conclusion could not be drawn from other preliminary studies.^{10,11}

Muller et al¹² observed blood pressure and PRA responses to oral captopril in 246 hypertensive patients with essential hypertension, RVHT, and other secondary forms of hypertension. For their clinical protocol, the patients maintained a normal salt intake and did not receive diuretics. If possible, all antihypertensive medications were withdrawn three weeks prior to testing. The patients were seated quietly for 30 minutes, blood pressure was measured, and blood was sampled for determination of peripheral PRA. Captopril was then administered orally (25–50 mg crushed and diluted in 10 mL of

water). Blood pressure was then monitored frequently over the next hour. Venous blood was sampled at 60 minutes for determination of captopril-stimulated PRA.

In a retrospective analysis of the data, the following criteria were developed to exploit the hyper-responsiveness of renin secretion in the RVHT patients:

1. A 60-minute post-captopril PRA of >12 ng/mL/h,
2. An absolute PRA increase of 10 ng/mL/h or more, or
3. A 150% increase in PRA (or 400% increase if baseline PRA <3 ng/mL/h).

Retrospectively, the application of these criteria identified all 56 patients with proven renovascular disease (100% sensitivity) out of 200 hypertensive patients with preserved renal function. In this group, false-positive results occurred in only two of 112 patients with essential hypertension (98% specificity) and in six with secondary hypertension. The test was neither as sensitive nor as specific in the 46 patients with renal insufficiency defined as a serum creatinine value ≥ 2 mg/100 mL. The

tests were also less sensitive and specific in the patients who required antihypertensive therapy during the time of testing. The antihypertensive response to captopril could not distinguish predictably between the patients with RVHT *v* other forms of hypertension.

Overall, this retrospective study demonstrated that the renin response to oral captopril could be a very useful screening test for identifying patients with unilateral or bilateral RVHT. Subsequently, these proposed criteria for the PRA response to captopril have been prospectively evaluated in 100 hypertensive patients (29 with RVHT) at the University of Florida.¹³ This study confirmed the excellent sensitivity (100%) for the captopril-stimulated PRA in a selected hypertensive population referred because of suspicion of RVHT. Specificity of the test was reported to be 79%, and the positive predictive value was 66%.

In contrast, a recent report from France prospectively evaluated the captopril PRA response using a modified protocol in a series of 101 consecutive patients referred for evaluation of possible secondary hypertension.¹⁴ There was considerable overlap of the captopril-stimulated PRA and a high degree of variability of response in patients <40 years old.

Overall, however, the captopril-stimulated PRA test appears to have a great deal of clinical utility in evaluating the hypertensive patient in that it is reasonably safe, noninvasive, and easy to perform.

CAPTAPRIL RENOGRAPHY

Preliminary findings on the effects of captopril stimulation on conventional radionuclide studies of the renovascular bed have also been quite encouraging in identifying patients with renovascular disease. The rationale for the captopril-stimulation radionuclide studies is that captopril removes the angiotensin-II-dependent, efferent arteriolar resistance that results in a reduction in the transcapillary forces driving glomerular filtration and thereby reduces renal function of the kidney distal to the stenosis (*Figure 2*). It has been postulated that when renal perfusion pressure is reduced, as seen in RAS, the transcapillary pressures that maintain the forces to drive glomerular filtration are sustained by a preferential increase in efferent arteriolar resistance behind the glomerulus (*Figure 2B*). This increased efferent arteriolar resistance is maintained by angiotensin II. Captopril acts to block the formation of angiotensin II and consequently removes the postglomerular resistance and diminishes the transcapillary forces maintaining filtration so the glomerular filtration rate (GFR) of the af-

fected kidney decreases (*Figure 2C*). This decrement in individual kidney function may then be noninvasively assessed using conventional radionuclide studies.

Assessment of individual kidney function is possible utilizing noninvasive technology with conventional renal scans using either I-131-orthoiodohippurate (Hippuran) or Tc-99m-labeled-diethylenetriaminepentaacetic acid (DTPA). DTPA is excreted via the kidneys solely via glomerular filtration. Because of the superior imaging capabilities of the Tc-99m label, early phases of the DTPA study may also offer an index of renal perfusion and kidney size. On the other hand, the kidney handles I-131-orthoiodohippurate as it does para-aminohippurate (PAH) with excretion by both glomerular filtration and tubular secretion such that its clearance is a marker of effective renal plasma flow (ERPF). I-131-orthoiodohippurate has a very high extraction ratio and excretion after it is delivered to the kidney, which could be advantageous for renal imaging. Unfortunately, the I-131 label suffers from suboptimal imaging characteristics. In the near future, Tc-99m-labeled mercaptopacetyl triglycine, which is excreted via the kidney in a fashion similar to PAH or orthoiodohippurate, should become clinically available for renography. It may offer both advantageous Tc-99m labeling characteristics and suitability for estimating renal plasma flow.

Several parameters of the renograms may be analyzed to assess kidney perfusion, size, and function, including scintiphotographs as an estimate of renal perfusion and size, time-activity curves of the individual kidneys, and kidney uptakes as an estimation of GFR (DTPA) or ERPF (I-131-orthoiodohippurate). Abnormalities in the unstimulated renograms that suggest the presence of renovascular disease include reduction in kidney perfusion and size, as well as delay in uptake and excretion of the radionuclide. To date, the captopril-induced changes in the renogram that have been suggested as diagnostic criteria for the stenotic kidney include a reduction/delay in DTPA uptake of the stenotic kidney(s), a delay in the time to maximal activity of the I-131-orthoiodohippurate renogram, and a delay in the I-131-orthoiodohippurate washout ("cortical retention"). Both DTPA and I-131-orthoiodohippurate studies have been advocated for detecting changes after captopril administration.

These changes in the renogram after captopril can be appreciated by reviewing the DTPA time-activity curve in *Figure 3*. The baseline study (*Figure 3A*) demonstrates physiological uptake and excretion of the radionuclide although the peak activity of the left kidney is approximately two-thirds that of the right. Captopril adminis-

A, B

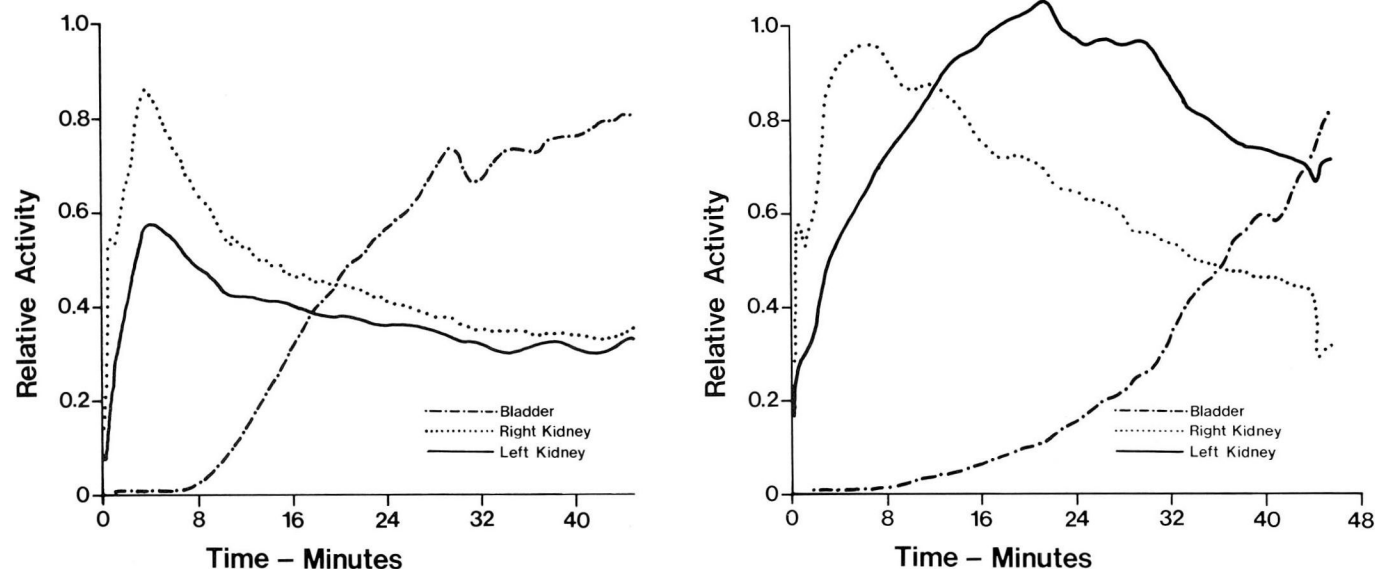


FIGURE 3. Unilateral left RAS. FIGURE 3A. Tc-99m DTPA time-activity curves during baseline. FIGURE 3B. Tc-99m DTPA time-activity following captopril stimulation.

tration results in marked changes in the DTPA study; prolonged uptake, accumulation, and delayed excretion on the left are consistent with a diagnosis of left RAS. Subsequent angiography demonstrated a 75% stenosis on the left with two normal right renal arteries. Successful percutaneous renal angioplasty normalized the patient's blood pressure.

Armed with the understanding of the effects of ACE inhibition upon renal physiology as well as the renal handling of conventional radionuclides, the clinical observations regarding captopril-stimulated renography reported in recent years can be put into perspective. The early studies of Wenting et al¹⁵ involving patients with unilateral RAS or essential hypertension are of particular interest. Changes in ERPF and GFR (as measured by I-131-orthoiodohippurate and I-125-thalamate clearances, respectively) in response to captopril were studied in each group of patients. In patients with unilateral RAS, renal extraction ratios for both I-131-orthoiodohippurate and I-125-thalamate were significantly reduced on the stenotic side after administration of captopril. Total and ipsilateral GFR were reduced, but total ERPF did not decrease. Interestingly, the patients with the greatly reduced single kidney extraction ratios following ACE inhibition had serum creatinine elevation during long-term captopril therapy. Subsequent DTPA uptake was absent on the stenotic side in these

patients, who were maintained on captopril (50 mg daily for 3–5 weeks). Both the loss of renal function and the changes in the DTPA renograms were reversible after captopril was discontinued.

These studies emphasize the value of quantitating individual kidney function in patients with RVHT in response to ACE inhibiting agents or other medical therapies. It must be recognized that total renal function (as assessed by serum creatinine values or other total GFR measurements) may change little in response to ACE inhibition. However, the absence of change of total GFR in unilateral RAS may actually reflect a substantial detrimental reduction of GFR of the stenotic kidney, with a compensatory increase in GFR of the contralateral kidney. Indeed, more recent reports from Japan¹⁶ and Australia¹⁷ using computer-assisted DTPA renography to follow patients with RVHT undergoing chronic therapy with ACE inhibitors documented significant reductions in GFR of the stenotic kidney.

Majd et al¹⁸ first reported that captopril altered the DTPA renograms in four hypertensive children suspected of having RAS.¹⁸ Application of this combined technique for use in screening hypertensive patients was introduced by Oei et al¹⁹ from The Netherlands. Many other preliminary reports have been subsequently issued from both the United States and Europe.^{20–25} Upon review and reflection, several observations that address

clinically relevant points can be gleaned from these reports.

Geyskes et al²⁶ reported their study of 21 hypertensives with angiographically documented unilateral RAS and 13 patients with essential hypertension and normal renal arteries. The hypertensive patients were studied with baseline and captopril-stimulated DTPA and I-131-orthoiodohippurate renography and the patients with unilateral RAS were subsequently treated via technically successful renal angioplasty. Captopril-stimulation of both the DTPA and I-131-orthoiodohippurate renograms appeared to increase the sensitivity of the radionuclide studies and the studies also appeared to be predictive of the response to interventional therapy with angioplasty. Comparative studies are needed to examine the predictive capabilities of captopril renography v conventional renal vein renin determinations in addressing this issue. In contrast, a "negative" captopril renogram may be of great value in guiding the clinical evaluation of the hypertensive patient if subsequent studies confirm that a negative test correlates highly with a poor response to intervention.

In a more recent series, Fommei et al²⁷ evaluated 42 patients referred for evaluation of possible RVHT. Of the patients with normal renal arteries, 24 of the 25 patients (96% specificity) exhibited no changes in the renogram following administration of captopril. Sixteen of the 17 studies were positive in the patients with an-

giographically proven renal artery disease (93% sensitivity). In contrast, the authors noted a high false-positive rate with captopril renography in the patients with underlying glomerulopathies.

These studies underscore the possible higher degrees of sensitivity and specificity with captopril-stimulated renography in hypertensive patients who are appropriately selected on clinical grounds. A recent report²⁸ on patients with angiographically proven RAS suggests that captopril-stimulated renography may be more sensitive as a diagnostic index of RVHT than captopril-stimulated PRA. Further studies to test these observations appear warranted.

SUMMARY

Captopril renography seems to offer promise in the detection of RVHT. Studies published to date tend to be in selected series of patients who generally have unilateral RAS. Additional studies using this combined technique in a prospective, randomized fashion to evaluate a referred hypertensive patient population are warranted.

Data from both the captopril-stimulated PRA and captopril renography are preliminary, yet the data suggest their diagnostic sensitivity and specificity may meet or exceed that of the existing clinical tools for the diagnosis of RVHT.

REFERENCES

- Kaplan NM. Renal vascular hypertension. [In] Kaplan NM, ed. Hypertension. 4th ed. Baltimore, Williams & Wilkins, 1986, pp 317-344.
- Goldblatt H, Lynch J, Hanzal RF, Summerville WW. Studies on experimental hypertension; production of persistent elevation of systolic blood pressure by means of renal ischemia. *J Exp Med* 1934; 59:347-379.
- Maxwell MH. Cooperative study of renovascular hypertension: current status. *Kidney Int* 1975; 8(suppl):S153-S160.
- Fine EJ, Scharf SC, Blaufox MD. The role of nuclear medicine in evaluating the hypertensive patient. [In] Freeman LM, Weissman HS, eds. *Nuclear Medicine Annual*, 1984. New York, Raven Press, 1984, pp 23-79.
- Havey RJ, Krumlovsky F, delGreco F, Martin HG. Screening for renovascular hypertension: is renal digital-subtraction angiography the preferred noninvasive test? *JAMA* 1985; 254:388-393.
- Curtis JJ, Luke RG, Welch JD, Diethelm AG, Jones P, Dustan HP. Inhibition of angiotensin-converting enzyme in renal transplant recipients with hypertension. *N Engl J Med* 1983; 308:377-381.
- Hricik DE, Browning PJ, Kopelman R, Goorno WE, Madias NE, Dzaui VJ. Captopril-induced functional renal insufficiency in patients with bilateral renal-artery stenoses or renal-artery stenoses in a solitary kidney. *N Engl J Med* 1983; 308:373-376.
- Blythe WB. Captopril and renal autoregulation. *N Engl J Med* 1983; 308:390-391.
- Case DB, Laragh JH. Reactive hyper-reninemia in renovascular hypertension after angiotensin blockade with saralasin or converting enzyme inhibitor. *Ann Intern Med* 1979; 91:153-160.
- McGrath BP, Matthews PC, Johnston CI. Use of captopril in the diagnosis of renal hypertension. *Aust NZ J Med* 1981; 11:359-363.
- Thibonnier N, Sassano P, Joseph A, et al. Diagnostic value of a single dose of captopril in renin- and aldosterone-dependent, surgically curable hypertension. *Cardiovasc Rev Rep* 1982; 3:1659-1668.
- Muller FB, Sealey JE, Case DB, et al. The captopril test for identifying renovascular disease in hypertensive patients. *Am J Med* 1986; 80:633-644.
- Wilcox CS, Williams CM, Smith TB, Frederickson ED, Wingo C, Bucci CN. Diagnostic uses of angiotensin-converting enzyme inhibitors in renovascular hypertension. *Am J Hypertens* 1988; 1:344S-349S.
- Idrissi A, Fournier A, Renaud N, et al. The captopril challenge test as a screening test for renovascular hypertension. *Kidney Int* 1988; 34(suppl 25):S138-S141.
- Wenting GJ, Tan-Tjong HL, Derckx FHM, de Bruyn JHB, Man in't Veld AJ, Schalekamp MADH. Split renal function after captopril in unilateral renal artery stenosis. *Br Med J* 1984; 288:886-890.
- Miyamori I, Yasuhara S, Takeda Y, et al. Effects of converting enzyme inhibition on split renal function in renovascular hypertension. *Hypertension* 1986; 8:415-421.
- Jackson B, McGrath BP, Matthews PG, Wong C, Johnston CI. Differential renal function during angiotensin converting enzyme inhibition in renovascular hypertension. *Hypertension* 1986; 8:650-654.
- Majd N, Porter BN, Guzzetta PC, Ruley EJ. Effect of captopril on efficacy of renal scintigraphy in detection of renal artery stenosis (abst). *J Nucl Med* 1983; 24:P23.
- Oei H, Geyskes G, Dorhout M, Puijlaert C. Captopril-induced renographic alterations in unilateral renal artery stenosis (abst). *J Nucl*

- Med 1984;25:P36.
20. Geyskes GG, Oei HY, Faber JAJ. Renography: prediction of blood pressure after dilatation of renal artery stenosis. *Nephron* 1986; **44**(suppl 1):54-59.
 21. Hilson A, Frankel AH, Othman S, Sweny P. Captopril-enhanced 99m Tc DTPA studies as a screening test for renovascular disease in the setting of the general nephrology clinic (abst). *J Nucl Med* 1987; **28**:613.
 22. Sfakianakis CN, Bourgoigne JJ, Jaffe D. The effect of captopril on renography in renovascular hypertension (RVH): a predictor of response to angioplasty (abst). *J Nucl Med* 1987; **28**:613.
 23. Fommei E, Ghione S, Palla L, Bertelli P, Marabotti C, Palombo C. The scintigraphic captopril test in renovascular hypertension (abst). *J Nucl Med* 1987; **28**:613-614.
 24. Subramanian K, Sarker S, Mann S, et al. Single dose captopril renography with Tc-99m-DTPA and I-131-hippuran in renovascular hypertension (RVH) (abst). *J Nucl Med* 1987; **28**:735.
 25. Nally JV Jr, Gupta BK, Clarke HS Jr, Higgins JT Jr, Potvin WJ, Gross ML. Captopril renography for the detection of renovascular hypertension: a preliminary report. *Cleve Clin J Med* 1988; **55**:311-318.
 26. Geyskes GG, Oei HY, Puylaert CBAJ, Mees EJD. Renovascular hypertension identified by captopril-induced changes in the renogram. *Hypertension* 1987; **9**: 451-458.
 27. Fommei E, Ghione S, Bertelli P, et al. Renal scintigraphic captopril test: comparison of scintigraphic and angiographic data and preliminary observations in chronic glomerulonephritis (abst). *J Nucl Med* 1988; **29**:907.
 28. Kletter K, Leitha T, Dudczak R. Captopril renography and captopril test in unilateral and bilateral renal artery stenosis (abst). *J Nucl Med* 1988; **29**:850.

