

Results of surgical management of nasopharyngeal angiofibroma

The Cleveland Clinic experience, 1977–1986

JAY K. ROBERTS, MD; GEORGE K. KORONES, MD; HOWARD L. LEVINE, MD; BENJAMIN G. WOOD, MD;
HARVEY M. TUCKER, MD; PIERRE LAVERTU, MD

■ During 1977 through 1986, 15 patients were evaluated and underwent surgery for nasopharyngeal angiofibroma at the Cleveland Clinic Foundation. All were males aged five to 20 years. Diagnoses were established clinically and radiographically. The most common presentations were nasal obstruction and epistaxis. Computed tomographic scans were obtained in almost all cases. In 14 patients, preoperative embolization of the tumor was performed at the time of diagnostic angiography; embolization of tumors made surgical excision easier and reduced blood loss. The most common surgical exposure used was a combination of transpalatal and transantral approaches. Follow-up of one to 10 years showed recurrence in only two patients. One had no further recurrence after subsequent surgery; the other remains asymptomatic with no further progression. The approach to diagnosis and treatment described results in cure for most patients.

□ INDEX TERM: NASOPHARYNGEAL NEOPLASMS □ CLEVE CLIN J MED 1989; 56:529–533

ANGIOFIBROMA is a highly vascular, locally invasive, nonencapsulated tumor that almost always occurs in the posterior nares or nasopharynx of adolescent males.¹ By the time of initial evaluation and treatment, more than 90% of these lesions have extended beyond the nasal cavity and nasopharynx. Ten percent to 20% have invaded the orbit and a similar percentage have extended intracranially.^{2,3}

These uncommon tumors originate on the posterolateral wall of the roof of the nose where the palatine bone meets the vomer and the root of the pterygoid process of the sphenoid bone, which is at the superior margin of the sphenopalatine foramen. The lesion grows submucosally in any direction within the nose and nasopharynx and frequently through the sphenopalatine foramen into the pterygopalatine fossa. As it extends laterally, it can enlarge the infratemporal fossa and cause bulging in the cheek. It may extend into any of the paranasal sinuses, through the inferior orbital fissure into the orbit, and/or, after destroying portions of the sphenoid, into the middle cranial fossa.⁴

From the Department of Otolaryngology and Communicative Disorders, The Cleveland Clinic Foundation. Submitted April 1988; accepted Aug 1988.

Address reprint requests to P.L., Department of Otolaryngology and Communicative Disorders, The Cleveland Clinic Foundation, One Clinic Center, 9500 Euclid Avenue, Cleveland, Ohio 44195-5034.

Although patients can present with a number of different signs and symptoms (*Table 1*), the most common are nasal obstruction, epistaxis, and nasal drainage. Indeed, this triad of symptoms in a pubescent male is vir-

TABLE I
PRESENTING SYMPTOMS AND SIGNS OF NASOPHARYNGEAL ANGIOFIBROMA

Epistaxis
Nasal obstruction
Nasal drainage
Nasal/nasopharyngeal mass
Anosmia
Facial deformity
Headache
Visual loss
Diplopia
Proptosis
Rhinolalia clausa
Otalgia
Otitis media
Hearing loss
Dysphagia
Other cranial nerve symptoms

tually pathognomonic for angiofibroma. Epistaxis can be life-threatening in some patients. On examination, a firm, somewhat grayish mass covered with normal-appearing mucosa is seen in the posterior nares or nasopharynx.

Despite nearly complete male predominance, no significant endocrine abnormalities have been detected. Several investigators have attempted but have been unable to identify estrogen receptors within the substance of the tumor, although testosterone and dihydrotestosterone binding proteins are present.^{5,6} These are thought to have some role in rapid growth of the tumor, which tends to occur around puberty.⁶

Histopathologically, angiofibromata consist of numerous endothelial-lined vascular channels in a fibrous stroma. The vessels vary in size, shape, and distribution. Typically, the vessels are slit-like spaces lined by a single layer of endothelial cells. The stroma consists of coarse and fine collagen fibrils. The tumors tend to become more fibrous and less vascular with time.¹

The Cleveland Clinic experience in the management of 15 patients with histologically proven angiofibroma is reported. Preoperative documentation of extent of disease, methods to minimize blood loss, length of hospital stay, and recurrence and its management are discussed.

PATIENTS

Fifteen patients were treated for nasopharyngeal angiofibroma between 1977 and 1986 at The Cleveland Clinic Foundation Department of Otolaryngology and Communicative Disorders. Their charts and follow-up contacts were reviewed with respect to type of presentation, duration of symptoms, age at diagnosis, diagnostic and treatment modalities, and complications (Table 2).

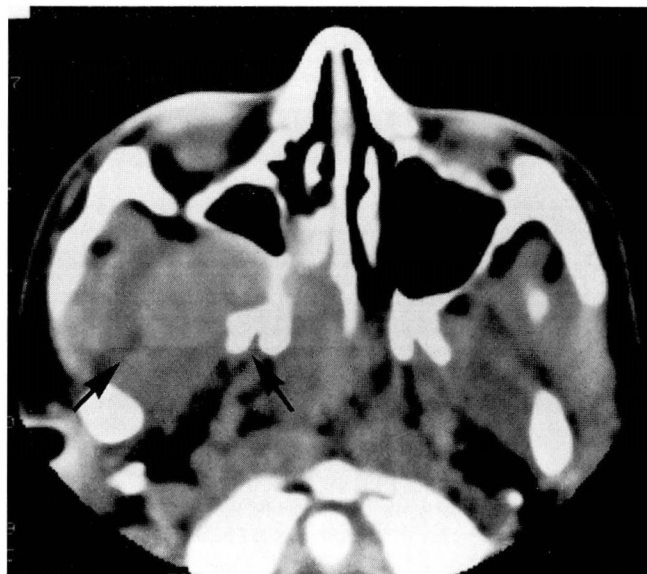

FIGURE 1. Computed tomogram of the nose and paranasal sinuses showing right-sided angiofibroma (on left side of figure). Note mass in right side of nose, nasopharynx, and pterygopalatine fossa, as well as anterior bowing of posterior wall of right maxillary sinus and erosion of anterior aspect of pterygoid plates on right.

All patients were males, aged five to 20 years (mean, 13.2 years).

Thirteen patients presented with nasal obstruction; 12 had epistaxis. Seven complained of nasal discharge, three of hearing loss, and one of voice change. Duration of symptoms was from two to 12 months (mean, eight months). Most patients had been treated symptomatically prior to their referral to the Clinic, although in no case had surgical excision been attempted. Three of six patients treated for epistaxis had required transfusion. Three patients had undergone biopsy (one via a Caldwell-Luc approach), and one was treated with antibiotics for otitis media, presumably because the eustachian tube was obstructed by tumor in the nasopharynx. None had had an attempt at surgical excision.

DIAGNOSTIC PROCEDURES

Diagnostic procedures performed included: computed tomography (CT) (Figure 1) (13 patients), plain tomography (3 patients), plain radiography (2 patients), and magnetic resonance imaging and xeroradiography (1 patient each). Fourteen patients underwent angiography with embolization shortly before surgery. Unilateral blood supply was noted in 11 of the 14, and blood supply

TABLE 2
SUMMARY OF CLINICAL INFORMATION

Case/sex/age (yr)	Symptoms/duration (mo)	Diagnostic procedures	Tumor extension and angiography results	Surgical procedure	Blood loss (mL)	Transfusions	Length of stay (days)	Recurrence	Length of follow-up since most recent treatment (yr)
1/M/15	obstruction, epistaxis/5	CT/A/E	NP/MS/ITF EC and IC	TP/TA	700	1	13		1
2/M/9	obstruction, drainage, epistaxis/6	CT/P/A/E	NP/SS UNI EC	TP/TA	400	0	9		3 1/2
3/M/15	obstruction, drainage, epistaxis/7	B/A/E	NP/MS UNI EC	TP/TA	1500	4	10		10 1/2
4/M/20	obstruction, epistaxis/9	P/CT/A/E	N/NP/SS/ES/SPF UNI EC	TP/TA	900	3	7		10
5/M/18	obstruction, epistaxis/5	R/CT/A/E	NP/NP BIL EC	TP/TA	1200	2	9		9 1/2
6/M/16	obstruction, epistaxis/6	CT/A/E	N/NP/ES/SPF UNI EC	TP/TA	600	0	8		9
7/M/14	obstruction, epistaxis, voice change/5	A/E	N/NP/SPF/ITF/SS/ES UNI EC	TP/TA	500	0	5		1
8/M/20	obstruction/12	CT/X/A/E	N/NP/ES BIL EC	TP	1000	2	9		7 1/2
9/M/10	obstruction, epistaxis/10	CT/A/E	N/NP/SPF/ITF UNI EC	TP/TA	400	1	6		7
10/M/17	epistaxis/12	CT/A/E	NP/SPF/ITF BIL EC	TA	1300	1	6	at 15 mo; asymptomatic; in N/NP/SPF/ITF	1
11/M/5	drainage, hearing loss/7	C/CT/A/E	N/NP/MCF/ITF/SPF/O EC and IC	MFC/TP/TA	3500	6	10	at 29 mo; asymptomatic; in SS/SPF/ITF	3 1/2
12/M/13	obstruction, drainage, hearing loss/2	R/CT/MRI/A/E	N/NP/SPF/ITF/MCF UNI EC	BEC/TP/TA	1800	4	12		2
13/M/18	obstruction, drainage, epistaxis/12	CT/D/SA/A/E	N/NP/SPF UNI EC	TP/TA	400	0	6		2
14/M/14	obstruction, drainage, epistaxis, hearing loss/12	CT/A/E	N/NP/SPF/ITF/O UNI EC	TP/TA	900	1	7		1
15/M/15	obstruction, drainage, epistaxis/6	CT	N/NP/ES/SS	TP	900	0	3		1

A = angiography
 B = biopsy
 BIL EC = tumor supplied by branches of both external carotids
 BFC = bifrontal craniotomy
 CT = computed tomography
 DSA = digital subtraction angiography
 E = embolization
 EC and IC = tumor supplied by branches of both external and internal carotids
 ES = ethmoid sinus
 ITF = infratemporal fossa
 MCF = middle fossa craniotomy
 MRI = magnetic resonance imaging
 MS = maxillary sinus
 N = nasal cavity
 NP = nasopharynx
 O = orbit
 P = plain tomography
 R = plain radiograph
 SPF = sphenopalatine (pterygopalatine) fossa
 SS = sphenoid sinus
 TA = transantral
 TP = transpalatal
 UNI EC = tumor supplied by branches of ipsilateral external carotid
 X = xerogram

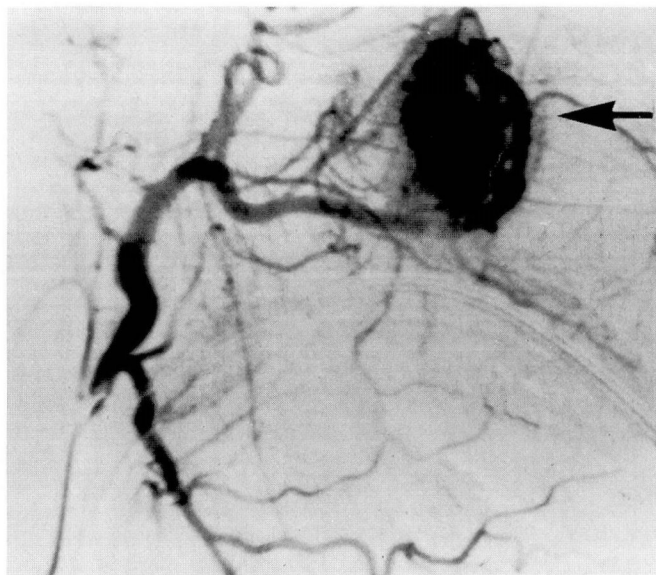


FIGURE 2. Pre-embolization angiogram of right external carotid arterial system, showing vascular mass fed by the internal maxillary artery.

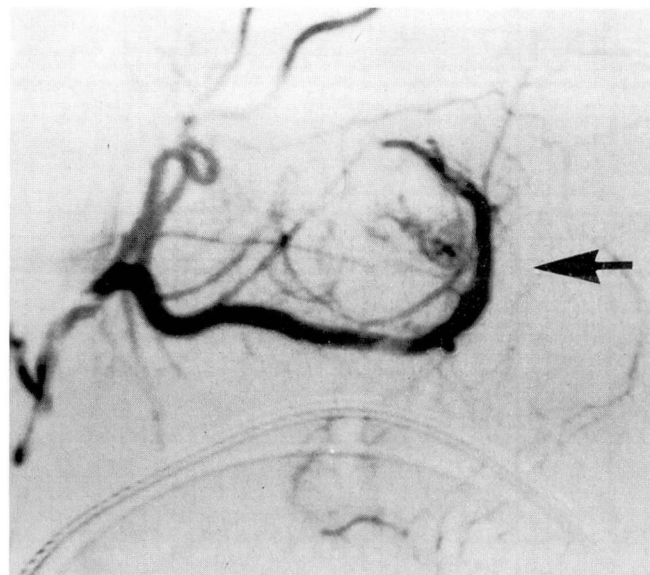


FIGURE 3. Faint tumor blush is apparent after embolization.

derived partly from the internal carotid system was noted in two. Pre- and post-embolization angiograms are shown in *Figures 2 and 3*.

SURGICAL PROCEDURES

The surgical exposure most often used was a combination of the transpalatal and transantral approaches. One patient required bifrontal craniotomy and another required middle fossa craniotomy for complete excision. Pathological examination confirmed angiofibroma in all cases.

Blood loss ranged from 400 to 3500 mL (mean, just over 1000 mL). Ten of the 15 patients lost 1 L of blood or less and only one lost more than 2 L (3.5 L). Five patients received no transfusions. Four patients received one transfusion each, and six received more than one. Total units of blood transfused ranged from zero to six per patient (mean, 1.7 units/patient).

The length of hospitalization ranged from three to 13 days (mean, eight days).

FOLLOW-UP

Duration of follow-up for these patients has been from one to 10 years after surgery (mean, 4.6 years). Four patients were lost to follow-up between 12 and 18 months after surgery.

Two of the 15 patients had recurrence of angiofibroma. A 17-year-old patient had evidence of tumor in the nose, nasopharynx, pterygopalatine fossa, and infratemporal fossa 15 months after surgery. Angiography with embolization was followed by transantral excision; 600 mL of blood was lost and no transfusions were needed. There has been no further recurrence in 3.5 years.

The youngest patient in the series (age five years) had an asymptomatic recurrence 29 months after excision of the tumor, which originally extended into the orbit and middle cranial fossa. A recurrence in the right sphenoid wing and sphenoid sinus was noted on a CT scan obtained to determine the cause of the patient's headaches. Serial CT scans have shown no further growth in one year.

Postsurgical complications occurred in six patients. Two had palatal fistulas, which closed spontaneously in one case and required surgical repair in the other. Two patients had nasal synechiae, one of which required lysis for symptoms of nasal obstruction. Two patients had nasal regurgitation and rhinolalia aperta, which resolved without treatment within a few weeks of surgery.

DISCUSSION

Angiofibroma can often be distinguished clinically from other nasopharyngeal tumors on the basis of symptoms, physical findings, and the age and sex of the patient. Classically, anterior bowing of the posterior maxillary wall as seen on plain sinus radiographs suggests the diagnosis. Today, CT scanning, angiography

with or without embolization, and biopsy (only at the time of definitive surgery) are the tools most commonly used in the diagnosis of angiofibroma.⁷⁻⁹ Because the characteristics of angiofibroma are consistently seen on CT, this is the logical first step in diagnosis.

Further confirmation of the diagnosis is obtained by carotid angiography. Angiography has also been valuable in identifying unexpected blood supply from the internal carotid artery. Tumors that have significant blood supply from the internal carotid artery system cause greater blood loss and are much more difficult to deal with.

Embolization changes the consistency of the angiofibroma, making it easier to remove surgically. Since it has been shown that embolization on the day of surgery decreases blood loss by up to two thirds,⁷ it should be carried out no longer than 24 hours before surgery. Embolization is especially important in patients whose hemoglobin level is low because of recurrent epistaxis. Also, because of the potential for bleeding, biopsy should be deferred until the time of definitive surgery unless previous studies suggest that the mass is not vascular.

In the past, treatment has included electrocoagulation, injection of sclerosing agents, cryosurgery, hormone therapy, radiation therapy, and surgery with or without embolization, hypothermia, or hypotensive anesthesia.^{3,10-12} Hypothermic anesthesia, hypotensive anesthesia, ligation of the external carotid artery, and cryosurgery have all been of questionable value.¹⁰⁻¹⁴ Observation alone has not been a satisfactory method of management.¹²

Although an earlier report has not shown an advantage to the use of radiation therapy,¹⁵ researchers at Princess Margaret Hospital in Toronto have reported encouraging results; 80% permanent tumor control was achieved in 55 patients following a single course of 3000 to 3500 cGy during a three-week period.³ However, the possibility of the development of a malignancy secondary to radiation therapy is a concern throughout the remainder of the patient's life. Delayed development of thyroid carcinoma, malignant transformation of angiofibroma, and development of sarcoma within the field have all been reported after radiation therapy for angiofibroma.^{3,16-18} Patients who are operated on after radiation failure or who have had preoperative endocrine therapy tend to have decreased blood loss.^{10,11}

Prompt surgical intervention is now the favored approach to the treatment of angiofibromas. The recurrence rate of these tumors as seen in our data and as reported in the literature is less than 20% after surgical removal.^{8,9,11,19} Treatment of symptomatic recurrences by surgery and/or radiation therapy brings the overall survival rate to approximately 95%.

CONCLUSIONS

The results of management of 15 patients with juvenile angiofibroma support primary surgical resection as the method of choice for control of this tumor. Embolization reduces blood loss and simplifies tumor removal. Biopsy should be withheld until the time of definitive surgery.

REFERENCES

- Batsakis JG, Tumors of the Head and Neck, 2nd ed. Baltimore, Williams & Wilkins, 1979, pp 296-300.
- Ward PH, Thompson R, Calcatera T, Kadin MR. Juvenile angiofibroma: a more rational therapeutic approach based upon clinical and experimental evidence. *Laryngoscope* 1974; **84**:2181-2194.
- Cummings BJ, Blend R, Keane T, et al. Primary radiation therapy for juvenile nasopharyngeal angiofibroma. *Laryngoscope* 1984; **94**:1599-1605.
- Schiff M. Juvenile nasopharyngeal angiofibroma. *Laryngoscope* 1959; **69**:981-1016.
- Johns ME, MacLeod RM, Cantrell RW. Estrogen receptors in nasopharyngeal angiofibromas. *Laryngoscope* 1980; **90**:628-634.
- Lee DA, Roa BR, Meyer JS, Prioleau PG, Bauer WC. Hormonal receptor determination in juvenile nasopharyngeal angiofibromas. *Cancer* 1980; **46**:547-551.
- Waldman SR, Levine HL, Astor F, Wood BG, Weinstein M, Tucker HM. Surgical experience with nasopharyngeal angiofibroma. *Arch Otolaryngol* 1981; **107**:677-682.
- Chandler JR, Goulding R, Moskowitz L, Quencer RM. Nasopharyngeal angiofibromas: staging and management. *Ann Otol Rhinol Laryngol* 1984; **93**:322-329.
- Harrison DFN. The natural history, pathogenesis and treatment of juvenile angiofibroma. *Arch Otolaryngol Head Neck Surg* 1987; **113**:936-942.
- Conley J, Healy WV, Blaugrund SM, Perzin KH. Nasopharyngeal angiofibroma in the juvenile. *Surg Gynecol Obstet* 1968; **126**:825-837.
- Jafek BW, Nahum AM, Butler RM, Ward PH. Surgical treatment of juvenile nasopharyngeal angiofibroma. *Laryngoscope* 1973; **83**:707-720.
- Pressman JJ. Nasopharyngeal angiofibroma removal with hypothermia. *Arch Otolaryngol* 1962; **76**:167-173.
- Maniglia AJ, Mazzarella LA, Minkowitz S, Moskowitz H. Maxillary sinus angiofibroma treated with cryosurgery. *Arch Otolaryngol* 1969; **89**:527-532.
- Smith MFW, Boles R, Work WP. Cryosurgical techniques in removal of angiofibromas. *Laryngoscope* 1964; **74**:1071-1080.
- Neel HB III, Whicker JH, Devine KD, Weiland LH. Juvenile angiofibroma: review of 120 cases. *Am J Surg* 1973; **126**:547-556.
- Spagnolo DV, Papadimitriou JM, Archer M. Postirradiation malignant fibrous histiocytoma arising in juvenile nasopharyngeal angiofibroma and producing alpha-1-antitrypsin. *Histopathology* 1984; **8**:339-352.
- Chen KTK, Bauer FW. Sarcomatous transformation of nasopharyngeal angiofibroma. *Cancer* 1982; **49**:369-371.
- Donald PJ. Sarcomatous degeneration in a nasopharyngeal angiofibroma. *Otolaryngol Head Neck Surg* 1979; **87**:42-46.
- Antonelli AR, Cappiello J, Di Lorenzo D, Donajo CA, Nicholai P, Orlandini A. Diagnosis, staging, and treatment of juvenile nasopharyngeal angiofibroma (JNA). *Laryngoscope* 1987; **97**:1319-1325.