

Complex partial seizures in children

Clinical manifestations and identification of surgical candidates

ELAINE WYLLIE, MD AND HANS LÜDERS, MD, PHD

COMPLEX partial seizures (CPS) are not infrequent in children. The majority of adults with CPS had the onset of their epilepsy before the age of 20 years;¹ and among children with epilepsy, the seizure type is complex partial in approximately 13% to 25% of patients.²⁻⁴ CPS are often intractable to medication, leading to thoughts of possible surgery; and in fact, many of these patients do have a single resectable epileptogenic focus. This review will address some considerations in the identification of pediatric epilepsy surgery candidates and the timing of operation.

DEFINITIONS

The hallmark of partial seizures in children and adults is focal epileptiform discharges localized to a portion of one cerebral hemisphere. With the current classification system, partial seizures are further divided into "simple" or "complex" types: complex partial seizures include impairment of consciousness, and simple partial seizures do not.⁵ The impairment of consciousness during CPS may occur at onset of the episode or after an initial simple partial seizure with preserved consciousness. When the preceding simple partial seizure is sensory, it is sometimes called an aura.

With this classification system, "complex" does not mean "complicated," and this variance from the collo-

quial meaning of the word has caused some confusion.^{6,7} Another problem has been that the ictal level of consciousness may be difficult to assess, especially in young children. However, the basic distinction between simple and complex partial seizures may be useful in that it identifies those seizures that have the very disabling symptom of altered consciousness. As the patient grows older, altered consciousness takes on added importance with considerations about driving and performance in the school or workplace. In this review, we will concentrate on the clinical features of CPS. A discussion of simple partial seizures, which are more commonly seen in extratemporal epilepsy, may be found elsewhere.⁶

Patients may also be grouped not just by type of seizure but by type of epilepsy. This classification system groups patients according to clinical, electrographic, radiographic, and pathologic findings. In the current International Classification,⁸ the partial or focal epilepsies are called "localization-related epilepsies."

The localization-related epilepsies may be further subdivided, according to a simplified scheme,⁶ into temporal lobe epilepsy and extratemporal epilepsy. Patients with temporal lobe epilepsy have seizures arising from the temporal lobe, with epileptiform discharges from that region on the electroencephalogram (EEG); and patients with extratemporal epilepsy have seizures arising from frontal, parietal, or occipital regions. Children with temporal lobe epilepsy typically have CPS, but not all children with CPS have temporal lobe epilepsy. Some children with CPS may instead have extratemporal epilepsy. Intensive EEG evaluation

Section of Epilepsy and Clinical Neurophysiology (E.W., H.L.) and Section of Pediatric Neurology (E.W.), The Cleveland Clinic Foundation.

is often required to determine the location of onset of CPS in children and adults.

IDENTIFICATION OF SURGICAL CANDIDATES

The major criteria for epilepsy surgery include the following: (1) a clearly established diagnosis of localization-related epilepsy; (2) location of seizure onset in a relatively "silent" area of the brain that could be removed with a low risk of neurologic deficit; and (3) intractable, handicapping seizures for at least two or three years. The first two of these criteria are based on results of an intensive presurgical evaluation, usually at a specialized center for epilepsy surgery. The third criterion is more relative, based to a great degree on the clinician's judgment.

CRITERION 1: A CLEARLY ESTABLISHED DIAGNOSIS OF LOCALIZATION-RELATED EPILEPSY

Clinical manifestations of CPS

For a solid diagnosis of localization-related epilepsy, the child's episodes should be consistent with the clinical profile of partial seizures. The clinical features of CPS have been well defined in adults,^{7,9-14} but there is less detailed information about such seizures in infants and young children.⁶ Available data indicate that there are some differences between these groups.

Auras have been less often identified in children. A simple partial sensory seizure preceding the CPS has been reported for the majority of adult patients with temporal lobe epilepsy,^{9,11,12,14} but for fewer than one third of children.^{15,16} It is possible, however, that more children actually start with a simple partial seizure but cannot describe the feeling. Sometimes an initial simple partial seizure can be suspected because the child typically comes to a parent for help just before the development of altered consciousness.

Impairment of consciousness is more difficult to assess in infants and children than in adults, and this sometimes complicates the identification of seizures as complex partial. Impaired consciousness may manifest simply as an arrest of ongoing activity, decreased responsiveness, or a blank stare; and these signs may be difficult to identify in young patients, especially in infants, and will be even more difficult to recognize if the child is mentally retarded. In addition, the young child, unlike an adult, will not be able to explain that he "blacked out" for a short time; and it may be difficult

to determine whether the child has had amnesia for ictal events. Because the International Classification⁵ requires amnesia to define ictal unconsciousness, it is especially difficult to apply this classification system to younger patients and to group them for scientific study.

It may sometimes be possible to demonstrate unresponsiveness during partial seizures in infants and young children. However, unresponsiveness does not necessarily indicate altered consciousness and may be due to aphasia, apraxia, severe dysarthria, or preoccupation with sensory or motor ictal phenomena. For these reasons, unresponsiveness is not equivalent to amnesia as an indicator of altered consciousness. Because we cannot assess amnesia in infants, it is important that we reexamine our classification of partial seizures in these youngest patients.

Automatisms, reported to be equally frequent during CPS in children and adults, are most common during the seizures of temporal lobe epilepsy; but they may also be seen in frontal, parietal, or occipital lobe epilepsy, or in childhood generalized absence epilepsy (petit mal).¹⁷ Because automatisms occur after consciousness has been lost, children do not remember them.

Few studies of younger patients with CPS have been based on video-EEG,^{15,16,18-20} but in the available series, results have been consistent. Holmes¹⁶ found automatisms during videotaped CPS in 87% of children 5 to 19 years old, and Yamamoto et al²⁰ found automatisms in 78% of children 3 to 13 years old. These figures are similar to those reported for adults,^{9,12,21} and also for infants: Yamamoto et al found automatisms during CPS in 80% of babies 0 to 2 years old, and Duchowny¹⁸ found automatisms in 57% of babies in the same age group. Most, but not all, of the patients in these series had temporal lobe epilepsy.

The automatisms during CPS vary widely between patients but tend to be stereotyped from one seizure to another for individual children. Children and adolescents may have automatisms consisting of a wide range of poorly coordinated semipurposeful activity, similar to those seen in adults;^{16,20} but infants most often have just alimentary automatisms, such as chewing, swallowing, or lip smacking.^{18,20} Gestural automatisms, such as fumbling with nearby objects or picking at clothes or bedsheets, are infrequent in infants,^{18,20} perhaps because babies, unlike older children or adults, do not yet have a large repertoire of coordinated, purposeful hand movements as part of their normal behavior. This makes recognition of CPS more difficult in infants and young children because alimentary automatisms, which are predominantly sucking movements, may be difficult

to distinguish from normal infantile background behavior.

Automatisms may also occur during the postictal phase of CPS, while the child is still significantly confused. If the child is physically restrained during that time, he may react with aggressive behavior against the restraining person; but if he is left alone except for maneuvers to protect his safety, there will probably be no directed violence.²²

Secondary spreading and generalization may occur during CPS in children or adults. In patients with temporal lobe epilepsy, the spread of the ictal discharge throughout one hemisphere may typically result in such symptoms as dystonic posturing²³ of the contralateral limbs, clonic jerking of the contralateral limbs or face, or versive turning of the head to the contralateral side.²⁴ This same progression has also been observed during CPS in infants.¹⁸ During videotaped CPS, some infants may also display other types of motor phenomena such as "hooking" or "boxing" movements of the arms, loss of neck muscle tone, or posturing resembling an asymmetric tonic neck response.¹⁸ The exact significance of these more unusual motor phenomena is unclear.

With secondary spreading of the ictal discharge, many patients may have a full generalized tonic-clonic convulsion. When secondary generalization is frequent, it may cause the temporal lobe epilepsy to be even more debilitating, resulting in earlier consideration of epilepsy surgery.

In summary, there appear to be some differences in the clinical manifestations of CPS between infants, children, and adults. In general, these differences make it more difficult to identify CPS in the youngest patients.

Some evidence suggests that temporal lobe epilepsy is an under-recognized entity in patients less than 2 years old. Harbord and Mason²⁵ studied 63 children with CPS and found that 16% had onset of seizures before the age of 2, but most were not diagnosed until several years later. Diagnosis is more difficult in infants than in older children, for the clinical reasons described above, and also because the typical interictal EEG findings may not appear until later. Dinner et al²⁶ studied 30 patients with childhood-onset temporal lobe epilepsy and found that none of them had interictal sharp waves before the age of 6; but 48% had onset of seizures between birth and 5 years of age. Decreased frequency of interictal epileptiform discharges in infants with CPS has also been noted by others.²⁰

It is clear that the typical temporal lobe epilepsy of

adolescents and adults may begin very early in life, even though it is often not diagnosed until later. In pediatric epilepsy surgery series, 11%^{27,28} to 50%²⁹ of patients had onset of their CPS before the age of 2 and the early- and later-onset groups were indistinguishable at time of operation. This lack of difference between early- and later-onset groups was also noted in the patients with temporal lobe epilepsy who were first studied by Dinner et al,²⁶ and then reevaluated five years later by Kotagal et al.³⁰

Etiology

The predominant etiologic issue in the identification of epilepsy surgery candidates is the possibility of a focal structural cerebral lesion. Other issues concerned with etiology have been discussed in detail elsewhere.⁶

The diagnosis of a focal structural cerebral lesion is usually best made by magnetic resonance imaging (MRI).³¹⁻³⁵ This technique has significant advantages over computed tomography (CT) because of higher sensitivity, superior image quality, lack of radiation exposure, and capacity for multiplanar display. In some cases, MRI has disclosed a lesion not seen on CT. The most frequent location for CT or MRI abnormalities in patients with CPS is the temporal lobe (*Figure 1*); typical lesions include arteriovenous malformations, subarachnoid cysts, hamartomas, old infarction, mesial temporal sclerosis, or slow-growing gliomas.

If a focal structural lesion is found, then the surgery may be scheduled earlier because of a concern that the lesion is neoplastic.³⁶⁻³⁸ This is especially true when the lesion is seen to expand on serial MRIs or CT scans, although even apparently static lesions may turn out to be slow-growing gliomas. It has also been suggested that a structural lesion may indicate an increased chance that the seizures are truly intractable.³⁶ In addition, if the focal structural lesion is in the same region as the epileptiform discharges on EEG, then the finding may give added confidence that the EEG localization is correct and that epilepsy surgery will be effective.^{39,40} For these reasons, neuroimaging is an important part of the presurgical evaluation.

Patients may also have pathologically identified structural lesions that are not definitely identified until necropsy or examination of the surgical specimen. These pathologic findings include lesions such as small tumors, mesial temporal sclerosis, vascular malformations that did not show up preoperatively on CT or MRI, or neuronal heterotopias.⁴¹ The exact etiologic significance of some of these pathologic findings is still controversial.

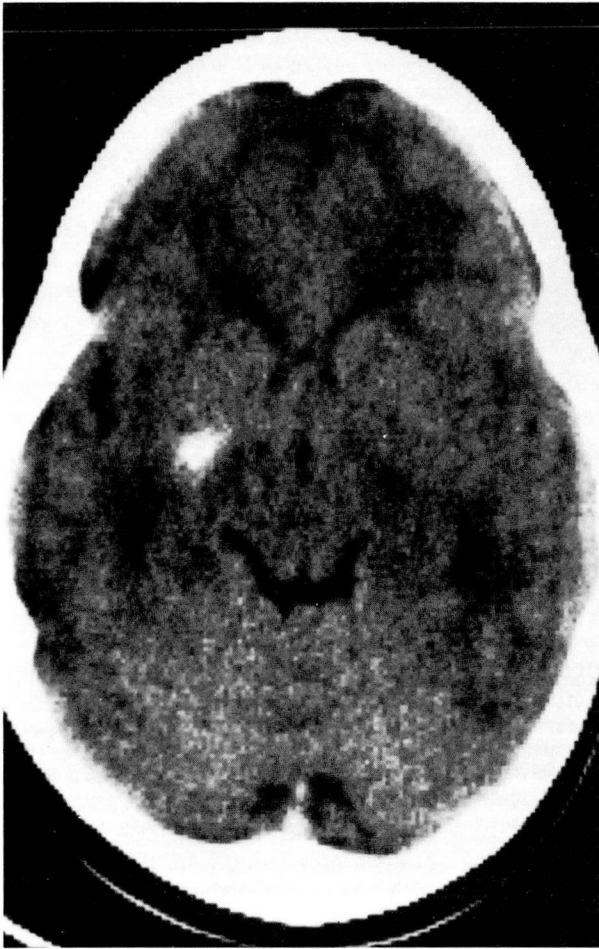


FIGURE 1. CT scan without contrast of a 21-month-old baby with CPS, showing a calcified lesion in the right anterior temporal region (sides are reversed on this film). The infant's ictal EEG is reproduced in Figure 4. The patient had CPS with staring and a frightened look, up to two or three per day, from the age of 3 months.

EEG manifestations. If the interictal EEG shows focal spikes or sharp waves from the temporal lobe (Figures 2 and 3), then there is strong supportive evidence for a diagnosis of CPS in the proper clinical setting.

However, not all children with CPS have temporal lobe epilepsy; and some will have interictal spikes or sharp waves from an extratemporal region. Other aspects of the EEG findings in children with CPS are discussed in detail elsewhere.⁴²

A significant proportion of patients with CPS have normal routine interictal EEGs; this may be especially true for infants²⁰ and children.¹⁵ In this case, if the

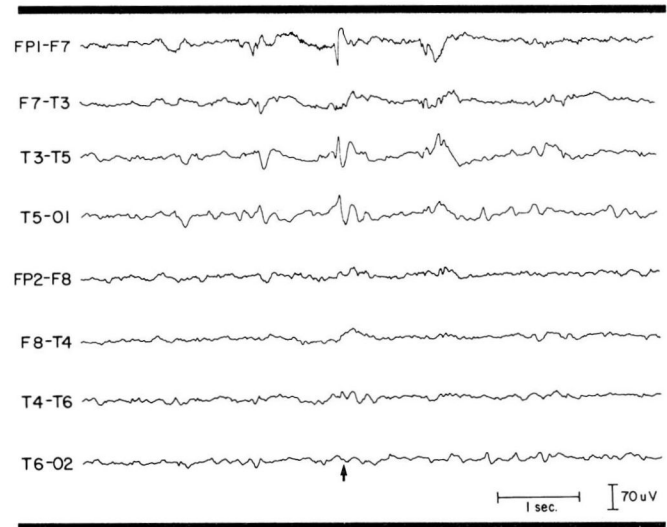


FIGURE 2. Left anterior temporal interictal sharp wave (arrow) in a 9-year-old girl with CPS for many years. See also Figure 3.

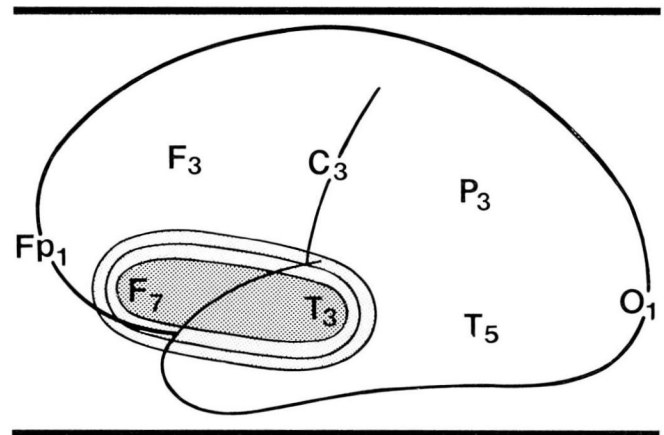


FIGURE 3. Schematic illustration of the distribution of the left anterior temporal sharp wave in Figure 2. The focal discharge is essentially limited to the left frontotemporal area beneath electrodes F₇ and T₃.

history is suggestive and initial medical treatment is ineffective, then it is appropriate to consider additional prolonged EEG recording to confirm the diagnosis.⁴³ In addition, the chance of actually recording a seizure may be increased by weaning the antiepileptic medication.

It must be remembered that children 2 to 16 years old may have a type of interictal sharp wave that does not support a diagnosis of CPS: the centrottemporal spikes of benign childhood epilepsy. Although these

discharges are clearly epileptiform, they frequently occur in normal children. It has been estimated that only 8.8% of children with these EEG discharges actually ever have a seizure.⁴⁴ Among children with these centrottemporal spikes who do have seizures, the type is usually generalized tonic-clonic or simple partial with focal motor phenomena, not complex partial.^{19,44} This means that in a child who presents with a complaint of staring spells, the centrottemporal spikes may be only an incidental finding and not proof that the child has CPS.

CRITERION II: LOCATION OF SEIZURE ONSET IN A RELATIVELY "SILENT" AREA OF THE BRAIN

Determination of the precise location of seizure onset requires intensive EEG evaluation, sometimes with invasive techniques.⁴⁵⁻⁴⁸ This is usually best accomplished at a specialized center for epilepsy surgery.

From a surgical point of view, the ideal situation is seizures arising from the anterior portion of one temporal lobe, because this region can usually be safely removed without postoperative neurological deficit. It is more difficult when the seizures arise from extratemporal regions or from the left posterior temporal area. It should be remembered, however, that many children have had successful resection of the left anterior temporal lobe,³⁸ even when a posterior temporal focus was initially suspected on clinical grounds. Ictal or postictal aphasia is not necessarily a bad prognostic sign because it does not prove that the seizures actually began in the posterior temporal region. Many patients have ictal or postictal aphasia after the seizure discharge has spread from the anterior to the posterior temporal region.⁴⁹

CRITERION III: INTRACTABLE, HANDICAPPING SEIZURES

This is the most difficult and controversial of the criteria for epilepsy surgery, especially in children, because it is more relative than the other two and because it is based more on the judgement of the clinician. Three questions must be answered to satisfy this criterion.

Are the seizures truly intractable? This depends on the degree to which medical management has been aggressive. (A strategy for medical management has been described in detail elsewhere.⁶) If the child has persistent seizures despite maximum tolerated doses of

each of the major antiepileptic medications, then the seizures are intractable. However, the key question is: was each drug used at increasing dosage until signs of clinical toxicity appeared, regardless of the serum concentration? Until signs and symptoms of toxicity are seen, the child's own maximum tolerated dosage is unknown. Such a maximum dosage often results in a serum concentration above the usual therapeutic range; hence, blood tests alone should not be used to determine whether a medication has failed.^{7,43}

Sometimes better tolerance of high dosages of medication can be obtained by dividing the total daily amount into smaller, more frequent doses to minimize postdose peaks in concentration. In addition, certain adverse effects can sometimes be treated with measures other than decreasing the dosage; for example, drug-induced gastritis may respond to treatment with histamine H₂-receptor antagonists.⁵⁰ Polypharmacy should be avoided because it may increase the likelihood of adverse effects.⁴³ And finally, it is important to continue each regimen long enough to afford a reasonable observation period. It may take several weeks for the medication to reach a final steady-state serum concentration, and it may take several more weeks after that to be sure that the dosage is ineffective.

We feel that in treating children it is wise to explore the most aggressive medical managements prior to surgery. To complete the full series of drug maneuvers requires at least a year or two of intensive work; but in children it is probably especially critical to be sure of intractability because of the shorter previous course of the epilepsy.

Are the seizures sufficiently handicapping to warrant a surgical procedure? Adults and older adolescents with intractable CPS may have severe limitations on their lifestyle because of employment and driving difficulties; but in young children it may be more difficult to appreciate the adverse impact of CPS. It must be remembered that the child has the special problem of having to deal with the epilepsy while developing a sense of self.⁵¹⁻⁵³ The unpredictable, recurrent nature of the attacks may cause anxiety, depression, and poor self-esteem,^{54,55} and in children especially this may lead to a sense of decreased competency and independence. Compounding this are two other factors—the tendency for parents of children with epilepsy to be overprotective^{56,57} and the likelihood of social ostracism by peers.⁵⁸ By the time these children reach early adulthood, they may already have significant psychosocial difficulties that limit their educational, social, and vocational potential. It has been suggested that

TABLE 1
RATES OF SPONTANEOUS REMISSION IN SERIES OF CHILDREN WITH CPS

| Report | All patients had focal EEG sharp waves | No patients had benign focal epilepsy | % of patients seizure-free at follow-up |
|-------------------------------------|--|---------------------------------------|---|
| Glaser 1967 ⁶⁴ | — | — | 29 |
| Currie et al 1971 ¹⁴ | — | — | 32 |
| Lindsay et al 1979 ⁶⁵ | — | — | 33 |
| Iemolo et al 1981 ⁶⁶ | — | Yes | 20 |
| Sofijanov 1982 ⁶⁷ | Yes | — | 36 |
| Loiseau et al 1983 ⁶⁸ | — | Yes | 48 |
| Sillanpää 1983 ⁶⁹ | — | — | 29 |
| Schmidt et al 1983 ⁷⁰ | — | — | 62 |
| Deonna et al 1986 ⁷¹ | — | Yes | 24 |
| Harbord & Manson 1987 ²⁵ | Yes | Yes | 10* |
| Kotagal et al 1987 ³⁰ | Yes | Yes | 18*† |

* Only these two series were limited to children with firm EEG evidence of localization-related epilepsy, and specifically excluded patients with benign focal epilepsy with centrottemporal spikes.

† None of the patients were able to come off medication. Seizure-free patients were controlled with antiepileptic drugs.

earlier epilepsy surgery may help to prevent these long-term problems.^{39,59-62}

It should also be remembered that a certain type and severity of seizures may mean a different degree of disability to two different children. Two or three CPS a month may have a strong adverse effect on the lifestyle of a high-functioning high school student who is active in sports and social activities, learning to drive, and preparing for college and a career. On the other hand, two or three such seizures a month may be acceptable to a more limited youngster who lives in a supervised home and is training for a job in a sheltered workshop. There is no absolute number of seizures per

month that forms an index of severity. Severity is relative and is more concerned with the context of seizure frequency in terms of the lifestyle of each patient. In each case, a careful psychosocial assessment is necessary to determine whether the seizures are sufficiently handicapping to warrant epilepsy surgery.

One clinical feature that we feel should not be used as an absolute contraindication for seizure surgery is mental retardation. However, it is important to identify a specific goal for improved lifestyle that could be realistically accomplished by improvement of the seizures after surgery, and this may vary depending on intellect. For high-functioning children with temporal lobe epilepsy, the goal would be an independent, normal life; but for children with mental retardation the goals may be an opportunity to live in a group home instead of a nursing facility or to continue working in a sheltered workshop. In any case, there must be some realistic expectation that lifestyle would be improved with better seizure control. If the EEG, clinical, and radiographic evidence suggest that there is a single resectable focus, and if the child meets the other criteria for this type of epilepsy surgery, then we feel that operation should be considered.

To the psychologically damaging potential of uncontrolled seizures must be added the problem of chronic exposure to high doses of antiepileptic medication. Each of the drugs may have serious side effects,⁶³ especially when used at high dosages; but if epilepsy surgery is successful, then the child may need less medication or eventually even no medication.

Is there any realistic chance that the seizures will remit spontaneously? A major concern about early surgery in children is that until adulthood, it may be difficult to be

sure that the child will not outgrow the seizures. However, it has not been clearly demonstrated that childhood-onset CPS have higher rates of spontaneous remission than adult-onset seizures. Recently reported remission rates in children with partial seizures have ranged from 10% to 62% (Table 1),^{14,25,30,64-71} but most reports have had limitations.

Several were based on clinical criteria only, so some patients may have had

TABLE 2
RESULTS OF EPILEPSY SURGERY IN PEDIATRIC SERIES

| Report | No. of patients | Ages (yrs) at operation | Resected areas | % with good outcome |
|--|-----------------|-------------------------|---------------------------|---------------------|
| Davidson and Falconer 1975 ³⁹ | 40 | 2-34 | Temporal | 60 |
| Rasmussen 1977 ³⁷ | 77 | 6-15 | Temporal | 73 |
| Jensen and Vaernet 1977 ⁷² | 12 | 3-15 | Temporal | 83 |
| Green 1977 ⁷³ | 32 | 2-18 | Temporal | 93 |
| Polkey 1980 ³⁶ | 40 | <15 | Temporal | 57 |
| Whittle 1981 ²⁹ | 8 | 5-18 | Temporal | 62 |
| Goldring and Gregorie 1984 ⁷⁴ | 29 | 0.5-14 | Temporal or extratemporal | 62 |
| Lindsay et al 1984 ⁷⁵ | 13 | 7-36 | Temporal or hemispheric | 100 |
| Meyer et al 1986 ⁶¹ | 50 | 7-18 | Temporal | 78 |
| Wyllie et al 1988 ³⁸ | 23 | 3-18 | Temporal or extratemporal | 70 |

childhood-absence epilepsy, psychogenic seizures, or other nonepileptic events; and several included patients with benign childhood epilepsy with centrotemporal spikes, which typically resolves spontaneously by the time the patient is about 16 years old.⁴⁴ The inclusion of these other groups might have falsely raised the remission rate. Only two reports have been limited to children with EEG-demonstrated temporal lobe epilepsy, and in these the remission rates were only 10%²⁵ and 18%.³⁰ In addition, it should be noted that in one of these series³⁰ remission was defined only as controlled on medications: none of the patients were seizure-free off drugs. These data suggest that temporal lobe epilepsy is frequently intractable in children as well as adults, and that spontaneous remission is unlikely.

RESULTS OF EPILEPSY SURGERY IN CHILDREN

In order to assess whether epilepsy surgery might be appropriate for a given child, it is important to be familiar with the results of these procedures in children. The most frequent type of epilepsy surgery performed in children and adults is temporal lobectomy, followed by frontal lobectomy; but some patients have benefited from other types of extratemporal resections.

The definition of good outcome after epilepsy surgery has varied between reports, but in general it includes being seizure-free, with auras only, or with a very marked decrease in seizure frequency. The overall reported rate of good outcome in pediatric series has ranged from 57% to 100% of patients, with most centers reporting good outcome for about 75% of operated children (Table 2).^{29,36-39,61,72-75}

These rates are comparable to those reported in adult series. It has become clear that children as well as adults may benefit from early epilepsy surgery.

Complications have been infrequent, but some children have had infection, intracranial hemorrhage, infarction, or persistent postoperative language or memory impairment. In every surgical series, however, the favorable results have far outweighed the occasional complications.

The timing of cortical resection in children

We feel that if there is clear EEG and clinical evidence of localization-related epilepsy, with rigorous exclusion of childhood-absence epilepsy and benign childhood epilepsy with centrotemporal spikes, and if the seizures are truly intractable and disabling despite

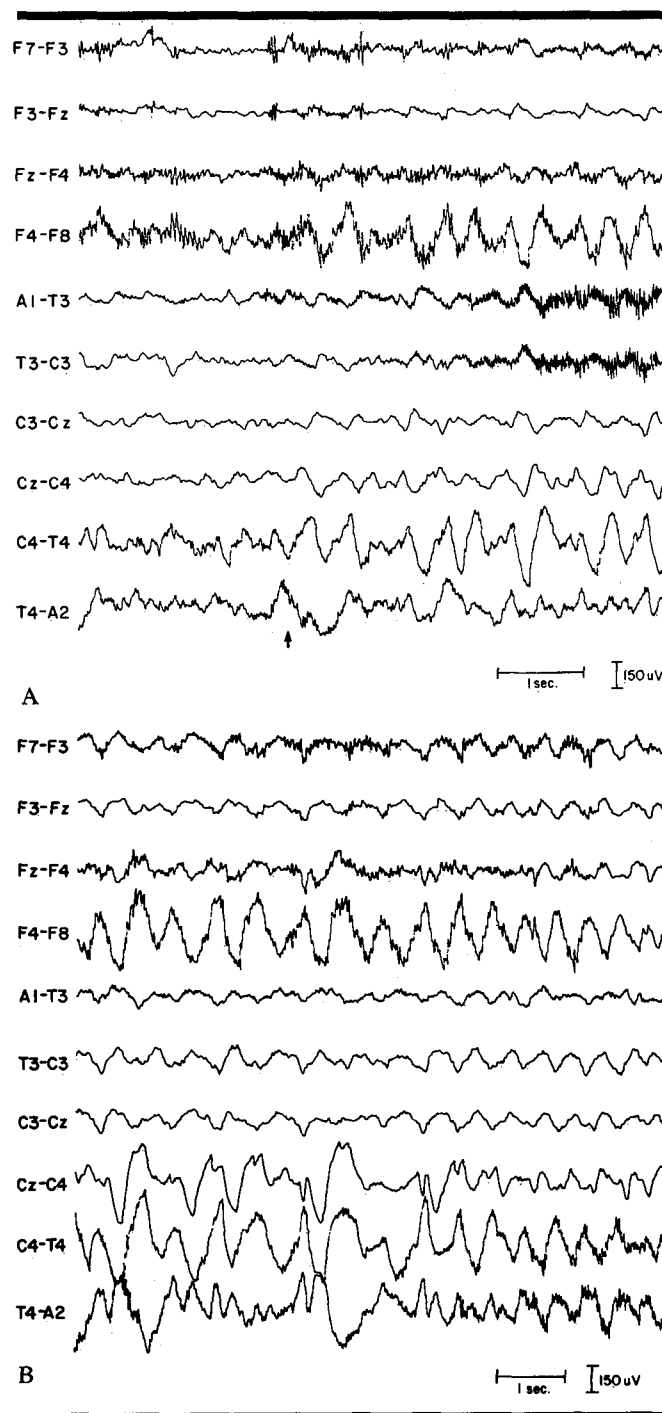


FIGURE 4. EEG recording during a CPS in the 21-month-old baby whose CT scan is shown in Figure 1. The second segment of the tracing (B) is the continuation of the first (A). This recorded seizure included staring and apparent unresponsiveness, with arrest of activity, beginning at the time marked by the arrow. The paroxysmal slowing on EEG was maximal in the right anterior temporal region (see also Figure 5).

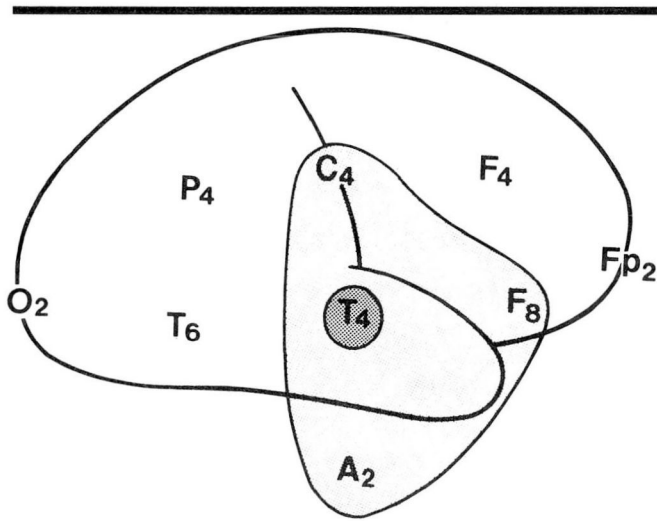


FIGURE 5. Schematic illustration of the distribution of the right anterior temporal EEG seizure pattern in Figure 4.

aggressive medication trials for two or three years, then it is appropriate to consider epilepsy surgery, even in young children. In most cases, patients with childhood-onset localization-related epilepsy should be considered for operation before the end of high school, in mid to late adolescence, to facilitate a more normal entry into adulthood. In cases with earlier satisfaction of selection criteria, it may be appropriate to operate sooner, as early as 7 or 8 years old, to facilitate a more normal adolescence.

Several pediatric operative series have included patients as young as 2 or 3 years old.^{38,39,72-74} The increasing use of EEG monitoring in infants is broadening our understanding of localization-related epilepsy in this age group,^{18,20,76} and in desperate cases, operation may be appropriate.⁷⁷ However, in all but the most severe cases, it usually takes several years for the diagnosis to become clear and for exhaustive medication trials to be completed. Even in patients with onset of seizures in infancy, the selection criteria are usually not fulfilled before at least the early school-age years.

CONCLUSION

If there is clear EEG and clinical evidence of localization-related epilepsy, with rigorous exclusion of childhood absence epilepsy and benign childhood epilepsy with centrotemporal spikes, and if the seizures are truly intractable and disabling despite aggressive medication trials for two or three years, then it is appropriate to consider epilepsy surgery. We feel that early surgery in young patients may result in an increased likelihood of normal social, emotional, and vocational adjustment and should be strongly considered for appropriate candidates.

ELAINE WYLLIE, MD
Department of Neurology
The Cleveland Clinic Foundation
One Clinic Center
9500 Euclid Avenue
Cleveland, Ohio 44195

REFERENCES

- Falconer MA, Taylor DC. Temporal lobe epilepsy. Clinical features, pathology, diagnosis and treatment. [In] Price JH, ed. *Modern Trends in Psychological Medicine*. London, Butterworths, 1970, pp 346-373.
- Cavazzuti GB. Epidemiology of different types of epilepsy in school age children of Modena, Italy. *Epilepsia* 1980; **21**:57-62.
- Hauser WA, Durland LT. The epidemiology of epilepsy in Rochester, Minnesota, 1935 through 1967. *Epilepsia* 1975; **16**:1-66.
- Juul-Jensen P, Foldspang A. Natural history of epileptic seizures. *Epilepsia* 1983; **24**:297-312.
- Commission on Classification and Terminology of the International League Against Epilepsy. Proposal for revised clinical and electroencephalographic classification of epileptic seizures. *Epilepsia* 1981; **22**:489-501.
- Wyllie E, Rothner AD, Lüders H. Partial seizures in children, and surgical considerations. *Ped Clin North Am* 1989 (in press).
- Sharbrough FW. Complex partial seizures. [In] Lüders H, Lesser RL, eds. *Epilepsy: Electroclinical Syndromes*. New York, Springer-Verlag, 1987, pp 279-302.
- Commission on Classification and Terminology of the International League Against Epilepsy. Proposal for classification of epilepsies and epileptic syndromes. *Epilepsia* 1985; **26**:268-278.
- Delgado-Escueta AV, Bacsai FE, Treiman DM. Complex partial seizures on closed-circuit television and EEG: A study of 691 attacks in 79 patients. *Ann Neurol* 1982; **11**:292-300.
- Delgado-Escueta AV, Walsh GO. Type I complex partial seizures of hippocampal origin: excellent results of anterior temporal lobectomy. *Neurology (NY)* 1985; **35**:143-154.
- Gupta A, Jeavons PM, Hughes RC, et al. Aura in temporal lobe epilepsy; Clinical and electroencephalographic correlation. *J Neurol Neurosurg Psychiatry* 1983; **46**:1079-1083.
- King DW, Ajmone-Marsan C. Clinical features and ictal patterns in epileptic patients with EEG temporal lobe foci. *Ann Neurol* 1977; **2**:138-147.
- Weiser HG. *Electroclinical Features of the Psychomotor Seizure*. New York, Butterworths, 1983, pp 30-110.
- Currie S, Heathfield KWG, Henson RA, et al. Clinical course and prognosis of temporal lobe epilepsy: A survey of 666 patients. *Brain* 1971; **94**:173-190.
- Holmes GL. Partial complex seizures in children: An analysis of 69

- seizures in 24 patients using EEG FM radiotelemetry and videotape recording. *Electroencephalogr Clin Neurophysiol* 1984; 57:13-20.
16. Holmes GL. Partial seizures in children. *Pediatrics* 1986; 77:725-731.
 17. Penry JK, Porter RJ, Dreifuss FE. Simultaneous recording of absence seizures with videotape and electroencephalography: A study of 374 seizures in 48 patients. *Brain* 1975; 98:427-440.
 18. Duchowny MS. Complex partial seizures of infancy. *Arch Neurol* 1987; 44:911-914.
 19. Holmes GL. Partial seizures. [In] *Diagnosis and Management of Seizures in Children*. Philadelphia, WB Saunders, 1987, vol 30, pp 125-161.
 20. Yamamoto N, Watanabe K, Negoro T, Takaesu E, Aso K, Furune S, Takahashi I. Complex partial seizures in children: Ictal manifestations and their relation to clinical course. *Neurology* 1987; 37:1979-1982.
 21. Theodore WH, Porter RJ, Penry JK. Complex partial seizures: Clinical characteristics and differential diagnosis. *Neurology* 1983; 33:1115-1121.
 22. Delgado-Escueta AV, Mattson R, King L, et al. The nature of aggression during epileptic seizures. *N Engl J Med* 1981; 305:711-716.
 23. Kotagal P, Lüders H, Morris H, Wyllie E, Dinner DS. Unilateral dystonic posturing in complex partial seizures of temporal lobe onset: A new lateralizing sign. *Neurology* 1988; 38(suppl):277.
 24. Wyllie E, Lüders H, Morris HH, Lesser RP, Dinner DS. The lateralizing significance of versive head and eye movements during epileptic seizures. *Neurology* 1986; 36:606-611.
 25. Harbord MG, Manson JL. Temporal lobe epilepsy in childhood: A reappraisal of etiology and outcome. *Pediatr Neurol* 1987; 3:263-268.
 26. Dinner DS, Lüders H, Rothner AD, Erenberg G. Complex partial seizures of childhood onset: a clinical and encephalographic study. *Cleve Clin Q* 1984; 51:287-291.
 27. Falconer MA, Serafetinides EA. A follow-up study of surgery in temporal lobe epilepsy. *J Neurol Neurosurg Psychiatr* 1963; 26:154-165.
 28. Jensen I. Temporal lobe epilepsy. Types of seizures, age, and surgical results. *Acta Neurol Scandin* 1976; 53:335-337.
 29. Whittle IR, Ellis HJ, Simpson DA. The surgical treatment of intractable childhood and adolescent epilepsy. *Aust NZ J Surg* 1981; 51:190-196.
 30. Kotagal P, Rothner AD, Erenberg G, Cruse R, Wyllie E. Complex partial seizures of childhood onset: A five-year follow-up study. *Arch Neurol* 1987; 44:1177-1180.
 31. Jabbari B, Gunderson CH, Wippold F, et al. Magnetic resonance imaging in partial complex epilepsy. *Arch Neurol* 1986; 43:869-872.
 32. Laster W, Penry JK, Moody D, et al. Chronic seizure disorders. Contribution of MR imaging when CT is normal. *Am J Neurorad* 1985; 6:177-180.
 33. Theodore WH, Dorwart R, Holmes M, et al. Neuroimaging in refractory partial seizures: comparison of PET, CT, and MRI. *Neurology* 1986; 36:750-759.
 34. Lesser R, Modic M, Weinstein M, et al. Magnetic resonance imaging in patients with intractable focal seizures. *Arch Neurol* 1986; 43:367-371.
 35. Sperling MR, Wilson G, Engel J, et al. Magnetic resonance imaging in intractable partial epilepsy: correlative studies. *Ann Neurol* 1986; 20:57-62.
 36. Polkey CE. Selection of patients with intractable epilepsy for resective surgery. *Arch Dis Child* 1980; 55:841-844.
 37. Rasmussen TB. Surgical aspects. [In] Wise G, ed. *Topics in Child Neurology*. Inglewood Cliffs, NJ, Spectrum Publications, Inc., 1977, pp 143-153.
 38. Wyllie E, Lüders H, Morris HH, Lesser RP, Dinner DS, Hahn J, Estes ML, Rothner AD, Erenberg G, Cruse R, Friedman D. Subdural electrodes in the evaluation for epilepsy surgery in children and adults. *Neuropediatrics* 1988; 19:80-86.
 39. Davidson S, Falconer MA. Outcome of surgery in 40 children with temporal-lobe epilepsy. *Lancet* 1975; 2:1260-1263.
 40. Lieb JP, Engel J, Brown WJ, Gevins AS, Crandall PH. Neuropathological findings following temporal lobectomy related to surface and deep EEG patterns. *Epilepsia* 1981; 22:539-549.
 41. Babb TL, Brown WJ. Pathological findings in epilepsy. [In] Engel J, ed. *Surgical Treatment of the Epilepsies*. New York, Raven Press, 1987, pp 511-552.
 42. Lüders H, Dinner DS, Morris HH, Wyllie E, Godoy J. EEG evaluation for epilepsy surgery in children. *Cleve Clin J Med* 1989; 56:S-53-S-61.
 43. Lesser RP, Dinner DS, Lüders H, Morris HH. Differential diagnosis and treatment of intractable seizures. *Cleve Clin Q* 1984; 51:227-240.
 44. Lüders H, Lesser RP, Dinner DS, Morris HH. Benign focal epilepsy of childhood. [In] Lüders H, Lesser RL, eds. *Epilepsy: Electroclinical Syndromes*. New York, Springer-Verlag, 1987, pp 303-346.
 45. Wyllie E, Lüders H, Morris HH, Lesser RP, Dinner DS, Hahn J, Estes ML, Rothner AD, Erenberg G, Cruse R, Friedman D. Clinical outcome after complete or partial cortical resection for intractable epilepsy. *Neurology* 1987; 37:1634-1641.
 46. Lüders H, Lesser RP, Dinner DS, Morris HH, Hahn JF, Friedman L, Skipper G, Wyllie E, Friedman D. Chronic intracranial recording and stimulation with subdural electrodes. [In] Engel J, ed. *Surgical Treatment of the Epilepsies*. New York, Raven Press, 1987, pp 297-321.
 47. Spencer DD, Spencer SS. Surgery for epilepsy. *Neurologic Clinics* 1985; 3:313-330.
 48. Spencer SS. Depth electroencephalography in selection of refractory epilepsy for surgery. *Ann Neurol* 1981; 9:207-214.
 49. Gabr M, Lüders H, Dinner DS, Morris HH, Wyllie E. Ictal speech abnormalities in temporal lobe epilepsy. *Epilepsia* 1987; 28:622-623.
 50. Marks WA, Morris M, Bodensteiner JB, Bobele B, Grunow J, Hille M, Tuggle D. Valproate-induced gastritis. *Ann Neurol* 1987; 22:414.
 51. Holmes GL. Psychosocial factors in childhood epilepsy. [In] *Diagnosis and Management of Seizures in Children*. Major Problems in Clinical Pediatrics, Philadelphia, W.B. Saunders, 1987, vol 30, pp 112-124.
 52. Ziegler RG. Impairments of control and competence in epileptic children and their families. *Epilepsia* 1981; 22:339-346.
 53. Viberg M, Blennow G, Polski B. Epilepsy in adolescence: Implications for the development of personality. *Epilepsia* 1987; 28:542-546.
 54. Hoare P. Does illness foster dependency? A study of epileptic and diabetic children. *Dev Med Child Neurol* 1984; 26:3-13.
 55. Matthews WS, Barabas G, Ferrari M. Emotional concomitants of childhood epilepsy. *Epilepsia* 1982; 23:671-681.
 56. Long CG, Moore JR. Parental expectations for their epileptic children. *J Child Psychol Psychiatry* 1970; 23:80-89.
 57. Ross EM, Peckham CS. School children with epilepsy. [In] Parsonage M, Grant RHE, Craig AG, eds. *Advances in Epileptology: XIVth Epilepsy International Symposium*. New York, Raven Press, 1983, pp 215-220.
 58. Caveness WF, Gallop GH. A survey of public attitudes toward epilepsy in 1979 with an indication of trends over the past thirty years. *Epilepsia* 1980; 21:509-518.
 59. Falconer MA. Place of surgery for temporal lobe epilepsy during childhood. *Brit Med J* 1972; 2:631-635.
 60. Lindsay J, Ounsted C, Richards P. Long-term outcome in children with temporal lobe seizures: V. Indications and contraindications for neurosurgery. *Dev Med Child Neurol* 1984; 26:25-32.
 61. Meyers FB, Marsh WR, Laws ER, Sharbrough FW. Temporal lobectomy in children with epilepsy. *J Neurosurg* 1986; 64:371-376.
 62. Rasmussen T. Cortical resection in children with focal epilepsy. [In] Parsonage M, Grant RHE, Craig HG, eds. *Advances in Epileptology: XIVth Epilepsy International Symposium*. New York, Raven Press, 1983, pp 249-254.
 63. Holmes G. Pharmacology of antiepileptic drugs. [In] *Diagnosis and Management of Seizures in Children*. Major Problems in Clinical Pediatrics. Philadelphia, W.B. Saunders, 1987, vol 30, pp 72-111.

64. Glaser GH. Limbic epilepsy in childhood. *J Nerv Ment Dis* 1967; **114**:391-397.
65. Lindsay J, Ounsted C, Richards P. Longterm outcome in children with temporal lobe seizures: I. Social outcome and childhood factors. *Dev Med Child Neurol* 1979; **21**:285-298.
66. Iemolo F, Farnarier G, Serbanescu T, Menendez P. Etude longitudinale des epilepsies survenant dans l'adolescence. *Rev EEG Neurophysiol* 1981; **11**:502-508.
67. Sofijanov NG. Clinical evolution and prognosis of childhood epilepsies. *Epilepsia* 1982; **23**:61-69.
68. Loiseau P, Dartigues JF, Pestre M. Prognosis of partial epileptic seizures in the adolescent. *Epilepsia* 1983; **24**:472-481.
69. Sillanpää M. Social functioning and seizure status of young adults with onset of epilepsy in childhood: An epidemiological 10-year follow-up study. *Acta Neurol Scandin* 1983; **68**:8-77.
70. Schmidt D, Tsai JJ, Janz D. Generalized tonic-clonic seizures in patients with complex partial seizures: Natural history and prognostic relevance. *Epilepsia* 1983; **24**:43-48.
71. Deonna T, Ziegler AL, Despland PA, et al. Partial epilepsy in neurologically normal children: Clinical syndromes and prognosis. *Epilepsia* 1986; **27**:241-247.
72. Jensen I, Vaernet K. Temporal lobe epilepsy. Follow-up investigation of 74 temporal lobe resected patients. *Acta Neurochir* 1977; **37**:173-200.
73. Green JR. Surgical treatment of epilepsy during childhood and adolescence. *Surg Neurol* 1977; **8**:71-80.
74. Goldring S, Gregorie EM. Surgical management using epidural recordings to localize the seizure focus: review of 100 cases. *J Neurosurg* 1984; **60**:457-466.
75. Lindsay J, Glaser G, Richards P, Ounsted C. Developmental aspects of focal epilepsies of childhood treated by neurosurgery. *Dev Med Child Neurol* 1984; **26**:574-587.
76. Duchowny MS. Intensive monitoring in the epileptic child. *J Clin Neurophysiol* 1988; **2**:203-219.
77. Duchowny MS, Alvarez LA, Resnick TJ, Morrison G. Surgery in infancy for partial seizures (abstract). *Cleve Clin J Med* 1989; **56** (suppl pt 2).