

# Electroencephalography and pediatric epilepsy

WARREN T. BLUME, MD; SOLOMON L. MOSHÉ, MD; BARRY R. THARP, MD

**E**LECTROENCEPHALOGRAPHY (EEG) is useful in the diagnosis and management of pediatric patients with known or suspected seizure disorders; but just as the EEG of children and adolescents differs in some normal and abnormal phenomena from that of adults, neonatal EEG forms still a third distinct discipline.

---

## EEG IN NEONATES

---

Seizures are a common diagnostic and therapeutic challenge in the newborn nursery and can appear in infants at any gestational age. Nearly any of the several neurologic disorders afflicting such infants can be associated with seizures.<sup>1</sup> Clinical manifestations of neonatal seizures differ in several respects from those of older children. The most common forms are focal or multifocal clonic, tonic, and myoclonic attacks. Often such attacks are fragmentary, minimal, and very subtle. Generalized convulsive seizures, particularly tonic-clonic or grand mal, are rare in the newborn, particularly in the premature newborn.

EEG plays a major role in assessing central nervous system (CNS) function in neonates with seizure disorders and in monitoring the effectiveness of any therapy. It is particularly valuable in situations where the attacks are subtle and easily confused with normal or abnormal nonepileptiform motor behavior. For example, Mizrahi and Kellaway<sup>2</sup> demonstrated that many types of abnormal

motor behavior, particularly in neurologically abnormal neonates, are not accompanied by ictal EEG patterns.

Infants with abnormal pulmonary function or persistent fetal circulation are now being managed with pharmacologic neuromuscular blockade so that ventilatory support can be more effective. Because many of these infants have suffered hypoxic-ischemic events that may be epileptogenic, status epilepticus is not uncommon. Neuromuscular blockade can prevent peripheral expression of seizures in this group of patients. EEG can also help to evaluate jittery babies, including those of drug-addicted mothers; the motor behavior of such babies may easily be confused with seizures.

Seizures in the neonate are usually electrographically focal and spread in various degrees over the ipsilateral and contralateral hemispheres. Because there is a limited number of EEG patterns occurring in association with a plethora of clinical manifestations, the electroclinical correlation is variable and often poor. A seizure can be identified electrographically as progressively augmenting sequential rhythmic waves at any frequency, repetitive spikes, or sharp waves. The pace of such evolution may be slower than in older children or adults, particularly if the associated encephalopathy is severe. Multifocal seizures, i.e., two seizures appearing simultaneously in separate cortical regions with independent evolutions, occur commonly in neonates with severe encephalopathies.

Interictal background patterns reflect the severity of the underlying encephalopathy responsible for the seizures and vary considerably from normal to paroxysmal patterns to electric inactivity. In assessing such background activity, remember that it may be transiently worsened by several seizure-related factors. The hypoxia and altered cerebral metabolism associated with the seizure, systemic postictal changes, and anticonvul-

---

Departments of Clinical Neurological Sciences and Paediatrics, University Hospital, University of Western Ontario, London, Ontario, Canada (W.T.B.); Departments of Neurology and Pediatrics, Albert Einstein College of Medicine, New York, NY (S.L.M.); and Departments of Neurology and Pediatrics, Stanford Medical School, Stanford, CA (B.R.T.).

sant or other medication may all worsen such background activity. Full and valid assessment of such background activity, therefore, may require a prolonged recording to allow sufficient recovery from these ictal and postictal effects. If available, the pre-seizure background activity would be helpful in this respect.

Some EEG and clinical features may suggest an unfavorable prognosis. Electrographic seizures that have only subtle or absent clinical manifestations usually herald later neurologic sequelae. Subtle clinical phenomena can include eye deviation, mouth or tongue movements, apnea or other respiratory irregularity, or only minimal movements of an extremity. Such clinical-electrographic dissociation reflects the severity of the underlying encephalopathy, which in turn determines the risk of ultimate neurologic impairment. Multifocal ictal activity, described above, is a second manifestation of this condition. A third unfavorable prognostic sign is a persistently abnormal interictal EEG background activity for age of the patient that cannot be attributed to potentially reversible effects such as systemic, metabolic, electrolytic, or therapeutic factors.

The foregoing principles underscore the fact that only high quality EEG can be of any value. Persistent electrode artifact can be mistakenly interpreted as ictal activity. Improper application of electrodes, inappropriate machine controls, and poor annotation can all lead to erroneous assessment of background activity. Incomplete observation and annotation can falsely suggest that an electrographic seizure has an incomplete clinical manifestation. These pitfalls will be avoided only if specifically trained and devoted electroencephalographers and technologists are made responsible for these tasks.

---

#### EEG IN INFANTS, CHILDREN, AND ADOLESCENTS

---

Overwhelmed as he or she may be by the vast array of diagnostic tests covering almost every conceivable clinical situation, the generalist or specialist clinician may reasonably doubt the value of his or her own diagnostic acumen and the logic of his or her own management. Yet epilepsy remains a clinical diagnosis, and its management, a product of clinical assessment by the physician who is attentive to the patient's history and needs. None of the procedures outlined below has proven to be superior to painstaking clinical analysis. A seizure, however, is a relatively brief disturbance of cerebral function, and therefore only rarely will a

physician witness a complete attack. A complete and reliable description of the attack is usually an adequate substitute, so long as the physician is aware of appropriate questions to ask in making the differential diagnosis of the disorder and its classification. When descriptions are fragmentary despite scrutiny of the history, and when several of the ictal manifestations are shared by more than one type of epileptic seizure and/or by nonepileptic conditions, goal-directed EEG can provide valuable assistance. "Goal-directed" implies specific questions directed to the laboratory undertaking the test.

Almost since the demonstration of ictal patterns in petit mal absence, grand mal, and complex partial seizures, EEG has been the principal laboratory test indicated for patients with known or suspected seizure disorders, including particularly the pediatric age groups.

---

#### VALUE OF EEG IN DIAGNOSING AND CLASSIFYING AN EPILEPTIC SEIZURE

---

##### **Interictal abnormalities**

Because they occur far more commonly than EEG-recorded clinical seizures, interictal abnormalities play the major role in diagnosing and/or classifying an epileptic condition. Eighty-two percent of Trojaborg's 242 children with spike foci had epilepsy,<sup>3</sup> whereas Eeg-Olofsson et al<sup>4</sup> found focal spikes or sharp waves in only 1.9% of their 743 normal children. Cavazzuti et al<sup>5</sup> found such discharges in 3.54% of their normal children and most of these were rolandic spikes. Thus, there is a good, but imperfect, correlation between epileptiform activity in resting EEGs and seizure disorders in children. It is quite possible, however, for a patient to have focal spikes without a seizure disorder. On the other hand, demonstration of spikes is not required for diagnosis of a seizure disorder; for example, about a third of the children with partial seizures reported by Deonna et al<sup>6</sup> never had spikes.

Identifying EEG phenomena as spikes is facilitated in children by the greater abundance and usually more spectacular appearance of spikes than is seen in recordings of older patients. It is normal, however, for a greater number of waves in pediatric EEGs to be sharply contoured, and overreading such features as epileptiform is a common error in clinical practice. Normal sharply contoured waves in pediatric awake recordings include Mu rhythm, posterior slow of youth, sharply contoured temporal waves, and the buildup in hyper-

ventilation. Any medication-induced beta creates sharply contoured waves in association with the already abundant diffuse theta. In drowsiness, normal bursts of 3- to 5-Hz high voltage rhythmic waves can be indented by superimposed wave forms to create a notched spike-wave-like appearance. The normal apiculate V waves of children, comb-shaped spindles, and sharply contoured occipital delta are sleep potentials that can be mistaken for spikes.

In addition, many of the clinically innocent spike phenomena occur commonly in children. The most historically famous of these is the 14- and 6-per-second positive spike phenomenon which is a normal pattern seen in sleep recordings of many adolescents. The 6-per-second spike-wave phenomenon in its purest form likewise does not correlate with a seizure disorder. Although very spectacular in the rare instances in which it appears, the psychomotor variant phenomenon is likewise clinically insignificant. As will be seen later, the several spike phenomena peculiar to children vary in their correlation with epileptic conditions.

Despite such reservations, spikes or spike waves that are well identified and that appear at least occasionally in the resting record, not only give reasonable support to a clinical impression of a seizure disorder in children, but also help the physician to determine whether the attacks represent partial, partial and secondary generalized, or primary generalized seizure disorders.

### Ictal patterns

As an EEG-recorded clinically typical seizure would provide the best diagnostic confirmation of a seizure disorder and its mechanism (partial, generalized, or secondarily generalized), the physician should become familiar with EEG phenomena constituting such attacks so that they can be readily recognized.

A partial (focal) epileptic seizure consists of repetitive activity from one region that is dissimilar to its background rhythms and is not simply due to a change in state. The morphology of this sustained activity may be sequential spikes and sharp waves or sinusoidal waves. Such phenomena evolve as progressive changes in morphology and/or frequency in almost all clinically apparent seizures.<sup>7</sup> Thus, sinusoidal waves may evolve to repetitive spikes, or the reverse may occur. As the attack evolves, the repetition rate of its component phenomena may increase, decrease, or increase in some areas while decreasing in others. This evolution can help distinguish partial seizures electrographically from sequential, sharply contoured, clinically innocent phenomena such as psychomotor variant episodes. Unfor-

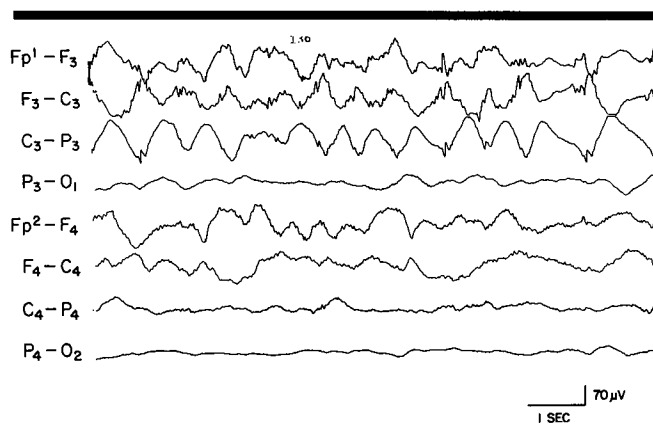


FIGURE 1. A polymorphic left frontal-central seizure of slow, irregular evolution in a 2-year-old comatose child with a diffuse encephalopathy. Interictal activity on the left resembled that seen here in corresponding right hemispheric derivations.

tunately, the morphology and sequencing of ictal phenomena can be bizarre, irregular, and slower when a diffuse encephalopathy is present (Figure 1).

Bilaterally synchronous or generalized ictal phenomena consist of sequential spikes, high-frequency sinusoidal waves, or sequential spike-wave complexes. Although the frequency of such phenomena may slow during the attack, morphological evolution is less commonly evident than in partial seizures.

### Nonepileptiform abnormalities

These interictal phenomena have an even more tenuous relationship with seizures than do interictal spikes. However, there are some nonepileptiform phenomena whose presence should stimulate a search for epileptiform potentials by a more prolonged recording or by activating procedures. Distinct focal delta activity or a convincing regional attenuation of background activity, if not artifactual, may represent a focal cerebral cortical abnormality that could give rise to partial seizures. This would be particularly true if this type of abnormality gradually disappeared over the course of a recording, suggesting that it was postictal. Secondly, bursts of rhythmic 3- to 4-Hz waves clearly unrelated to drowsiness may constitute "waves without spikes." A more prolonged recording or additional hyperventilation may reveal these to be incompletely expressed spike-wave paroxysms. A third example, occurring particularly in younger children, is posteriorly accentuated persistent rhythmic to arrhythmic delta activity

whose most common clinical correlates are a recent generalized febrile or afebrile seizure and recent mild head trauma.

---

#### ROUTINE ACTIVATING PROCEDURES

---

##### **Hyperventilation**

Production of generalized spike-wave discharges by hyperventilation can occur in about 50% of patients with absence attacks. This procedure can also elicit focal epileptiform abnormalities albeit less commonly. In children, the buildup of theta or delta waves may normally be regionally accentuated. This buildup, therefore, has to be quite predominantly hemispheric or focal before clinical significance can be ascribed to it. If hyperventilation on one occasion gives ambiguous results, these may be clarified by simply repeating the procedure.

##### **Photic stimulation**

Of the responses to photic stimulation, only the photoconvulsive (photoparoxysmal) response is associated with a seizure disorder, and this seizure disorder is generalized. Thus, Jeavons<sup>8</sup> found a photoparoxysmal response in 2.8% of all patients referred for EEG examination while Stevens<sup>9</sup> found this in 3% of patients with focal seizures. In contrast, Gastaut et al<sup>10</sup> found this in 40% of their cases of absence and in 20% of those with grand mal.

Reilly and Peters<sup>11</sup> distinguished three types of response to photic stimulation: 1) prolonged: epileptiform complexes or paroxysmal slow activity whose frequency bore no relationship to the stimulus rate and continued after stimulus termination, 2) self-limited: similar to 1) but ceasing during photic stimulation, and 3) flash-dependent: phenomena time-locked to the stimulus. Among patients whose EEGs were otherwise normal, most of those with the prolonged type had a convulsive disorder, a minority of those with the self-limited type had seizures, and none with the flash-dependent form had seizures.

Thus, spike waves appearing exclusively with photic stimulation give only supporting evidence that a seizure disorder is present. Even a clinical attack evoked by photic stimulation would not be diagnosed as a seizure disorder unless the history suggested such an association.

---

#### MONITORING

---

Monitoring is a term applied to any method that supplements the routine EEG recording by prolonging it and/or combining it with simultaneous video recording.

##### **Ambulatory cassette EEG recording**

Prolonged ambulatory EEG monitoring in the patient's own environment has been developed for the patient able to wear a cassette battery-powered EEG recording device. Its value has been impeded by the montage limitation of three channels, but nine to 16 channels are now becoming available. A user-activated, time-lapse system limits sampling to clinically significant events.

Ebersole<sup>12</sup> found that such ambulatory monitoring increased the yield of epileptiform abnormalities by a factor of 1.5 to 2.5. Aminoff et al<sup>13</sup> studied 40 epileptic and 55 nonepileptic children. Among the epileptic patients, 17 had clinical attacks, all with "appropriate" EEG changes, while some of the attacks of an additional five patients had such changes. Twenty-four of the nonepileptic children had clinical attacks during ambulatory recording, and none had electrographic alteration. The investigators felt that ambulatory EEG did support their clinical diagnosis of pseudoseizures. They cautioned, however, that the role of this device in the evaluation of patients in whom the nature of the attacks is clinically unclear remains to be established. We support this conclusion.

A second function claimed for ambulatory cassette recording is assessment of medication effect. This currently applies only to absence attacks with spike-wave paroxysms, as there is no direct correlation between quantity of other interictal epileptiform and nonepileptiform abnormalities and the incidence of simple or complex partial seizures and grand mal attacks. Although ambulatory recording does increase the sampling effect as compared to routine EEGs, such recording cannot be prolonged indefinitely, and therefore itself carries a sampling limitation. More prolonged, if intermittent, observation by the patient's close associates might be equally effective in monitoring therapy, especially as complete eradication of all spike-wave paroxysms need not be a goal. Such monitoring at home may only augment the stigma of epilepsy for some patients.



### Video recording with routine EEG

Such simultaneous monitoring would maximize the value of any clinically typical event that might occur during routine EEG. This would have particular value in supporting a diagnosis of pseudoseizures if no cerebrally originating alteration were to occur in such an attack, particularly if the patient remains unresponsive while the EEG is normal. Thus, Sheridan et al<sup>14</sup> found that the clinical impression was altered in five of 17 patients who had one or more seizures recorded: four had pseudoseizures and one (believed to have had a pseudoseizure), had in fact a complex partial seizure.

### Telemetered EEG with video recording

This in-hospital procedure is useful in selected juvenile patients who may be candidates for epilepsy surgery. Movement and other artifacts detectable by this procedure are more common in children than in most adults, but the attacks need to be sufficiently abundant and evident electrographically since children's tolerance for the procedure is more limited in time. The procedure could help to establish classification of the seizure disorder in those difficult cases in which clinical manifestations and routine EEG fail to clarify the matter.

---

### STATUS EPILEPTICUS

---

As with other age groups, the clinical expression of recurrent or continuous epileptic seizures in children may be incomplete or subtle because of an associated encephalopathy or partial eradication by anticonvulsant therapy; such seizures may also be masked by pharmacologic blockade of the neuromuscular junction. Under these circumstances, electrographic seizures may evolve slowly and irregularly and may appear bizarre. To exclude artifacts and their possible misinterpretation, prolonged monitoring in an intensive care unit is best performed with a technologist present. Intermittent monitoring would be superior to persistent unattended recording.

---

### PEDIATRIC EPILEPTIFORM PATTERNS

---

#### Hypsarrhythmia

This interictal pattern, closely associated with infantile spasms, consists of very high voltage 1- to 3-Hz waves with multifocal asynchronous spikes and sharp waves of varying morphology, location, and amplitude.

Synchronous spikes are also common. As with many EEG phenomena in the age groups of hypsarrhythmia (4 to 30 months), the spikes are more common posteriorly. Hypsarrhythmia may be confined to sleep, or its pattern may be continuous during wakefulness and interrupted by one- to two-second epochs of relative inactivity during nonrapid eye movement (nonREM) sleep.

There is a close but incomplete correlation between hypsarrhythmia and infantile spasms in that most but not all patients with hypsarrhythmia will have infantile spasms whereas about two thirds of patients with infantile spasms will have hypsarrhythmia on the first recording (see Blume<sup>15</sup> and Neidermeyer<sup>16</sup> for reviews).

During an infantile spasm, the EEG alters suddenly and diffusely. A high-voltage wave with or without a spike occurs, usually followed by diffuse attenuation (termed an electrodecremental event) upon which low-voltage high-frequency waves may be superimposed. Following the spasm, the recording may appear more normal for age for a few seconds, followed by a resumption of the hypsarrhythmia pattern.

No aspect of the interictal or ictal pattern reliably correlates with etiology, course, or prognosis. Synchronous spikes, however, may gradually predominate with time if an evolution toward slow spike waves is occurring. The pattern tends to disappear with age and is quite rare after 3 years. The EEGs then come close to normal for age or exhibit focal or multifocal spikes or slowing. Although reflecting diffuse CNS disease, infantile spasms with hypsarrhythmia may occur with unilateral cerebral infarcts.<sup>17</sup>

#### Generalized slow spike and waves

These may appear as bilaterally synchronous spike waves with a repetition rate of one to two per second or as a bilaterally synchronous complex consisting of a sharp wave followed by a slow wave, also repeating at one to two per second. The morphology of this latter form may merge with that of triphasic waves. Slow spike waves are more abundant than three-per-second spike waves and correlate less closely with clinical phenomena. Unlike their 3-Hz counterpart, hyperventilation and photic stimulation have no effect on them, but sleep augments their abundance. The background recording is usually abnormally slow for age. Normal sleep potentials may be absent. Polyspike waves, generalized polyspikes, and rhythmic 10- to 20-Hz waves may appear in sleep. Although the maximum incidence of this phenomenon occurs in children between 1 and 5 years, it may be seen even in adulthood.

Seizures occur in almost all patients with slow spike waves. Tonic seizures and atypical absences are the most common forms. Many patients have more than one type of attack, and seizures are typically therapy-resistant. Mental subnormality appears in about 75% to 80% of such patients. The seizure disorder, mental subnormality, and slow spike-wave phenomena constitute the Lennox-Gastaut syndrome.

### Fast rhythmic waves

These consist of bursts of 8- to 30-Hz widespread or generalized waves that may appear in wakefulness or sleep and may be bilateral or clearly unilateral. The usual clinical accompaniment is a tonic seizure when hypsarrhythmia or sharp-and-slow-wave complexes appear on the same recording, whereas when spike-wave complexes (SWCs) appear, the usual clinical accompaniment is an absence attack. Distinction between such activity and medication-induced beta may be difficult as the latter may also appear intermittently. Usually, the two phenomena will not have the same repetition rate; and the fast rhythmic waves may be associated with diffuse attenuation of other activity and an occasional evolution to SWDs.

### Generalized Spike-Wave Complexes

These well-known phenomena consist of bilaterally synchronous and diffuse electronegative spikes or multiple spikes followed by an almost sinusoidal slow wave lasting about 300 msec. These may occur as single complexes, brief bursts, or prolonged trains. In prolonged sequences, the spike component is usually most evident at its beginning where there may be multiple spikes. Repetition rate gradually slows as the sequence proceeds. Spike waves begin and end abruptly with an almost immediate return to the interictal EEG; rarely, frontally predominant one or two rhythmic slow waves persist for a few seconds. Fragments of SWCs are common and may be hemispheric or even regional. Their morphology usually serves to distinguish them from focal spikes. Rarely, a classical spike-wave series may be confined to a single hemisphere. Fully developed SWCs are usually maximally expressed anteriorly, but on occasion they may be seen in the parietal-occipital regions bilaterally.

Hyperventilation may elicit or increase the incidence of SWCs in about half the patients in whom they appear. Their incidence also usually increases in non-REM sleep where they may become irregular, fragmented, or appear as polyspike waves. The interparoxysmal recording may be normal but may also show

bursts of rhythmic 3- to 4-Hz waves, which may be considered as SWCs without expression of the spikes. Trains of 3-Hz rhythmic waves may appear posteriorly, from which posteriorly situated spike waves may emerge. However, neither of these nonpileptiform phenomena, without associated spike waves, carries the clinical significance of spike waves.

Over 95% of patients with generalized SWCs in the resting recording or with hyperventilation have generalized seizure disorders (see Blume<sup>15</sup> for review). The most common clinical association is absence attacks, but grand mal and myoclonic attacks are also seen in patients with such discharges. In these latter instances, SWCs are briefer and may contain multiple spikes. The type of generalized seizure disorder varies considerably from study to study, possibly reflecting different age groups:

Although most studies have demonstrated an impairment of consciousness in association with SWCs, the degree of such impairment varies considerably. Simple motor tasks are less sensitive than short-term memory, signal detection, or discriminative tasks (see Aicardi<sup>18</sup>). Photic stimulation may elicit SWCs (see above and Blume<sup>15</sup> for review).

### Rolandic spikes

These prominent diphasic or triphasic spikes characteristically localized over the lower rolandic regions classically are associated with benign epilepsy of childhood with rolandic spikes. These spikes are usually abundant and may appear independently over either rolandic region but usually predominate on one side in any given recording. They appear most prominently in the derivation F3,4-C3,4, reflecting a dipole involving these leads which can occasionally be established using a distant reference. Spikes with this typical morphology may be seen in the central or parietal sagittal area, over the parietal lobe, and even over the occipital lobe. Rarely, such spikes appear synchronously in either hemisphere when they may merge into generalized SWCs. The quantity of such rolandic spikes increases considerably in nonREM sleep, and in some patients they may appear only in sleep. Aside from transient slowing during periods of abundant spikes, the interparoxysmal recordings are classically normal.

Age at appearance of this EEG pattern closely parallels the associated seizure disorder: from 2 to 14 years. About 50% to 70% of children with rolandic spikes have the associated seizure disorder, consisting of partial motor or sensory motor seizures and occasional grand mal attacks. Such discharges support a clinical

diagnosis of epilepsy, therefore, only when symptoms are consistent with the associated seizure disorder. For example, such discharges would fail to give any support to a clinical impression of complex partial seizures of temporal lobe origin.

The relatively low percentage of patients with epilepsy indicates that rolandic spikes may be an incidental finding in a patient having an EEG for another purpose. We found left rolandic spikes in a patient with recorded right frontal seizures due to a right frontal tumor. Tumor removal eradicated the seizures but had no effect upon the left rolandic spikes. Although regional, these discharges do not represent underlying structural lesions. These must be distinguished from Mu rhythm which can also be sharply contoured, anterior temporal spikes whose fields may overlap somewhat, and asymmetrical V waves whose morphology differs from that of rolandic spikes. Of course, spikes associated with a rolandic structural lesion would appear as any such associated spikes and would also be associated with persistent background abnormalities such as delta, excess theta, or a decrease in normally appearing central rhythms including beta.

### Occipital spikes

These are usually well defined, surface negative, more abundant with eyes closed than with eyes open, and spread to the ipsilateral parietal or posterior temporal regions.

They must be distinguished from several other commonly occurring and abundant sharply contoured phenomena appearing in the posterior head regions in children's EEGs. The most common of these would be lambda waves, which are primarily electropositive and appear only with the eyes open. EKG potentials are occasionally maximally expressed posteriorly in children and could be distinguished by a monitor. Posterior slow of youth and posterior sharp-wave transients

associated with eyeblinks are other phenomena which should not be mistaken for occipital spikes. Although these two phenomena are sharply contoured, they are less so than are occipital spikes. They may more plausibly arise from the background activity than do occipital spikes.

Eeg-Olofsson et al<sup>4</sup> found occipital spikes in only two of their 743 normal children. Smith and Kellaway<sup>19</sup> found seizures in only 54% of their 318 children with occipital spikes. Nineteen percent of these children had ocular abnormalities from early life such as strabismus and congenital cataracts. Of these, only a third had seizures. Therefore, in this study, 59% of the children with occipital spikes but without ocular abnormalities had seizures.

Occipital spikes have also been described by Gastaut<sup>20</sup> in a syndrome termed benign occipital epilepsy. In this syndrome, which most commonly begins at age 6, most seizures are partial, with visual symptoms that may be followed by hemisensory, motor, or complex partial phenomena. Similarly, Camfield et al<sup>21</sup> described temporal-occipital spikes with associated generalized spike waves in adolescents who had basilar migraine and occasional focal or generalized seizures with auras. Such spikes may be abundant, and the associated seizure disorder may not always be easily controlled.

WARREN T. BLUME, MD  
Epilepsy Unit  
University Hospital  
London, Ontario, Canada N6A 5A5

---

### ACKNOWLEDGMENT

Mrs. Maria Raffa carefully prepared the manuscript.

---

### REFERENCES

1. Tharp BR. Neonatal and pediatric electroencephalography. [In] Aminoff MJ, ed. *Electrodiagnosis in Clinical Neurology*. New York, Churchill Livingstone, 1986, pp 77-124.
2. Mizrahi E, Kellaway P. Characteristics of seizures in neonates and young infants by time-synchronized electroencephalography/polygraphic/video monitoring. *Ann Neurol* 1984; **16**:383.
3. Trojaborg W. Changes of spike foci in children. [In] Kellaway P, Petersen I, eds. *Clinical Electroencephalography of Children*. New York, Grune and Stratton, 1968, pp 213-225.
4. Eeg-Olofsson O, Petersen I, Sellden U. The development of the electroencephalogram in normal children from the age of 1 through 15 years. *Paroxysmal activity*. *Neuropadiatrie* 1971; **2**:375-404.
5. Cavazzuti GB, Cappella L, Nalin A. Longitudinal study of epileptiform EEG patterns in normal children. *Epilepsia* 1980; **21**:43-55.
6. Deonna T, Ziegler A-L, Despland P-A, van Melle G. Partial epilepsy in neurologically normal children: clinical syndromes and prognosis. *Epilepsia* 1986; **27**:241-247.
7. Blume WT, Young GB, Lemieux JF. EEG morphology of partial epileptic seizures. *Electroencephalogr Clin Neurophysiol* 1984; **57**:295-302.
8. Jeavons PM. The use of photic stimulation in clinical electroencephalography. *Proc Electrophysiol Technol Assoc* 1969; **16**:225-240.
9. Stevens JR. Control and peripheral factors in epileptic discharge. *Clinical studies*. *Arch Neurol* 1962; **7**:330-338.
10. Gastaut H, Trevisan C, Naquet R. Diagnostic value of electroen-

- cephalographic abnormalities provoked by intermittent photic stimulation. *Electroencephalogr Clin Neurophysiol* 1958; **10**:194–195.
11. Reilly EL, Peters JF. Relationship of some varieties of electroencephalographic photosensitivity to clinical convulsive disorders. *Neurology* 1973; **23**:1050–1057.
  12. Ebersole JS. Ambulatory cassette EEG. *J Clin Neurophysiol* 1985; **2**(4):397–418.
  13. Aminoff MJ, Goodin DS, Berg BO, Compton MN. Clinical relevance of ambulatory electroencephalographic recording in 95 epileptic and nonepileptic children (abstr). *Ann Neurol* 1987; **22**:130.
  14. Sheridan PH, Sato S, Porter RJ. Video monitoring during a single, outpatient, routine EEG recording (abstr). *Epilepsia* 1984; **25**:653.
  15. Blume WT. *Atlas of Pediatric Electroencephalography*. New York, Raven Press, 1982.
  16. Niedermeyer E. Epileptic seizure disorders. [In] Niedermeyer E, Lopes da Silva F, eds. *Electroencephalography. Basic Principles, Clinical Applications and Related Fields*. Baltimore, Urban & Schwarzenberg, 1987.
  17. Alvarez LA, Shinnar S, Moshé SL. Infantile spasms due to unilateral cerebral infarcts. *Pediatrics* 1987; **79**:1024–1026.
  18. Aicardi J. *Epilepsy in Children*. New York, Raven Press, 1986, p 84.
  19. Smith JMB, Kellaway P. The natural history and clinical correlates of occipital foci in children. [In] Kellaway P, Petersen I, eds. *Neurological and Electroencephalographic Correlative Studies in Infancy*. New York, Grune & Stratton, 1964.
  20. Gastaut H. L'épilepsie bénigne de l'enfant à pointe-ondes occipitales. *Rev Electroencephalogr Neurophysiol Clin* 1982; **12**:179–201.
  21. Camfield PR, Metrakos K, Andermann F. Basilar migraine, seizures, and severe epileptiform EEG abnormalities. *Neurology* 1978; **28**:584–588.