



# Intra-aortic balloon-pump rupture and entrapment

GEORGE K. BRODELL, MD; E. MURAT TUZCU, MD; STEVEN J. WEISS, MD; CONRAD SIMPFENDORFER, MD

■ The authors report a case of intra-aortic balloon rupture and entrapment in a patient with extensive vascular disease. The balloon was subsequently removed percutaneously. A review of the diagnosis and management of this unusual complication is presented.

□ INDEX TERMS: CASE REPORTS; INTRA-AORTIC BALLOON PUMPING, COMPLICATIONS □ CLEVE CLIN J MED 1989; 56:740-742

**S**INCE the introduction in 1967 of the intra-aortic balloon pump (IABP) for the support of patients in cardiogenic shock, the indications for its use have widened considerably. The incidence and spectrum of complications related to the IABP have been well defined.<sup>1</sup> Rupture and entrapment of the intra-aortic balloon (IAB) are rare complications that generally require surgical management. We report a case in which the IAB ruptured, was entrapped, and subsequently was removed percutaneously.

## CASE REPORT

A 51-year-old white woman was first admitted to another hospital on May 25, 1988, with the diagnosis of asthma. Three days later, she sustained a lateral myocardial infarction, became hypotensive, and required in-

creasing doses of vasopressor drugs. On May 31, 1988, she was transferred to the Cleveland Clinic. Upon arrival, she was in cardiogenic shock. Using fluoroscopic guidance, a 9.5-F Datascope IAB was inserted percutaneously over a guide wire via the right femoral artery. At the time of IAB placement, the femoral and iliac arteries were noted to be calcified and tortuous. Heparin was given and the level was maintained by constant infusion.

The next day, the patient underwent cardiac catheterization, which revealed subtotal obstruction of a large, dominant, left circumflex artery and 50% obstruction of the proximal left anterior descending artery. She subsequently underwent percutaneous transluminal coronary angioplasty of the circumflex coronary artery from a right brachial approach.

On the fourth day following IAB insertion, blood was noted in the safety chamber and IAB perforation was diagnosed. There was no prior indication of IAB perforation, such as loss of augmentation, alarm signals, or increased frequency of IAB filling. The IABP was stopped and the line clamped. Initial attempts to remove the IAB were unsuccessful; gentle traction did not result in movement. Under fluoroscopy, contrast medium was injected slowly to visualize the IAB and related structures. A small perforation was noted in the distal portion of the IAB. Filling defects were seen in

From the Departments of Cardiology and Cardiothoracic Surgery, The Cleveland Clinic Foundation. Submitted Aug 1988; accepted Nov 1988. Present location of S.J.W.: Department of Cardiothoracic Surgery, Albert Einstein Medical Center, Philadelphia, Pennsylvania.

Address reprint requests to C.S., Department of Cardiology, The Cleveland Clinic Foundation, One Clinic Center, 9500 Euclid Avenue, Cleveland, Ohio 44195.

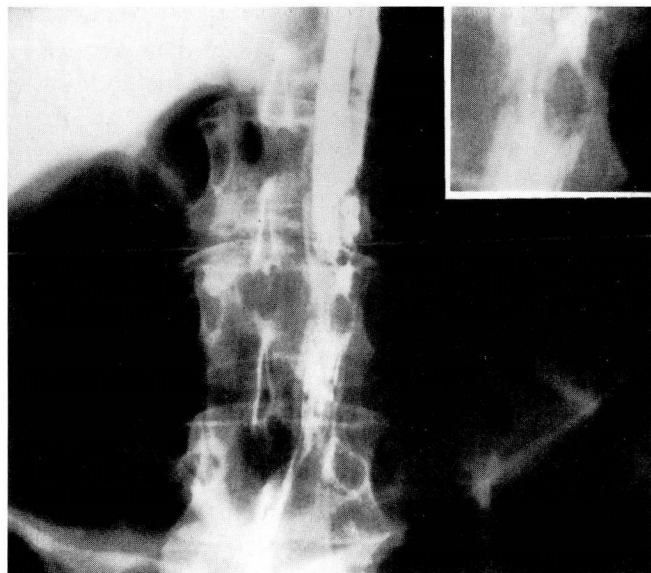


FIGURE 1. Filling defect suggesting clot formation in the balloon filled with contrast material. The insert shows a close-up of the filling defect.

the IAB, which suggested thrombus formation (Figure 1). Intravenous heparin infusion was continued, and the activated partial thromboplastin time was 58.7 seconds (control range, 21–31 seconds). The IAB and sheath were partially extracted but remained at the level of the thoracic aorta. Under fluoroscopic guidance, gentle continuous traction was applied after maximally deflating and wrapping the IAB. Further aggressive traction resulted in withdrawal of the IAB to the level of the right iliac artery. The distal assembly of the IAB was removed, and the 9.5-F sheath was replaced by a 14-F sheath. With continued traction, the distal segment of the IAB was intussuscepted upon itself, and the sheath and IAB were extracted in toto. Inspection of the IAB revealed a small perforation in the distal portion. A firm clot in the shape of an hourglass at the midportion was noted (Figure 2). Full anticoagulation with heparin was continued throughout this period. For the next several hours, the lower extremities became warmer and pulses became palpable. Leukocytosis and fever developed, and antibiotic therapy was initiated. The patient died 15 days later of cardiogenic shock. Autopsy showed a large, organized myocardial infarction in the posterior-lateral distribution. The abdominal and thoracic aorta and all of its major branches showed extensive atherosclerotic changes and calcified, ulcerated plaques.

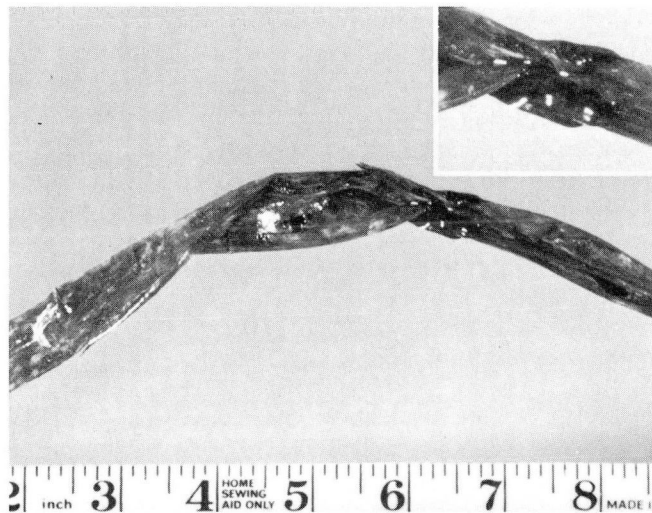


FIGURE 2. Hourglass-shape clot in the extracted intra-aortic balloon. The insert shows a close-up of the clot in the balloon.

#### DISCUSSION

Vascular complications secondary to IABP occur in about 10% of patients undergoing this therapy.<sup>2</sup> Major vascular complications can be expected in up to 30% of patients with peripheral vascular disease.<sup>3</sup> Perforation of the IAB is rare and has been attributed to abrasion of the IAB membrane secondary to contact with calcified atherosclerotic plaques.<sup>4,5</sup> In our patient, there was fluoroscopic and autopsy evidence of extensive calcified atherosclerotic disease in the thoracic and abdominal aorta.

IAB entrapment as a consequence of IAB perforation has been reported by Milgalter et al<sup>5</sup> and Aru et al.<sup>6</sup> These reports were associated with the Koutron balloon catheter. In previously reported cases, the presence of clot in the IAB lumen caused entrapment of the IAB in the femoral artery, and surgical removal was required. In our patient, the IAB became lodged higher in the thoracic aorta. Surgical removal would have required a major operation, and given the status of the patient, would have involved an unacceptable risk. Thus we elected to remove the IAB percutaneously, aware that this could be complicated by a serious arterial laceration.

Not all IAB perforations are complicated by entrapment. Perhaps the best way to avoid entrapment is by early diagnosis of IAB perforation, before the formation of large, hard, intraluminal clots. Early IAB rupture could be signaled by loss of augmentation and/or increased frequency of IAB filling, although increased

frequency of automatic filling in the newer systems might not be noted and gas loss through microscopic IAB penetration might be minimal. Appearance of blood in the line connecting the IAB to the safety chamber should be considered an early warning sign. In this case, noting blood when it arrived in the safety chamber might have caused some delay in diagnosing

the problem. Prompt removal of the IAB might avoid intraluminal thrombus formation and make percutaneous removal less traumatic. Intraluminal infusion of streptokinase to dissolve clot has been suggested.<sup>7</sup> Surgical removal in case of IAB entrapment, signalled by difficulty in removing the IAB, is still the treatment of choice for this rare complication.

#### REFERENCES

1. Kantrowitz A, Wasfie T, Freed PS, Rubenfire M, Wajszczuk W, Schork MA. Intraaortic balloon pumping 1967 through 1982: analysis of complications in 733 patients. *Am J Cardiol* 1986; **57**:976-983.
2. McEnany MT, Kay HR, Buckley MJ, et al. Clinical experience with intraaortic balloon pump support in 728 patients. *Circulation* 1978; **58**(suppl 1):124-132.
3. Gottlieb SO, Brinker JA, Borkon AM, et al. Identification of patients at high risk for complications of intraaortic balloon counterpulsation: a multivariate risk analysis. *Am J Cardiol* 1984; **53**:1135-1139.
4. Mayerhofer KE, Billhardt RA, Codini MA. Delayed abrasion perforation of two intra-aortic balloons. *Am Heart J* 1984; **108**:1361-1363.
5. Milgalter E, Mosseri M, Uretzky G, Romanoff H. Intraaortic balloon entrapment: a complication of balloon perforation. *Ann Thorac Surg* 1986; **42**:697-698.
6. Aru GM, King JT Jr, Hovaguimian H, Floten HS, Ahmad A, Starr A. The entrapped balloon: report of a possibly serious complication. *J Thorac Cardiovasc Surg* 1986; **91**:146-149.
7. Lambert CJ. Intraaortic balloon entrapment (letter). *Ann Thorac Surg* 1987; **44**:446.

