

# Quantification of temporal lobe resections: a new approach

ISSAM A. AWAD, MD; AMIRAM KATZ, MD; HANS LÜDERS, MD; MEREDITH WEINSTEIN, MD

■ Extent of resection in temporal lobectomy has been traditionally based on intraoperative linear measurements. The complex geometrical contour of the temporal lobe limits the precision and accuracy of such measurements, and it is often difficult to verify the extent of actual resection after surgery. The authors propose a new method of evaluating extent of resection based on a 20-compartment model of the temporal lobe. The temporal lobe is divided into five anteroposterior coronal sections in relation to the anterior and posterior borders of the mesencephalon. Each section is then divided into superior lateral, inferior lateral, basal, and medial quadrants. The resulting compartments are easily identified on postoperative magnetic resonance images obtained along the coronal plane. Resection within each compartment is noted as none (0), partial (1), or complete (2). An index of resection can then be computed for superior lateral, inferior lateral, basal, and medial quadrants and for the whole temporal lobe. Potentially, this technique can be used to evaluate surgical failures and correlate extent of resection with surgical outcome and neurologic complications. It also allows objective and semiquantitative comparison of surgical approaches practiced at different institutions.

□ INDEX TERMS: BRAIN, SURGERY; TECHNICAL NOTES; TEMPORAL LOBE □ CLEVE CLIN J MED 1989; 56:833-836

**T**EMPORAL LOBECTOMY has become a widely accepted surgical treatment for intractable epilepsy of temporal-lobe origin. However, surgical procedures, and thus the extent of resection of different temporal-lobe anatomic structures, differ from center to center.<sup>1-3</sup> At a single institution, it is difficult to verify that resection has been consistently done according to plan. Precise assessment of extent of resection of various portions of the temporal

lobe is essential to analyze surgical outcome, as well as to evaluate different surgical approaches and to plan possible future modifications.

Several authors have correlated postoperative seizure outcome, memory changes, and neurologic complications (visual, speech, and motor deficits) with extent of resection of the temporal lobe, as estimated from drawings and measurements performed at surgery.<sup>4-14</sup> These estimates, however, were based on linear and, at best, two-dimensional representations from which volumetric conclusions were drawn. The fate of the deep medial structures (amygdala and hippocampus) has been deduced from these surface measurements or from the surgeon's impression. Because many centers use a surgical technique in which the medial structures are aspirated,<sup>2</sup> pathological identification of excised medial structures

From the Departments of Neurosurgery (I.A.A.), Neurology (A.K., H.L.), and Neuroradiology (M.W.), The Cleveland Clinic Foundation. Submitted April 1989; accepted June 1989.

Address reprint requests to I.A.A., Department of Neurosurgery, The Cleveland Clinic Foundation, One Clinic Center, 9500 Euclid Avenue, Cleveland, Ohio 44195.

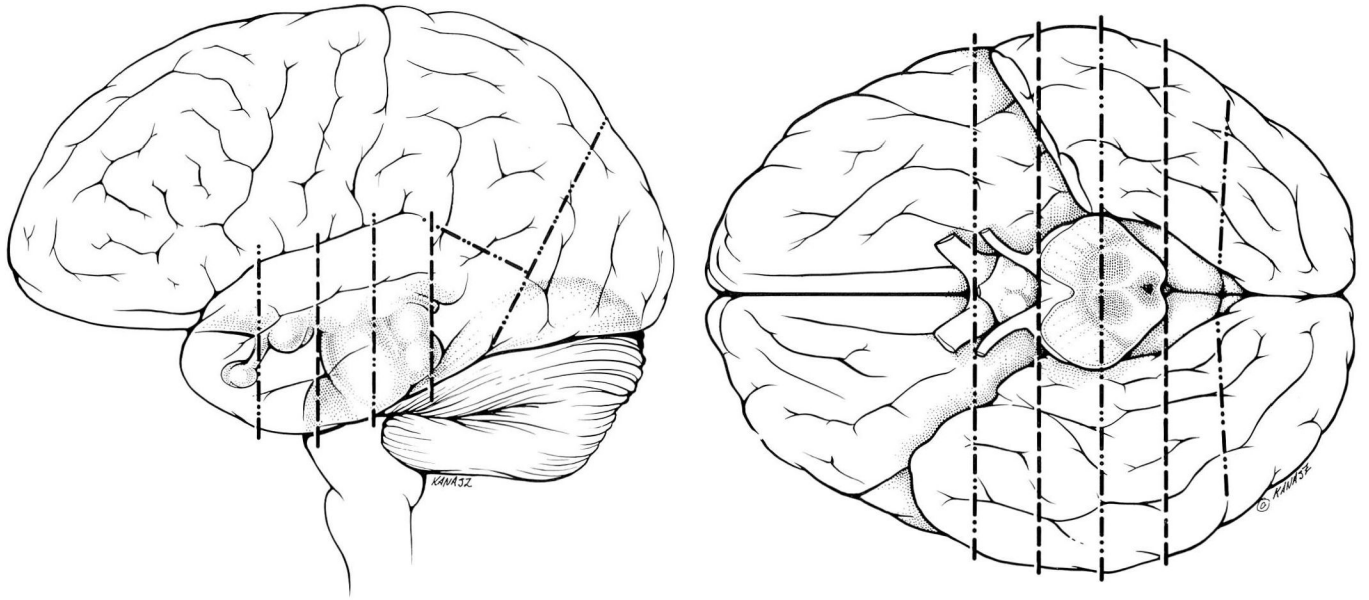


FIGURE 1. Five coronal layers of the temporal lobe. FIGURE 1A. Basal view. FIGURE 1B. Lateral view. Primary coronal planes are delineated by dashes. The secondary coronal planes are delineated by dots and dashes.

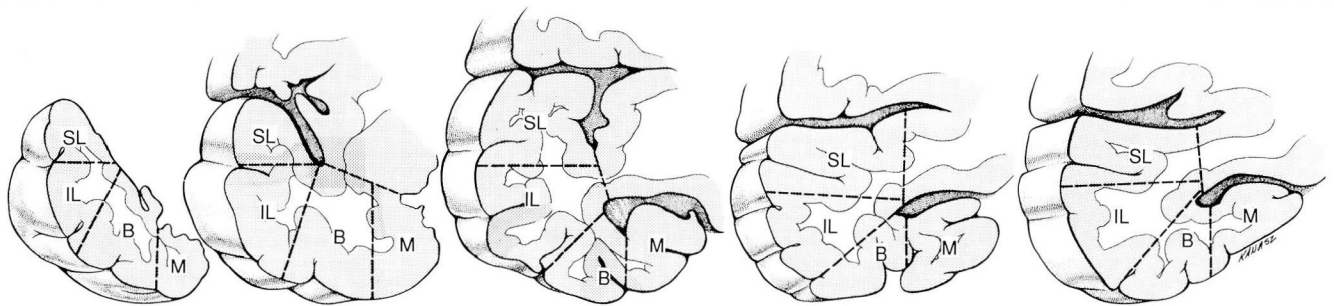


FIGURE 2. Compartmental model of the temporal lobe. The five coronal layers are subdivided into four quadrants. B = basal; IL = inferior lateral; M = medial; SL = superior lateral.

is often suboptimal.

Intraoperative linear measurements are limited by gross imprecisions since the temporal lobe has a complex contour that does not lend itself to simple geometric approximation. Cerebrospinal fluid drainage and intraoperative brain shifts further limit the precision and accuracy of these measurements. Also, a given lateral resection border can be beveled in various directions, producing widely different excisions of basal and medial structures. Lastly, ischemic or compressive damage to unresected brain can go unrecognized at surgery

but can affect the extent of “actual resection.”

Postoperative imaging provides the most accurate and reliable means of assessing extent of resection. Precise volumetric calculations can be performed with available software and postoperative computed-tomographic (CT) scans or magnetic resonance images (MRI).<sup>15,16</sup> Yet, the volume of tissue resected does not necessarily reflect specific structures excised. Because of these considerations, we have developed a three-dimensional model of the temporal lobe with 20 compartments easily recognizable on routine postoperative MRI.

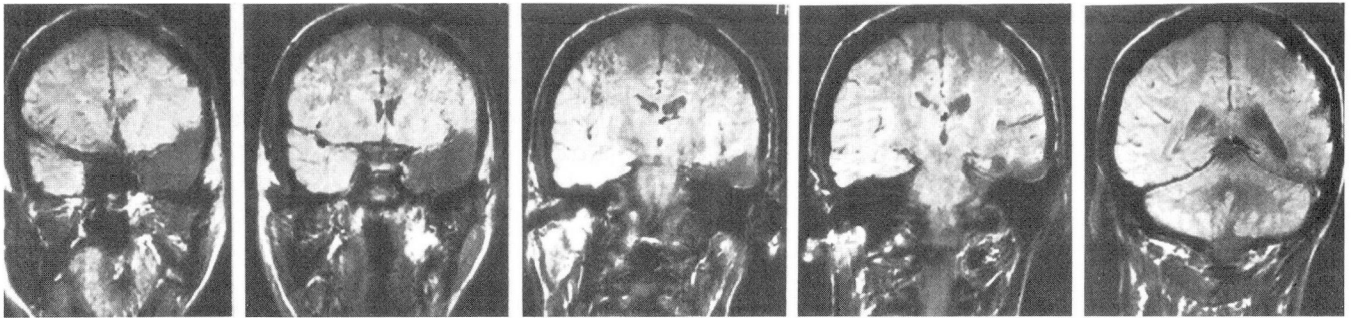


FIGURE 3. MRI images illustrate the five coronal sections in a case of left temporal lobectomy.

TECHNIQUE

The temporal lobe is divided into five coronal sections by four coronal planes (Figure 1). Two primary coronal planes are determined by the anterior and posterior borders of the mesencephalon. Two secondary coronal planes bisect the pre-mesencephalic and paramesencephalic portions of the temporal lobe, respectively. Each coronal section is further divided into four quadrants (Figure 2). The temporal lobe thus comprises 20 compartments that are easily identified on postoperative MRI scans obtained along the coronal plane (Figure 3).

The extent of resection is evaluated and recorded on a standardized form containing diagrammatic blanks of all coronal sections and their compartments (Figure 4). Each compartment is given a resection score of 0 (all tissue present), 1 (incomplete resection), or 2 (complete resection). An index of resection estimating the anteroposterior extent of resection of each quadrant is calculated by adding the resection scores of all five compartments of that quadrant. Therefore, for each quadrant, indexes of resection range from 0 to 10. For the whole temporal lobe, the index of resection ranges from 0 to 40 (the sum of the indexes of resection of the four quadrants). In addition, extent of resection of amygdalohippocampal structures is noted separately by assessing excision of the upper half of the medial compartments in sections 2–5.

DISCUSSION

Accurate assessment of extent of temporal lobectomy is essential to the analysis of surgical outcome. The technique described here is based on postoperative MRI rather than intraoperative measurements, and therefore provides an account of actual resection while minimiz-

Quantitative Temporal Lobectomy Evaluation

Patient Name \_\_\_\_\_  
 Clinic No. \_\_\_\_\_  
 Surgery No. \_\_\_\_\_  
 Surgery Date \_\_\_\_\_  
 MRI Date \_\_\_\_\_  
 Preop Diagnosis \_\_\_\_\_  
 \_\_\_\_\_  
 \_\_\_\_\_

Tissue Resected *				
	M	B	LI	LS
1				
2				
3				
4				
5				
Total				

\* 0-no resection  
 1-partial resection  
 2-complete compartment resection

RIGHT LEFT

1 2 3 4 5

Examiner initials \_\_\_\_\_  
 Date \_\_\_\_\_

FIGURE 4. Quantitative temporal lobectomy “scoring sheet.” For each of the five coronal sections, extent of resection is noted for the medial quadrant (M), basal quadrant (B), inferior lateral quadrant (IL), and superior lateral quadrant (SL). Resection of each of the 20 compartments is scored as 0 (no resection), 1 (partial resection), or 2 (complete resection).

ing investigator bias. In addition to semiquantitative information, the model allows an anatomic definition of the resection. Extent of resection of medial structures

carries particular anatomic relevance: the posterior pre-mesencephalic level (section 2) contains most of the amygdaloid nucleus, while the paramesencephalic levels (sections 3 and 4) contain the hippocampal formation. Our method does not require special equipment or software and allows easy comparison of resections from different institutions.

Other potential applications of this method include correlation of extent of resection with seizure outcome, memory changes, visual field defects, and other neurologic complications following temporal lobectomy. These correlations can be performed blindly and in a semiquantitative fashion and can potentially address the role of medial *v* lateral resections in prospective trials.

Asymmetry and dysmorphism of the temporal lobe, shifting of unresected tissue into the lobectomy cavity, and progressive postoperative dilation of the ipsilateral temporal horn are potential problems with this method. To our knowledge, however, this technique represents the first serious attempt at quantifying extent of temporal lobectomy in an objective, anatomically relevant, and widely applicable fashion.

We have used this approach at the Cleveland Clinic for one-and-a-half years and are currently submitting it to rigorous reliability, reproducibility, and interobserver validation studies. The results of these studies and of preliminary outcome correlations are beyond the scope of this technical report and will be published separately.

#### REFERENCES

1. Falconer MA. Anterior temporal lobectomy for epilepsy. [In] Logue V, ed. *Operative Surgery*. Vol. 14. London, Butterworth, 1971, pp 142–149.
2. Olivier A. Cortical resections. [In] Engel J, ed. *Surgical Treatment of the Epilepsies*. New York, Raven Press, 1987, pp 405–516.
3. Yasargil MG, Teddy PJ, Roth P. Selective amygdalo-hippocampectomy: operative anatomy and surgical techniques. *Adv Tech Stand Neurosurg* 1985; 12:93–123.
4. Bengzon ARA, Rasmussen T, Gloor P, et al. Prognostic factors in the surgical treatment of temporal lobe epileptics. *Neurology* 1968; 18:717–731.
5. Cahan LD, Sutherling W, McCullough MA, et al. Review of the 20-year UCLA experience with surgery for epilepsy. *Cleve Clin Q* 1984; 51:313–318.
6. Dinner DS, Lüders H, Lesser RP, et al. Relationship of memory changes after temporal lobectomy and extent of resection. *Neurology* 1986; 36(suppl 1):294–295.
7. Hahn JF, Sellers M. Surgical techniques for relief from seizures. *Cleve Clin Q* 1984; 51:307–311.
8. Incisa della Rochetta A. Classification and recall of pictures after unilateral frontal or temporal lobectomy. *Cortex* 1986; 22:189–211.
9. Jensen I, Vaernet K. Temporal lobe epilepsy: follow-up investigation of 74 temporal lobe resected patients. *Acta Neurochir* 1977; 37:173–200.
10. Marino R, Rasmussen T. Visual field changes after temporal lobectomy in man. *Neurology* 1968; 18:825–835.
11. Ojemann GA, Dodrill CB. Verbal memory deficits after left temporal lobectomy for epilepsy. *J Neurosurg* 1985; 62:101–107.
12. Penfield W, Lende RA, Rasmussen T. Manipulation hemiplegia: an untoward complication in the surgery of focal epilepsy. *J Neurosurg* 1961; 18:760–776.
13. Spencer DD, Spencer SS. Surgery for epilepsy. *Neurol Clin North Am* 1985; 3:313–330.
14. Van Buren JM, Ajmone Marsan C, Mutsuga N, et al. Surgery of temporal lobe epilepsy. [In] Purpura DP, Penry JK, Walter RD, eds. *Advances in Neurology: Neurosurgical Management of the Epilepsies*. Vol 8. New York, Raven Press, 1975, pp 155–196.
15. Bolender NE, Wyler AR. CT measurements of mesial temporal lobe herniation in epileptics. *Epilepsia* 1982; 23:409–416.
16. Clifford RJ, Gehring DG, Sharbrough FW, et al. Temporal lobe volume measurement from MR images: accuracy and left-right asymmetry in normal persons. *J Comput Assist Tomogr* 1988; 12:21–29.