



# Mosaic hair color changes in alopecia areata

ANNE K. MCBRIDE, MD AND WILMA F. BERGFELD, MD

■ This paper documents the mosaic hair color changes in two patients with extensive alopecia areata. The authors suggest that these changes are the end result of localized immunologic reactions directed against the melanocyte, resulting in a cytotoxic effect on the melanocytes and altering the hair color. Visually, the change is identified as patchy lightening, occasional depigmentation, and whitening of existing scalp hair. These changes reflect increased activity and progression of alopecia areata.

□ INDEX TERMS: ALOPECIA AREATA; HAIR COLOR □ CLEVELAND CLINIC JOURNAL OF MEDICINE 1990; 57:354-356

**A**LOPECIA is a complex disease, and its etiology and pathophysiology are still unclear. Several factors are associated with alopecia areata, including emotional stress, genetic predisposition, defects in autoimmunity, and atopic state.<sup>1,2</sup> Alopecia areata is usually characterized by hair loss in well-circumscribed areas of the scalp. The hair may regrow within a few months. The new hairs are often fine and unpigmented and may eventually regain normal diameter and color. The following two cases represent hair-color changes associated with alopecia areata.

## CASE REPORTS

### Case 1

A 7-year-old girl was examined in November 1974 with a 6-week history of significant hair loss that resulted in alopecia totalis. Results of a scalp biopsy confirmed the clinical diagnosis of alopecia areata. Over 13 years of follow-up, she has had a full head of hair (total

regrowth) with episodic development of active alopecia areata involving 10% to 35% of the total scalp. The patient's medical history was significant for severe chronic atopic dermatitis and allergic rhinitis. On 12 separate occasions when she experienced flares of an atopic condition, she had exacerbations of her alopecia areata. These flares usually occurred in autumn. In addition, she noted flares several times when she was desensitized with intradermal injections of allergens, such as dust and mold. Her disease has been well controlled with intralesional corticosteroids and continuous oral prednisone (7.5 mg/d).

The interesting aspect of this patient's alopecia areata is that prior to each hair loss, she noticed that specific areas of hair turned carrot orange and were associated with increased pruritus of skin. Her normal hair color is auburn. Hair regrowth was initially blond with gradual repigmentation to auburn. Once we recognized these patterns, the areas were injected with corticosteroids at the time of pruritus prior to hair loss to prevent the occurrence of alopecic patches. Most of the time, this treatment was successful.

### Case 2

A 49-year-old white man was first examined in November 1977 with a 2-year history of hair loss of the body and head, which resulted in alopecia universalis.

From the Department of Dermatology, The Cleveland Clinic Foundation.

Address reprint requests to W.F.B., Department of Dermatology, The Cleveland Clinic Foundation, One Clinic Center, 9500 Euclid Avenue, Cleveland, Ohio 44195

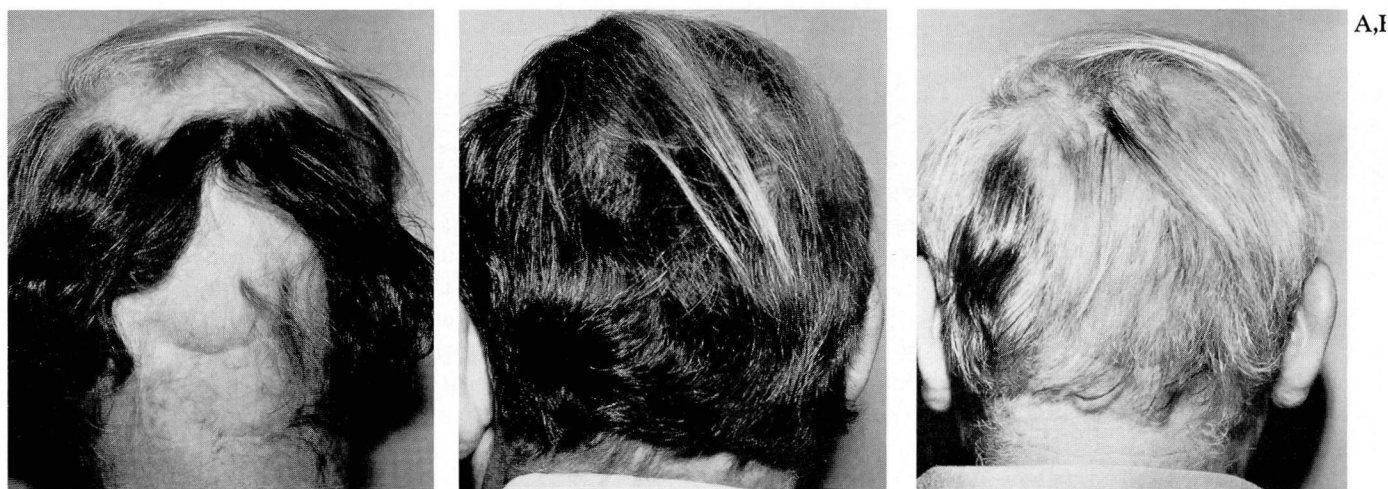


FIGURE 1. Case 2. FIGURE 1A. A 49-year-old man with alopecia areata totalis, which progressed to alopecia universalis (1977). FIGURE 1B. Regrowth of alopecia totalis with streaks of white terminal hair (1979). FIGURE 1C. Exacerbation of alopecia totalis with diffuse and patchy hair loss. Note change in hair color (1981).

At presentation, his alopecia involved eyebrows, eyelashes, small areas on the chest and legs, male-pattern frontal baldness, and a large area of hair loss on the occiput. Over 10 years of follow-up, he had had a full head of hair with episodic development of active alopecia areata involving 10% to 50% of the scalp and mild loss of eyebrows and eyelashes. He had had hypertension for 5 years and gout for 3 years.

Relapses corresponded with stressful times in his life and with the tapering of systemic steroids. His alopecia was well controlled with intralesional corticosteroids, systemic oral prednisone (5 mg/d to 30 mg/d), and topical dinitrochlorobenzene (DNCB) 0.1% to 0.2%.

The interesting aspect of this patient's case was the spectrum and pattern of hair color with regrowth. He demonstrated a spectrum of patchy hair color from white to gray to black and then a reversal of these colors in a wave of mosaic patterns (Figure 1). Over the next 10 years, his hair grew in mosaic waves. Single hairs would display all three colors. His original hair color was black with mild graying. One area consistently treated with DNCB regrew black without changing colors.

#### DISCUSSION

Hair color results from transfer of melanosomes from melanocytes to newly formed keratinocytes. These melanocytes are situated in the hair bulb at the apex of the dermal papilla. The melanosomes are situated close to the nucleus in the Golgi region within the cytoplasm

of the melanocytes. As the melanosomes mature and enlarge,<sup>3</sup> they migrate away from the nuclear region and enter the dendritic processes from which they are transferred to adjacent keratinocytes.<sup>4</sup> The intensity of hair color is determined by the quality and density of pigment in the cortex of the hair.

Melanocytes are only active in depositing melanosomes during anagen, the actively growing stage of the hair cycle. There have been several theories as to the fate of these inactive melanocytes in late anagen and subsequent telogen, the final stage of hair growth. It was formerly proposed that melanocytes degenerate and disappear during telogen.<sup>3</sup> Rook and Dawber<sup>5</sup> stated that the hair matrix melanocytes degenerate during catagen, but during telogen they remain at the surface of the papilla in a shrunken dendritic form. In a light- and electron-microscopic study of the regrowing white hair in alopecia areata, Messenger and Bleehen<sup>6</sup> stated that the number of melanocytes and their melanization were much less than in the normal pigmented follicle, and pigment transfer was rarely seen. Prior to the termination of anagen, scalp follicles show a lightening of the pigment at the base of the shaft as the melanocytes cease to produce melanosomes and transfer melanin.

Alopecia areata is characterized by well-circumscribed, round or oval, nonscarred areas of hair loss. It is caused by sporadic increases of hair follicles in telogen and is preceded by anagen and catagen, the brief transitional stage prior to telogen. In telogen, the hair follicle regresses, and hair is shed. In the normal scalp, telogen

hairs constitute 10% to 15% of scalp hair, but in chronic alopecia areata, a larger percentage is entering into telogen.<sup>7</sup> In alopecia areata, a patch of follicles prematurely enters telogen in a wavelike pattern from the center of the patch outward. In extremely acute alopecia areata, hairs fall out while still in anagen. In either event, histologically, there is a predominantly lymphocytic infiltrate around the anagen and catagen hair bulbs. These events explain the carrot orange and whitening of hair at the site of increased activity of alopecia areata in *Case 1*. This patient had increased hair loss with her atopic flare. With early treatment of the atopic flare, focal discoloration of hair and hair loss were averted most of the time.

*Case 2* illustrates another color change that has been classically documented in alopecia areata—mosaic whitening of hair.<sup>8</sup> The white hairs present at the onset of alopecia areata are spared and not lost, while the pigmented hairs are frequently lost. This has been reported in patients whose hair suddenly appeared to have turned white.<sup>9,10</sup> Black or gray hairs appear to be more vulnera-

ble to the alopecia process than white hair. As mentioned previously, alopecia areata has been associated with a defect in immunity or immunoregulation.<sup>1</sup> It has also been previously suggested that the primary immune reaction is directed against the melanocyte of the hair bulb.<sup>11</sup>

In alopecia areata, we believe a cytotoxic event occurs that either fully or partially destroys the melanocytes. In the partially destroyed melanocytes, the dendrites are injured and regress; with healing, they resume normal structure and function. The color changes seen in our cases corresponded with the local activity of their disease. In active areas of alopecia areata, hair that was carrot orange or white appeared to be secondary to melanocytic death or partial destruction. As inflammation decreased and melanocytes were restored, hair color was gradually restored (that is, carrot red to auburn and white to gray to black). The clinical mosaic changes of hair color in patients with alopecia areata reflect activity of the alopecic condition.

# REFERENCES

1. Sauder DN, Bergfeld WF, Krakauer RS. Alopecia areata: an inherited autoimmune defect. [In] Brown AC, Crounse RG, eds. *Hair, Trace Elements, and Human Illness*. New York, Praeger, 1980, pp 343–347.
2. Penders AJM. Alopecia areata and atopy. *Dermatologica* 1968; 136:395–399.
3. Wilkinson RD. Sudden melanization arrest. [In] Brown AC, Crounse RG, eds. *Hair, Trace Elements, and Human Illness*. New York, Praeger, 1980, pp 187–193.
4. Jimbow K, Kukita A. A fine structure of pigment granules. [In] Kamamura T, Fitzpatrick TB, Seiji M, eds. *Biology of Normal and Abnormal Melanocytes*. Baltimore, University Park Press, 1971, pp 171–193.
5. Rook AJ, Dawber R. *Diseases of the Hair and Scalp*. Oxford, Blackwell Scientific, 1982, p 348.
6. Messenger AG, Bleeen SS. Alopecia areata: light and electron microscopic pathology of the regrowing white hair. *Br J Dermatol* 1984; 110:155–162.
7. Ebling FS. Biology of hair follicles. [In] Fitzpatrick TB, Eisen AZ, Wolff K, Freedberg IM, Austen KF, eds. *Dermatology in General Medicine*, Third Edition. New York, McGraw-Hill, 1986, pp 213–219.
8. Klingmuller VG. Über "plotzliches weisswerden" und psychische Traumen bei der Alopecia areata. *Dermatologica* 1958; 117:84–92.
9. Helm F, Milgrom H. Can scalp hair suddenly turn white? A case of canities subita. *Arch Dermatol* 1970; 102:102–103.
10. Ortonne J-P, Jeune R. Hair color and alopecia areata (letter). *Arch Dermatol* 1978; 114:1716–1717.
11. De Villez RL, Buchanan JM. The graying phenomenon: an unusual manifestation of alopecia areata. *Int J Dermatol* 1982; 21:344–346.