

Thrombotic thrombocytopenic purpura in a patient with AIDS

GLENN H. SEGAL, DO; RAYMOND R. TUBBS, DO; NORMAN B. RATLIFF, MD; MICHAEL L. MILLER, DO; DAVID L. LONGWORTH, MD

■ Thrombotic thrombocytopenic purpura (TTP) has only recently been documented in association with human immunodeficiency virus infection. The authors present the clinical, laboratory, and pathologic features of a unique case of secondary thrombotic thrombocytopenic purpura occurring in a patient with AIDS, including the immunohistologic characterization of the vascular thrombi. They also review 12 previously reported cases of thrombotic thrombocytopenic purpura associated with human immunodeficiency virus infection.

□ INDEX TERMS: ACQUIRED IMMUNODEFICIENCY SYNDROME; PURPURA, THROMBOTIC THROMBOCYTOPENIC □ CLEVE CLIN J MED 1990; 57:360-366

THROMBOTIC thrombocytopenic purpura (TTP) is characterized by the pentad of microangiopathic hemolytic anemia (MAHA), thrombocytopenia, neurologic disturbances, renal alterations, and fever. Although most cases are idiopathic, occurring abruptly in otherwise healthy individuals,¹ the disorder has been associated with underlying connective tissue diseases, malignancies, and a variety of systemic infections.² In the face of such an associated disease, the term *secondary TTP* is preferred. Recently, TTP has been described in patients seropositive for the antibody to the human immunodeficiency virus (HIV), suggesting an association with this infection.³⁻⁷

We report the case of a 31-year-old HIV-seropositive white man with acquired immune deficiency syndrome

(AIDS) who presented with rectal bleeding, thrombocytopenia, and MAHA, with subsequent complete development of the classic pentad of TTP. The patient's course was marked by poor response to plasma exchange therapy and rapid clinical deterioration with death on the 16th hospital day. Postmortem examination demonstrated widespread platelet thrombi in the arterial microvasculature, which are characteristic of this syndrome.

We present the clinical, laboratory, and pathologic features of this unique case of secondary TTP, including the immunohistologic characterization of the vascular thrombi, along with a review of the reported cases of TTP associated with HIV-related disease.

CASE PRESENTATION

The patient was a 31-year-old white man with AIDS (CDC class 4 HIV-related disease) diagnosed in July 1986. He presented initially with *Pneumocystis carinii* pneumonia and was discovered to be HIV seropositive. AZT (zidovudine) therapy was instituted in November of that year. Over the following 14 months, he was hospitalized five times because of pneumonia caused by

From the Departments of Pathology (G.H.S., R.R.T., N.B.R.), Laboratory Hematology (M.L.M.), and Infectious Disease (D.L.L.), The Cleveland Clinic Foundation.

Address reprint requests to G.H.S., Department of Pathology, The Cleveland Clinic Foundation, One Clinic Center, 9500 Euclid Avenue, Cleveland, Ohio 44195.

P. carinii, *Mycoplasma pneumoniae*, and *Streptococcus pneumoniae*; severe dehydration; and cytomegalovirus (CMV) retinitis.

AZT was discontinued in early March 1988 because of significant bone marrow suppression. A complete blood count obtained several weeks later disclosed hemoglobin, 9.0 g/dL (normal, 13.5–17.5 g/dL); hematocrit 27% (normal, 40% to 52%); platelets, $100 \times 10^3/\mu\text{L}$ (normal, $150\text{--}400 \times 10^3/\mu\text{L}$); and white blood cells, $4.0 \times 10^3/\mu\text{L}$ (normal, $4.0\text{--}11.0 \times 10^3/\mu\text{L}$). Pertinent laboratory findings included a T helper/inducer (CD4) lymphocyte count of 1 cell/ μL (normal, 436–1394 cells/ μL), a T suppressor/cytotoxic (CD8) lymphocyte count of 25 cells/ μL (normal, 166–882 cells/ μL), and a CD4/CD8 ratio of 0.04 (normal, 0.5–3.3). CMV was cultured from peripheral blood buffy coat samples.

In late April 1988 the patient presented to The Cleveland Clinic Foundation with a 1-day history of hematochezia. He was alert and oriented. He was afebrile and his blood pressure was 120/90 mmHg. Physical examination was unremarkable except for candidal plaques on the surface of the tongue and gross blood on rectal inspection.

Initial laboratory values included hemoglobin, 6.9 g/dL; hematocrit, 19.6%; platelets, $90 \times 10^3/\mu\text{L}$; white blood cells, $3.3 \times 10^3/\mu\text{L}$; serum lactic dehydrogenase (LDH), 665 IU/L (normal, 100–185 IU/L); serum total bilirubin, 1.6 mg/dL (normal, 0.3–1.5 mg/dL); blood urea nitrogen, 37.0 mg/dL (normal, 10–20 mg/dL); and serum creatinine, 1.6 mg/dL (normal, 0.7–1.4 mg/dL).

Examination of the peripheral blood smear by a staff hematopathologist showed occasional red blood cell fragments. Prothrombin time, activated partial thromboplastin time (APTT), and fibrinogen were within normal limits. Urinalysis disclosed 1+ protein, 2+ hemoglobin, three to five red blood cells per high-power field, 11 to 25 white blood cells per high-power field, and no bilirubin or urobilinogen.

On the day after admission, the patient had a generalized tonic-clonic seizure. No focal neurologic deficits were identified, and a computed tomographic scan of the head with and without contrast medium was negative. Although no further seizures were witnessed, lethargy, transient confusion, and dysarthria progressed to stupor and coma.

The patient continued to manifest laboratory features of MAHA, including a marked increase in the number of erythrocyte fragments, elevation of serum LDH and serum total bilirubin, the presence of urine hemosiderin, and a serum haptoglobin of less than 5 mg/dL (normal, 30–200 mg/dL). In addition, he had severe and re-

fractory thrombocytopenia with platelet counts of $14\text{--}88 \times 10^3/\mu\text{L}$, progressive renal failure with a maximal serum creatinine of 7.6 mg/dL, and temperature elevation to 38.4 °C. Three of four blood cultures drawn on the fourth hospital day and a urine culture obtained on the fifth day grew *Staphylococcus aureus*. Vancomycin was administered, and subsequent blood cultures remained negative; however, no improvement in his clinical status was evident.

The prothrombin time, APTT, and fibrinogen remained normal. Fibrinogen/fibrin degradation products were continually elevated at low titer, 20 to 40 $\mu\text{g/mL}$. Both the direct and indirect antiglobulin (Coomb's) tests were negative.

The classic pentad of TTP—MAHA, thrombocytopenia, neurologic and renal abnormalities, and fever—was fulfilled. A clinical diagnosis of TTP was made, and a course of plasma exchange therapy was begun on the seventh hospital day. Despite four plasmaphereses with fresh-frozen plasma exchanges, the patient's clinical status deteriorated, and he died on the 16th hospital day.

AUTOPSY METHODS

Light microscopy

Routine tissue sections obtained at autopsy were fixed in 10% buffered formalin, and selected tissues were submitted separately in Hollande's and B5 fixatives. All were paraffin-embedded, routinely processed, and stained with hematoxylin and eosin. Selected tissue sections were stained with either Gram's, Gomori's methenamine silver, Ziehl-Neelsen, periodic acid-Schiff, or luxol fast blue-cresyl violet eosin stains.

Immunohistology

Polyclonal antibodies directed at factor VIII:Ag (vWF) (Dako, Santa Barbara, Calif), and fibrinogen/fibrin-related substances (Dako, Santa Barbara, Calif) were used to immunostain selected fixed sections of various tissues. Fresh-frozen tissue sections of kidney were evaluated with a monoclonal antibody to glycoprotein IIb/IIIa (AMAC, Inc., Westbrook, Me). All immunohistologic studies were performed using the avidin-biotinylated peroxidase complex (Vector, Burlingame, Calif) method.⁸ Appropriate positive and negative control studies were performed simultaneously for each reagent.⁸

Electron microscopy

One cubic millimeter portions of fresh kidney were fixed immediately in 0.1 mol/L cacodylate-buffered

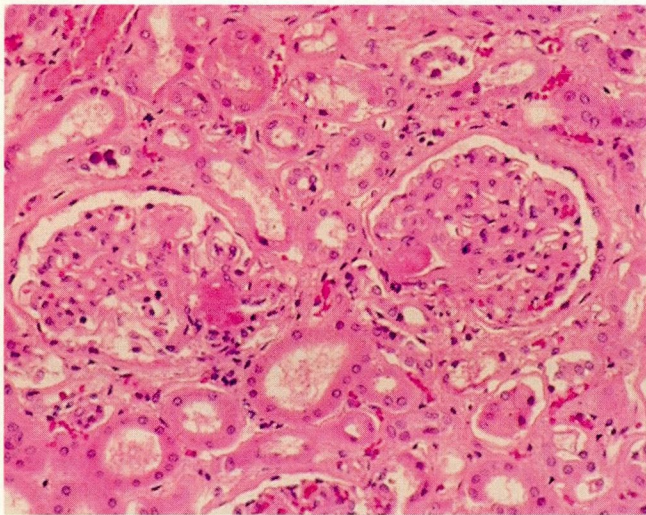


FIGURE 1. Occlusive thrombi within the vascular poles of two adjacent glomeruli. (Hematoxylin-eosin, original magnification $\times 50$).

3.75% glutaraldehyde containing 6% sucrose, postfixed in cacodylate-buffered 1% osmium tetroxide, embedded in Spurr resin. Ultrathin sections were stained with uranyl acetate and lead citrate and examined using a Philips 410 electron microscope.

AUTOPSY FINDINGS

External examination revealed an emaciated and cachectic white man with scattered petechiae, predominantly on the skin of the extremities.

Both lungs were similar and showed gross and microscopic evidence of acute, necrotizing pneumonitis. There were numerous clusters of gram-negative bacilli and gram-positive cocci within a sea of neutrophils and associated extensive parenchymal necrosis. In addition, CMV antigen was detected in lung tissue submitted for culture.

Both kidneys were enlarged with swollen subcapsular surfaces. Light microscopy showed eosinophilic thrombi occluding the vascular poles of many glomeruli (Figure 1). Characteristic changes of acute tubular necrosis were evident. Electron microscopy revealed widespread separation of glomerular loop capillary endothelial cells from underlying basement membrane; granular material was present within these expanded spaces (Figure 2).

Focal microinfarcts were noted in the brain, heart, and adrenal cortex, and there were multiple foci of parenchymal necrosis in the pancreas. Eosinophilic

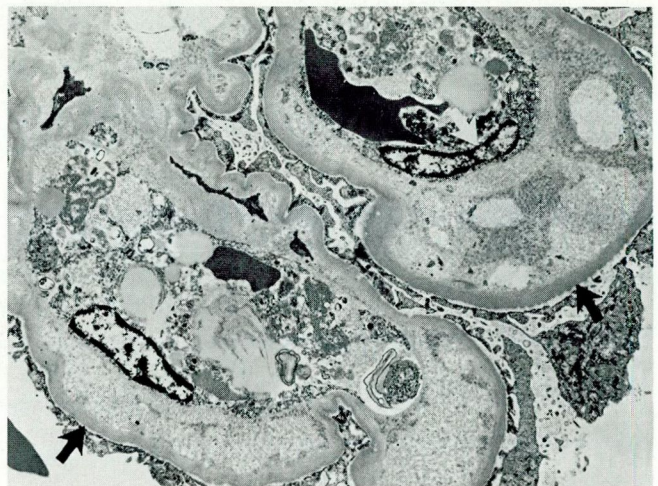


FIGURE 2. Separation of endothelial cells (white arrows) from underlying glomerular basement membrane (black arrows); this ultrastructural finding is characteristic of TTP and other microangiopathies. (Uranyl acetate and lead citrate, original magnification $\times 2,800$).

thrombi were also present within arterioles and small arteries of the brain, heart, pancreas, thyroid, liver, and spleen (Figure 3).

The spleen showed extramedullary hematopoiesis with prominent hemosiderin deposition, and the bone marrow demonstrated erythroid and megakaryocytic hyperplasia, indicative of a severe hemolytic anemia and consumptive platelet disorder.

Immunohistologic analysis of fixed tissue showed vascular thrombi in the various organs to exhibit moderately intense vWF reactivity. Variable staining, ranging from a complete absence in most thrombi to strongly positive in a few, was seen with the preparation directed at fibrinogen/fibrin related substances. Snap-frozen sections of kidney showed marked immunostaining of glomerular vascular pole thrombi and more distal capillary loops with platelet-specific glycoprotein IIb/IIIa (Figure 4).

DISCUSSION

Thrombotic thrombocytopenic purpura is a heterogeneous disorder characterized by a typical constellation of clinical and laboratory findings and histologic evidence of platelet thrombi in the arterial microvasculature. In 1924 Moschowitz⁹ described a single case of a young woman with anemia, thrombocytopenia, neurologic abnormalities, and a rapidly progressive fatal course; autopsy revealed widespread vascular hyaline

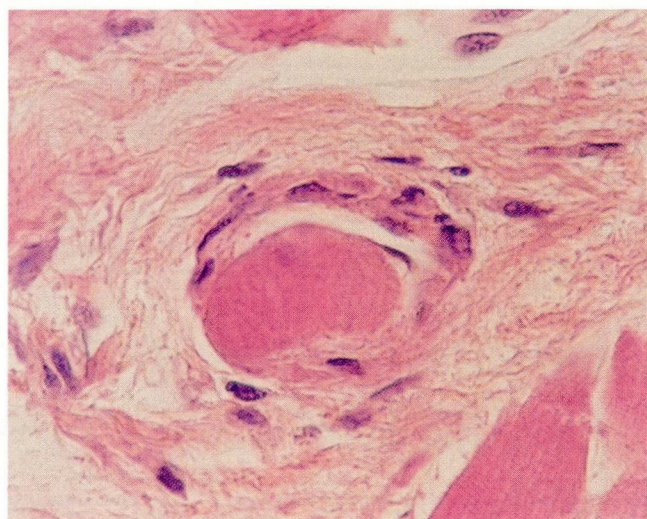


FIGURE 3. Densely eosinophilic, partially occlusive arteriolar thrombus in the myocardium. (Hematoxylin-eosin, original mag. $\times 200$).

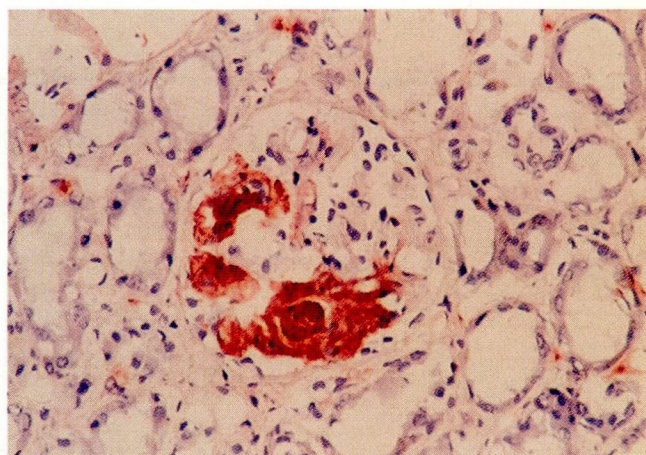


FIGURE 4. Glomerular vascular pole thrombus showing intense immunoreactivity with anti-glycoprotein IIb/IIIa. Granular red-brown color indicates a positive reaction. This immunohistologic pattern is consistent with a platelet thrombus. (Hematoxylin counterstain, original magnification $\times 80$).

thrombi. This is considered to be the first documented report of TTP.

Twelve years later Baehr and associates¹⁰ reported four additional cases with similar clinical courses and autopsy findings. In addition, they proposed that the arterial thrombi were composed predominantly of platelets, a supposition that has been subsequently proven by immunohistologic and electron microscopic methods.¹¹ The first major literature review of this syndrome was undertaken by Amorosi and Ultmann in 1966.¹² They reviewed the 255 cases documented before that year and offered 16 new cases from Columbia Presbyterian Medical Center. This paper was significant in solidifying the diagnostic hallmarks of TTP: the pentad of MAHA, thrombocytopenia, neurologic and renal abnormalities, and fever. In addition, it underscored the syndrome's virtually fatal natural course (95% mortality).^{12,13}

In 1976 Bukowski and colleagues¹⁴ reported complete remissions in 8 of 14 cases managed with whole-blood exchange transfusion, and in 1977 they documented 2 cases of patients with TTP who were cured with plasma exchange therapy.¹⁵ These experiences were therapeutic milestones, and today most patients with acute TTP are treated routinely with plasma exchange therapy.^{16,17}

Association with HIV

TTP has recently been described in HIV-seropositive persons.³⁻⁷ In 1987 Jokela and coauthors,³ described the first case of TTP in association with HIV-related disease.

A 32-year-old HIV-seropositive homosexual man had a severe MAHA, thrombocytopenia, headaches and peripheral sensory disturbances, proteinuria and hematuria, and fever; corroborative histologic evidence of TTP consisted of "hyaline and granular" thrombi in vessels in bone marrow.

In 1988 Meisenberg and associates⁶ described two HIV-seropositive patients with acute presentations of MAHA, thrombocytopenia, and varied neurologic and renal dysfunction. In one case, gingival tissue biopsy findings were apparently characteristic of TTP.

Botti and colleagues⁴ described a 44-year-old black man with no apparent risk factors for HIV-related disease who presented with gingival hemorrhage and behavioral disturbances. MAHA, thrombocytopenia, renal dysfunction, and fever were noted, along with a normal coagulation profile; there was no histopathologic correlation with these clinical and laboratory findings. Three weeks after hospital discharge the patient presented with a viral-like syndrome, and within 5 weeks he was diagnosed with *Pneumocystis carinii* pneumonia. He was found to be HIV-seropositive at that time.

Leaf and colleagues⁵ reported six more cases of TTP in persons with apparent HIV-related disease. Three patients were documented HIV-seropositive, but HIV serologic status was not mentioned for the other three. Two of the latter three had reasonably convincing evidence of HIV-related disease. Both were in high-risk groups; one had a low T helper/suppressor ratio, and the

TABLE 1
SUMMARY DATA OF THE 13 REPORTED CASES OF HIV-ASSOCIATED TTP*

Age/Sex	HIV serologic status	Histologic evidence of vascular thrombi	Plasma exchange therapy	Survival	AIDS	Reference
32/M	+	Yes (bone marrow)	Yes	Yes	No	3
25/M	+	Yes (gingiva)	Yes	Yes	No	6
31/M†	+	NB	Yes	Yes	No	
44/M	+‡	NB	Yes	Yes	Yes§	4
31/M	NR¶	No	Yes	Yes	No	5
36/F	NR¶	NB	Yes	Yes	No	
34/M	+	NB	Yes	Yes	No	
39/M	NR#	Yes (multiple organs)	No**	No	No	
30/M	+	Yes (gingiva)	Yes	Yes	No	
42/M	+	NB	No**	No	No	
47/F	+	No	Yes	Yes	No	7
32/M	+	Yes (lymph node)	Yes	Yes	No	
31/M	+	Yes (multiple organs)	Yes	No	Yes	(present case)

* All patients had clinical evidence of TTP

† History of focal glomerulosclerosis

‡ Testing performed several weeks after resolution of acute TTP episode

§ Developed AIDS several weeks after acute TTP episode

|| History of Hodgkin's disease

¶ Depressed CD4/CD8, IV drug abuse

Homosexual with generalized lymphadenopathy

** Died on day of hospital presentation

NB = no biopsy; NR = not reported.

other had generalized lymphadenopathy. The third patient had Hodgkin's disease, but no other evidence of HIV-related disease except a high-risk homosexual lifestyle. The four who were treated with plasma exchange therapy along with various adjunct therapies survived; the other two died rapidly of cardiopulmonary failure before plasma exchange therapy could begin. An autopsy of one of these patients demonstrated "complete occlusion of the microvasculature, with a pink, amorphous, eosinophilic material, consistent with fibrin deposition." Of the four survivors, gingival tissue was "positive for TTP" in the one case in which a biopsy was performed.

The final two cases of HIV-associated TTP were reported by Nair and colleagues.⁷ Both patients were HIV-seropositive. In one case a lymph node disclosed vascular "fibrin" thrombi.

In summary, 13 cases of TTP associated with HIV-related disease, including our patient, have been described in the literature to date (Table 1). In our opinion, three of these are of questionable validity with respect to definitive establishment of HIV infection for reasons previously mentioned.

Of the 11 patients who underwent plasma exchange therapy, 10 (91%) survived the acute episode of TTP. This response rate to plasma exchange therapy is comparable to recently reported data from various groups de-

monstrating from 60% to 100% response rates in "typical" patients with TTP.^{16,17} This suggests that plasma exchange therapy (plasmapheresis with fresh-frozen plasma exchanges) should also be first-line therapy in patients with TTP associated with HIV-related disease.

To our knowledge, the case presented is the first to document TTP in an individual with AIDS (CDC class 4 HIV-related disease). The 12 other cases occurred in individuals with only HIV-seropositive status and no other manifestations of HIV-related disease (CDC class 2) or with presumptive HIV-related disease without serologic documentation or other diagnostic features of AIDS. In one patient, AIDS apparently developed several weeks after an acute episode of TTP.⁴

Another novel feature of our case was the presence of disseminated CMV infection. Although usually idiopathic, TTP has been associated with a variety of underlying disorders, including various infections,^{1,2,18} and in such settings is categorized as secondary TTP. However, the syndrome has not been reported in association with CMV infection. Although the presence of HIV and CMV infections in our patient is documented, we can draw no conclusions concerning the causative role of either of these viral organisms in the pathogenesis of TTP. In addition, the possible pathogenetic role of the individual microorganisms comprising the polymicrobial bacterial pneumonitis evident at autopsy is

also uncertain. Our case is, thus, best categorized as secondary TTP, rather than the primary or idiopathic form, since several likely etiologic candidates are apparent.

Confirmation of platelet thrombi

Although not always necessary for initiating treatment, the identification of platelet thrombi in the arterial microvasculature is essential for a definitive clinicopathologic diagnosis of TTP. Histopathologic corroboration of HIV-associated TTP has been documented in only five other cases before our case (Table 1): two on gingival biopsy,^{5,6} one on bone marrow biopsy,³ one on lymph node biopsy,⁷ and one at postmortem examination.⁵ The reports of these cases included only brief descriptions and superficial characterizations of the vascular thrombi. In two instances fibrin thrombi were reported^{5,7} and thought to be consistent with TTP. This common misconception that fibrin is the major component of vascular thrombi in TTP has been disproved by immunohistologic methods and electron microscopic techniques.¹¹

Asada and coworkers¹¹ used immunohistologic techniques and antibody preparations to detect vWF (which is found in alpha granules of platelets, as well as in vascular endothelial cells) and fibrinogen- and fibrin-related substances. They demonstrated that thrombi in TTP were composed predominantly of platelets with only small amounts of fibrin-related substances. In contrast, vascular thrombi in patients with disseminated intravascular coagulation contained a preponderance of fibrinogen- and fibrin-related substances. We confirmed these observations in our case by demonstrating prominent factor vWF staining, with a variable but typically scant amount of fibrin-related substance within the widespread vascular thrombi characteristic of TTP.

In addition, we used a platelet-specific monoclonal antibody to detect glycoprotein IIb/IIIa, the platelet membrane fibrinogen receptor best known for its ab-

sence in Glanzmann's thrombasthenia. Although the anti-glycoprotein IIb/IIIa was useful only on frozen tissue, it marked the vascular thrombi with great intensity (even at a dilution of 1:500) and seemed to be more sensitive than anti-vWF in our particular case.

Our thorough characterization of the widespread microvascular thrombi identified at autopsy shows them to be composed predominantly of platelets, consistent with the accepted pathophysiologic mechanism of in vivo platelet agglutination in TTP. Recent studies exploring the pathogenesis of TTP have implicated a heterogeneous group of platelet-agglutinating/aggregating factors, with or without involvement of large vWF multimers, as most probably responsible for most cases of this syndrome.¹⁸⁻²¹ In fact, a specific platelet-agglutinating protein, P37, possibly a derivative of an infectious agent, has been isolated and purified from the plasma of some patients with acute TTP.^{19,22} The role of HIV in initiating platelet thrombus formation and/or maintaining these thrombi in the arterial microvasculature in acute TTP remains to be elucidated.

ADDENDUM

After our manuscript was accepted for publication, two additional cases of apparent HIV-associated TTP were reported.²³ In one patient, who subsequently died, AIDS appeared to develop during hospitalization for an acute TTP episode; however, no HIV serologic testing was mentioned and no autopsy was performed. The other patient was HIV-seropositive without other manifestations diagnostic of AIDS.

ACKNOWLEDGMENT

We would like to thank James T. McMahon, PhD, for preparation of the electron microscopic material for this case.

REFERENCES

- Ridolfi RL and Bell WR. Thrombotic thrombocytopenic purpura: report of 25 cases and review of the literature. *Medicine* 1981; 60:413-428.
- Kwaan HC. Miscellaneous secondary thrombotic microangiopathy. *Semin Hematol* 1987; 24:141-147.
- Jokela J, Flynn T, Henry K. Thrombotic thrombocytopenic purpura in a human immunodeficiency virus (HIV)-seropositive homosexual man. *Am J Hematol* 1987; 25:341-343.
- Botti AC, Hyde P, DiPillo F. Thrombotic thrombocytopenic purpura in a patient who subsequently developed the acquired immunodeficiency syndrome (AIDS). *Ann Intern Med* 1988; 109:242-243.
- Leaf AN, Laubenstein LJ, Raphael B, Hochster H, Baez L, Karparkin S. Thrombotic thrombocytopenic purpura associated with human immunodeficiency virus type 1 (HIV-1) infection. *Ann Intern Med* 1988; 109:194-197.
- Meisenberg BR, Robinson WL, Mosley CA, Duke MS, Rabetoy GM, Kosty MP. Thrombotic thrombocytopenic purpura in human immunodeficiency (HIV)-seropositive males. *Am J Hematol* 1988; 27:212-215.
- Nair JMG, Bellevue R, Bertoni M, Dosik H. Thrombotic thrombocytopenic purpura in patients with the acquired immunodeficiency syndrome (AIDS)-related complex: a report of 2 cases. *Ann Intern Med* 1988; 109:209-212.
- Tubbs RR, Sheibani K. Immunohistology of lymphoproliferative disorders. *Sem Diag Pathol* 1984; 1:272-284.
- Moschcowitz E. Hyaline thrombosis of the terminal arterioles and capillaries: a hitherto undescribed disease. *Proc NY Pathol Soc* 1924; 24:21-24.

10. Baehr G, Klemperer P, Schiffrin A. An acute febrile anemia and thrombocytopenic purpura with diffuse platelet thrombosis of capillaries and arterioles. *Trans Assoc Am Physicians* 1936; **51**:43-58.
11. Asada Y, Sumiyoshi A, Hayashi T, Suzumiya J, Kaketuni K. Immunohistochemistry of vascular lesion in thrombotic thrombocytopenic purpura, with special reference to factor VIII related antigen. *Thromb Res* 1985; **38**:469-479.
12. Amorosi EL and Ultmann JE. Thrombotic thrombocytopenic purpura: report of 16 cases and review of the literature. *Medicine* 1966; **45**:139-159.
13. Kwaan HC. Clinicopathologic features of thrombotic thrombocytopenic purpura. *Semin Hematol* 1987; **24**:71-81.
14. Bukowski RM, Hewlett JS, Harris JW, et al. Exchange transfusion in the treatment of thrombotic thrombocytopenic purpura. *Semin Hematol* 1976; **13**:219-232.
15. Bukowski RM, King JW, Hewlett JS. Plasmapheresis in the treatment of thrombotic thrombocytopenic purpura. *Blood* 1977; **50**:413-417.
16. Blitzer JB, Granfortuna JM, Gottlieb AJ, et al. Thrombotic thrombocytopenic purpura: treatment with plasmapheresis. *Am J Hematol* 1987; **24**:329-339.
17. Shepard KV, Bukowski RM. The treatment of thrombotic thrombocytopenic purpura with exchange transfusions, plasma infusions, and plasma exchange. *Semin Hematol* 1987; **24**:178-193.
18. Bukowski RM. Thrombotic thrombocytopenic purpura: a review. *Prog Hemost Thromb* 1982; **6**:287-337.
19. Lian ECY. Pathogenesis of thrombotic thrombocytopenic purpura. *Semin Hematol* 1987; **24**:82-100.
20. Byrnes JJ, Moake JL. Thrombotic thrombocytopenic purpura and haemolytic-uraemic syndrome: evolving concepts of pathogenesis and therapy. *Clin Hematol* 1986; **15**:413-442.
21. Kelton JG, Moore J, Santos A, Sheridan D. Detection of a platelet-agglutinating factor in thrombotic thrombocytopenic purpura. *Ann Intern Med* 1984; **101**:589-593.
22. Siddiqui FA, Lian ECY. Platelet-agglutinating protein P37 from a thrombotic thrombocytopenic purpura plasma forms a complex with human immunoglobulin G. *Blood* 1988; **71**:299-304.
23. Platanias LC, Paiusco D, Bernstein S, Murali MR. Thrombotic thrombocytopenic purpura as the first manifestation of human immunodeficiency virus infection. *Am J Med* 1989; **87**:699-700.

