

Pneumomediastinum and subcutaneous emphysema during laparoscopy

SANTOSH B. KALHAN, MBBS; JOHN A. REANEY, MD; ROBERT L. COLLINS, MD

■ Laparoscopy, with the use of carbon dioxide or nitrous oxide for insufflation, is a common procedure with the potential for several major complications. For example, pneumomediastinum, pneumothorax, and subcutaneous emphysema can occur singly or in any combination with this procedure. The authors report a patient in whom pneumomediastinum and massive subcutaneous emphysema developed without pneumothorax. Possible mechanisms are presented, along with discussion of the need for prompt diagnosis and termination of the procedure with deflation of the abdomen. The life-threatening potential of this complication is emphasized.

□ INDEX TERMS: LAPAROSCOPY; PNEUMOMEDIASTINUM; SUBCUTANEOUS EMPHYSEMA □ CLEVE CLIN J MED 1990; 57:639-642

LAPAROSCOPY is a common outpatient gynecologic procedure. Although minor and major complications have been attributed to this procedure, their frequency is low. Among the major complications are hemorrhage, bowel perforation, gas embolism, cardiovascular collapse, pneumothorax, pneumomediastinum, and subcutaneous emphysema. The last three may be seen in the same patient individually or in various combinations.

Subcutaneous emphysema has been reported with pneumothorax or pneumomediastinum or both. Doctor and associates¹ reported a case in which bilateral pneumothorax was diagnosed in the immediate postoperative period. More recently Batra and colleagues² reported a case of subcutaneous emphysema with pneumothorax and pneumomediastinum.

This report describes a case of pneumomediastinum

with massive subcutaneous emphysema occurring without pneumothorax during a diagnostic and operative laparoscopy with laser fulguration of endometriosis.

REPORT OF A CASE

A healthy, 58-kg, 154-cm, 33-year-old female was scheduled for diagnostic and operative laparoscopy as an outpatient. Her laboratory data were unremarkable and she was taking no medications.

No preoperative medications were given. In the operating room, the patient was monitored with electrocardiography, pulse oximetry, an automated blood pressure device, and an axillary temperature probe. Immediately prior to induction, she received fentanyl, 50 µg, and droperidol, 625 µg, intravenously. Anesthesia was induced with 250 mg thiopental.

After ascertaining the adequacy of her airway by mask, she received atracurium, 30 mg intravenously. She was then ventilated with oxygen and enflurane for 4 1/2 minutes, at which time her trachea was intubated atraumatically with a 7.5-mm cuffed endotracheal tube. Anesthesia was maintained with enflurane and nitrous

From the Divisions of Anesthesiology (S.B.K., J.A.R.) and Surgery (R.L.C.), The Cleveland Clinic Foundation.

Address reprint requests to S.B.K., Division of Anesthesiology, Desk M26, The Cleveland Clinic Foundation, One Clinic Center, 9500 Euclid Avenue, Cleveland, Ohio 44195-5154.

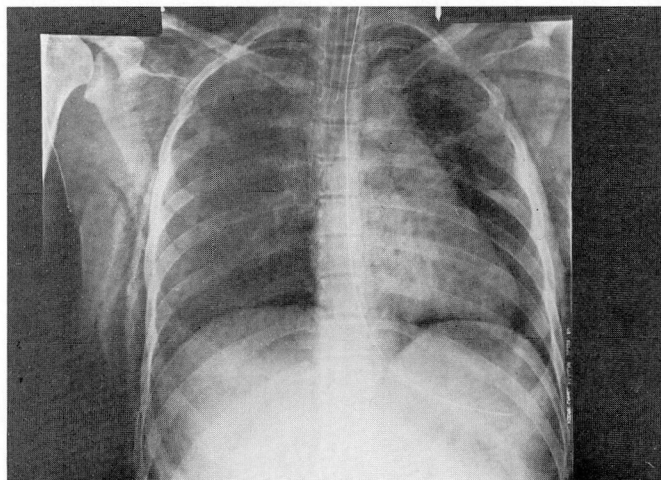


FIGURE 1. Anteroposterior chest radiograph showing pneumomediastinum and extensive subcutaneous emphysema of the neck and chest wall.

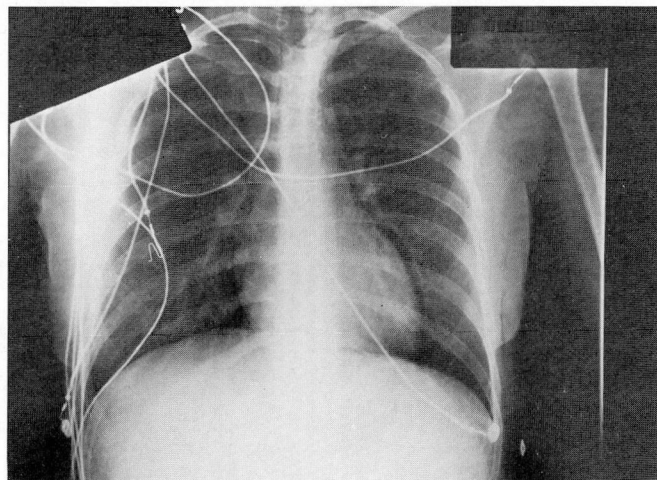


FIGURE 2. Almost complete resolution of pneumomediastinum with minimal subcutaneous emphysema of the chest wall 6 hours postoperatively.

oxide (60%) and ventilation was controlled. End-tidal carbon dioxide (ETCO₂) was monitored with a capnogram and maintained in the range of 30 mmHg to 32 mmHg. An orogastric tube was placed and the stomach contents aspirated. The oxygen saturation by pulse oximeter (SpO₂) was maintained at 98% to 99%.

The patient was placed in the Trendelenburg position and a Verres needle was inserted through the subumbilical area. A pneumoperitoneum was established using 2.5 L of CO₂. The Verres needle was removed and a large trocar was introduced through a small subumbilical incision and was followed by the laparoscope. A smaller trocar with a probe was placed 3 cm above the symphysis pubis.

The pelvic contents were identified and a diagnosis of moderate pelvic endometriosis was made. The argon laser probe was inserted through a small right lower quadrant incision and fulguration of the endometriotic implants was begun. Fulguration also included some implants on the urinary bladder surface.

Half an hour after the start of surgery, the patient's lung-thorax compliance decreased. This decrease was very brief in duration. Simultaneously, it was noted that the patient's neck had subcutaneous emphysema with crepitus. This spread very rapidly to include the anterior and lateral chest walls, face, and forehead. The conjunctivae were noted to be bulging. The intra-abdominal pressure was below 30 mmHg at all times. SpO₂ was maintained at 98% and the heart rate and blood pressure were unchanged. The ETCO₂ increased to 55 mmHg briefly before returning to 33 to 34 mmHg.

The surgeon was asked to terminate the procedure and decompress the abdomen. Nitrous oxide was discontinued. A portable chest radiograph was obtained immediately and showed pneumomediastinum and extensive subcutaneous emphysema of the neck and chest wall but no pneumothorax (Figure 1). Over the next 15 to 20 minutes, the facial and conjunctival subcutaneous emphysema decreased visibly. The muscle relaxant effect was reversed and the patient was allowed to awaken. The SpO₂ and vital signs were maintained well and the trachea was extubated.

She was transported to the recovery room awake and oriented. She continued to maintain good vital signs and a good SpO₂ on 6 L O₂ by face shield. A chest radiograph taken 6 hours postoperatively showed marked decrease of the pneumomediastinum with minimal residual subcutaneous emphysema of the chest wall (Figure 2). She was admitted overnight for observation and was discharged home the next morning. At that time, there was mild crepitus over the lateral chest walls only.

DISCUSSION

Laparoscopy is a common gynecologic procedure performed routinely on outpatients. A pneumoperitoneum is created using either N₂O or CO₂. Reported mortality rates vary from 0.2% for earlier studies³ to 0.08% for later studies.⁴ The incidence of major complications (eg, hemorrhage, gas embolism, cardiovascular collapse, pneumothorax, pneumomediastinum with subcutaneous em-

physema, perforation of viscera, peritonitis) have been reported to vary from 2.49%⁵ to 0.6%.⁶

Subcutaneous emphysema

Subcutaneous emphysema may occur by two mechanisms. In one, the tip of the Verres needle does not penetrate deeply enough to enter the peritoneal cavity prior to insufflation of gas. This may cause the insufflating gas to accumulate in the subcutaneous tissue or between the fascia and the peritoneum. The incidence of this complication varies from 0.43 to 2%.^{7,8} When the gas is preperitoneal (between the fascia and peritoneum), it can track upward and produce a pneumomediastinum.

In the second mechanism, subcutaneous emphysema of the neck, face, and chest wall occurs in conjunction with pneumothorax, pneumomediastinum, or both. This is potentially a more serious hazard. In this regard, the use of CO₂ is safer than N₂O because CO₂ is more soluble in blood and therefore more rapidly resorbed from any gas space or body cavity.

Pneumomediastinum, pneumothorax

Pneumomediastinum and pneumothorax can occur subsequent to pneumoperitoneum due to passage of gas through weak points or defects in the diaphragm.¹ There are several reports in the literature of catamenial pneumothorax. Muller and colleagues⁹ describe a case of recurrent postcoital pneumothorax treated successfully with tubal ligation. Acute hydrothorax complicating peritoneal dialysis has also been described.^{10,11} Presumably these are caused by air or fluid passing through defects in the diaphragm which may be either congenital in nature or secondary to endometriosis. The patient reported here had endometriosis, and defects in the diaphragm could have been possible.

A probe could also produce a retroperitoneal dissection of the insufflating gas along the large vessels into the mediastinum and further progress to a pneumothorax or subcutaneous emphysema or both of the neck and chest wall. There are several reports of this complication in the European literature.^{12,13}

Herrerias and co-workers¹⁴ report a case of pneumopericardium occurring in addition to pneumomediastinum and subcutaneous emphysema after laparoscopy for liver biopsy. This could result in cardiac tamponade and a life-threatening situation. In another series, mediastinal emphysema was reported in 8 of 3,000 subjects undergoing peritoneoscopy.¹⁵ Bilateral tension pneumothorax with subcutaneous emphysema following fulguration of a bladder tumor has also been reported.¹⁶ Our patient had laser fulguration of en-

dometriotic implants on the urinary bladder surface, and this could have been an alternative route for gas escape into the retroperitoneal area.

The association of pneumoretroperitoneum and pneumoperitoneum with pneumothorax, pneumomediastinum, or both is rare though well described.¹⁷⁻¹⁹ The entity may develop when a ruptured bleb or bulla leads to a tension pneumothorax and subsequent air leak into the peritoneal cavity through defects in the diaphragm.¹⁷ Alternatively, airleaks may occur through a distended alveolus without perforation of the visceral pleura. The air then dissects along the blood vessels towards the mediastinum, causing a pneumomediastinum. The gas under pressure in the mediastinum can cause the mediastinal parietal pleura to rupture, resulting in a secondary pneumothorax.²⁰

Air in the mediastinum may also dissect along the aorta and inferior vena cava openings in the diaphragm and cause pneumoretroperitoneum and, ultimately, pneumoperitoneum.¹⁷ In most cases described in the literature this complication occurred in patients on mechanical ventilators with high inflation pressures and use of positive end-expiratory pressure. An exploratory laparotomy may be indicated for these patients to exclude a ruptured viscus.

Recommendations

Undetected pneumothorax and pneumomediastinum can be life-threatening. In our case, the transient decrease in lung-thorax compliance may have occurred when the rush of gas into the mediastinum compressed the hilar structures. The subcutaneous emphysema of the neck, chest wall, and face may have acted as a "relief valve" to vent this increased pressure.

As soon as this complication is suspected, a chest radiograph should be obtained to diagnose or rule out a pneumomediastinum or pneumothorax. If there is clinical evidence of a tension pneumothorax, then decompression is needed before obtaining a chest radiograph.

The brief increase in our patient's ET_{CO₂} may have been the result of a simultaneous, self-limiting, CO₂ embolus. The absence of a mill wheel murmur excluded a significant gas embolus. Once the CO₂ insufflation was discontinued and the abdomen decompressed, the subcutaneous emphysema began to resolve very rapidly. The extreme solubility of CO₂ facilitated absorption and permitted rapid resolution of the pneumomediastinum.

Most cases of pneumomediastinum associated with laparoscopy require observation without major intervention; however, we need to be aware of the life-threatening potential of this complication if gas insufflation into the peritoneal cavity continues.

REFERENCES

1. Doctor NH, Hussain Z. Bilateral pneumothorax associated with laparoscopy. A case report of a rare hazard and review of the literature. *Anaesthesia* 1973; **28**:75-81.
2. Batra MS, Driscoll JJ, Coburn WA, Marks WM. Evanescent nitrous oxide pneumothorax after laparoscopy. *Anesth Analg* 1983; **62**:1121-3.
3. Horwitz ST. Laparoscopy in gynecology. *Obstet Gynecol Surv* 1972; **27**:1-13.
4. Ohlgisser M, Sorokin Y, Heifetz M. Gynecologic laparoscopy: a review article. *Obstet Gynecol Surv* 1985; **40**:385-96.
5. Bruhl W. Complications of laparoscopy and liver biopsy under vision: the results of a survey. *Ger Med Mon* 1967; **12**:31-32.
6. Hulka JF, Soderstrom RM, Corson SL, Brooks PG. Complications Committee of the Association of Gynecologic Laparoscopists. First Annual Report. *J Reprod Med* 1973; **10**:301-306.
7. Mumford ST, Bhiwandiwala PP, Chi I-C. Laparoscopic and mini-laparotomy female sterilization compared in 15,176 cases. *Lancet* 1980; **2**:1066-1070.
8. Vilardell F, Seres I, Marti-Vicente A. Complications of peritoneoscopy. A survey of 1,455 examinations. *Gastrointest Endosc* 1968; **14**:178-180.
9. Muller NL, Nelems B. Postcoital catamenial pneumothorax. Report of a case not associated with endometriosis and successfully treated with tubal ligation. *Am Rev Respir Dis* 1986; **134**:803-804.
10. Edward SR, Unger AM. Acute hydrothorax. A new complication of peritoneal dialysis. *JAMA* 1967; **199**:853-855.
11. Finn R, Jowett EW. Acute hydrothorax complicating peritoneal dialysis. *Br Med J* 1970; **2**:94.
12. Riegel R. Pneumothorax nach diagnostischem pneumoperitoneum bei Laparoskopie. *Beitrage zur Klinik der Tuberkulose* 1952; **107**:467.
13. Motschmann H. Pneumothorax as Zwischenfall bei der Laparoskopie. *Medizinische Klinik* 1954; **49**:401.
14. Herrerias JM, Ariza A, Garrido M. An unusual complication of laparoscopy. Pneumopericardium. *Endoscopy* 1980; **12**:254-255.
15. Vilardell F, Marti-Vicente A. Peritoneoscopy (Laparoscopy) [In] Bockus HL, ed. *Gastroenterology*, Vol 4. Philadelphia, WB Saunders, 1976.
16. Sivak BJ. Surgical emphysema. Report of a case and review. *Anesth Analg* 1964; **43**:415-417.
17. Glauser, FL, Bartlett RH. Pneumoperitoneum in association with pneumothorax. *Chest* 1974; **66**:536-540.
18. Egan M, Boutros A. Pneumoperitoneum following tension pneumothorax. Report of two cases. *Crit Care Med* 1970; **3**:170-172.
19. Altman AR, Johnson TH. Pneumoperitoneum and pneumoretroperitoneum. Consequences of positive end expiratory pressure therapy. *Arch Surg* 1979; **114**:208-211.
20. Macklin GC. Transport of air along sheaths of pulmonic blood vessels from alveolus to mediastinum. *Arch Int Med* 1939; **65**:914.

