



## Virilization secondary to topical testosterone

LYDIA U. PARKER, MD AND WILMA F. BERGFELD, MD

■ Topical testosterone is recognized as a standard treatment for vulvar lichen sclerosus et atrophicus. Systemic androgenic side effects of this medication are widely believed to be uncommon and mild. A case is reported of severe hirsutism with other signs of virilization and markedly elevated serum testosterone levels secondary to use of topical testosterone propionate for vulvar lichen sclerosus et atrophicus. Caution is necessary in the use of topical testosterone, with close monitoring for signs of virilization. Alternative treatments for this condition, such as intralesional corticosteroids or topical progesterone, are recommended to avoid the risk of androgenic side effects.

□ INDEX TERMS: HIRSUTISM; TESTOSTERONE, TOPICAL □ CLEVE CLIN J MED 1991; 58:43-46

**T**OPICAL TESTOSTERONE is a standard therapeutic agent for vulvar lichen sclerosus et atrophicus (LSA), a common form of chronic vulvar dystrophy.<sup>1,2</sup> LSA is a cutaneous disorder of unknown etiology that can affect all areas of the skin, but most commonly affects the vulva of white, middle-aged women. Patients usually complain of intractable vulvar pruritus. The typical lesions are flat, white papules, often confluent, producing depressed or hypertrophic white plaques. As the atrophic condition progresses, fine wrinkling with a "cigarette paper" appearance often develops. With further atrophy, erosions and bullae may form and the vulvar anatomy may be severely altered. Patients with hypertrophic LSA have an increased risk of developing squamous cell carcinoma.<sup>3</sup>

Several clinical studies of patients with biopsy-proven vulvar dystrophy have shown that 2% tes-

tosterone propionate in petrolatum can relieve symptoms and reverse the gross appearance and histological changes of vulvar dystrophy.<sup>2,4-7</sup> This medication is not commercially available and must be compounded by a pharmacist. It is applied to the vulva two or three times a day for at least 6 months before a therapeutic response can be evaluated. Treatment must be continued indefinitely or symptoms will recur within 6 months.<sup>1,6</sup>

Some studies have shown that treatment with topical testosterone caused no significant increase in serum androgen levels, but a recent study found serum total testosterone and dihydrotestosterone levels to be significantly increased after treatment with topical 2% testosterone propionate. No relationship was found between androgen levels and development of side effects, however.<sup>2</sup>

Adverse effects of topical testosterone have been described as minimal by authors of five clinical studies reporting on a total of 90 patients with vulvar dystrophy.<sup>2,4-7</sup> Increased libido, clitoral hypertrophy, and pubic hirsutism have been reported as common but not bothersome side effects in patients using topical testosterone. Uncommon side effects include thin-

From the Department of Dermatology, The Cleveland Clinic Foundation.

Address reprint requests to W.F.B., Department of Dermatology, The Cleveland Clinic Foundation, One Clinic Center, 9500 Euclid Avenue, Cleveland, Ohio 44195.

TABLE 1  
CLINICAL SUMMARY

Date	Treatment	Symptoms	Testosterone level (ng/dL)*
Apr 1984	Test cr† tid	None	—
Dec 1984	Test cr tid	Deepened voice	383 ng/dL
Aug 1985	Test cr qd	Deepened voice, hirsutism	—
Sep 1986	No test cr × 2 wk	Further deepened voice, increased hirsutism, 5.9-kg weight gain, masculine, muscular upper trunk	18 mg/dL
Oct 1986	Test cr qd; Aldactone, 50 mg qd; Premarin	Deepened voice, hirsutism, massive upper trunk, amenorrhea, hot flashes	150 ng/dL
Jan 1987	IL Kenalog‡; Aldactone, 50 mg bid; Premarin, Provera	Voice higher, hirsutism no longer progressing	—
May 1987	IL Kenalog; Aldactone, 50 mg bid; Estraderm; Norlutin	Voice higher, hirsutism markedly diminished, 3.9-kg weight loss, menstruating regularly	20 ng/dL
Nov 1987	IL Kenalog; Valisone 0.1% Ointment; Aldactone, 25 mg bid; Estraderm; Norlutin	Voice change and hirsutism resolved, decreased upper trunk mass	13 mg/dL

\*normal, 20-70 ng/dL

†Test cream, topical 2% testosterone propionate in 0.5% hydrocortisone cream

‡IL Kenalog, intralesional Kenalog, 5 mg/cc once a month

ning of scalp hair in elderly patients,<sup>6</sup> one case of slight facial acne,<sup>6</sup> and, rarely, voice change.<sup>8</sup> Cases of hirsutism have been limited to uncommon reports of mildly increased facial hair growth in patients with pre-existing facial hirsutism<sup>4,6</sup> and a single report of extensive lanugo-like hair over the face, back, and neck of a sterile, obese 30-year-old patient.<sup>6</sup>

We report a case of severe hirsutism with other signs of virilization and markedly elevated serum testosterone levels secondary to use of topical 2% testosterone propionate for vulvar LSA. A review of the literature revealed no other case of severe virilization with significantly increased androgen levels as a result of therapy with topical testosterone.

## CASE REPORT

A 50-year-old, white female was seen in the Cleveland Clinic Department of Dermatology for evaluation of a 1-year history of hirsutism. More than 2 years prior to this visit, the patient began using topical 2% testosterone propionate in 0.5% hydrocortisone cream for vulvar lichen sclerosus et atrophicus as prescribed by her gynecologist. The cream was applied to the vulva three times daily with good clinical results,

including alleviation of her severe pruritus.

The patient had no adverse effects from this therapy until 8 months later, when she complained of hoarseness. Her serum testosterone level was found to be markedly elevated (Table 1). Her dehydroepiandrosterone-sulfate (DHEA-S) level was normal. The testosterone cream was thought to be incorrectly prepared, and the patient was asked to change pharmacists and continue using the cream three times a day. After 6 more months of therapy, the LSA continued to be well-controlled and the dosage was decreased to once-a-day application.

The patient's hoarseness continued, however, and she noted increased hair growth over her face, chest, abdomen, arms, and thighs. She discontinued the cream for 2 weeks and revisited her gynecologist, who noted signs of virilization on clinical examination (Table 1). Serum testosterone level after discontinuance of the cream was normal. DHEA-S level was 0.07 µg/mL (normal, 0.36 to 3.2) and sex hormone binding globulin level was normal. Abdominal and pelvic computed tomographic scans revealed no adrenal or ovarian mass. The patient was referred for a dermatologic evaluation of her hirsutism.

When seen in the Department of Dermatology, the patient was again using the testosterone cream once a day and had been on spironolactone (Aldactone), 50 mg a day, for 1 month as prescribed by her family doctor for treatment of the hirsutism. She was on no other medications. She had no personal or family history of hirsutism.

On physical examination, the patient was found to have excessive facial hair, which she had been bleaching. Fine blonde hairs covered heavily and completely the moustache area, sideburn area, chin, and neck (Figure 1). Coarse dark hair was found around the areolae, on the midline chest and abdomen, on the anterior

and medial surfaces of the thighs, and on the upper arms. She was also noted to have a large, masculine-appearing upper trunk with muscular upper extremities. The patient had no acne or menstrual irregularities. Clinically, she did not appear Cushingoid or acromegalic, and she had no history of galactorrhea.

The patient was referred to the Department of Endocrinology for further evaluation. She had since developed a 2-month history of amenorrhea and hot flashes and was started on conjugated estrogens (Premarin) by her family doctor. A serum testosterone level at this time was again elevated. The hirsutism was thought to be secondary to the topical testosterone, which the patient was still using once a day. The patient was also thought to be menopausal. She was advised to decrease use of the testosterone cream to twice a week. Her spironolactone dosage was increased and medroxyprogesterone (Provera) was started.

The testosterone cream was discontinued 1 month later and the patient returned to the Department of Dermatology, where her LSA was treated with monthly intralesional injections of triamcinolone acetonide (Kenalog) 5 mg/cc.

Two months after discontinuing the topical testosterone, the patient's voice was noticeably higher and her abnormal hair growth had stopped progressing. After 5 months, the hirsutism and other signs of virilization were resolving. Serum testosterone level normalized. Her dosage of spironolactone was decreased to 25 mg twice a day.

Eleven months after the topical testosterone was discontinued, the patient's signs of virilization had resolved. The LSA remained well controlled with intralesional triamcinolone once a month and topical betamethasone valerate (Valisone) ointment. The spironolactone dosage has been further decreased and it is expected that this medication can be discontinued without recurrence of the patient's hirsutism or elevated serum testosterone levels.

#### DISCUSSION

Topical testosterone has been used by gynecologists as the treatment of choice for vulvar LSA, with the widely held belief that side effects are minimal. A review of the literature, as described above, revealed that systemic effects of this topical treatment, such as increased libido and clitoral hypertrophy, are not uncommon. Our case illustrates that systemic effects can be severe, with markedly elevated serum testosterone levels and obvious signs of virilization.

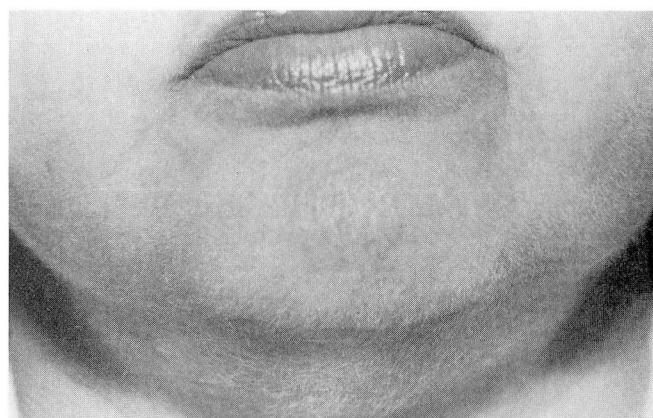


FIGURE 1. Excessive facial hair developed during 2 years of treatment with topical testosterone propionate for vulvar LSA. Fine, long blonde hairs (bleached by the patient) heavily cover the sideburn area, moustache area, chin, and neck.

In this case, the testosterone was prepared in a hydrocortisone cream base rather than in petrolatum, as is generally recommended. It is possible that the testosterone in sesame oil separated from the cream base and was actually applied in a much higher concentration than 2%. However, this patient tried a fresh preparation of the cream with continued progression of virilization.

We believe that alternative treatments should be considered for all cases of vulvar LSA. Topical progesterone has been shown to be effective and well tolerated. A mixture of 100 mg progesterone in oil/ounce of Aquaphor has been used with reported clinical success.<sup>1,8</sup> This medication, like topical testosterone, is not readily available and must be compounded by a pharmacist.

Experience at the Cleveland Clinic Department of Dermatology has shown that monthly intralesional injections of triamcinolone acetonide, 5 mg/cc, effectively control the symptoms and reverse the gross pathologic changes of vulvar LSA. Some patients could be seen as infrequently as once or twice a year for intralesional therapy. An intermediate topical steroid, such as betamethasone valerate cream, may be used to maintain symptomatic relief, if necessary.

These alternative treatments, intralesional corticosteroids and topical progesterone, are likely to be effective because of their structural similarity to testosterone, or, in the case of progesterone, because of its peripheral conversion to testosterone.<sup>1</sup> We believe these alternatives to be superior to topical testosterone as treatment for vulvar LSA because they offer a



similar therapeutic effect without the risk of androgenic side effects.

Systemic side effects of topical testosterone are more common and can, in rare instances, be much more severe than is widely believed. We conclude that cau-

tion is necessary in the use of topical testosterone, and advise careful monitoring for signs of androgen excess. We also suggest consideration of alternative treatments which may be effective without the risk of virilization.

#### REFERENCES

1. Friedrich EG, Jr. Lichen sclerosus. In: Maddin S, ed. *Current Dermatologic Therapy*. Philadelphia: WB Saunders, 1982: 284-286.
2. Friedrich EG Jr, Kalra PS. Serum levels of sex hormones in vulvar lichen sclerosus, and the effect of topical testosterone. *N Engl J Med* 1974; **310**:488-491.
3. Pincus SH. Cutaneous diseases of the female genitalia. In: Fitzpatrick TB, Eisen AZ, Wolff K, et al, eds. *Dermatology in General Medicine*, 3rd ed. New York: McGraw-Hill; 1987:1244-1265.
4. Friedrich EG Jr. Topical testosterone for benign vulvar dystrophy. *Obstet Gynecol* 1971; **37**:677-686.
5. Zelle K. Treatment of vulvar dystrophies with topical testosterone propionate. *Am J Obstet Gynecol* 1971; **109**:570-573.
6. Williams CA, Richardson AC, Hatchcock EW. Topical testosterone in dystrophic diseases of the vulva. *Am J Obstet Gynecol* 1966; **96**:21-30.
7. Richardson AC, Williams CA. Topical androgenic hormones in vulvar kraurosis-leukoplakia syndrome. *Am J Obstet Gynecol* 1958; **76**:791-799.
8. Friedrich EG, Jr. Vulvar dystrophy. *Clin Obstet Gynecol* 1985; **28**:178-187.

