



# Prolonged survival with isolated levocardia and situs inversus

VANI VIJAYAKUMAR, MD AND THOMAS BRANDT, MD

■ Isolated levocardia with situs inversus, or ILSI, is a rare anomaly with a reported incidence of 1:22,000 in the general population and from 0.4% to 1.2% of all patients with congenital heart diseases. It is commonly associated with both congenital heart disease and splenic abnormalities, either asplenia or polysplenia. The prognosis is poor, and only about 5% to 13% of patients survive more than 5 years. The case described here, which had computed tomographic findings, is the first case reported with multiple malignancies associated with ILSI. This patient, at 73 years of age, is the second longest survivor reported in the literature.

□ INDEX TERMS: LEVOCARDIA; SITUS INVERSUS □ CLEVE CLIN J MED 1991; 58:243-247

**I**SOLATED levocardia with situs inversus (ILSI) is a rare condition in which the heart is located within the left hemithorax with its base apex axis pointing caudally to the left and with partial or complete inversion of the abdominal viscera. ILSI has a reported incidence of 0.4% to 1.2% of all congenital heart diseases<sup>1,2</sup> and a poor prognosis.

The case described here was documented by computerized tomography (CT). This patient is the second longest survivor reported<sup>1-17</sup> and, to our knowledge, the first to have ILSI with multiple malignancies.

## CASE REPORT

A 73-year-old Caucasian woman underwent CT scans of the chest and abdomen in February 1989 as

part of a staging evaluation for a recently diagnosed scalp lymphoma. She had a history of multiple medical, surgical, and oncological problems. These included viral encephalitis diagnosed in 1948; carcinoma of the right breast treated with a mastectomy in 1960; hypothyroidism diagnosed in 1960; adenocarcinoma of the endometrium treated with a transabdominal hysterectomy in 1975; bilateral salpingo-oophorectomy and radiation therapy in 1975; transitional cell carcinoma of the bladder treated with a radical cystectomy in 1982; rheumatoid arthritis diagnosed in 1985; and non-Hodgkin's lymphoma diagnosed in 1989.

The patient's abdominal situs inversus appeared to have been first diagnosed in 1975 from a radionuclide liver-spleen scan performed during a workup for adenocarcinoma of the endometrium. She was 59 years old. Levocardia was diagnosed by electrocardiographic (ECG) findings showing a normal left caudal axis and by radiographic demonstration of normal positions of the heart, pulmonary lobes, and left aortic arch.

Because of the diagnosis of situs inversus at age 59

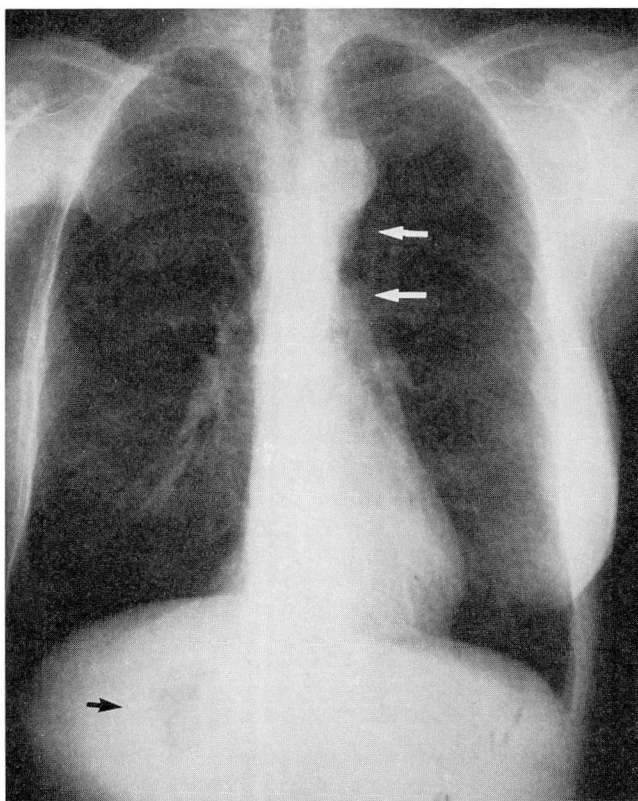


FIGURE 1. Posterior-anterior view of the chest demonstrating normal left-sided cardiac silhouette, aortic knob, and descending thoracic aorta (top arrow). Stomach bubble (bottom arrow) seen under the right hemidiaphragm.

with no associated cardiac signs or symptoms and the above-mentioned findings, the patient's cardiac status was considered normal on initial evaluation, and an echocardiogram was not performed. The upright posterior-anterior chest radiograph (Figure 1) showed a gastric air shadow within the right hemiabdomen. A CT scan of the chest (Figure 2) showed normal anatomical structures except for a prominent azygous vein, which in this patient represented azygous continuation of the inferior vena cava (IVC). Also seen were evidence of her earlier right mastectomy and a left lower lobe parenchymal nodule, which was suspicious for pulmonary metastasis. A CT scan of the abdomen (Figure 3) showed a midline liver with the larger lobe on the left, the spleen and stomach in the right upper quadrant, and the abdominal aorta to the left of the midsagittal plane. The patient currently exhibits no symptoms from ILSI. She is being followed regularly for her medical and oncological problems.

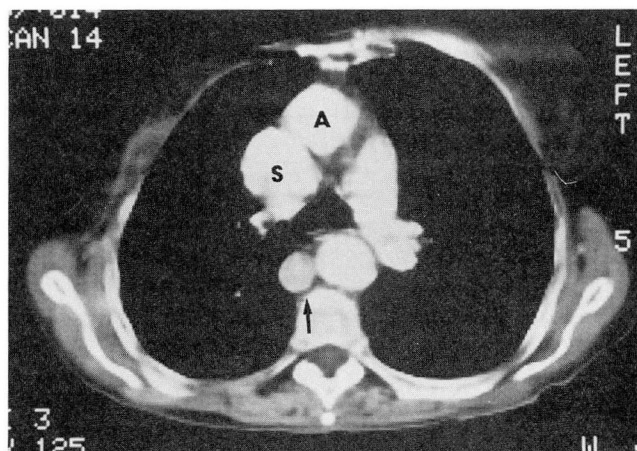


FIGURE 2. Contrast-enhanced CT scan at the level of the aorto-pulmonary window showing prominent azygous vein (arrow). Superior vena cava (S), ascending aorta (A), and main pulmonary artery are all in normal position.

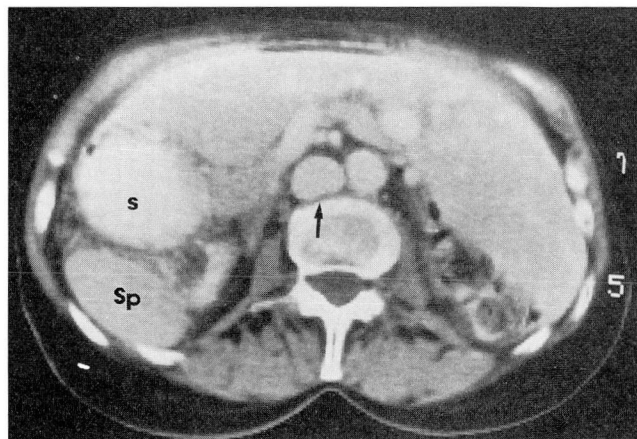


FIGURE 3. Contrast-enhanced abdominal CT scan revealing midline liver, spleen (Sp), and stomach (S) on the right; normal aorta; prominent azygous vein (arrow); and absence of the normal inferior vena cava.

#### DISCUSSION

ILSI is a rare condition with a reported incidence of 0.4% to 1.2% of all congenital heart diseases.<sup>1,2</sup> A total of 249 cases have been reported,<sup>1-17</sup> including the case described here (Table). ILSI is generally associated with congenital intracardiac abnormalities, and a normal or acyanotic heart is an uncommon finding. Including our patient, only 16 (6.4%) of the 249 known cases are reported to have had a normal heart.

## Terminology

Multiple and overlapping terms are used in the literature to describe ILSI and its associated conditions. The most relevant for our case are levoverision, mixed levocardia, and situs inversus.

*Levoverision* describes the compatibility concordance of the apex of the heart with the hepato-cavo-atrial segment, both situated to the left.<sup>13</sup>

In *mixed levocardia*, the heart is located in the left hemithorax with the apex axis pointing toward the left and caudally; however, the atrial and ventricular chambers are reversed.<sup>6</sup> Mixed levocardia may be seen with either atrial or ventricular inversion. Campbell and Deuchar<sup>1</sup> described 20 patients with atrial inversion and divided them into two subgroups: those with a left-sided vena cava and venous atrium and those with a right-sided vena cava and venous atrium. All 20 patients also had other congenital heart malformations. In addition, 6 of 30 cases (20%) reported by Liberthson and colleagues<sup>2</sup> had atrial inversions. Lev and Rowlatt<sup>6</sup> reported 13 cases of mixed levocardia with ventricular inversion, which they classified into two subgroups: those with complete transposition of the aorta and pulmonary artery and those with inverted transposition.

In *situs inversus*, the greater lobe of the liver, the venous atrium, and the suprahepatic segment of the IVC are all on the left side of the heart.<sup>13</sup> Situs inversus or visceral heterotaxy may be complete or partial. When situs inversus is complete, the location of the structures presents a mirror image of normal anatomy, whereas when situs inversus is partial, only some of the structures are inverted or in an abnormal position.

*Situs inversus* is caused by disturbances of migration, rotation, descent, or fixation during the embryonic development of the alimentary canal.<sup>3</sup> There is a close relationship between the development of the abdominal viscera and the venous atrium that is responsible for the variations in ILSI.<sup>18</sup> When the viscera are positioned normally, the IVC and the venous atrium are situated on the right; when situs inversus is complete, the IVC and venous atrium are on the left.

When an anomalous IVC and an anatomical right atrium are located on opposite sides of the midsagittal plane, the sites of the venous atria and the abdominal viscera may be discordant.<sup>12</sup> In order to achieve systemic venous drainage in this situation, the anomalous IVC must cross the midline to join the normally positioned venous atrium, usually via a hemiazygous to azygous communication at approximately T-12. However, the criterion of IVC-to-right atrial continuity

TABLE  
FREQUENCY OF NORMAL HEART WITH ILSI

Year	Authors	No. of cases	No. of normal hearts
1941	Anton, et al <sup>3</sup>	1	1
1951	Young, Griswold <sup>4</sup>	8*	—
1953	Campbell, et al <sup>5</sup>	14*	—
1961	Lev, Rowlatt <sup>6</sup>	13*	—
1962	Rosenbaum, et al <sup>7</sup>	3*	1
1965	Campbell, Deuchar <sup>1</sup>	6*	—
1965	Harris, Rainey <sup>8</sup>	160	9
1966	Chesler, et al <sup>9</sup>	1	—
1967	Annamalai, Ramakrishnan <sup>10</sup>	1	—
1968	Sugiura, et al <sup>11</sup>	32 <sup>†</sup>	3
1968	Hastreiter, Rodriguez-Coronel <sup>12</sup>	2	1
1972	Anselmi, et al <sup>13</sup>	7	—
1973	Liberthson, et al <sup>2</sup>	30	—
1973	Attie, et al <sup>14</sup>	1	—
1977	Matsuo, et al <sup>15</sup>	1	—
1982	Tonkin, Tonkin <sup>16</sup>	10	—
1983	Chacko, et al <sup>17</sup>	2	1/2 <sup>‡</sup>
1990	Vijayakumar, Brandt	1	1

\*Cases included by Harris and Rainey<sup>8</sup>

<sup>†</sup>Authors collected 32 cases from the Japanese literature since 1908, including one case of their own.

<sup>‡</sup>The only abnormality was mild pulmonary stenosis in one patient. The case was designated as "normal" by the authors.

does not apply in cases where there is an anomalous interrupted or absent IVC with azygous continuation, as occurred in our case.<sup>12</sup>

With normal embryologic development, the right atrium should receive the vena cava; however, other considerations, such as the visceral-atrial situs and intracardiac communications may also determine the functional site of the cardiac chambers.<sup>18</sup>

## Diagnosis

Isolated levocardia with visceral heterotaxy should be suspected in all patients with congenital heart disease. It can be identified or excluded by a thorough history and physical examination, chest radiograph, ECG, and echocardiogram. Depending on the initial examination, further evaluation with angiocardiography, radionuclide scans, or CT scans should be considered.

On the frontal radiograph, the heart is located on the left with the gastric shadow visible in the right upper quadrant of the abdomen. The ECG should show an upright P wave in lead I, while the echocardiogram will identify intracardiac anomalies. Arteriography is unwarranted in patients who have no significant cardiac

symptoms. CT scans of the chest and abdomen with intravenous and oral contrast should be obtained if delineation of the abdominal situs is necessary.

Radionuclide scintigraphy, sonography, and CT scanning all have relative advantages and disadvantages. Although splenic scintigraphy, radionuclide venography, and  $^{99m}\text{Tc}$ -sulfur colloid imaging have been diagnostic in the evaluation of ILSI, they are of limited value because they provide relatively poor spatial resolution.<sup>19,20</sup> Sonography is noninvasive, and it has good temporal and spatial resolution with the capacity to evaluate cardiac valve motion in variable imaging planes. However, it may have a limited field of view because overlying bony structures, air in the lungs or bowel, wounds, or chest wall fibrosis may interfere with imaging.<sup>16,21–25</sup>

CT scanning provides a large field of view, excellent spatial resolution, and the capability of displaying anatomic structures in three dimensions. Thus, CT scans may better demonstrate anatomic relationships and preclude the need for additional invasive studies. As faster scanning times become available, even greater definition of structures will be possible.<sup>16,22–24</sup>

Recently, magnetic resonance imaging has shown some benefits over ultrasound and CT scans for evaluating congenital cardiac malformations as it provides excellent tissue contrast between vasculature

and other surrounding structures. However, more studies are needed to confirm the diagnostic value of this technique.

### Survival

The prognosis is poor for patients with ILSI, and survival is usually related to the severity of an associated cardiac abnormality. Five-year survival ranges from 5% to 13%.<sup>2,8,10</sup> ILSI with a normal heart accounts for only 6.4% of all cases. Our patient, at the age of 73, is the second longest survivor reported. The longest survivor was reported by Sugiura and associates,<sup>11</sup> who described a patient alive at the age of 75. As in our case, that patient also had no significant intracardiac abnormality.<sup>11</sup>

### CONCLUSION

Our case suggests that in asymptomatic patients a CT examination of the chest and abdomen is sufficient to confirm the diagnosis of ILSI. Invasive procedures may be unnecessary. In addition, if intracardiac malformations are suspected, echocardiography may be used in the initial evaluation. The association of multiple malignancies with ILSI, like those seen in our patient, has not been previously reported, and the significance of this association is not known.

### REFERENCES

- Campbell M, Deuchar DC. Dextrocardia and isolated laevocardia. I: Isolated laevocardia. *Br Heart J* 1965; 27:69–82.
- Liberthson RR, Hastreiter AR, Sinha SN, Bharati S, Novak GM, Lev M. Levocardia with visceral heterotaxy—isolated levocardia: pathologic anatomy and its clinical implications. *Am Heart J* 1973; 85:40–54.
- Anton JJ, Panoff CE, Spiegel MB. Case reports. Segmental abdominal heterotaxy: situs inversus viscerum abdominis partialis. *Am J Surg* 1941; 54:446–456.
- Young MD, Griswold HE. Situs inversus of the abdominal viscera with levocardia: report of eight cases submitted to the Blalock-Taussig operation. *Circulation* 1951; 3:202–214.
- Campbell M, Forgacs P. Levocardia with transposition of the abdominal viscera. *Br Heart J* 1953; 15:401–422.
- Lev M, Rowlatt UF. The pathologic anatomy of mixed levocardia: a review of thirteen cases of atrial or ventricular inversion with or without corrected transposition. *Am J Cardiol* 1961; 8:216–263.
- Rosenbaum HD, Pellegrino ED, Treციokas LJ. Acyanotic levocardia. *Circulation* 1962; 26:60–72.
- Harris TR, Rainey RL. Clinical communications: ideal isolated levocardia. *Am Heart J* 1965; 7:440–448.
- Chesler E, Joffe N, Levin S, Freiman E. Levocardia with transposition of the abdominal viscera and acquired (rheumatic) heart disease. *Am J Cardiol* 1966; 18:764–768.
- Annamalai AL, Ramakrishnan T. Levocardia with partial sub-diaphragmatic heterotaxia. *Am Heart J* 1967; 19:268–274.
- Sugiura M, Okada R, Hiraoka K. Case report: isolated levocardia with polysplenia in an aged with special reference to minor cardiac abnormalities. *Jpn Heart J* 1968; 9:603–608.
- Hastreiter AR, Rodriguez-Coronel AR. Case reports. Discordant situs of thoracic and abdominal viscera. *Am J Cardiol* 1968; 22:111–118.
- Anselmi G, Munoz S, Blanco P, Machado I, de la Cruz MV. Systematization and clinical study of dextroversion, mirror image dextrocardia, and laevoversion. *Br Heart J* 1972; 34:1085–1098.
- Attie F, Malpartida F, Poveda JJ, Testelli MR, Veda JE. Acyanotic levoversion in situs inversus. *Chest* 1973; 64:668–670.
- Matsuo T, Yao T, Yoshida M, Miyazaki K. An elderly case of mixed levocardia with situs inversus including inverted atria and complete transposition of the great vessels—an autopsied case. *Jpn Circ J* 1977; 42:1015–1021.
- Tonkin ILD, Tonkin AK. Visceroatrial situs abnormalities. Sonographic and computed tomographic appearance. *Am J Roentgenol* 1982; 138:509–515.
- Chacko KA, Krishnaswami S, Sukumar IP, Cherian G. Isolated levocardia: two cases with abdominal situs inversus, thoracic situs solitus, and normal circulation. *Am Heart J* 1983; 106:155–159.
- Van Praagh R, Van Praagh S, Vlad P, Keith JD. Anatomic types of congenital dextrocardia: diagnostic and embryologic implications. *Am J Cardiol* 1964; 13:510–531.
- Freedom RM, Treves S. Splenic scintigraphy and radionuclide venography in the heterotaxy syndrome. *Radiology* 1973; 107:381–386.

20. Fitzer PM. An approach to cardiac malposition and the heterotaxy syndrome using  $^{99m}\text{Tc}$ -sulfur colloid imaging. *Am J Roentgenol* 1976; **127**:1021-1025.
21. Silverman NH. An ultrasonic approach to the diagnosis of cardiac situs, connections, and malpositions. *Cardiol Clin* 1983; **1**:473-486.
22. Bank ER, Hernandez RJ. CT and MR of congenital heart disease. *Radiol Clin North Am* 1988; **26**:241-262.
23. Farmer DW, Lipton MJ, Webb WR, Ringertz H, Higgins CB. Computed tomography in congenital heart disease. *J Comput Assist Tomogr* 1984; **8**:677-687.
24. Winer-Muram HT, Tonkin ILD. The spectrum of heterotaxic syndromes. *Radiol Clin North Am* 1989; **27**:1147-1170.
25. Huhta JC, Smallhorn JF, Macartney FJ. Two-dimensional echocardiographic diagnosis of situs. *Br Heart J* 1982; **48**:97-108.

