

Intensive care management of acute hemorrhagic leukoencephalitis with favorable neurologic outcome

BILL MASTRODIMOS, MD; GENE H. BARNETT, MD; ISSAM A. AWAD, MD

■ A 36-year-old woman who presented with acute hemorrhagic leukoencephalitis survived with favorable neurologic outcome. The patient underwent evacuation of a right temporal hematoma, with aggressive postoperative management in the neurosurgical intensive care unit. Aggressive surgical and medical therapy, including high-dose corticosteroid therapy and continuous intracranial pressure monitoring may yield favorable outcomes in an entity previously associated with dismal neurologic prognosis.

□ INDEX TERMS: ACUTE HEMORRHAGIC LEUKOENCEPHALITIS; INTRACEREBRAL HEMATOMA; INTRACRANIAL PRESSURE MONITORING
□ CLEVE CLIN J MED 1992; 59:549-552

ACUTE HEMORRHAGIC leukoencephalitis (AHL) is a rare fulminant disease affecting the cerebral white matter. First described in 1941,¹ AHL remains a poorly understood disease. It is often preceded by an upper respiratory tract infection which is later followed by a progressive neurologic decline over a period of 2 days to 2 weeks. AHL is usually fatal: only eight survivors have been reported. Of these survivors, five were diagnosed histologically, two by computed tomography (CT) and clinical findings, and one by clinical and laboratory findings.²⁻⁷ The disease can recur after an initial remission which may last months.^{3,8}

We present a patient who developed AHL and survived. The diagnosis was made by CT and clinical findings and was confirmed histopathologically at the time of surgery. The patient underwent surgical evacuation of an intracerebral hematoma and was

managed postoperatively in the neurosurgical intensive care unit with continuous intracranial pressure (ICP) monitoring, intravenous mannitol, and high-dose intravenous corticosteroid therapy.

CASE HISTORY

The patient, a 36-year-old woman, had a history of dermatomyositis and inflammatory bowel disease, for which she was being treated with chloroquine (150 mg/day), chlorambucil (4 mg/day), methotrexate (7.5 mg/week), and prednisone (20 mg/day). She presented to a local hospital complaining of generalized weakness, confusion and rectal bleeding. Her hemoglobin level was 5.9 mg/dL, and she was admitted for transfusion and evaluation of her rectal bleeding. On the second hospital day she complained of numbness and weakness on the right side of her body. She subsequently had a generalized tonic-clonic seizure and a temperature elevation to 39.3°C. A lumbar puncture was performed with an opening pressure of 42 cm H₂O. The cerebrospinal fluid (CSF) was xanthochromic, with a protein of 132 mg/dL, glucose of 87 mg/dL (serum glucose was 180 mg/dL), and white blood cell

From the Department of Neurological Surgery and the Neurosurgical Intensive Care Unit, The Cleveland Clinic Foundation.

Address reprint requests to G.H.B., The Cleveland Clinic Foundation, 9500 Euclid Avenue, Cleveland, OH 44195.

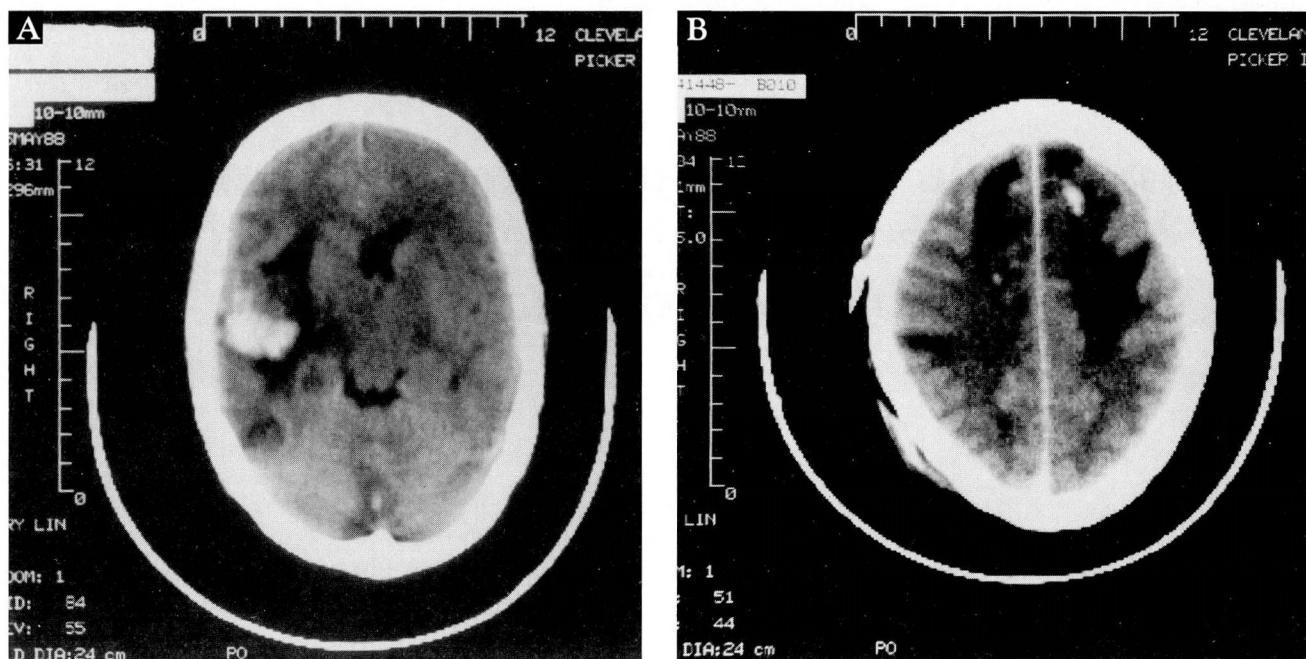


FIGURE. A computed tomography scan performed upon admission showed a 3-cm hematoma in the right temporal lobe (A), with surrounding edema and mass effect on the lateral ventricles. An additional 1-cm hematoma (B) was noted in the left frontal lobe, with a large amount of surrounding edema.

count of 4 per high-power field. Cultures of blood and CSF were negative. The patient had a second generalized tonic-clonic seizure within 3 hours, and she was subsequently intubated. By the third hospital day she was unresponsive to painful stimuli, had spontaneous decerebrate posturing, and her Glasgow coma scale score was 3T.⁹

She was transferred to the Cleveland Clinic Hospital. Upon arrival she was able to open her eyes to pain, and there was extensor posturing of her legs. Her right lower extremity was areflexic, plantar reflexes were extensor bilaterally, and muscle tone was greatly increased throughout. A CT scan of the head showed a 3-cm hematoma in the right temporal lobe and a 1-cm hemorrhage in the left frontal lobe, both with a large amount of surrounding edema (Figure). An emergency craniotomy was performed with evacuation of the right temporal hematoma. When the dura was opened, hematoma extruded under moderate pressure. The surrounding brain was edematous. Brain biopsy was performed from the wall of the hematoma cavity. A fiberoptic ICP monitor (Camino 420, Camino Laboratories, San Diego, CA 92121) was placed at this time.

Histopathologic findings were diagnostic of acute hemorrhagic leukoencephalitis. Dexamethasone, 10

mg intravenously every 6 hours, was started immediately and was gradually tapered over the next 3 weeks. Her ICP was continuously monitored; it reached a peak of 26 mm Hg on the second postoperative day. In addition to steroids, intracranial hypertension was further treated with intravenous mannitol titrated to maintain ICP below 20 mm Hg. The mannitol was then tapered gradually over a period of 1 week, as her ICP would permit. Her mental status improved greatly, and she became able to talk. She had severe extensor spasms of her lower extremities, and flexor spasms of her upper extremities. An intensive physical therapy program was begun; at 1 year follow-up, she is able to walk without assistance, has normal cognitive function, and has a Karnofsky score of 60.¹⁰

DISCUSSION

Pathophysiology

The etiology of AHL is unknown, though it is thought to be a delayed hypersensitivity reaction.^{2,11} An infectious process typically precedes it, though a causative agent has not been identified. It affects males and females equally and tends to occur in the second through fifth decades of life.

AHL progresses in three phases: prodromal, inter-

val, and neurologic.¹² The prodromal phase usually consists of a viral upper respiratory tract infection, although there are reports of AHL following a host of conditions, eg, viral pneumonia, surgery, vaccination, measles, and chicken pox.¹² In this phase, headache, generalized weakness, fever, confusion, nuchal rigidity, nausea, and vomiting are common.^{11,13-15} During the interval phase, these symptoms usually remit for a short period. The neurologic phase consists of a rapid, violently progressive neurologic decline. Paralysis affecting one or more limbs is common, as are cranial nerve palsies, focal and generalized seizures, hemianesthesia, headache, stupor, and aphasia. These findings usually appear in conjunction with a peripheral leukocytosis, proteinuria, and pyrexia.

CSF analysis reveals a pleocytosis with predominance of polymorphonuclear leukocytes. The pressure may be normal or slightly elevated. The glucose level is usually normal, but total protein is elevated in the range of 50 to 620 mg/dL. CSF cultures are invariably sterile.

The mortality rate from AHL remains high, with the diagnosis being made primarily at autopsy. The brain is congested, with changes confined to the white matter, and there is often evidence of herniation. Petechial hemorrhages are observed throughout the white matter, though some lesions become confluent and form hematomas. Subcortical "U-fibers" are typically spared. The infratentorial as well as the supratentorial compartments may be affected; however, only two cases of AHL confined to the posterior fossa have been reported.¹⁶ The histopathology of AHL has been previously described.^{14,15,17,18}

Recently, CT has played a role in early diagnosis. The findings are of multifocal areas of decreased attenuation in the cerebral white matter; these areas are of various sizes. Brain swelling with midline shift is usually noted.^{14,19,20} When the hemorrhages become confluent, multiple intracerebral hematomas may be observed. Follow-up CT scans on two reported cases showed partial or complete resolution of these lesions; unfortunately, the diagnosis was not confirmed histopathologically.^{6,7}

Treatment

Treatment of AHL has traditionally consisted of supportive measures with empiric treatment of

elevated ICP, and death is the usual outcome. Recently, the use of high-dose corticosteroid therapy, dehydrating agents, and surgical decompression has led to survival in some cases.^{3,5} Among previously reported survivors, two recovered spontaneously, three were treated with high-dose corticosteroid therapy alone, one with surgical decompression only, and two with surgery and corticosteroids.^{2-7,21}

High-dose corticosteroids. Steroids may disrupt the inflammatory component of AHL and help to decrease cerebral edema. In our case, the use of immunosuppressive agents prior to presentation did not prevent the disease, nor affect its severity. This finding calls into question the proposed pathophysiology of AHL (ie, that it is a delayed hypersensitivity reaction), but doesn't diminish the value of high-dose corticosteroid treatment in combatting inflammation and cerebral edema.

Surgery. Surgical decompression has been advocated when medical management of progressive cerebral edema cannot be accomplished.⁵ Ordinarily, surgical evacuation of a hematoma to relieve mass effect and midline shift should be carried out early, as it was in this case. However, when multiple intracerebral hematomas in the absence of trauma, malignancy, or coagulopathy do not warrant immediate evacuation, we advocate stereotactic biopsy to establish the diagnosis.²²

ICP monitoring. The use of ICP monitoring has not been previously described in the management of AHL. In our case, ICP monitoring proved useful in titrating hyperosmolar agents to a desired ICP while maintaining normal systemic hemodynamic parameters. ICP monitoring may assist in deciding the need for and timing of surgical intervention, should ICP elevations become refractory to medical management.

CONCLUSION

The rapid decline frequently observed in AHL underscores the need for early diagnosis and aggressive intervention to treat hematoma and malignant brain edema. Clinical suspicion coupled with laboratory and CT findings should alert the clinician to the possibility of AHL. High-dose corticosteroid therapy and surgical decompression are integral to therapy of AHL, and ICP monitoring can be a useful adjunct to therapy.

REFERENCES

1. Hurst EW. Acute haemorrhagic leucoencephalitis: a previously un-
2. Byers RK. Acute hemorrhagic leukoencephalitis: report of three cases and review of the literature. *Pediatrics* 1975; 56:727-735.

defined entity. *Med J Aust* 1941; 2:1-6.

3. Coxe WS, Luse SA. Acute hemorrhagic leukoencephalitis. A clinical and electron-microscopic report of two patients treated with surgical decompression. *J Neurosurg* 1963; **20**:584-596.
4. Kristansen K, Harkman W, Cohen MM. Acute hemorrhagic encephalitis. *Neurology* 1956; **6**:503-509.
5. Litel G, Ehni G. Acute hemorrhagic leukoencephalitis. Treatment with corticosteroids and dehydrating agents. *J Neurosurg* 1970; **33**:444-452.
6. Reich H, Lin S-R, Goldblatt D. Computerized tomography in acute hemorrhagic leukoencephalopathy: a case report. *Neurology* 1979; **29**:255-258.
7. Suchowersky O, Sweeney VP, Berry K, Bratty PJ. Acute hemorrhagic leukoencephalopathy. A clinical, pathological, and radiological correlation. *Canadian Journal of Neurological Sciences* 1983; **10**:63-67.
8. Lamarche JB, Behan PO, Segarra JM, Feldman RG. Recurrent acute necrotizing hemorrhagic encephalopathy. *Acta Neuropathol* 1972; **22**:79-87.
9. Teasdale G, Jennett B. Assessment of coma and impaired consciousness. A practical scale. *Lancet* 1974; **2**:81-84.
10. Karnofsky DA, Burchenal JH. The clinical evaluation of chemotherapeutic agents in cancer. Symposium Microbiology Section, New York Academy of Medicine. New York, New York: Columbia University Press, 1948:191-205.
11. Behan PO, Moore MJ, Lamarche JB. Acute necrotizing hemorrhagic encephalopathy. *Postgrad Med* 1973; **54**:154-160.
12. Kulick SA. Acute hemorrhagic leukoencephalitis: report of a case and review of the literature. *BMJ* 1960; **11**:120-130.
13. Bennet DR, ZuRhein GM, Roberts TS. Acute necrotizing encephalitis. A diagnostic problem in temporal lobe disease: report of three cases. *Arch Neurol* 1962; **6**:96-113.
14. Castleman B, Kibbee BU. Case records of the Massachusetts General Hospital: Case 48-1961. *N Engl J Med* 1961; **265**:34-40.
15. Gosztanyi G. Acute hemorrhagic leukoencephalitis. Report of three cases. *Z Neurol* 1973; **204**:43-66.
16. Michaud J, Helle TL. Acute haemorrhagic leukoencephalitis localised to the brainstem and cerebellum: a report of two cases. *J Neurol Neurosurg Psychiatry* 1982; **45**:151-157.
17. Aronson SM, Perl DP. Clinicopathologic conference: acute hemorrhagic necrotizing encephalopathy. *Dis Nerv Syst* 1973; **34**(5):263-268.
18. Graham DI, Behan PO, More IAR. Brain damage complicating septic shock. Acute hemorrhagic leukoencephalitis as a complications of the generalized Shwartzman reaction. *J Neurol Neurosurg Psychiatry* 1979; **42**:19-28.
19. Barontini F, DiLollo S, Toscani L. Acute hemorrhagic leukoencephalopathy. Clinical and CT diagnosis and histopathological confirmation in an elderly patient. *Ital J Neurol Sci* 1984; **5**:215-218.
20. Watson RT, Ballinger WE, Quisling RG. Acute hemorrhagic leukoencephalitis: diagnosis by computerized tomography. *Ann Neurol* 1984; **15**:611-162.
21. Rao SV, Roy S, Shankar SK, Virmani V. Acute necrotising leukoencephalitis. Report of two cases. *Neurol India* 1978; **26**:190-192B.
22. Whiting DM, Barnett GH, Estes ML, et al. Stereotactic biopsy of non-neoplastic lesions in adults. *Cleve Clin J Med* 1992; **59**:48-55.

