

# WILMS' TUMOR (ADENOMYOSARCOMA) OF THE KIDNEY IN CHILDREN

## *Report of a Case*

C. C. HIGGINS, M. D. and F. L. SHIVELY, JR., M. D.

Wilms' tumor of the kidney is a topic of considerable discussion today by both the medical profession and the laity. The tumor was recognized as early as 1872 and has been a subject of conjecture since its first description. In this year, Eberth<sup>1</sup> presented an accurate description of the neoplasm. Prior to this time any tumor of the kidney, regardless of the age of the patient, was classified as being carcinomatous in nature.

Wilms' tumor of the kidney is a mixed cell tumor and may contain any or all of the derivatives of the three germinal layers. Because of the multiplicity of tissues, many theories have been advanced as to its derivation. In 1872, Eberth<sup>1</sup> suggested the theory that the tumor was derived from remnants of the wolffian body. Cohnheim<sup>2</sup>, in 1875, attributed the origin to aberrant germ plasm from the primitive segments and Ribbert<sup>3</sup>, in 1886, in agreement with Cohnheim, stated the tumor was derived from a totipotent blastomere. In 1894, Birch-Hirschfeld<sup>4</sup> concurred with Eberth upon its origin from the wolffian body. Brock<sup>5</sup>, in 1895, averred that the derivation was from embryonic cell inclusions embedded in the urogenital fold.

One can readily observe that there was much confusion as to the exact origin or derivation of this neoplasm. This led Wilms<sup>6</sup>, to write his important monograph on the origin and derivation of this tumor. His theory at present is the one most widely accepted. He stated that the wolffian body could not be expected to produce all of the tissues so commonly found. He assumed that they were derived from primitive undifferentiated mesodermal tissue of the type that in the course of normal development gives rise to the myotome (skeletal muscle), sclerotome (vertebrae), nephrotome (wolffian body anlage), and mesenchymal tissue which gives rise to smooth muscle.

Several theories have been advanced in recent years, but most of these have been, more or less, reiterations of the theories mentioned previously. Ewing<sup>7</sup>, however, in 1934, favored the conception that these tumors are derived from the renal blastoma. This view attributes a prominent part to metaplasia, thus accounting for the adult types of tissues found, namely, squamous epithelium, striated muscle, cartilage, and bone.

## REPORT OF CASE

The patient was a girl, 4 years of age, who was admitted to the Clinic on May 4, 1939. The mother had observed a protuberant abdomen and stated that one side of the child's body was larger than the other.

The following history was obtained from the mother. The child was delivered normally, and was physically perfect in all respects. The patient had been given cod liver oil and orange juice since birth. The first difficulty was encountered when it became necessary to feed the child from the bottle, at which time marked constipation began and an umbilical hernia developed. She was subsequently placed on skim milk and the progress was quite satisfactory. At the age of about one year severe otitis media developed, the temperature being elevated for five weeks. This condition finally subsided and the child was in good health for the following year. It was then deemed advisable to place the patient on a high fat diet because of malnutrition. Following the use of this diet, severe vomiting, marked diarrhea, and a high fever developed. Urinalysis at this time revealed the presence of sugar, acetone, albumin, and pus. These urinary findings had recurred upon two other occasions when the so-called fat diets were administered and always subsided in about one week. Thyroid extract was advised by the attending physician but this was not given over an extended period of time because of an elevation of temperature which followed its administration.

Since the age of two years the patient had had a potbelly, accompanied by a considerable amount of gas which required an enema every night in order that she could sleep. The bowels, however, had been regular for the past six months, the stool being normal in all respects. The mother had also noticed that the left side of the body was larger than the right but was indefinite as to the duration of this symptom.

A few days prior to admission, the temperature became elevated, accompanied by an occasional pain in the abdomen. The patient also complained of frequency, nocturia, burning, and dysuria; pyuria was noted. Blood had not been observed in the urine. There were no respiratory or cardiovascular complaints.

*Physical Examination:* The patient was a well developed, well nourished girl whose height was 42 inches and weight 40 pounds. The temperature was 101.8° F., pulse rate 120 per minute, respirations 24, and blood pressure 100/70. The skin was pale and of good texture. Examination of the eyes, ears, nose, and mouth was negative. The thyroid was not enlarged. The chest, lungs, and mediastinum were normal and there were no abnormal findings in the heart. Examination of the abdomen revealed it to be large, prominent, and somewhat distended. There was an indefinite, tender, very large, irregular mass filling the entire left side of the abdomen. The right side was distended with gas. A small umbilical hernia was present. Examination of the external genitalia and rectum was negative. The right arm and leg were definitely smaller than the extremities of the opposite side but, however, there was no loss of power on the affected side. The cranial nerves and the reflexes were normal.

*Laboratory Findings:* Examination of the blood showed 3,950,000 red cells with 71 per cent hemoglobin, and 8,300 white cells with a differential count of 51 per cent neutrophils, 1 per cent eosinophils, 43 per cent lymphocytes, and 4 per cent monocytes. The level of blood sugar was 79 mg. per 100 cc. Wassermann and Kahn tests of the blood gave negative reactions. Urinalysis

## WILMS' TUMOR (ADENOMYOSARCOMA) OF KIDNEY IN CHILDREN

showed the pH to be 6.0, a trace of albumin, but no sugar was present; an occasional white blood cell and a rare red blood cell were found.

The initial roentgenogram of the abdomen revealed the lumbosacral region to be normal. No suspicious shadows were seen in the urinary tract. The kidneys could not be visualized because the intestines were distended with gas.

An intravenous urogram showed the kidneys to have prompt and good function. The right kidney was high but apparently normal. The left kidney was very large, extending low into the left abdomen. A definite filling defect was present (Fig. 1).

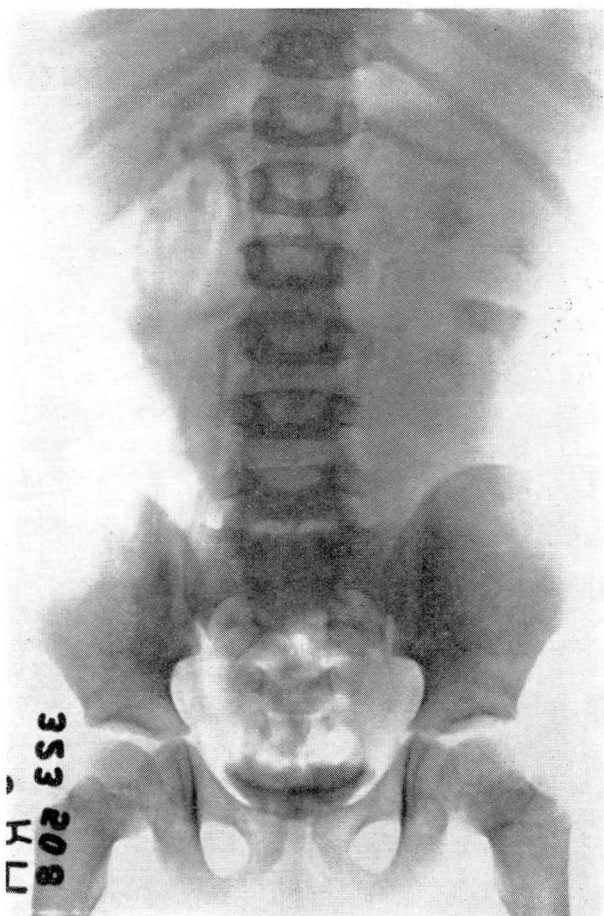


FIGURE 1: Intravenous urogram showing large filling defect in left kidney.

Roentgen examination of the chest was essentially normal. There was no evidence of metastasis.

A diagnosis of Wilms' tumor of the kidney was made and, after considering the above information, it was deemed advisable to administer a course of deep roentgen therapy. This was carried out in the following manner by Dr. R. D.

Bacon of Erie, Pennsylvania. Roentgen rays were applied in three ports, the anterior, lateral, and posterior renal areas, 200 kilovolts at 50 cm. with a Thoraeus filter and a half-value layer of 1.45 mm. of copper being used. The wave length was estimated as being .140 angstrom unit. In the treatment a portal 15x10 cm. vertical and transverse diameters respectively was used. Treatments of 100 r units daily were given until 1,700 r units had been administered to each of the three ports, making a total of 5,100 r units. It was estimated that this irradiation represented approximately 2,500 r units to the kidney pedicle.

The patient tolerated the above therapy very well, but developed a moderate radiation dermatitis with desquamation of the surface epithelium. This healed promptly in a few weeks.

An excellent result was obtained in that the patient lost but little weight while the abdominal circumference was reduced from 25 inches to 21 inches, and the circumference at the rib margin was reduced from 25 inches to 19.5 inches. Nephrectomy was advised, but it was thought best to postpone the surgical procedure for an additional three weeks, so that the patient could secure all possible benefit from the irradiation.

The patient was admitted to the Cleveland Clinic Hospital on June 29, 1939. The laboratory findings were as follows: Examination of the blood revealed 4,150,000 red cells with a slight anisocytosis, 65 per cent hemoglobin, and a color index of 0.78. There were 3,500 white cells, the differential count showing 60 per cent neutrophils, 3 per cent basophils, 24 per cent lymphocytes, and 12 per cent monocytes. No abnormal white blood cells were found. The blood platelets were normal. The level of the blood urea was 45 mg. per 100 cc. Blood Wassermann and Kahn tests gave negative reactions. Urinalysis showed the pH to be 6.0, and specific gravity 1.016, a trace of albumin was noted and no sugar was present; many red blood cells and a moderate amount of amorphous crystals were found. A vaginal smear for the gonococcus was negative.

On the following day operation was performed under avertin anesthesia. It was necessary to administer a small amount of ether during the course of the procedure. A left nephrectomy was done in the routine manner; no unforeseen circumstances were encountered during the operation. The course in the hospital was uneventful and the patient was discharged on the twelfth postoperative day.

*Pathological Description of Kidney Tumor:* The gross specimen consisted of a left kidney which weighed 182 grams and measured 12x5x5 cm. (Fig. 2). A small amount of fatty tissue was attached to the capsule. The ureter was divided approximately 1.5 cm. from the ureteropelvic junction. The upper pole, calices, and pelvis appeared to be normal. At the lower pole of the kidney there was an encapsulated tumor mass which measured 4.5x4.5x4.5 cm. It was sharply marked off from adjacent kidney tissue but was covered by the kidney capsule. The tumor had a mottled, hemorrhagic surface, with a large, irregular, central hyalinized scar around it, in which there were numerous small cystic areas varying from 0.5 to 1.5 cm. in diameter. The tumor tissue was spongy, edematous, hemorrhagic, and the cut surface had a mucoid appearance.

Immediately above the foregoing nodule and situated beneath the capsule on the lateral border was a second encapsulated, cystic, tumor mass 1.5 cm.



## WILMS' TUMOR (ADENOMYOSARCOMA) OF KIDNEY IN CHILDREN

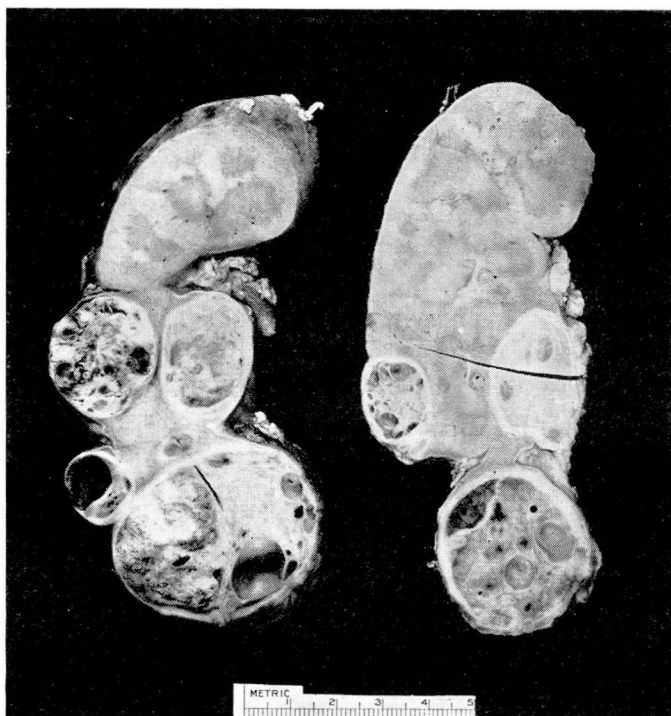


FIGURE 2: Gross specimen. Wilms' tumor at inferior pole. Note normal renal parenchyma at superior pole.

in diameter. This tumor was large and cystic, with little remaining solid neoplastic tissue. Deeply situated in the kidney just above the first tumor nodule described was a third small, encapsulated tumor nodule about 1 cm. in diameter which was solid and hemorrhagic but not cystic. On the mesial surface of the kidney at the lower pole of the hilum, was a fourth encapsulated tumor nodule measuring 2.5x2.0 cm. on the cut surface. Opposite the fourth tumor and embedded in the lateral border of the kidney, was a fifth encapsulated tumor measuring 2.8x2.4 cm. on the cut surface. This consisted of solid, fairly cellular, friable, yellowish-white tumor tissue with a few quite small cystic and hemorrhagic areas, but with very little hyalinization. On the mesial surface near the lower pole of the hilum there was a sixth small encapsulated tumor nodule 1 cm. in diameter, which had a solid white uniform cut surface. The tumor was solid, firm, elastic, and without cysts, areas of necrosis or hyalinized scars. At the same level near the lower pole on the lateral border was an eighth encapsulated tumor measuring 1.8x1.3 cm. on the cut surface. The tumor had numerous small cystic spaces. On the anterior surface and occupying the middle third of the kidney was a ninth tumor module less well encapsulated, having a very dense hyalinized peripheral zone and an irregular central zone composed of uniform, quite cellular, yellowish-brown tumor tissue, grossly suggestive of hypernephroma.

There was no grossly identifiable invasion of the pelvic veins. The tumor nodules did not involve the pelvic mucosa.

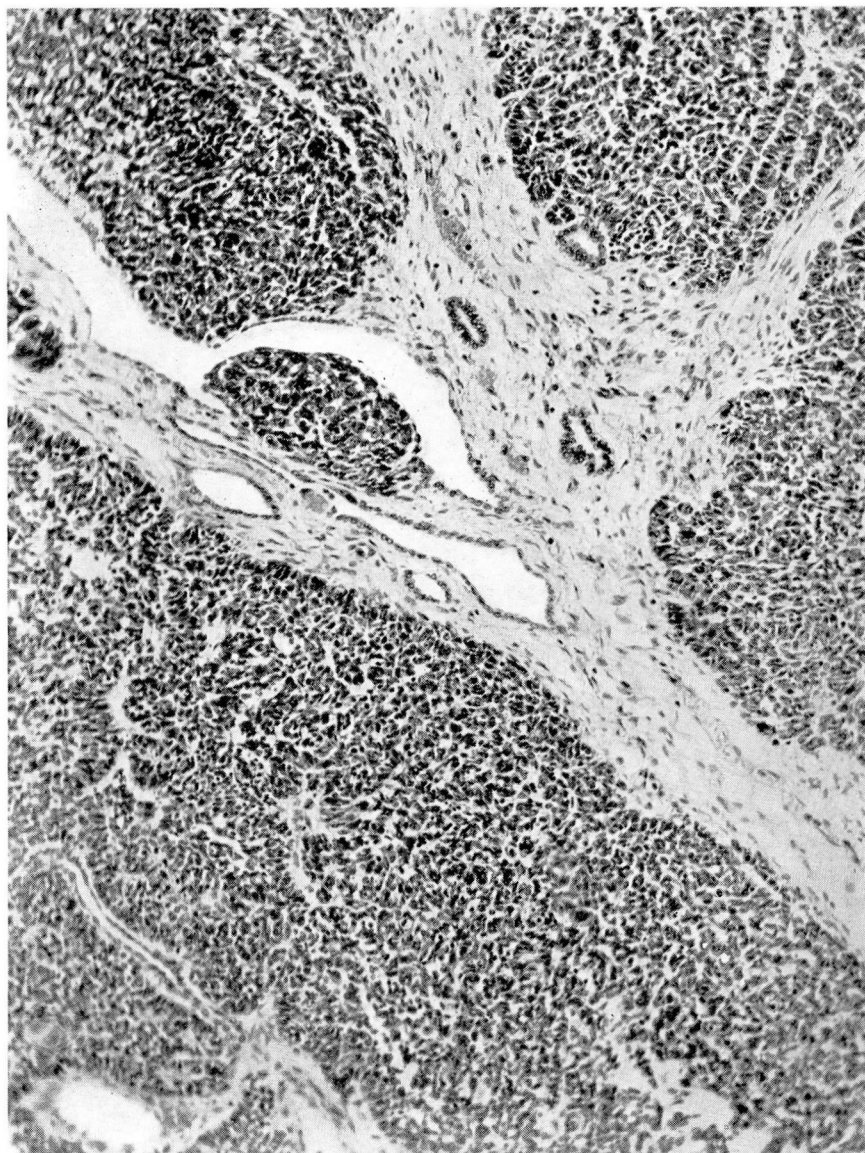


FIGURE 3: Microphotograph taken from a typical area in tumor showing similarity of cell growth and rather well marked hyalinization, necrosis, and cicatrization.

*Microscopic Examination:* Numerous sections from the various areas described above showed an essentially similar type of growth in all nodules (Fig. 3). There were differences due probably to variations in the degree of differentiation, degenerative changes, and also possibly to the effect of irradiation. All of the nodules appeared to be quite well localized or encapsulated and consisted of highly undifferentiated or embryonal cells of the epithelial type, showing varying degrees of differentiation toward what appear to be immature renal tubules and in some instances glomeruli. There was



## WILMS' TUMOR (ADENOMYOSARCOMA) OF KIDNEY IN CHILDREN

a great deal of loosely arranged, edematous stroma with areas of hyalinized degeneration, necrosis and cicatrization. There were areas of recent and old hemorrhage, of inflammatory reaction, phagocytosis of blood pigment and large phagocytic cells containing lipoid material. In none of the sections was there any cartilage. In one section there were several small plaques of well differentiated bone, probably of metaplastic origin (Fig. 4). No neoplastic muscle tissue was found in any of the sections.

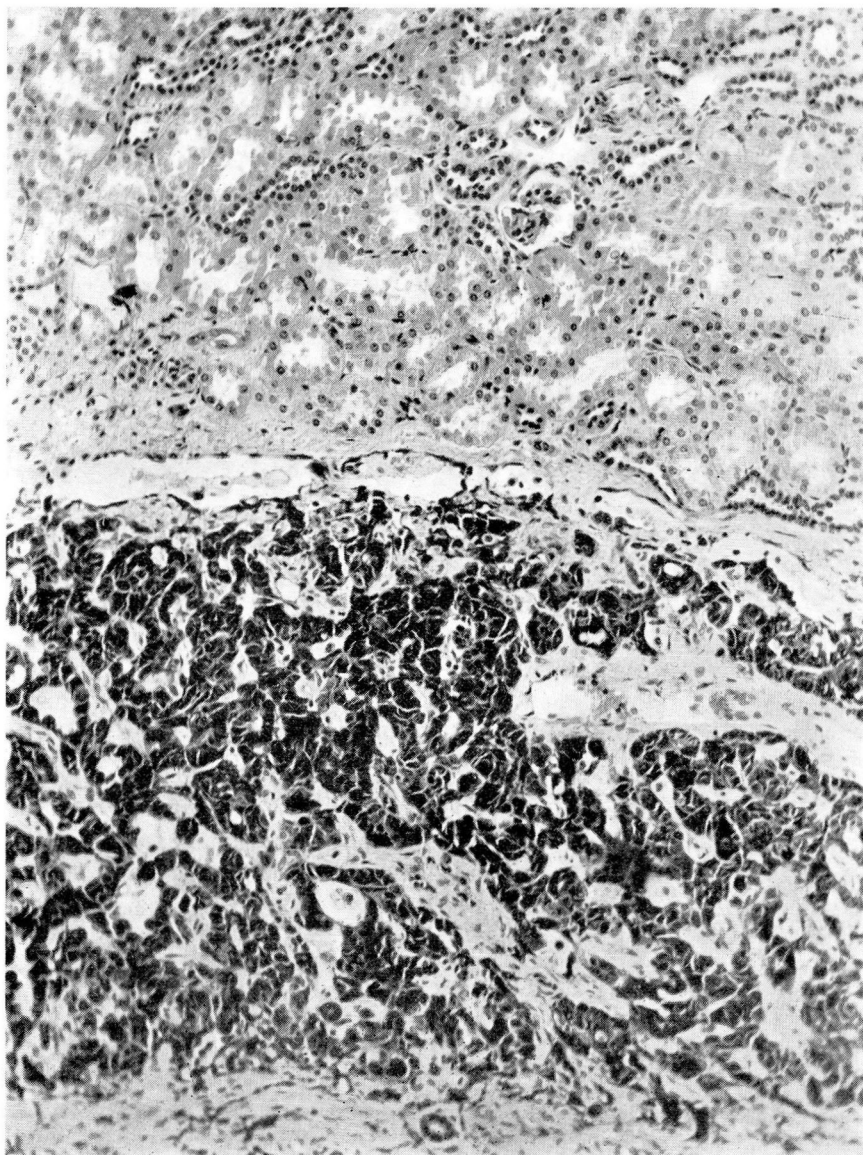


FIGURE 4: Microphotograph of section taken from an area showing immature renal tubules and scattered areas of differentiated bone.

*Follow-Up:* In view of the fact that the patient obtained such a good result from the preoperative irradiation, it was deemed advisable to continue the roentgen therapy postoperatively. This was done under the direction of Dr. Bacon. From July 11 to August 14, 1939, the patient had received eleven treatments of 100 r units successively to each of the three renal ports. This therapy is to be continued for the ensuing 6 weeks until a dose of 1,200 r units has been given to each port, making a total of 3,600 r units.

Together with the radiation therapy the attending roentgenologist administered 600 units of thiamine chloride (vitamin B<sub>1</sub>) daily in an attempt to obviate any undue gastrointestinal symptoms.

According to the last report, 2 months after the operation, the child is gaining weight and her general condition is excellent.

## DISCUSSION

The symptoms as a rule are not referable to the urinary tract but are general in nature. The most frequent symptom is that of an abdominal tumor. This is usually noticed by the mother, who states that the child's abdomen has grown progressively larger over a period of time and the enlargement usually is not accompanied by pain until late in the course of the disease. As the tumor increases in size, symptoms of pressure are noted, such as nausea, vomiting, constipation, and shortness of breath which is caused by the upward displacement of the diaphragm. Anemia becomes a prominent symptom as the disease progresses. In the more serious cases, blood transfusions may be resorted to prior to surgical intervention. Symptoms referable to the urinary tract may be absent. The usual complaints are frequency, nocturia, hematuria, and burning on urination.

Renal neoplasms comprise about 20 per cent of new growths occurring in children. The age incidence is variably placed between 6 months and 6 years. There have been 17 instances of this neoplasm at the Cleveland Clinic, of which this patient is a typical example. In our series of 17 cases, there were 6 male and 11 female children.

Concerning the symptomatology in the series, 65.5 per cent of the cases exhibited an abdominal tumor, 18.7 per cent experienced nephritic or abdominal pain, 12.5 per cent had gross hematuria, and 23.0 per cent showed microscopic blood in the urine. An elevation in temperature was present in 25.0 per cent of the cases. Anorexia and loss of weight were protean throughout the series.

The diagnosis is made with little difficulty. The history given by the mother is suggestive. The initial roentgenogram may reveal a large mass in the region of the kidney. The diagnosis of a kidney tumor may be determined by the use of the intravenous urogram or retrograde pyelography. The pyelogram is most useful in arriving at a diagnosis, having established the diagnosis in 100 per cent of the cases in Kretsch-



## WILMS' TUMOR (ADENOMYOSARCOMA) OF KIDNEY IN CHILDREN

mer's<sup>8</sup> series. The urogram is useful in only approximately 70 per cent of the cases. The reason for this is that a large amount of renal parenchyma may be destroyed, and there is insufficient renal tissue to concentrate the intravenous dye.

The accepted treatment at present is preoperative radiation therapy followed by nephrectomy. Kerr<sup>9</sup> advocates as preoperative radiation the use of 200 r units daily to each of three ports until a total dose of 3,000 to 4,000 r units have been given. He also advises the irradiation of pulmonary metastases. There are cases on record in which pulmonary metastases have disappeared following roentgen therapy. Some authors advocate the use of postoperative irradiation. Transfusion of blood may be required if pronounced anemia is present.

According to many authors the prognosis is not favorable. The mortality is variously placed at 90 per cent and very few patients have survived a five-year period. The most discouraging complication is metastases, the most frequent sites being first to lungs and second to bone. The duration of the tumor and the age of the patient seem to have little bearing upon the appearance of metastases.

As to the end results in our series, 9 patients were traced and all were dead with the exception of the one reported herein. The average duration of life, regardless of the therapy instituted, was 8.6 months. Nephrectomy was performed in 14 cases. Exploration was done in two cases, both of which were dead within a period of five months. There was no follow-up on 5 of the cases.

The morbidity and mortality in this group was as follows: 14.3 per cent lived two and one-half years, 21.4 per cent lived one and one-half years, and 69.0 per cent were dead within 6 months after operation.

### CONCLUSIONS

The case reported is a typical example of the occurrence of a Wilms' tumor in a child. The tumor was first noted by the mother, which is the usual rule. The primary symptoms were generalized, urological symptoms being secondary. There was no evidence of metastases to the pulmonary system or to bone.

This tumor was rapidly reduced in size by irradiation to each of three renal ports, a total of 5,100 r units being administered. Nephrectomy was then performed and roentgen therapy was instituted following surgical intervention.

The prognosis of this case is guarded. It is possible with pre- and postoperative irradiation combined with nephrectomy, that the patient may survive for the five-year period.

REFERENCES

1. Eberth, C. J.: Myoma sarcomatodes renum, Virchow's Arch. f. path. Anat., 55:518-520, 1872.
2. Cohnheim, J: Congenitales, quergestreiftes Muskelsarkom der Nieren, Virchow's Arch. f. path. Anat., 65:64-69, 1875.
3. Ribbert: Ueber ein Myosarcoma striocellulare des Nierenbeckens und des Ureters, Virchow's Arch. f. path. Anat., 106:282-295, 1886.
4. Birch-Hirschfeld, F. V.: Op. cit. 8.
5. Brock, G.: Eine geschwulst der Nierengegend mit quergestreiften Muskelfasern, Virchow's Arch. f. path. Anat., 140: 493-502, 1895.
6. Wilms, M.: Die Mischgeschwuelste. Arthur Georgi, Leipzig, 1899.
7. Ewing, James: Neoplastic Diseases. W. B. Saunders Co., Philadelphia, 1934.
8. Kretschmer, H. L.: Malignant tumors of kidney in children, J. Urol., 39:250-275, (March) 1938.
9. Kerr, H. D.: Treatment of tumors of the kidney in children, J. A. M. A., 112:408-411, (February) 1939.