

Tretinoin emollient cream 0.01% for the treatment of photoaged skin

JUDITH M. ANDREANO, MD; WILMA F. BERGFELD, MD; SHARON VANDERBRUG MEDENDORP, MPH

■ Tretinoin emollient cream 0.01% was used to treat 40 patients with photoaged skin of the face and forearms in a 48-week, randomized, double-blind, placebo-controlled study. On the face, a significant difference between treatment groups was found in the investigator's global evaluation ($P < .001$), and in fine wrinkling ($P < .001$) and coarse wrinkling ($P = .02$) at 24 weeks. Tretinoin-treated forearms showed significantly greater improvement in roughness, mottled hyperpigmentation, fine wrinkling, and lentigines at 24 and 48 weeks. More consistent improvement was seen on the forearms than on the face. Adverse experiences on the face in both treatment groups included dryness, peeling, and acne. No significant difference in reported adverse experiences was found between forearms in both treatment groups. On forearms, dermatitis was the most common adverse event. Tretinoin 0.01% was generally well tolerated, and skin irritation was minimal. Tretinoin emollient cream 0.01% is a potentially safe, effective treatment for photodamaged skin.

□ INDEX TERMS: TRETINOIN; SKIN AGING; ULTRAVIOLET RAYS □ CLEVE CLIN J MED 1993; 60:49-55

CHRONIC EXPOSURE to ultraviolet radiation, or photoaging, causes profound clinical, mechanical, and histologic changes in human skin.¹ It contributes to age-related changes in the skin and accounts for many of the visible signs of premature aging, such as roughness, mottled hyperpigmentation, wrinkling, laxity, and, eventually, premalignant and malignant neoplasms.²

■ See editorial, p.88

Early studies with hairless mice suggested a role for topical tretinoin (retinoic acid) in the treatment of extrinsic aging.^{3,4} Subepidermal collagen formation

was evident after avoidance of further ultraviolet radiation and the use of sunscreens.^{4,5} Topically applied tretinoin accelerated the repair of ultraviolet radiation damage in a time- and dose-dependent manner.^{6,7}

The multiple effects of tretinoin on the epidermis and dermis have led to a widespread interest in its potential as an "anti-aging" agent. Several studies in humans have reported partial reversal of clinical and histologic signs of photodamage in tretinoin-treated skin.⁸⁻¹³

In a double-blind, vehicle-controlled study of 30 patients, Weiss et al^{9,10} observed clinical and histologic improvement in photodamaged skin after 16 weeks of treatment with tretinoin 0.1%. All tretinoin-treated forearms and 93% of tretinoin-treated faces improved, whereas no improvement occurred with vehicle treatment. Statistically significant improvement was seen in both fine and coarse wrinkling, pinkness, and roughness. During the study, 92% of subjects experienced dermatitis in tretinoin-treated areas. Statistically significant histologic changes were noted, including increased epidermal thickness, reduction of dysplasia,

From the Departments of Dermatology (J.M.A., W.F.B.) and Biostatistics and Epidemiology (S.V.M.), The Cleveland Clinic Foundation.

Address reprint requests to W.F.B., Department of Dermatology, A61, The Cleveland Clinic Foundation, 9500 Euclid Avenue, Cleveland, OH 44195.

TABLE 1
CLINICAL IMPROVEMENT OF THE FACE AFTER 24 AND 48 WEEKS OF TRETINOIN THERAPY

	Global response 24 weeks		Global response 48 weeks		Fine wrinkling 24 weeks		Coarse wrinkling 24 weeks	
	Placebo n (%)	Active n (%)	P/A* n (%)	Active n (%)	Placebo n (%)	Active n (%)	Placebo n (%)	Active n (%)
Much improved [†]	2 (12)	3 (18)	3 (19)	5 (31)	0 (0)	0 (0)	1 (6)	0(0)
Improved [‡]	0 (0)	3 (18)	4 (25)	5 (31)	0 (0)	3 (18)	0 (0)	1 (6)
Slightly improved [§]	1 (6)	8 (47)	8 (50)	6 (38)	3 (18)	10 (59)	0 (0)	6 (35)
No improvement/worse	14 (82)	3 (18)	1 (6)	0 (0)	14 (82)	4 (23)	16 (94)	10 (59)
Total	17 (100)	17 (100)	16 (100)	16 (100)	17 (100)	17 (100)	17 (100)	17 (100)
Exact chi-square test	P< .001		P= .73		P< .001		P= .02	

*Placebo cross over to active
[†]Score decreased three units
[‡]Score decreased two units
[§]Score decreased one unit
^{||}Score did not decrease

and decreased melanocyte activity. The clinical improvement was sustained for up to 22 months during an open-label follow-up study, despite reductions in dose or frequency of tretinoin application.¹¹

A subsequent double-blind, vehicle-controlled study by Leyden et al¹² using 0.05% tretinoin cream confirmed the efficacy of tretinoin for the treatment of photodamaged facial skin. In addition to improvement in clinical features, skin was smoother and less wrinkled in the tretinoin-treated group than in the vehicle-control group. A more recent multicenter study provided additional evidence that tretinoin 0.05% is effective in treating photodamaged skin, and that tretinoin 0.01%, although less effective, also improved photodamaged skin by some criteria used.¹³

We conducted a double-blind, randomized, placebo-controlled investigation using a low concentration of tretinoin (0.01%) in a new emollient-cream vehicle to evaluate its safety and efficacy for the treatment of photoaged skin.

MATERIALS AND METHODS

Forty Caucasian patients, ages 30 to 50, with mild or moderate photoaging of the face, forearms, and hands, were entered in the 48-week study. All patients were healthy and had discontinued all topical drugs 30 days before they entered the study. Pregnant or nursing women and patients with visible actinic keratoses or a history of skin cancer were excluded. Informed consent was obtained from all patients, and a negative serum beta-subunit pregnancy test was required of female patients before the initial drug administration.

All patients received tretinoin emollient cream

(TEC) 0.01% (RW Johnson Pharmaceutical Research Institute, Raritan, NJ) and placebo vehicle cream daily to opposite forearms and hands for 48 weeks, and half of the patients were randomly assigned to receive TEC 0.01% to the face for 48 weeks. Patients who received the placebo vehicle to the face for the first 24 weeks crossed over to open-label TEC 0.01% to the face for the remaining 24 weeks. Test article application was made to the designated treatment sites once each evening during the therapy period. TEC was mineral-oil based and contained standard preservatives and fragrances; it had no active ingredients other than tretinoin.

Patients were supplied with emollient cream (Purpose Dry Skin Cream, Johnson & Johnson Consumer Products, Inc.), mild soap (Johnson's Baby Bar, Johnson & Johnson Consumer Products, Inc.), and sunscreen (Sundown, SPF #15, Johnson & Johnson Products, Inc.). Patients were instructed to wash with the mild soap before applying the test articles and to use the emollient cream when needed for excessive skin irritation or dryness. Sunscreen was to be applied before extended periods of exposure to ultraviolet light. The use of cosmetics or any other topical drug or medicated products was discouraged. In addition, desonide 0.05% (Tridesilon, Miles Pharmaceuticals) cream was given to four patients who developed unacceptable irritation.

Efficacy parameters

Clinical signs of photodamaged skin were rated on a scale of 0 to 9 at baseline after 2 and 4 weeks, and then at monthly intervals until therapy was completed. Patients' faces and forearms were graded for roughness, fine and coarse wrinkling, laxity, mottled hyperpig-

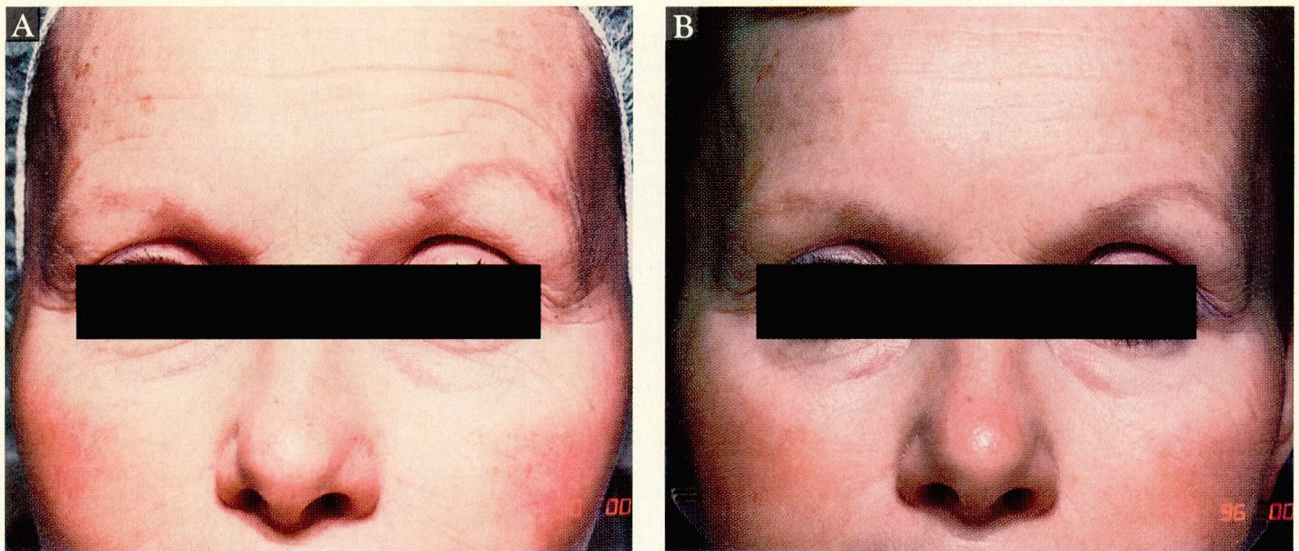


FIGURE 1. Face of patient at baseline (A) and after 6 months of treatment with tretinoin emollient cream (B). Note the increased smoothness and decreased fine wrinkling in the periorbital area and forehead after treatment.

mentation, yellowing, telangiectasia, and lentigines. The overall clinical severity of photodamage was also graded at each visit on a 0 to 9 scale (0, none; 1–3, mild; 4–6, moderate; 7–9, severe). At weeks 24 and 48, a global evaluation of clinical response was graded by the investigator and was rated as “much improved,” “improved,” “slightly improved,” “no change,” or “worse,” compared with baseline. All grading was carried out by the same investigator (J.M.A.) for all visits on every patient. Photographs were obtained at baseline and at 12, 24, 36, and 48 weeks; they were used only to document clinical changes and were not used for data collection or analysis. Patients completed self-assessment questionnaires at each study visit, and overall self-assessment ratings at weeks 24 and 48. Subjects rated themselves in terms of skin texture (roughness), tone (sallow color), color (brown spots), pore size, small wrinkles, tightness, and overall appearance and feel of their skin.

Punch biopsies were taken from the face (2 mm from the left periorbital area) and each forearm (3 mm from the dorsal surface) at admission and after 24 and 48 weeks of therapy. Histologic evaluation of various epidermal and dermal parameters included epidermal dysplasia, viable epidermal thickness, melanin distribution, elastosis, collagen, and dermal blood vessels. The investigator who evaluated the skin biopsy specimens was unaware of treatment assignment.

The incidence and severity of skin irritation (erythema, peeling, dryness, inflammation, itching,

burning, and stinging) and other adverse experiences were recorded at each visit. Information about concurrent therapies and treatment compliance was collected throughout the study.

Statistics

For the face, the exact chi-square test¹⁴ was used to analyze the possible association between the general category of each clinical characteristic and treatment group. An extension of McNemar's test¹⁵ was used to compare results for weeks 24 and 48 within each treatment group. McNemar's test was also used to compare improvement levels of the two forearm treatment groups. The *P* values are for two-sided tests; a *P* of .05 or less was considered statistically significant.

Improvement from baseline in clinical efficacy parameters and overall severity was categorized by means of the 0 to 9 scale: a decrease of one numerical unit was considered slightly improved; a decrease of two units was considered improved; and a decrease of three or more units was considered much improved.

RESULTS

Patient characteristics

Of 40 patients enrolled in the study, 34 (28 women, 6 men) were valid for analysis at week 24, and 32 (27 women, 5 men) were valid for analysis at week 48. Patients were evenly divided between active- and placebo-treatment groups for the face. Thirty patients

TABLE 2
CLINICAL IMPROVEMENT OF THE FOREARMS AFTER 24 AND 48 WEEKS OF TRETINOIN THERAPY

	24 weeks		48 weeks	
	Placebo n (%)	Active n (%)	Placebo n (%)	Active n (%)
Roughness*				
Much improved [†]	0 (0)	2 (6)	0 (0)	6 (19)
Improved [‡]	1 (3)	6 (18)	1 (3)	12 (38)
Slightly improved [§]	5 (15)	19 (56)	5 (16)	13 (41)
No improvement/worse	28 (82)	7 (20)	26 (81)	1 (3)
Mottled hyperpigmentation*				
Much improved	0 (0)	2 (6)	0 (0)	7 (22)
Improved	0 (0)	5 (15)	0 (0)	13 (41)
Slightly improved	2 (6)	16 (47)	2 (6)	9 (28)
No improvement/worse	32 (94)	11 (32)	30 (94)	3 (9)
Fine wrinkling*				
Much improved	0 (0)	0 (0)	0 (0)	4 (13)
Improved	0 (0)	3 (9)	0 (0)	18 (56)
Slightly improved	1 (3)	21 (62)	1 (3)	9 (28)
No improvement/worse	33 (97)	10 (29)	31 (97)	1 (3)
Lentigines*				
Much improved	0 (0)	0 (0)	0 (0)	2 (6)
Improved	0 (0)	3 (9)	0 (0)	12 (38)
Slightly improved	1 (3)	13 (38)	1 (3)	7 (22)
No improvement/worse	33 (97)	18 (53)	31 (97)	11 (34)
Overall change in severity				
Much improved	0 (0)	0 (0)	0 (0)	1 (30)
Improved	0 (0)	2 (6)	0 (0)	11 (34)
Slightly improved	0 (0)	18 (53)	0 (0)	14 (44)
No improvement/worse	34 (100)	14 (41)	32 (100)	6 (19)

*At both 24 and 48 weeks the active arm was more likely to be improved than the placebo arm ($P < .01$)

[†]Score decreased three units

[‡]Score decreased two units

[§]Score decreased one unit

^{||}Score did not decrease

consented to punch biopsies at baseline and after 24 and 48 weeks of therapy. Of the eight subjects who discontinued, two in the facial active-treatment group withdrew for personal reasons, two in the facial placebo group were withdrawn for protocol violations, one in the active-treatment group withdrew for an adverse event, and three (two in the placebo group and one in the active-treatment group) were lost to follow-up.

The ages of the participants ranged from 31 to 50, with a mean of 41. The ages were similar in both groups. Overall severity of photodamage on the face at baseline was moderate in 26 of 34 (76%) subjects in both groups and mild in all other subjects. Clinical characteristics at baseline did not differ significantly between the two treatment groups. Severity of each of the clinical signs at baseline was almost identical for both forearms, being either mild or moderate.

Efficacy for the face

After 24 weeks, 14 of 17 (82%) patients valid for analysis and treated with TEC 0.01% showed improvement in facial photoaging (3 much improved, 3 im-

proved, and 8 slightly improved), whereas only 3 of 17 (18%) treated with the placebo improved, based on the investigator's global evaluation (Table 1). In addition, the active-treatment group showed significantly reduced fine wrinkling (Figure 1, Table 1) and coarse wrinkling compared with the placebo group. Also, higher proportions of subjects treated with TEC 0.01% showed improvement in roughness (65% vs 41%), overall severity (47% vs 18%), mottled hyperpigmentation (41% vs 18%), and laxity (41% vs 12%) than did vehicle-treated subjects, although these differences were not statistically significant.

At 48 weeks, further global improvement was noted in patients in the active-treatment group: five

were much improved, five improved, and six slightly improved (Table 1). Patients who crossed over from placebo to active drug from weeks 24 to 48 were significantly more likely to be improved at week 48 than at week 24 ($P < .01$). After crossover, their improvement was similar to the improvement of those who were treated with active drug from the beginning.

The patient self-assessment questionnaires completed at week 24 noted some improvement in most areas. In general, this improvement did not differ between treatment groups, with the exception of small wrinkles, where the active-treatment group was significantly more likely to improve than the placebo group ($P = .01$). A higher proportion of subjects with active treatment also reported improvement in pore size (65% vs 35%), tone (41% vs 12%) and overall appearance (76% vs 47%), although these improvements were not statistically significant.

The time to first improvement was examined for those patients in the active-treatment group who improved on various clinical parameters. This time ranged from 4 to 24 weeks; 50% of these patients

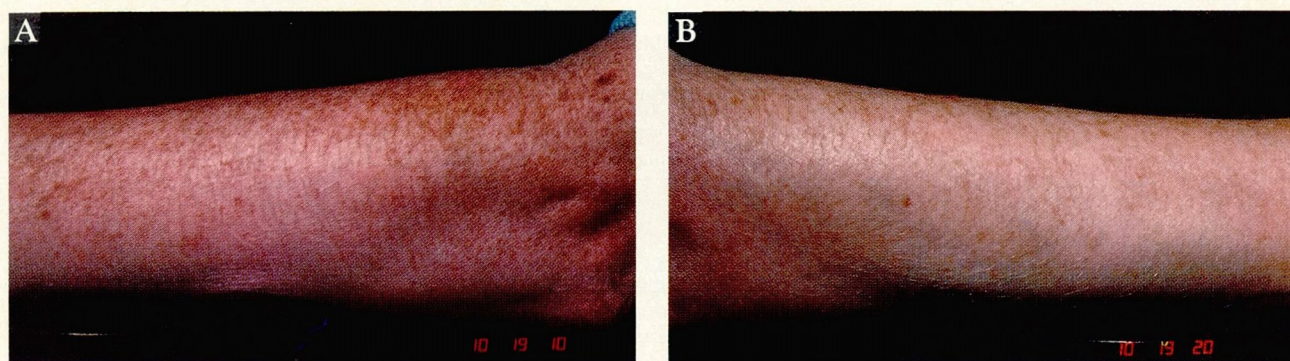

FIGURE 2. Placebo-treated left forearm (A) and tretinoin-treated right forearm (B) after 9 months of therapy with tretinoin emollient cream 0.01%. Note the difference in mottled hyperpigmentation and fine wrinkling.

showed improvement in overall severity by week 22. The earliest improvements were noted in roughness (median 12 weeks) and mottled hyperpigmentation (median 16 weeks).

Efficacy for the forearm

After 24 and 48 weeks, the TEC-treated arm evidenced significantly reduced roughness, mottled hyperpigmentation, fine wrinkling, lentigines, and yellowing (Table 2, Figure 2), compared with the placebo-treated arm. In addition, by week 48, 19 of 32 (59%) patients valid for analysis showed improvement in coarse wrinkling on the active-treatment arm, while none of the arms treated with placebo improved. In the overall rating, the arms treated with placebo did not improve at all, while in 20 of 34 (59%) cases valid for analysis at 24 weeks the TEC-treated arm showed some improvement (Table 2). At 48 weeks, further overall improvement from baseline was reached for the active-treatment arm with 26 of 32 (81%) patients showing some improvement (Table 2). As on the face, fine wrinkling was the parameter on the forearms at 48 weeks that was most likely to be improved.

In the investigator's global evaluation at weeks 24 and 48, the TEC-treated arm showed greater improvement of photodamaged skin than did the vehicle-treated arm (Table 3), with 31 of 32 (97%) showing improvement by week 48 (7 [22%] much improved, 16 [50%] improved, and 8 [25%] slightly improved).

Self-assessments at 24 and 48 weeks judged the TEC-treated arm to show significantly more improvement than the placebo-treated arm on all parameters, including the overall score ($P < .01$). Histologic analysis of the biopsies at 24 weeks showed no significant differences between the two groups.

Adverse experiences: facial treatment

No significant difference in the number of reported adverse experiences was found between subjects treated with TEC 0.01% on the face and those treated with vehicle for the first 24 weeks of the study. In that period, 14 of 17 (82%) subjects in the active-treatment group and 13 of 17 (76%) subjects in the placebo group reported one or more adverse events (erythema, dermatitis, dryness and peeling, periorbital swelling, or acne) of the facial skin and subcutaneous tissue system. The most common adverse experiences were dryness, peeling, and acne. Although in general there was no association between treatment group and side effects, the active-treatment group was significantly more likely to experience erythema than the placebo group (35.5% vs 0%, $P = .01$). Although not statistically significant, some evidence suggested that the active-treatment group was more likely to experience dryness (64.7% vs 35.3%, $P = .09$), and the placebo group was more likely to experience acne (52.9% vs 29.4%, $P = .19$).

The severity of most of these experiences was mild to moderate, with only a possible relationship to the drug. The time of onset of adverse experiences varied from week 1 to week 24 after initiation of therapy (median, 4.5 weeks) and lasted anywhere from 1 day to 24 weeks (median, 21 days). Usually no action was taken. The drug was temporarily discontinued for five experiences in the placebo group and 18 in the active-treatment group (median, 5 days).

Adverse experiences: forearm treatment

From week 1 through week 48, 27 of 34 patients (79%) in the active-treatment group experienced 53 side effects, while in the placebo group 16 of 34 (47%)

TABLE 3
INVESTIGATOR'S GLOBAL EVALUATION OF FOREARM IMPROVEMENT
AFTER 24 AND 48 WEEKS OF TRETINOIN THERAPY*

Week	Placebo arm	Active arm			
		Much [†] improved	Improved [‡]	Slightly [§] improved	No improvement/worse
24	Slightly improved	0	1	0	0
	No improvement/worse	4	11	14	4
48	Slightly improved	0	1	0	0
	No improvement/worse	7	15	8	1

*At both 24 and 48 weeks the active arm was more likely to be improved than the placebo arm ($P < .01$)

[†]Score decreased three units

[‡]Score decreased two units

[§]Score decreased one unit

^{||}Score did not decrease

experienced 25 side effects. Eleven patients had adverse experiences only on the forearm receiving active treatment, and 16 had adverse experiences on both the TEC-treated and vehicle-treated arms. The TEC-treated arm was significantly more likely to have adverse experiences than the placebo-treated arm ($P < .001$). The most common type of adverse effect was mild dermatitis. The median time of onset was 9 weeks for active treatment and 11 weeks for placebo treatment, and median duration was 28 days and 21 days, respectively. For both arms, the time of onset ranged from 1 week to 44 weeks, and duration ranged from 2 days to 210 days. For 37 adverse experiences in the active group and 22 experiences in the placebo group, one or more study applications were withheld because of irritation.

Topical steroids were not frequently used to alleviate skin irritation, which generally diminished after temporary reductions in application frequency or increased emollient use. Two patients in the active-treatment group and two in both placebo and active-treatment groups used desonide cream 0.05% for 14 days or less. Only one subject in the facial active-treatment group discontinued the study because of irritation on the face and both arms.

DISCUSSION

Our placebo-controlled study of treatment of the face with TEC 0.01% found significant improvement in the active-treatment group based on the investigator's global evaluation and on assessments of fine and coarse wrinkling. No significant difference was found in the degree of roughness or mottled hyperpigmentation; this is most likely the result of the moisturizing effect of the vehicle and the patients' general attention to skin care and avoidance of the sun.

More consistent improvement was found on the forearm than on the face; it may be that the forearms were easier to evaluate because they could be compared with each other, with one forearm serving as a control. By contrast, clinical evaluation of the face relied on memory and photographic comparison.

In the double-blind, vehicle-controlled study by Weiss et al,⁹ clinical and histologic improvement was observed in 100% of 0.1% tretinoin-treated forearms and 93% of tretinoin-treated faces; the most improved parameter was fine wrinkling.

In comparison, in our study, 88% of 0.01% TEC-treated forearms and 82% of TEC-treated faces improved overall by week 24, and 97% of TEC-treated forearms and 100% of TEC-treated faces improved overall by week 48. In addition, during the study of Weiss et al,⁹ more than 90% of the patients experienced some degree of dermatitis in the tretinoin-treated areas, with 11 out of 30 (37%) patients being offered use of a potent topical steroid to mitigate the inflammation. In our study, as in that of Weinstein et al,¹³ irritation was less prevalent with the lower concentration of tretinoin.

In humans, the response of extrinsic aging to topical tretinoin appears to be dose-dependent.^{10,13,16} Weiss et al⁹ noted improvement starting as early as 2 weeks; approximately 50% of their patients improved by 4 weeks, and most patients improved by 12 weeks. Further improvement was seen as therapy continued.^{10,16} Kligman^{3,6,7} also found that the subepidermal repair zone in hairless mice was significantly wider after treatment with tretinoin after 10 weeks compared with 5 weeks. In our study, 50% of tretinoin-treated faces improved by 22 weeks, indicating a slower therapeutic response to TEC 0.01%. Studies with hairless mice also confirmed the dose-dependent nature of tretinoin-induced repair, with the increased width of the reconstruction zone being proportional to the concentration of tretinoin.^{6,7} In support of this finding, the lower concentration of tretinoin used in our study produced somewhat less effective results than the dramatic clinical responses previously reported with 0.1% tretinoin cream,⁹ but our results are consistent with the more recent dose-dependent tretinoin effects

by Weinstein et al,¹³ in which two doses were compared in a single-study design.

In our study, no significant difference was found between the active group and placebo group in the number of subjects who reported cutaneous adverse events on the face, the most common being dryness and peeling and acne. However, a higher incidence of erythema was reported in the TEC 0.01% group than in the vehicle group. The signs and symptoms were most often mild, and the occurrence decreased before the end of therapy without specific treatment. Nine of 17 (53%) patients in the placebo group and 5 of 17 (29%) patients in the active group experienced acne. Therefore, the emollient cream vehicle or perhaps the sunscreen used may be comedogenic.

On the forearms, the TEC-treated arm was significantly more likely to have an adverse experience than the placebo-treated arm, although 16 of 34 patients experienced dermatitis on both arms. The dermatitis seen in both active and placebo-treatment groups may have been due to an irritating component of the emollient cream base itself rather than the active drug, or it may be the result of inadvertent cross-contamination by tretinoin applied to the other arm.

The fact that patients experienced irritation on placebo-treated arms but had no clinical improvement further supports the notion that irritation is not central to the pharmacologic action of tretinoin. Changes were also detected in patients who had no irritation. In fact, just as Leyden et al¹¹ observed in their study, we found that some patients who showed the most im-

provement experienced little or no irritation at all. Ellis et al¹⁷ found no clinical or histologic evidence to support a role for tretinoin-induced irritation or edema as the cause of decreased wrinkling. More recently, a histologic study by Bhawan et al¹⁸ comparing three concentrations of tretinoin (0.05%, 0.01%, and 0.001%) found no correlation between clinical improvement and histologic inflammation. Animal studies have also failed to show enhanced repair of ultraviolet radiation damage using nonspecific irritating compounds; therefore, the observed beneficial effects appear to be tretinoin-specific.^{3,7}

CONCLUSION

Our findings confirm the positive findings of earlier investigations. TEC 0.01% is potentially a safe, effective topical treatment for retarding and reversing clinical changes associated with chronic exposure to ultraviolet light. In our study, the TEC 0.01% formulation had a low-to-moderate potential for skin irritation and was generally well tolerated. The 0.01% concentration may represent the lower threshold at which we can expect to see clinical results with topical tretinoin in photodamaged skin.

ACKNOWLEDGMENT

This research project was supported in part by Ortho Pharmaceutical Corporation, Raritan, NJ.

We thank Linda Langford for her assistance and Flora Williams for medical photography.

REFERENCES

- Gilchrist BA. Skin and aging processes. Boca Raton, FL: CRC Press, Inc, 1984:97-98.
- Gilchrist BA. Aging of skin. In: Fitzpatrick TB, Eisen AZ, Wolff K, editors. Dermatology in general medicine. 3rd ed. New York: McGraw-Hill, 1987:146-151.
- Kligman LH. Photoaging: manifestations, prevention and treatment. *Dermatol Clin* 1986; 4:517-528.
- Kligman LH, Akin FJ, Kligman AM. Prevention of ultraviolet damage to the dermis of hairless mice by sunscreens. *J Invest Dermatol* 1982; 78:181-189.
- Kligman LH, Akin FJ, Kligman AM. Sunscreens promote repair of ultraviolet radiation-induced dermal damage. *J Invest Dermatol* 1983; 81:98-102.
- Kligman LH, Duo CH, Kligman AM. Topical retinoic acid enhances the repair of ultraviolet damaged dermal connective tissue. *Connect Tissue Res* 1984; 12:139-150.
- Kligman LH. Effect of all-trans retinoic acid on the dermis of hairless mice. *J Am Acad Dermatol* 1986; 15:779-785.
- Kligman AM, Grove GL, Hirose R, Leyden J. Topical tretinoin for photoaged skin. *J Am Acad Dermatol* 1986; 15(4):836-859.
- Weiss JS, Ellis CN, Headington JT, Tincoff T, Hamilton TA, Voorhees JJ. Topical tretinoin improves photoaged skin: a double-blind vehicle-controlled study. *JAMA* 1988; 259:527-532.
- Weiss JS, Ellis CN, Headington JT, Voorhees JJ. Topical tretinoin in the treatment of aging skin. *J Am Acad Dermatol* 1988; 19:169-175.
- Ellis CN, Weiss JS, Hamilton TA, Headington JT, Zelickson AS, Voorhees JJ. Sustained improvement with prolonged topical tretinoin (retinoic acid) for photoaged skin. *J Am Acad Dermatol* 1990; 23:629-637.
- Leyden JJ, Grove GL, Grove MJ, Thorne EG, Lufano L. Treatment of photodamaged facial skin with topical tretinoin. *J Am Acad Dermatol* 1989; 21:638-644.
- Weinstein GD, Nigra TP, Pochi PE, et al. Topical tretinoin for treatment of photodamaged skin. *Arch Dermatol* 1991; 127:659-665.
- Agresti A, Waekerly P, Boyett J. Exact conditional tests for cross-classifications: approximation of attained significance levels. *Psychometrika* 1979; 44:75-83.
- Bowker AH. A test for symmetry in contingency tables. *J Am Stat Assoc* 1978; 43:572-574.
- Goldfarb MT, Ellis CN, Weiss JS, Voorhees JJ. Topical tretinoin and photoaged skin. *Cutis* 1989; 43:476-482.
- Ellis CN, Weiss JS, Hamilton TA, Headington JT, Voorhees JT. Topical tretinoin for photoaged skin [reply]. *JAMA* 1988; 259:3274.
- Bhawan J, Gonzales-Serva A, Nehal K, et al. Effects of tretinoin on photodamaged skin. *Arch Dermatol* 1991; 127:666-672.