



DAVID L. LONGWORTH, MD, AND JAMES K. STOLLER, MD, EDITORS

A pregnant woman with shortness of breath

A 36-YEAR-OLD BLACK WOMAN in her 34th week of pregnancy presented to the department of maternal and fetal medicine complaining of shortness of breath. For the past 2 days she had experienced chest discomfort, lightheadedness, and significant shortness of breath. She has hypertension, for which she takes methyldopa 500 mg three times a day; this controls her blood pressure well. Her pregnancy has otherwise been uncomplicated. Her family medical history is unremarkable. She has no allergies, reported no recent toxin exposure, and does not smoke or use alcohol.

Physical examination revealed mild respiratory distress. The patient was afebrile, and her blood pressure was 140/50 mm Hg in the right arm, measured with a standard adult-size cuff. Her heart rate was 100 beats per minute, and the rhythm was regular. She had neck vein distension, a few crackles in the bases of her lungs, and normal heart sounds with a soft, high-pitched, blowing diastolic murmur heard best along the left sternal border. Her point of maximal impulse seemed to be displaced laterally according to the examiner. She had a third heart sound in the left lateral decubitus position. There was a trace of peripheral edema.

Q1 The differential diagnosis of this patient includes all of the following *except*:

- ☐ Pulmonary embolism
- ☐ Amniotic fluid embolism
- ☐ Aortic insufficiency
- ☐ Endocarditis
- ☐ Aortic dissection

A1 This woman has had chest pain and shortness of breath for 2 days. The differential diagnosis would have to include pulmonary embolism to account for her symptoms. The diastolic blowing murmur suggests aortic valvular or aortic root disease from any number of causes. Amniotic fluid embolism is implicated in cardiovascular collapse during vaginal delivery and would not be a correct answer in this clinical setting.

Q2 The *best* test to further evaluate this patient would be:

- ☐ Chest roentgenography with decubitus films
- ☐ Electrocardiography
- ☐ Echocardiography
- ☐ Fetal ultrasonography to assess viability
- ☐ Arterial blood gas measurement

A2 This patient needs to be evaluated quickly and efficiently with limited risk to the fetus. Given her history of hypertension and the murmur auscultated on physical examination, the *best* test to order would be echocardiography, which would give the most information to continue evaluating this patient. Electrocardiography would not add much; the chances of an acute myocardial infarction are remote in this setting, and any other changes would be characterized as nondiagnostic. Chest roentgenography may be of value, but in the pregnant patient it would not be the best choice. Arterial blood gas measurement would show respiratory alkalosis, which is common in the latter stages of pregnancy, but would otherwise be nonspecific. Fetal Doppler echocardiographic studies of the heart are not indi-

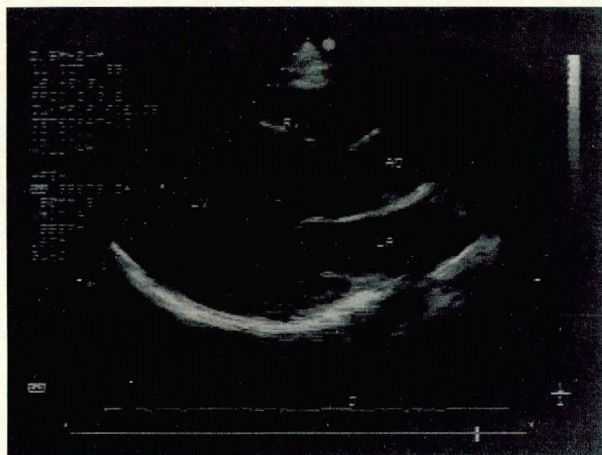


FIGURE 1

cated to evaluate the patient further, although fetal viability is always an issue in a seriously ill gravid woman.

The patient was evaluated with echocardiography. Figure 1 shows the patient's echocardiogram from the left parasternal view with the cardiac chambers labeled. Figure 2 shows the same view with color-flow Doppler added.

Q3 The echocardiograms shown are most consistent with the following diagnosis:

- ☐ Mitral insufficiency
- ☐ Aortic stenosis
- ☐ Large ventricular septal defect
- ☐ Aortic insufficiency
- ☐ Congenital atrial septal defect

A3 The echocardiograms reveal that there is a mild increase in the left ventricular dimensions, but most revealing is the color-flow Doppler study. With the transducer on the chest wall, flow that is directed towards the transducer appears red or orange in color, and flow that is away from the transducer or chest wall will appear to have a blue or greenish hue. This flow is clearly directed away from the transducer and goes from the aorta into the left ventricle. This is most suggestive of aortic insufficiency.

Because of the patient's chest pain and her newly discovered aortic insufficiency, the concern was raised as to whether the aortic valvular disease was caused by aortic dissection.

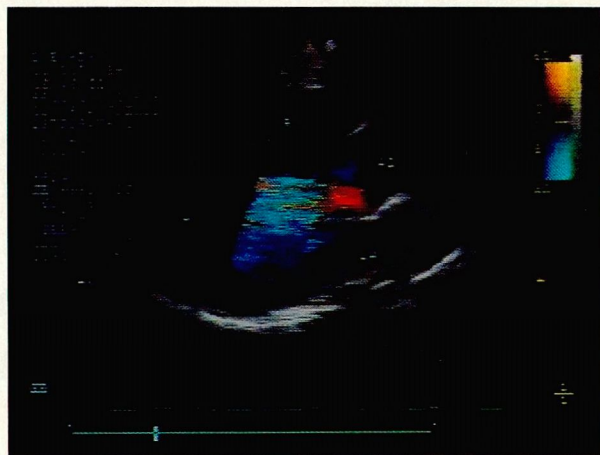


FIGURE 2

Q4 The best test to evaluate aortic integrity in this patient would be:

- ☐ Computed tomography
- ☐ Aortography
- ☐ Magnetic resonance scanning
- ☐ Transesophageal echocardiography
- ☐ Cine-computed tomography

A4 Given that the patient is pregnant, the least invasive test with the highest diagnostic yield should be used. The patient has aortic valvular disease, and the question is whether there is a type I or II DeBakey or a type A Stanford dissection that involves the ascending aorta. This information can be obtained with a very high yield and a low risk to both mother and fetus via transesophageal echocardiography. This procedure can be done at the bedside with the patient in the left lateral decubitus position, which is hemodynamically very stable for the fetus.

The patient was evaluated with transesophageal echocardiography and was shown to have a type II aortic dissection with evidence of aortic insufficiency and pericardial effusion, but no evidence of cardiac tamponade. She was seen in consultation by the cardiothoracic surgeon and the neonatologist. The fetus was found to be viable, and the patient's medical condition was stabilized. The following day the fetus was delivered via cesarean section, and the patient underwent immediate operative repair of her aortic dissection. The mother and infant had an uneventful recovery and were discharged to home.

Discussion

The diagnosis of cardiovascular disease in pregnancy can be challenging. Easy fatigability, chest discomfort, dyspnea, and palpitations are frequent complaints in pregnant women. Maternal hormones mediate circulatory changes that increase blood volume, total body water, cardiac output, and pulse pressure. Consequently, normal physical findings can include peripheral edema, neck vein distention, summation gallops, and systolic murmurs. A venous hum with a diastolic component and a mammary souffle are also normal findings as pregnancy advances. However, certain complaints mandate further investigation in a pregnant patient. Dyspnea that limits normal activities, hypertension, exertional syncope, true orthopnea, and paroxysmal nocturnal dyspnea are all abnormal, as are most diastolic murmurs.

The differential diagnosis of acute aortic insufficiency is limited. It includes trauma, rheumatic fever, bacterial endocarditis, and aortic dissection. The patient described has no history of trauma and has nothing in her clinical presentation to suggest acute rheumatic fever or bacterial endocarditis. The most likely cause of her acute aortic insufficiency is, therefore, aortic dissection.

Although aortic dissection is uncommon in women under age 40, when it does occur, more than 50% of the time it is related to pregnancy. The exact cause of pregnancy-related aortic dissection is unknown. Most dissections and aortic ruptures occur during the third trimester, when pregnancy-mediated hemodynamic stresses are at their maximum. Serial echocardiograms during gestation demonstrate progressive increases in aortic size and compliance. Whether this increased compliance weakens the wall and predisposes to dissection in the latter part of pregnancy is unknown. Alterations in sex hormones, primarily estradiol, may alter the biosynthesis of collagen in the smooth muscle cells of the aorta. This change in the hormonal milieu, coupled with the increased hemodynamic stresses of pregnancy, has been proposed as a mechanism for aortic disruption.

Pregnancy-related aortic dissection is more common in women of advanced age or parity, as well as in pregnancies complicated by hypertension or Marfan's syndrome. Dissection is most likely to occur during the third trimester (51%) but can occur dur-

ing labor and delivery (14%) or in the puerperium (20%). Some involvement of the ascending aorta is reported in the vast majority of cases. Women with Marfan's syndrome are already at increased risk of aortic dissection, but the risk is even greater during pregnancy. Marfan's syndrome, an autosomal-dominant connective tissue disease involving cystic medial necrosis, predisposes to aortic dilatation and eventual dissection. Women with Marfan's syndrome need to be aware of the risks of pregnancy to themselves and the genetic risks to the fetus.

Serial echocardiography has been very useful in monitoring aortic root dimensions. Some authors recommend terminating the pregnancy if progressive aortic dilatation occurs in the first or second trimester, then surgically repairing the aorta immediately afterward. In the third trimester, fetal viability becomes an important issue in patients with Marfan's syndrome, as well as in other women with aortic dissection. A team approach involving the cardiologist, cardiovascular surgeon, obstetrician, and neonatologist is pivotal for a safe delivery. If the mother's medical condition can be stabilized and if fetal viability can be assured, optimal therapy involves delivery via cesarean section, followed immediately by surgical repair of the aorta.

Although most of the reported series involve small numbers of patients, it is safe to conclude that, for the mother, the survival rate following surgery is over 85%. If the fetus is of viable age to be delivered, its chance of survival is also quite high. Fetal viability, ie, ability to live outside the womb, is virtually the only issue regarding the surgery. Several cases have been reported of nonviable fetuses withstanding operative repair of an aortic dissection in the mother with delivery 1 to 2 months later, but this is rare.

Therapy of pregnancy-related aortic dissection requires prompt diagnosis of the extent and location of the dissection. Options include aortography, computed tomography, magnetic resonance imaging, and transesophageal echocardiography. Institutional availability, operator expertise, diagnostic accuracy, and the risk-benefit ratio for the mother and fetus all play a role in selecting the best diagnostic method.

Concurrent with diagnostic evaluation, medical stabilization is essential. Control of associated hy-

pertension (present in over 80% of patients with dissection) can arrest further propagation and prevent rupture. Although animal data suggest that nitroprusside can cross the placenta, it is widely used in the treatment of aortic dissection along with intravenous beta blockade. The agent chosen for treatment should be readily titratable with a relatively short half-life. Maintaining the mean arterial pressure at approximately 75 mm Hg is recommended.

Although data on the effects of modern cardiopulmonary bypass on the fetus are limited, a high fetal mortality rate has been suggested. Whenever possible, delivery should be accomplished first via cesarean section to limit the hemodynamic load on the mother, and aortic repair should be performed immediately after abdominal closure.

JANIS A. ROBERTS, DO
ANITA M. ARNOLD, DO
Milwaukee, Wis

SUGGESTED READING

Barrett JM, Van Hooydonk JE, Bohem FH. Pregnancy related rupture of arterial aneurysms. *Obstet Gynecol Surg* 1982; 37:557-566.

Becker RM. Intracardiac surgery in pregnant women. *Ann Thorac Surg* 1983; 36:453-458.

Gigarroa JE, Isselbacher EM, De Sanctis RW, Eagle KA. Diagnostic imaging in the evaluation of suspected aortic dissection. *N Engl J Med* 1993; 238:35-43.

Mandel W, Evans EW, Walford RL. Dissecting aneurysm during pregnancy. *N Engl J Med* 1954; 251:1059-1061.

Pledowitz P, Parrell A. Aneurysm complicated by pregnancy. *Am J Obstet Gynecol* 1957; 73:720-735.

Williams GM, Gott VL, Brawley RK, Schauble JF, Labs JD. Aortic dissection associated with pregnancy. *J Vasc Surg* 1988; 8:470-475.

THE CLEVELAND CLINIC
FOUNDATION



presents

HEADACHES IN ADULTS AND CHILDREN

May 17-18, 1994

Bunts Auditorium
The Cleveland Clinic Foundation
Cleveland, Ohio

ABOUT THE SYMPOSIUM

This is a comprehensive two-day course on the pathophysiology and management of common headache problems seen in adults and children. Material presented will be of value to all physicians who see patients with headache complaints, including family practitioners, internists, neurologists, and dentists. Lectures, workshops, and case discussions with active participation will challenge participants.

FOR FURTHER INFORMATION,
PLEASE CONTACT:

The Cleveland Clinic Educational Foundation
Department of Continuing Education, TT-31
9500 Euclid Ave.
Cleveland, Ohio 44195
216-444-5696 (local) 800-762-8173 (toll-free)
216-445-9406 (fax)