

Congestive heart failure due to a pancreatic pseudocyst

FRANCIS Y.W. LEE, MD; YEE-TANG WANG, MD; SOO-CHUAN POH, MD

■ **BACKGROUND** Mediastinal extension of pancreatic pseudocysts has caused rare cases of cardiac compression, but to our knowledge, congestive heart disease due to cardiac compression by a pancreatic pseudocyst has never been reported.

■ **SUMMARY** A 48-year-old man presented with dyspnea, swelling of both lower limbs, left-sided chest pain, and colicky, nonradiating epigastric pain. Computed tomography of the abdomen and lower thorax revealed a huge cystic mass directly behind the heart, extending through the esophageal hiatus into the abdomen. The patient subsequently noted dysphagia and epigastric pain and began vomiting after meals. Radiography of the upper gastrointestinal system with barium contrast confirmed that the lower end of the esophagus and the right and lower portions of the stomach were extrinsically compressed. Complete recovery followed surgical removal and internal drainage of a large pancreatic pseudocyst.

■ **CONCLUSIONS** Mediastinal extension of a pancreatic pseudocyst can cause cardiac compression, leading to congestive heart failure.

■ **INDEX TERMS:** PANCREATIC PSEUDOCYST; MEDIASTINAL CYST; HEART FAILURE, CONGESTIVE ■ CLEVE CLIN J MED 1994; 61:141-143

From the Department of Respiratory Medicine, Tan Tock Seng Hospital, Republic of Singapore.

Address reprint requests to F.Y.W.L., Department of Respiratory Medicine, Tan Tock Seng Hospital, Moulmein Road, Republic of Singapore (SE1130).

PSEUDOCYST, a well-recognized complication of pancreatitis, consists of a chronic accumulation of fluid caused by the action of proteolytic enzymes. Pseudocysts may occur either inside or outside the pancreas, but the most common locations are the lesser sac or omental bursa and the anterior pararenal area. Mediastinal extension of a pancreatic pseudocyst is rare: to our knowledge, only 35 cases have been reported since 1951 in English-language journals.¹ Siegelman² reported only one such case in a series of 32 pseudocysts documented by computed tomography (CT). Patients with mediastinal pseudocysts have presented with symptoms of pain in the abdomen, chest, or back, dyspnea, vomiting, and dysphagia.³ Lipson⁴ presented a case of cardiac tamponade secondary to pericardial effusion attributed to subacute pancreatitis. The following case is unusual in its presentation as congestive cardiac failure unrelated to pericardial effusion.

CASE HISTORY

A 48-year-old man presented in June 1989 with dyspnea, swelling of

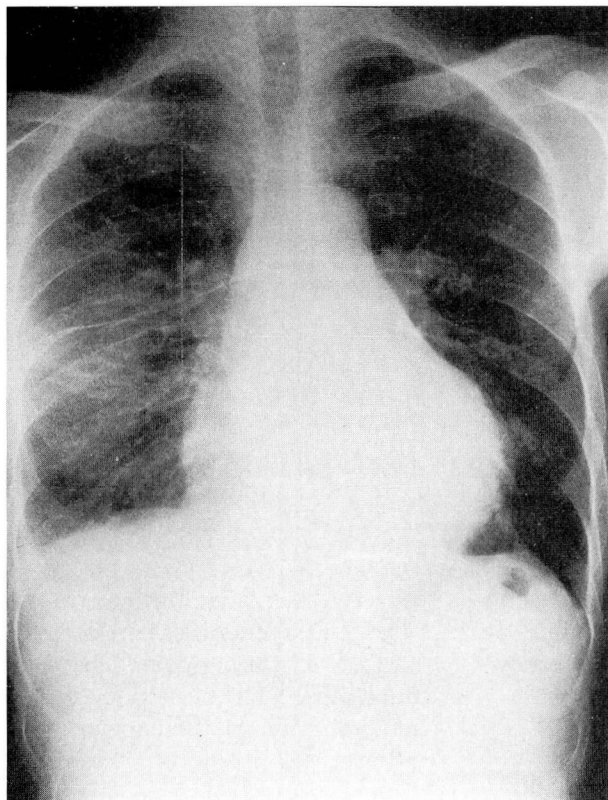


FIGURE 1. Chest roentgenogram on admission, showing cardiomegaly, a small right pleural effusion, and a large rounded opacity behind the left cardiac border.

both lower limbs, left-sided chest pain, and colicky, nonradiating epigastric pain; the symptoms had begun 2 days previously after a drinking binge. He had a history of alcohol abuse but had no previous pancreatitis, pseudocyst formation, or heart disease. On clinical examination, the patient was distressed and breathless. He had marked pitting edema of both legs, distended neck veins, fine crepitations and rhonchi in both lung fields, and signs of a right pleural effusion. Sinus tachycardia, a third heart sound, and a grade 2 systolic ejection murmur over the lower left sternal edge were noted. The blood pressure was 110/60 mm Hg. The epigastrium was tender and tense; however, no definite mass was palpable. Bowel sounds were sluggish. A roentgenogram of the chest revealed cardiomegaly with a small right pleural effusion, and there was a suspicion of a large rounded opacity behind the left cardiac border (Figure 1). The electrocardiogram did not show any ischemic changes. The patient's signs and symptoms resolved with standard therapy for heart failure.

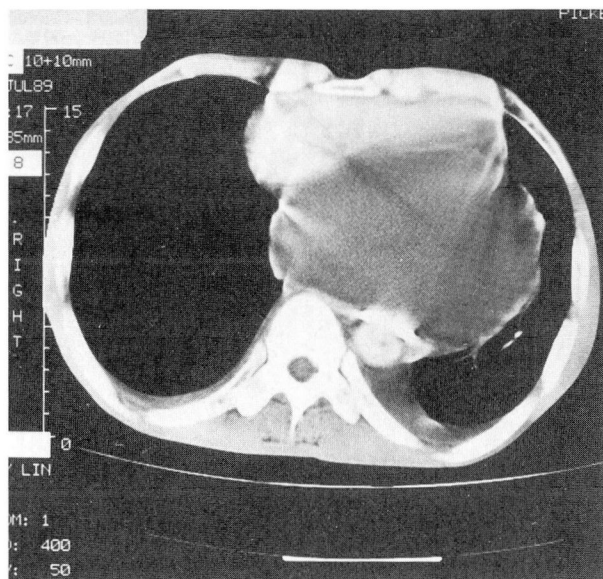


FIGURE 2. Computed tomographic scan of the lower thorax. A posterior mediastinal pancreatic pseudocyst compresses the heart.

Cardiac enzyme levels and results of liver function tests and a complete blood count were normal. On admission, the serum amylase level was 624 U/L and the urinary diastase level was 3250 U/L. These enzymes returned to normal levels within the next few days. A pleural tap revealed a lymphocyte-rich exudate. An abdominal roentgenogram showed a relatively gasless upper abdomen and no pancreatic calcifications.

Two-dimensional echocardiography revealed a small heart compressed by a posterior loculated cyst that extended into the abdomen between the two lobes of the liver. Good myocardial contractility was noted.

Computed tomography of the abdomen and lower thorax (Figure 2) revealed a huge cystic mass directly behind the heart, extending through the esophageal hiatus into the abdomen between the left and right lobes of the liver. Bilateral pleural effusions were also noted.

The patient subsequently complained of dysphagia and epigastric pain and began vomiting after meals. Radiography of the esophagus and stomach with barium contrast revealed smooth narrowing of the cardioesophageal junction with holdup of contrast. The lower end of the esophagus and right and lower portions of the stomach were extrinsically compressed.

Exploratory surgery revealed a cyst arising from the superior aspect of the pancreas extending upwards, stretching the left cupola of the diaphragm. It also extended into the thorax through the esophageal hiatus, pushing the heart anteriorly and compressing it against the chest wall. The abdominal portion of the pseudocyst extended as far as the true pelvis. The mediastinal portion of the cyst was excised and the remainder drained via a Roux-en-Y cystojejunostomy. The pancreas was hard and nodular. Histologic study of the cyst wall revealed a fibrous layer with no epithelial lining. Mild chronic inflammation was present. The patient's postoperative recovery was uneventful.

DISCUSSION

Retrocardiac compression by a mediastinal pancreatic pseudocyst was first reported in 1980 by Shah and Schwartz, who used echocardiography to diagnose the condition.⁵ Although their patient was orthopneic and had sinus tachycardia, clinical features of congestive cardiac failure were not described. Pericardial effusion associated with pancreatitis was first described by Mitchell⁶ in 1964.

REFERENCES

1. Edlin P. Mediastinal pseudocyst of the pancreas. *Gastroenterology* 1951; 17:96-102.
2. Siegelman SS, Copeland BE, Saba GP, Cameron JL, Sanders RC, Zerhouni EA. CT of fluid collections associated with pancreatitis. *Am J Roentgenol* 1980; 134:1121-1132.
3. Kirchner SD, Richard MH, Clyde WS. Pancreatic pseudocyst of the mediastinum. *Diagnostic Radiology* 1977; 123:37-42.
4. Lipson JD, Stephenson HE Jr. Pancreatitis complicated by pericardial effusion and cardiac tamponade. *Arch Surg* 1971; 103:414-416.
5. Shah A, Schwartz H. Echocardiographic features of cardiac

Lipson and Stephenson⁴ were the first to describe a case of pericardial effusion and cardiac tamponade complicating subacute pancreatitis; Strimlan and Turbinder⁷ described the second case in 1982.

After reviewing the literature published in English, we believe that a mediastinal pancreatic pseudocyst presenting as congestive cardiac failure from retrocardiac compression has not been previously described. It was interesting to note that our patient's complaint of dysphagia was also uncommon. Kirchner³ reviewed a series of 16 patients with mediastinal pseudocysts in 1977; only three of them complained of dysphagia. Since then, Siegelman,² Edell,⁸ Owens,⁹ and Ball¹⁰ have also described patients with dysphagia, bringing the number to seven. Evidence on upper gastrointestinal radiographic series in these patients^{3,8-10} may, however, show a higher subclinical incidence of esophageal and stomach compression.

ACKNOWLEDGMENT

The authors are grateful to Dr. Atul C. Mehta, Head, Section of Bronchology, Department of Pulmonary Disease, The Cleveland Clinic Foundation, for his invaluable assistance and advice in reviewing the manuscript.

- compression by mediastinal pancreatic pseudocyst. *Chest* 1980; 77(3):440-443.
6. Mitchell CE. Relapsing pancreatitis with recurrent pericardial and pleural effusions. *Ann Intern Med* 1964; 60:1047-1053.
7. Strimlan CV, Turbinder EH. Pleuropericardial effusions associated with chest and abdominal pain. *Chest* 1982; 81:493-494.
8. Edell SL, Good LI. Mediastinal pancreatic pseudocyst. *Am J Gastroenterol* 1979; 71:78-82.
9. Owens GR, Arger PH, Mulhern CB Jr, Coleman BG, Gohel V. CT evaluation of mediastinal pseudocyst. *J Comput Assist Tomogr* 1980; 4:256-259.
10. Ball JB, Clark RA. CT of mediastinal pancreatic fluid collections. *Comput Radiol* 1982; 6:295-300.