

CAROL A. LANGFORD, MD, MHS

Senior investigator, Laboratory of Immunoregulation,
National Institute of Allergy and Infectious Diseases,
National Institutes of Health, Bethesda, MD.

The diagnostic utility of c-ANCA in Wegener's granulomatosis

WEGENER'S GRANULOMATOSIS is an uncommon disease characterized by granulomas, necrosis, and systemic vasculitis. Although it has a predilection to involve the upper airway, lungs, and kidneys, it can be a difficult disease to identify, as these clinical features may not all be present at the time of disease onset.

The establishment of a correct and timely diagnosis is essential, as there exists the potential for morbidity and mortality from the disease, the treatment, or both.

Historically, the diagnosis of Wegener's granulomatosis has been based on the presence of characteristic histologic findings in a compatible clinical setting. Unfortunately, not all tissue samples are diagnostic and biopsies can be associated with discomfort and risks. These realities have left clinicians searching for less invasive, less costly, and more definitive diagnostic tests for Wegener's granulomatosis.

In 1982, a novel antibody was described which stained the cytoplasm of neutrophils.¹ Since then, indirect immunofluorescence has identified two main staining patterns of these antineutrophil cytoplasmic antibodies (ANCA): a cytoplasmic pattern (c-ANCA) and a perinuclear pattern (p-ANCA). After investigation into their disease associations, c-ANCA has been found to be highly associated with Wegener's granulomatosis.²⁻⁴

Because of this association, the question has been raised: Can c-ANCA be used as a diagnostic test for Wegener's granulomatosis, *in place of* histologic examination?

In this article, I argue that while a positive c-ANCA test may suggest the presence of Wegener's granulomatosis, in most cases it should not be used in place of a biopsy to diagnose this disease.

■ ABSTRACT

Anti-neutrophil cytoplasmic antibodies with a cytoplasmic staining pattern (c-ANCA) have been found to have a high degree of sensitivity and specificity for Wegener's granulomatosis. Nevertheless, despite the attraction of using this autoantibody as a diagnostic test, in almost all instances it should not be used in place of a biopsy to diagnose Wegener's granulomatosis.

■ KEY POINTS

Wegener's granulomatosis has a low pretest probability in most clinical situations, as it is an uncommon disease in which, quite often, not all features are present at the time of disease onset.

The presence of histologic abnormalities along with the characteristic clinical findings is the standard means of diagnosing Wegener's granulomatosis. However, a biopsy is not always diagnostic, and samples must be carefully examined for infection or other diseases with a similar pathologic appearance.

The diagnosis of Wegener's granulomatosis must be firmly established, as therapy is extremely toxic.

The posttest probability of disease is too low in most clinical situations to justify the use of c-ANCA alone as a means of diagnosing Wegener's granulomatosis.

The reasons for this are addressed by reviewing some key points about Wegener's granulomatosis, ANCA, and the parameters used to assess the utility of a diagnostic tool.

■ THE CLINICAL PICTURE

Wegener's granulomatosis is uncommon, affecting about 3 in 100,000 persons. It is a multisystem disease but most frequently affects the upper airways, lungs, and kidneys.⁵ Although signs and symptoms of upper respiratory, pulmonary, and renal involvement usually surface at some point during the course of the disease, they may not all be present at the onset. In particular, glomerulonephritis, which occurs in about 80% of patients during the disease course, is present in only about 20% of patients at initial presentation.⁵

The broad differential diagnosis

The differential diagnosis of Wegener's granulomatosis is based on the spectrum of symptoms and signs of organ involvement. The presence of glomerulonephritis helps narrow the differential diagnosis,⁶ but as noted above, it is uncommon at the time of presentation. Most patients first seek medical attention for symptoms related to the upper airways, lower airways, or both. In such cases, the differential diagnosis can be very broad, encompassing infections and neoplasms.⁷

Treatment is effective but highly toxic

Before treatment was available, patients with Wegener's granulomatosis had an extremely poor prognosis, with a mean survival of 5 months and a 2-year mortality rate of 93%.⁸ The introduction of therapy with glucocorticoids and cyclophosphamide was a significant advancement, which brought about marked improvement in 91% of patients and complete remission in 75% of patients.⁵

Despite its success, this regimen is highly toxic. Side effects include bone marrow suppression, bladder injury, sterility, and the induction of leukemia, lymphoma, and transitional cell carcinoma of the bladder.^{5,9} Furthermore, as this regimen is immunosuppressive, administering it to a patient with an underlying infection could be life-threatening. For this reason, it is critical not only to estab-

lish the diagnosis of Wegener's granulomatosis, but also to rule out infection before initiating therapy.

■ ROLE OF BIOPSY IN THE DIAGNOSIS

Pathologic abnormalities in a clinically compatible setting are the standard means of diagnosing Wegener's granulomatosis. Biopsy sampling, in addition to supporting the diagnosis of Wegener's granulomatosis, serves to rule out other diseases. Infection, in particular, may resemble Wegener's granulomatosis clinically and histologically and so should be sought out by performing special stains and cultures on all biopsy tissue.

Vasculitis, necrosis, and granulomas are the cardinal histologic characteristics of Wegener's granulomatosis.⁵ Unfortunately, these features are often patchy in distribution, so not all biopsies are diagnostic. The likelihood of obtaining a positive finding is influenced by the site chosen for sampling and the amount of tissue obtained.⁵

Upper airway biopsies are attractive as they are a less invasive option, but they demonstrate the combination of vasculitis and granulomas in only 21% of cases; and necrosis, vasculitis, and granulomas are seen in only 16% of samples.¹⁰ The yield varies according to location: diagnostically useful biopsies are most commonly obtained from the paranasal sinuses (55%), nasal mucosa (20%), and larynx (18%).

Renal biopsies rarely demonstrate either granulomas or vasculitis outside of the glomerulus. However, they can rule out other causes of renal disease and confirm the glomerular lesion of Wegener's granulomatosis, which is typically a segmental, necrotizing, pauci-immune glomerulonephritis.^{5,11-13}

Open lung biopsy sampling of the pulmonary parenchyma has the highest positive yield: granulomas and vasculitis or vasculitis, necrosis, and granulomas are found in 91% of specimens.¹⁴ Transbronchial biopsy of lung tissue has a disappointingly low yield, with diagnostic findings present in only 7% of specimens.⁵

The decision about where to perform the biopsy is based on multiple individual factors, including the severity of the patient's illness, the organs affected, and concurrent medical

Most seek medical attention for upper and lower airway symptoms



factors. For example, in a hospitalized patient who has significant pulmonary disease, open-lung biopsy should be considered preferentially even in the setting of upper airway involvement, as it has a higher likelihood of determining the diagnosis and may expedite appropriate treatment. In contrast, biopsy of an upper airway lesion may be considered first in a stable outpatient with upper and lower airway disease, as it is less invasive and may demonstrate the necessary histological changes.

■ AN OVERVIEW OF ANCA

Methods of testing

Indirect immunofluorescence of ethanol-fixed human granulocytes is the most common method used to detect ANCA. More recently, solid-phase immunoassay—in which the target antigen itself is the substrate—has been used. The major antigen corresponding to c-ANCA is proteinase-3, a serine protease found in the azurophilic granules of neutrophils.¹⁵ In vasculitis, p-ANCA is most often directed against myeloperoxidase, although a number of other target antigens are also associated with this staining pattern.¹⁶

The problem of testing variability

Since the description of its utility in the vasculitides, ANCA testing has become available through many laboratories. Although the quality and consistency of these tests have significantly improved, the results obtained by different laboratories can still vary.¹⁷ When ordering these studies, the clinician should insist that the samples be processed in a laboratory that has had substantial experience in testing for ANCA. Even in the hands of skilled personnel, testing by immunofluorescence is fairly subjective and is less reproducible and less specific for vasculitis than solid-phase antigen-specific assays. To ensure optimal assessment, some investigators recommend that both immunofluorescence and solid-phase testing be performed.¹⁸

Positive ANCA in other diseases

Positive c-ANCA tests have been reported in a number of disorders that are often in the differential diagnosis of Wegener's granulomatosis, including lymphoma and other malignant

diseases, connective tissue diseases, and infectious diseases such as tuberculosis and human immunodeficiency virus infection.^{3,4,19–21} As these are conditions that could worsen with immunosuppressive therapy, concern must immediately be raised about using c-ANCA as a sole means of diagnosis in most instances.

■ ANCA AS A DIAGNOSTIC TOOL

Probability and Bayes' theorem

Although a review of probability theory in the evaluation of diagnostic tests is beyond the scope of this article, the utility of ANCA cannot be assessed without understanding some key concepts. In the absence of a perfect means of diagnosis, clinicians have long had to make decisions based on the likelihood that an individual patient has a particular disease. The utility of a diagnostic test can be assessed in a number of ways.^{22–24} One approach employs Bayes' theorem, which provides a means of calculating the posttest probability of disease if the pretest probability, sensitivity, and specificity are known (TABLE 1). These terms are best illustrated by discussing their application to ANCA.

Sensitivity and specificity

The sensitivity of a test refers to the proportion of patients with disease whose test results are positive, while specificity refers to the proportion of patients who do not have disease and whose test results are negative.

Several early studies of selected patients with confirmed Wegener's granulomatosis found the sensitivity and specificity of a positive c-ANCA test to exceed 90%.^{25,26} Subsequent studies on larger groups of unselected patients have revealed a broader range of results, with sensitivity ranging from 34% to 92% and specificity from 88% to 100%.^{13,21,27,28} Patients with diseases clinically similar to Wegener's granulomatosis have not been studied in substantial numbers, although one report in patients with upper or lower respiratory tract symptoms found the sensitivity of ANCA to be 65% and the specificity 77%.²¹

Other factors that may influence studies on sensitivity and specificity include the sample size, patient selection, disease definition,

Rule out infection before starting immunosuppressive therapy

TABLE 1

Pretest and posttest probability when a diagnosis of Wegener's granulomatosis is considered

SITES OF DISEASE	PRETEST PROBABILITY (p[D])	POSTTEST PROBABILITY FOR A POSITIVE C-ANCA * WHERE THE TEST HAS		TREATMENT IF WEGENER'S GRANULOMATOSIS IS DIAGNOSED
		SENSITIVITY=75% SPECIFICITY=90%	SENSITIVITY=95% SPECIFICITY=95%	
None	0.003%	<1%	<1%	None
Sinus [†]	1%	7%	16%	Local care and possibly glucocorticoids
Sinus and pulmonary [‡]	10%	45%	68%	Glucocorticoids and cytotoxic agent
Sinus and glomerulonephritis [§]	30%	76%	89%	Glucocorticoids and cytotoxic agent
Sinus, pulmonary, and glomerulonephritis	85%	98%	99%	Glucocorticoids and cytotoxic agent

* Posttest probability of disease after obtaining a positive test result as calculated from Bayes' theorem:
$$\frac{p[D] \times \text{sensitivity}}{(p[D] \times \text{sensitivity}) + \{(1 - p[D]) \times (1 - \text{specificity})\}}$$

[†] Radiographic evidence of mucosal thickening involving one or more sinuses [‡] Radiographic presence of pulmonary infiltrates or nodules, or both [§] Urinalysis demonstrating microscopic hematuria and red blood cell casts

The posttest probability of disease must be high if toxic therapy is planned

and level of disease activity. Overall, patients with active Wegener's granulomatosis have been found to have higher c-ANCA levels compared with patients with inactive disease.^{2,25,26} However, this varies in individual patients and should not be used for therapeutic decision-making or as a sole means of determining disease activity.²⁹

A meta-analysis published in 1995 examined the reported studies of c-ANCA sensitivity and specificity using a rigorous, standardized article selection process.²⁷ The pooled sensitivity of c-ANCA was 66% (95% confidence interval 57% to 74%), and the pooled specificity was 98%. From a review of four articles that provided data on disease activity, the pooled sensitivity of c-ANCA with active disease was 91% (95% confidence interval 87% to 95%), and the pooled specificity was 99%. For inactive disease, the pooled sensitivity and specificity were 63% and 99.5%, respectively.

■ Posttest probability of disease

Although its sensitivity and specificity may be high, the usefulness of c-ANCA as a diagnos-

tic test is best assessed by examining how a positive test influences the posttest probability of disease.

Posttest probability of disease can be thought of as the probability that a patient has Wegener's granulomatosis, given that the c-ANCA test is positive.²²⁻²⁴ The calculation of posttest probability of disease is based not only on sensitivity and specificity, but also on pretest probability, which is the probability that the patient has Wegener's granulomatosis prior to ANCA testing (TABLE 1). The pretest probability varies and is estimated using published information, personal experience, and characteristics of the individual patient.^{23,24} As the pretest probability goes down, so does the posttest probability of disease and, thus, the likelihood that a positive test for c-ANCA indicates the presence of Wegener's granulomatosis (FIGURE 1). This is a critical point, as Wegener's granulomatosis is uncommon in most clinical settings, and thus in most situations the pretest probability of the disease will be low.

TABLE 1 illustrates how the pretest probability affects posttest probability in different clinical situations where Wegener's granulomato-



sis is included in the differential diagnosis. As discussed previously, many factors influence the estimation of pretest probability, and the values used in these examples should not be taken as exact figures.

What is an acceptable posttest probability of disease?

The decision about what level of posttest probability of disease is acceptable should take into account the impact the diagnosis would have and the risks if the diagnosis is incorrect. For example, a lower posttest probability of disease is often acceptable in deciding to treat a probable minor infection with an antibiotic. In contrast, a posttest probability of anything less than 100% is unsatisfactory when rendering a diagnosis of cancer and proceeding with therapy that has significant side effects.

In the case of Wegener's granulomatosis, the issues to be considered include:

- The risk of using toxic medications where they are not needed.
- Not treating the correct diagnosis.
- The potential physical, emotional, and economic effects that a diagnosis of Wegener's granulomatosis would have on the patient's life.

Because a diagnosis of Wegener's granulomatosis has such serious implications, a positive c-ANCA should be considered acceptable for making a diagnosis only if its posttest probability of disease is higher than the likelihood of obtaining a diagnosis by biopsy.

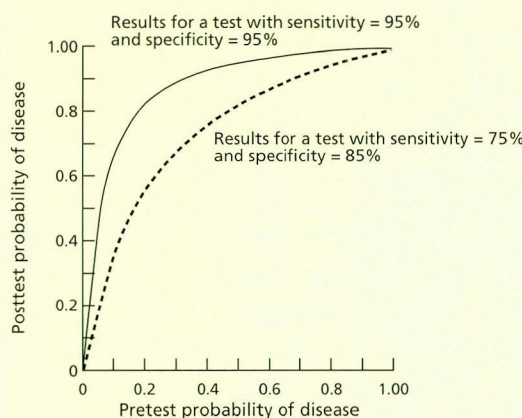
Can c-ANCA ever be used for diagnosis?

As seen in TABLE 1, for a patient with sinus, lung, and renal disease, the posttest probability of disease with a positive c-ANCA test is equal to or greater than that of biopsy, suggesting that a biopsy may not be indicated in this situation. Even so, the decision not to obtain a biopsy must be made very cautiously. The definition of "sinus, lung, and renal disease" is critical to the interpretation of posttest probability of disease. Specifically, such a patient must have:

- No other risk factors for infection in the medical history.
- Objective evidence of sinus disease, with sinus mucosal thickening detected by computed tomography.

FIGURE 1

The effect of pretest probability on the posttest probability of a diagnostic test



ADAPTED WITH PERMISSION FROM: SACKETT DL²²

- Glomerulonephritis, defined as an active urine sediment with red cell casts.
- Pulmonary abnormalities, evaluated by bronchoscopy, with bronchoalveolar lavage performed to rule out infection.

- Testing for antglomerular basement membrane antibodies, if pulmonary hemorrhage is present. These antibodies have been found to coincide with ANCA in a small number of patients.⁶

If all of the above conditions are met, which occurs in a very small number of patients, then it is feasible that a positive c-ANCA may be diagnostic of Wegener's granulomatosis in the absence of biopsy.

Utility of a negative ANCA


If one uses the lower reported levels of sensitivity, then having a negative c-ANCA test would not greatly decrease the posttest probability of disease from pretest estimates. More important, however, given the nature of Wegener's granulomatosis, a negative c-ANCA should almost never be used as a basis for eliminating Wegener's granulomatosis from diagnostic consideration. Untreated, Wegener's granulomatosis is potentially life-threatening. Therefore, in a patient in whom the pretest probability of

Wegener's granulomatosis most often affects the upper airways, lungs, and kidneys



disease is felt to be moderate to high on a clinical basis, a negative c-ANCA test should never be used to rule out disease, as failure to make the diagnosis can profoundly affect patient outcome.

CONCLUSIONS

The discovery of ANCA has raised many questions about our approach to Wegener's granulomatosis, among them the necessity of obtaining a histologic diagnosis. When evaluating a patient with suspected Wegener's granulomatosis, not only must the presence of the disease be confidently ascertained, but other diseases such as infection must be ruled out, because therapy for Wegener's granulomatosis can be extremely toxic. Although c-ANCA has been found to have a high sensitivity and specificity for Wegener's granulomatosis, it often carries an unacceptably low posttest probability of disease because of the low pretest probability of Wegener's granulomatosis in most clinical situations. Therefore, while a positive c-ANCA test may be useful to suggest the presence of Wegener's granulomatosis, in most cases it should not be used in place of a biopsy to diagnose this disease. 

REFERENCES

- Davies DJ, Moran JE, Niall JF, Ryan GB. Segmental necrotizing glomerulonephritis with antineutrophil antibody: possible arbovirus aetiology? *Br Med J* 1982; 285: 606.
- VanDer Woude FJ, Lobatto S, Permin H, et al. Autoantibodies against neutrophils and monocytes: Tool for diagnosis and marker of disease activity in Wegener's granulomatosis. *Lancet* 1985; 1: 425-429.
- Kallenberg C, Leontine-Mulder A, Cohen-Tervaert J. Antineutrophil cytoplasmic antibodies: A still-growing class of autoantibodies in inflammatory disorders. *Am J Med* 1992; 93: 675-682.
- Gross W. Antineutrophil cytoplasmic autoantibody testing in vasculitides. *Rheum Dis Clin North Am* 1995; 4: 987-1011.
- Hoffman GS, Kerr GS, Laved RY, et al. Wegener's granulomatosis: an analysis of 158 patients. *Ann Intern Med* 1992; 116: 488-494.
- Niles JL, Pan GL, Collins AB, et al. Antigen-specific radioimmunoassays for anti-neutrophil cytoplasmic antibodies in the diagnosis of rapidly progressive glomerulonephritis. *J Am Soc Nephrol* 1991; 2: 27-36.
- Mandell BF, Hoffman GS. Differentiating the vasculitides. *Rheum Dis Clin North Am* 1994; 20: 409-442.
- Walton E. Giant cell granuloma of the respiratory tract (Wegener's Granulomatosis). *Brit Med J* 1958; 2: 265-270.
- Talar-Williams C, Hijazi YM, Walther MM, et al. Cyclophosphamide-induced cystitis and bladder cancer in patients with Wegener granulomatosis. *Ann Intern Med* 1996; 124: 477-84.
- Devaney KO, Travis WD, Hoffman GS, et al. Interpretation of head and neck biopsies in Wegener's granulomatosis. A pathologic study of 126 biopsies in 70 patients. *Am J Surg Pathol* 1990; 14: 555-564.
- Weiss MA, Crissman JD. Renal pathologic features of Wegener's granulomatosis. *Sem Resp Med* 1989; 10: 141-148.
- Jennette JC, Wilkman AS, Falk RJ. Anti-neutrophil cytoplasmic autoantibody-associated glomerulonephritis and vasculitis. *Am J Pathol* 1989; 135: 921-930.
- Bindi P, Mougnot B, Mentre F, et al. Necrotizing crescentic glomerulonephritis without significant immune deposits: a clinical and serological study. *Q J Med* 1993; 86: 55-68.
- Travis WD, Hoffman GS, Leavitt RY, Pass HI, Fauci AS. Surgical pathology of the lung in Wegener's granulomatosis. Review of 87 open lung biopsies from 67 patients. *Am J Surg Pathol* 1991; 15: 315-333.
- Niles JL, McCluskey RT, Ahmad MF, Arnaout MA. Wegener's granulomatosis autoantigen is a novel neutrophil serine proteinase. *Blood* 1989; 74: 1888-1893.
- Falk RJ, Jennette JC. Anti-neutrophil cytoplasmic autoantibodies with specificity for myeloperoxidase in patients with systemic vasculitis and idiopathic necrotizing and crescentic glomerulonephritis. *N Engl J Med* 1988; 318: 1651-1657.
- Hagen EC, Andrassy K, et al. The value of indirect immunofluorescence and solid phase techniques for ANCA detection. *J Immunol Methods* 1993; 159: 1-16.
- Merkel PA, Polisson RP, Chang Y, Skates SJ, Niles JL. Prevalence of antineutrophil cytoplasmic antibodies in a large inception cohort of patients with connective tissue disease. *Ann Intern Med* 1997; 126: 866-873.
- Murphy EA, Fox JG, Galbraith I, et al. The spectrum of disease associated with a positive ANCA. *Clin Rheumatol* 1993; 12: 327-331.
- Davenport A. False positive perinuclear and cytoplasmic anti-neutrophil cytoplasmic antibody results leading to misdiagnosis of Wegener's granulomatosis and/or microscopic polyarteritis. *Clin Nephrol* 1992; 37: 124-130.
- Davenport A, Lock RJ, Wallington TB. Clinical relevance of testing for antineutrophil cytoplasm antibodies (ANCA) with a standard indirect immunofluorescence ANCA test in patients with upper or lower respiratory tract symptoms. *Thorax* 1994; 49: 213-217.
- Sackett DL, Haynes RB, Guyatt GH, Tugwell P. The interpretation of diagnostic data. In: Sackett DL (editor). *Clinical epidemiology: A basic science for clinical medicine*. Boston: Little, Brown, and Company, 1991: 51-152.
- Sox HC, Blatt MA, Higgins MC, Marton KI. *Medical decision making*. Stoneham: Butterworths, 1988.
- Sox HC. Probability theory in the use of diagnostic tests. *Ann Intern Med* 1986; 104: 60-66.
- Nolle B, Specks U, Ludemann J, et al. Anticytoplasmic autoantibodies: Their immunodiagnostic value in Wegener's granulomatosis. *Ann Intern Med* 1989; 111: 28-40.
- Cohen Tervaert JW, VanDer Woude F, et al. Association between active Wegener's granulomatosis and anticytoplasmic antibodies. *Arch Intern Med* 1989; 149: 2461-2465.
- Rao JK, Weinberger M, Oddone EZ, et al. The role of antineutrophil cytoplasmic antibody (c-ANCA) testing in the diagnosis of Wegener granulomatosis: A literature review and meta-analysis. *Ann Intern Med* 1995; 123: 925-932.
- Bosch X, Mirapeix E, Font J, et al. Anti-myeloperoxidase autoantibodies in patients with necrotizing glomerular and alveolar capillaritis. *Am J Kidney Dis* 1992; 20: 231-239.
- Kerr GS, Fleisher TA, Hallahan CW, et al. Limited prognostic value of changes in antineutrophil cytoplasmic antibody titer in patients with Wegener's granulomatosis. *Arthritis Rheum* 1993; 36: 365-371.

ADDRESS: Carol A. Langford, MD, MHS, Building 10, Room 11B-13, National Institutes of Health, Bethesda, MD, 20892.

A negative c-ANCA test does not rule out Wegener's granulomatosis