

**PRASOON JAIN, MD**

Staff physician, Department of Medicine, Louis A. Johnson Veterans Administration Medical Center, Clarksburg, WV.

**SALIM A. KATHAWALLA, MD**

Staff physician, Department of Pulmonary and Critical Care Medicine, Park Nicollet Clinic, Minneapolis, MN.

**ALEJANDRO C. ARROLIGA, MD**

Staff physician; acting director, Medical Intensive Care Unit; and director, fellowship program, Department of Pulmonary and Critical Care Medicine, Cleveland Clinic.

# Managing solitary pulmonary nodules

## ABSTRACT

A solitary pulmonary nodule (SPN) on a chest radiograph represents a major diagnostic dilemma. The goals of management are to resect malignant tumors without delay and to avoid unnecessary thoracotomy if the nodule is benign. But because of the difficulty distinguishing benign from malignant nodules, even with advances in imaging techniques, these goals cannot be met in all cases.

## KEY POINTS

Preoperative computed tomography of the chest is very helpful in distinguishing between benign and malignant SPNs.

Common primary tumors that metastasize to the lungs and manifest as SPNs include cancers of the head and neck, adenocarcinomas of the breast, kidney, and colon, and sarcomas of soft tissue.

Granulomatous diseases such as tuberculosis, histoplasmosis, and coccidioidomycosis constitute nearly 80% of all benign SPNs.

No study has looked at the association between smoking and the risk of malignant SPNs, but a history of smoking greatly increases the likelihood that an SPN is due to lung cancer.

**A**LTHOUGH MOST solitary pulmonary nodules (SPNs) are benign, unexpected discovery of a radiologic abnormality that can potentially represent lung cancer causes considerable anxiety for physicians and patients.

Without a doubt, appropriate management of SPNs remains one of the most difficult challenges that physicians face in clinical practice. A number of exciting advances in imaging technology have made it easier to distinguish benign from malignant SPNs. However, thoracotomy still remains the gold standard to distinguish between the two.

The optimal outcome for these patients requires a team approach. The team should include the primary care physician, pulmonologist, radiologist, thoracic surgeon, and the patient. Although a majority of patients with SPNs need specialty care, the role of the primary care physician should not be underestimated (TABLE 1). In the present health care environment, management of SPNs can not be considered as an entity entirely outside the domain of primary care physicians.

## BACKGROUND

SPNs are single, discrete pulmonary lesions surrounded by aerated lung and not associated with mediastinal lymphadenopathy, atelectasis, or pneumonitis on the chest radiograph.<sup>1,2</sup> Although some authorities include lesions up to 6 cm in size in the definition of SPNs, most regard a pulmonary radiographic opacity larger than 3 cm as a lung mass, not an SPN.

SPNs are common. Screening studies in adults revealed 1 to 2 SPNs per 1,000 chest radiographs.<sup>3,4</sup> In a 1987 estimate, 133,900 SPNs were detected on chest radiographs in the United States.<sup>5</sup> In most instances, SPNs are an incidental radiographic finding and are not associated with any symptoms.



TABLE 1

**Primary care management of SPNs**

Detection of solitary pulmonary nodule  
 Obtain all prior chest roentgenograms and chest CT scans if available  
 Comprehensive history and physical examination  
 Identify important comorbid conditions such as chronic obstructive pulmonary disease, ischemic heart disease, etc  
 Obtain baseline laboratory tests  
 Obtain spirometry whenever appropriate  
 Search for extrathoracic malignancy  
 Optimize medical condition  
 Initiate smoking cessation program  
 Patient education  
 Referral to pulmonary specialist  
 Follow-up care in consultation with pulmonary specialist

**THE CHALLENGE**

After finding a nodule in an asymptomatic patient, the main issue is to determine whether it is benign or malignant. The primary goals of management are to expeditiously resect potentially curable lung cancers that present as SPNs and to minimize the use of thoracotomy for benign SPNs. Although thoracotomy is still the gold standard for distinguishing between benign and malignant SPNs, major advances in imaging technology have improved our ability to achieve this goal without subjecting patients to the risks of major surgery.

**COMMON CAUSES**

A variety of benign and malignant lesions can present as an SPN on a chest radiograph. Common causes of SPNs are listed in TABLE 2.

The percentage of SPNs that are due to malignant diseases varies considerably among studies, depending on how patients are selected. For instance, in earlier community-based chest radiograph screening programs, as few as 3% to 5% of SPNs were due to malignant diseases.<sup>3,6</sup> In contrast, malignancy was detected in 35% to 40% of patients who underwent surgical resection for SPNs.<sup>7,8</sup> Recent studies that included computerized tomography (CT) as a standard preoperative test have reported malignancy in 60% to 90% of resected SPNs.<sup>9-11</sup>

These striking results are due to the superior ability of preoperative chest CT scans to distinguish between benign and malignant SPNs. As a result, these studies<sup>9-11</sup> show a strong selection bias, since patients had a high likelihood of malignancy before they were referred for thoracotomy.

**Bronchogenic carcinoma**

Bronchogenic carcinoma is the most common cause of malignant SPNs. Although all histologic cell types of lung cancer can present as an SPN, adenocarcinoma and large cell lung cancer are far more likely to present as an SPN than either squamous cell or small cell lung cancer.<sup>8-12</sup> Metastatic tumors account for 10% to 30% of all resected malignant SPNs.<sup>11,13</sup> Common primary tumors that metastasize to the lungs and manifest as an SPN include head and neck cancers, adenocarcinoma of the breast, kidney, and colon, and soft tissue sarcomas.

**Granulomatous disease**

Granulomatous diseases such as tuberculosis, histoplasmosis, and coccidioidomycosis constitute nearly 80% of all benign SPNs. About 10% of benign nodules are caused by hamartomas, benign tumors believed to arise from non-organized embryonic tissue ("rests"). The remaining 10% of benign SPNs are due to various other reasons as listed in TABLE 2.

**SPN: BENIGN OR MALIGNANT?**

Many epidemiological, clinical, and radiographic features help to differentiate between benign and malignant SPNs. These features include the patient's age, smoking history, and a prior history of malignancy. The presence and the pattern of calcification and the growth rate of the tumor (estimated by reviewing serial chest radiographs) are the two most useful features.

Unfortunately, clinical assessment can establish the nature of an SPN with a reasonable degree of certainty in only a minority of cases. Frequently, SPNs are classified as "indeterminate" after the initial assessment. Further diagnostic workup is needed for appropriate management of these patients.

**Bronchogenic cancer is the main cause of malignant SPNs**





## HISTORY AND PHYSICAL EXAMINATION

Even though most patients with SPNs are asymptomatic at presentation, the initial assessment should start with a comprehensive history and a thorough physical examination to identify risk factors.

When taking the history, record the following:

- Patient's age.
- Tobacco use.
- History of prior malignancy.
- Occupational exposure to carcinogens such as asbestos.

- Previous history of tuberculosis or pulmonary mycosis.

- History of residing or traveling to areas endemic for certain granulomatous infections.

The history and physical examination performed by the primary care physician may uncover coexisting medical problems, such as chronic obstructive pulmonary disease or coronary artery disease, which may influence the overall diagnostic and therapeutic strategy.

### Age

Many studies have shown that the chance that an SPN is malignant increases with age. For instance, in men over age 50, 50% to 65% of SPNs are malignant.<sup>7,8,11</sup> In contrast, the risk of a malignant SPN among nonsmokers under age 35 is sufficiently low to justify observation alone with serial chest radiography in many cases.<sup>12-14</sup>

Nevertheless, age alone is not infallible evidence against malignancy. Indeed, studies have shown that up to one third of SPNs in patients under age 50 ultimately prove to be malignant.<sup>11</sup>

### Tobacco use

Smoking is the most important predisposing cause of lung cancer. The risk of lung cancer is directly correlated with the duration and intensity of tobacco use. Interestingly, no study has specifically looked at the association between smoking and the risk of a malignant SPN. Nevertheless, it is widely accepted that a history of significant smoking greatly increases the likelihood that the SPN in question is due to lung cancer.

TABLE 2

### Common causes of solitary pulmonary nodules

BENIGN CAUSES	MALIGNANT CAUSES
<b>Granulomatous infections</b>	<b>Bronchogenic carcinoma</b>
Tuberculosis	Adenocarcinoma
Coccidioidomycosis	Large cell lung cancer
<b>Other infections</b>	<b>Pulmonary metastasis</b>
Pneumonitis	Head and neck tumors
Echinococcus cyst	Breast cancer
Ascariasis	Renal cell carcinoma
Dirofilariasis	Colon cancer
Pneumocystis carinii	Sarcomas
Atypical mycobacterial infection	<b>Pulmonary carcinoid tumors</b>
<b>Benign tumors</b>	
Hamartoma	
Lipoma	
Fibroma	
<b>Noninfectious granuloma</b>	
Sarcoidosis	
Wegener's granulomatosis	
Bronchiolitis obliterans with organizing pneumonia	
<b>Congenital</b>	
Pulmonary arteriovenous malformation	
Bronchogenic cyst	
<b>Miscellaneous</b>	
Rheumatoid nodule	
Amyloidoma	
Pulmonary infarction	

MODIFIED FROM STOLLER JK, AHMAD M, RICE TW. SOLITARY PULMONARY NODULE. CLEVELAND CLIN J MED 1988; 55:68-74.

### Extrathoracic malignancy

The probability that a nodule is malignant is very high in patients with concurrent or previous history of extrathoracic malignancy. In one study,<sup>15</sup> biopsy of the SPN showed evidence of malignancy in 80% of patients known to have concomitant or previous extrathoracic malignancy. Similar results were reported previously by Good and Wilson,<sup>4</sup> who found pulmonary metastasis as the cause of the SPN in 86 of 103 patients in whom an SPN was accompanied by a known extrapulmonary neoplasm.

Yet despite these impressive statistics, proceeding with biopsy is essential in these patients, as it is not safe to assume that an SPN is metastatic in origin even when there is a history of extrathoracic malignancy. Patients with proven malignancy at one site



may be at a higher risk of a second primary malignancy. In one study,<sup>16</sup> the authors concluded that an SPN in a patient with breast cancer should not be assumed to be metastatic in origin, and that further studies to exclude primary lung cancer are warranted.

### Rheumatoid arthritis

Patients with rheumatoid arthritis may present with solitary or multiple pulmonary nodules. Seropositive men with subcutaneous nodules are at higher risk of developing nodular opacities on chest radiography. However, SPNs in these patients should always be viewed with suspicion, especially when there is a history of significant tobacco use.

### Other risk factors to consider

A detailed history of residence, travel, and all prior occupations should be carefully recorded. Tuberculosis remains an important cause of SPNs in highly endemic areas.<sup>17</sup> Histoplasmosis is the most likely cause of SPNs in patients from the Ohio River valley presenting with a solitary calcified shadow on chest roentgenogram. Similarly, coccidioidoma was the cause of an SPN in more than 25% of patients living in an area where coccidioidomycosis is endemic.<sup>18</sup>

### The physical examination

Most patients with an SPN have a normal physical examination. Occasionally, physical examination may detect an unsuspected extrapulmonary malignancy, raising the likelihood of pulmonary metastasis as the cause of the SPN. In addition, dermal and mucosal telangiectasia may suggest pulmonary arteriovenous malformation as the cause of the SPN.

### ■ DIAGNOSTIC LABORATORY TESTS

A standard diagnostic laboratory workup in a patient with an SPN includes:

- Complete blood count.
- Serum electrolytes.
- Blood urea nitrogen.
- Serum creatinine.
- Liver function tests.
- Purified protein derivative, if tuberculosis is suspected.

There is no reason to obtain tumor markers to screen for malignancy. Sputum cytology

analysis in patients with a suspected malignant SPN has a very low yield: perhaps no more than 10% to 20% of patients with a malignant SPN have positive findings on sputum cytology analysis. Sputum cytology analysis contributes mainly to the diagnosis of squamous cell lung cancer but is of little or no value in detecting adenocarcinoma or large cell cancer.<sup>19</sup>

### ■ PULMONARY FUNCTION TESTS

Spirometry should be performed in all patients with an SPN who:

- Have a history of significant tobacco use.
- Have suspected chronic obstructive pulmonary disease.
- Are possible candidates for surgical resection.

A more comprehensive preoperative pulmonary assessment should be performed in consultation with a pulmonary specialist whenever surgical resection is being considered in patients with borderline lung functions (ie, a postoperative predicted forced expiratory volume in 1 second of less than 60% of the predicted value).

### ■ CHEST RADIOGRAPHY: SPNs AND MIMICS

SPNs are commonly discovered on chest radiography performed for another purpose. While SPNs as small as 5 mm may be visible, SPNs smaller than 1 cm due to bronchogenic carcinoma are usually not detected on plain films, even with optimal film technique and a thorough review of the chest radiograph.<sup>20</sup>

When a nodule is detected on a chest roentgenogram, the first step is to determine whether the lesion is truly pulmonary. From 10% to 20% of subtle radiological shadows initially thought to be SPNs prove to be artifacts or SPN mimics.<sup>21</sup> Common SPN mimics are listed in **TABLE 3**. In most cases, SPNs are visible on both posterior-anterior and lateral projections. From 5% to 10% of SPNs are seen only on the lateral view.<sup>22</sup>

It is sound clinical practice to entertain the likelihood of a mimic whenever a nodule is visible only on the posterior-anterior film. In most instances, the problem can be resolved

**Patients with an SPN tend to have a normal physical exam**





with repeated chest radiographs with nipple markers, oblique projections, and, occasionally, fluoroscopy. If doubt remains, a chest CT scan can be performed to clarify the issue.

### Compare previous films

Comparison of current chest radiographs with previous ones remains the single most critical step in the evaluation of SPNs, since differentiating between benign and malignant lesions on chest radiographs may not be possible in all cases. Therefore, every effort should be made to obtain all prior chest radiographs.

In many instances, review of a previous chest radiograph may provide sufficient information to the clinician to obviate the need for further diagnostic workup. SPNs with a benign pattern of calcification and no growth over a 2-year period are widely accepted as being benign. Although other features such as size, lobulated appearance, spiculated margins, and the presence or absence of satellite lesions provide useful clues to distinguish benign from malignant SPNs, these findings are of lesser discriminatory value.

### Calcification

Benign SPNs are more likely than malignant SPNs to show calcification on chest radiographs. Calcification in SPNs can follow several characteristic patterns. Some patterns of calcification have a very high predictive value for benign SPN. Dense, central, "bull's eye" calcification or laminated and diffuse calcification are characteristic of granuloma. A "popcorn" pattern of calcification on a chest roentgenogram strongly suggests hamartoma.

Only one third of patients with granulomas and only 10% to 15% of patients with hamartomas demonstrate characteristic patterns of calcification on plain chest radiographs. While the presence of a benign pattern of calcification virtually establishes benignity, the presence of calcification in other patterns is not helpful, as up to 10% of malignant SPNs may show evidence of calcification. Whenever present, calcification in a malignant SPN follows a stippled or eccentric pattern.

### Growth rate

The growth rate of an SPN, expressed as the doubling time, may help to distinguish

**TABLE 3**

### Solitary pulmonary nodule mimics

Nipple shadows	Pseudotumor
Soft tissue tumors, eg, neurofibroma	Round atelectasis
Bony shadow, eg, old healed rib fracture	Electrocardiogram leads
Pleural plaque	Buttons

whether it is benign or malignant.<sup>23,24</sup> However, this is not without pitfalls.<sup>5</sup> One of the most common pitfalls in assessing SPN doubling time on serial chest radiographs is to look for doubling of the diameter of the SPN. Actually, the doubling time is the time the nodule takes to double its volume. Assuming SPN to be a sphere, the doubling time can be calculated by measuring the nodule radius on serial chest roentgenograms using the equation  $Volume = 4/3 \pi r^3$ . Accordingly, the volume of an SPN doubles when its diameter increases by approximately 26%. The doubling time of lung cancers typically ranges from 20 to 400 days. Benign nodules grow either more rapidly or more slowly than this. A very rapid change in size raises suspicion of an infectious process, such as "round pneumonia," pulmonary infarction, or pulmonary vasculitis. Nodules that grow very slowly are more likely to be benign tumors or granulomas.<sup>25,26</sup>

### Other features

Larger SPNs are more likely to be malignant. However, smaller size does not mean an SPN is benign. Up to 42% of nodules smaller than 2 cm and 15% of nodules smaller than 1 cm subsequently prove to be malignant.<sup>27,28</sup>

Certain radiological features are more likely to be seen with malignant SPNs than with benign SPNs, including spiculated appearance of nodule margins (corona radiata), lobulated edges (notch sign), and pleural retraction (tail sign). These findings, however, have low predictive value, since a considerable number of benign SPNs may also show similar characteristics.

### Limitations of chest radiography

Apart from limitations in interpreting the noncharacteristic pattern of nodule calcification and difficulties in accurate radiological

**Some calcification patterns are highly indicative of a benign SPN**



measurement of doubling time, especially for small SPNs, evidence suggests that small nodules frequently escape radiological detection. It is estimated that the error rate for early detection of lung cancer is between 20% and 50%.<sup>29</sup> In actual clinical practice, when prior radiographs are reviewed after detecting an SPN, radiological abnormalities dating back months to years are very common.<sup>30</sup> There is evidence to suggest that even expert radiologists miss SPNs despite good film technique and careful review of radiographs.<sup>31</sup>

### ■ COMPUTED TOMOGRAPHY AND SPN

Inclusion of a chest CT scan in the workup of SPNs has allowed a more accurate characterization of SPNs as either benign or malignant. As a result, the incidence of thoracotomy for benign SPNs has declined significantly since CT scans became available.

#### Advantages of chest CT scans over conventional radiography

Chest CT has many advantages over conventional radiography in the evaluation of SPNs. Due to its axial format of data acquisition, chest CT is better at distinguishing true SPNs from chest wall lesions that mimic SPNs on chest roentgenograms. CT is better at interpreting subtle chest radiograph abnormalities in areas with high "anatomic image noise," such as lung apices, perihilar regions, and costophrenic angles.<sup>32</sup>

**Greater spatial resolution.** Chest CT has greater spatial resolution than chest radiography, which means SPNs as small as 3 to 4 mm are detectable on CT images. When performed in patients in whom the plain film demonstrates a solitary pulmonary metastasis, chest CT frequently reveals additional nodules not apparent on plain films. The CT evidence of multiple nodules in these patients is frequently the first clue that leads the physician to consider the possibility of pulmonary metastasis. Chest CT in this setting alters the overall patient management.

**More anatomic detail.** Chest CT captures the anatomical details of SPNs better than conventional radiographs do. Occasionally, typical morphological characteristics of an SPN may strongly suggest a specific diagnosis

such as rounded atelectasis,<sup>33</sup> aspergilloma,<sup>34</sup> or pulmonary arteriovenous malformation.<sup>35</sup>

**Demonstration of fat density with CT** images of an SPN strongly supports a benign etiology such as pulmonary hamartoma or lipoid pneumonia. In one study<sup>36</sup> that included 47 patients with pulmonary hamartomas, CT images showed recognizable fat in 18 patients and both fat and calcium in another 10 patients. No SPN with CT evidence of fat or fat and calcium in this series proved malignant on histologic analysis or follow-up.

**Detecting calcifications.** Finally, chest CT scans are clearly more sensitive than conventional radiography for detecting calcium within SPNs. Studies have shown that thin-section chest CT may demonstrate diffuse calcification in up to 50% of SPNs in which conventional methods failed to show any evidence of calcification.<sup>27,28</sup> The pattern of calcification in SPNs is better seen on chest CT than on standard chest radiographs (FIGURE 1.) Because CT images without intravenous contrast are required to detect calcification within the SPN, chest CT should always be performed both with and without intravenous contrast.

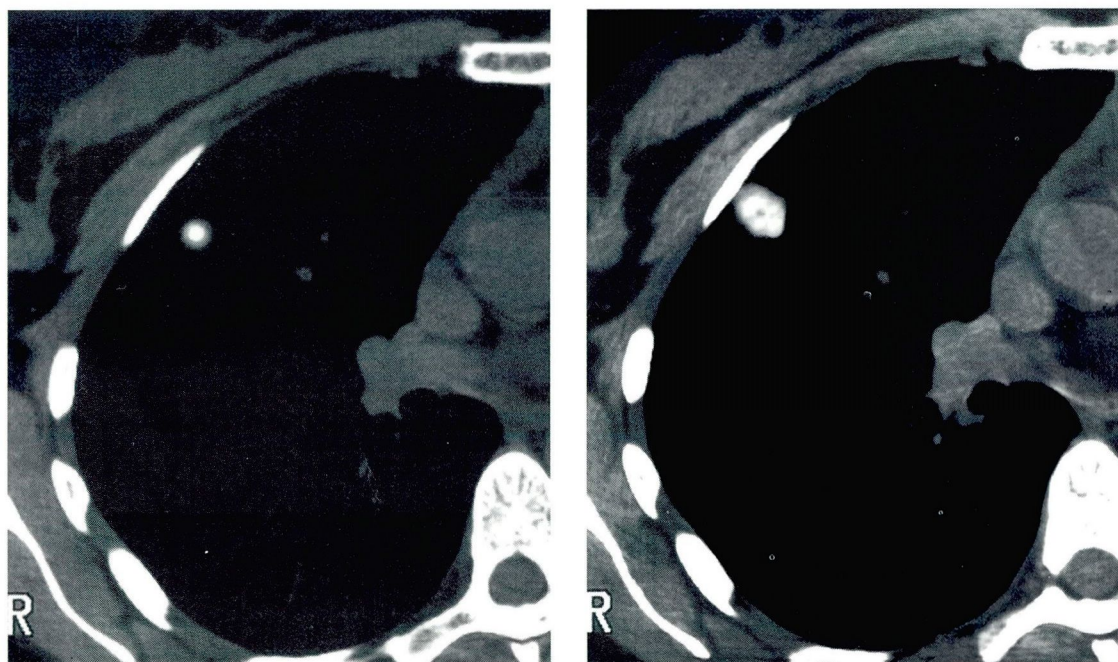
#### Indications for chest CT scanning

Chest CT scanning is most valuable when a comprehensive clinical evaluation and review of all available chest roentgenograms fail to confirm that an SPN is malignant. This is especially true for indeterminate SPNs smaller than 2 cm.<sup>27</sup> SPNs larger than 2 cm are less likely to be benign. Chest CT is less accurate in establishing the true nature of a benign SPN larger than 2 cm. Chest CT does not provide additional useful information when clinical and chest radiographic findings strongly support a diagnosis of a benign SPN.

Similarly, the role of chest CT remains uncertain for patients with a high likelihood of malignant SPNs. Despite uncertainties, it is common to perform chest CT with upper abdominal cuts for the purpose of staging prior to thoracotomy. Unfortunately, vigorous studies addressing the role of chest CT scanning in this setting are lacking. Available data appear to indicate that, for patients with localized bronchogenic carcinoma, chest CT seldom, if at all, changes the clinical stage or alters patient management.<sup>37</sup> Nevertheless, recent

**Chest CT has many advantages over standard radiography**





**FIGURE 1.** Computed tomography scans demonstrate dense, central “bull’s eye” (left) and “popcorn” patterns of pulmonary nodule calcification.

guidelines from the American Thoracic Society recommended chest CT scans for all patients with stage I non-small cell lung cancer before thoracotomy.<sup>38</sup>

### Conventional vs high-resolution chest CT

High-resolution chest CT is superior to conventional CT in the evaluation of SPNs. Structural details of SPNs such as edges, internal characteristics such as the presence of fat and calcium, and the nodule’s relation to the bronchus are all better defined with high-resolution CT.<sup>39</sup> Recent studies have indicated that presence of air bronchogram within the SPN increases the likelihood that the SPN is malignant.<sup>40,41</sup> The bronchus sign, a CT finding best appreciated on high-resolution CT images, refers to the presence of a bronchus leading directly to the SPN.<sup>42</sup> The diagnostic yield of flexible bronchoscopy for peripheral lung cancers is higher when the bronchus sign is present.

### Advances in the CT imaging of SPNs

Quantitative analysis of the density of SPNs by chest CT has generated considerable interest in the past 2 decades.

Quantitative measurement of enhancement of SPNs after intravenous injection of

contrast agent has proved to be a useful method of differentiating benign from malignant SPNs. Due to their higher vascularity, malignant SPNs show greater contrast enhancement than benign SPNs.

### ■ POSITRON EMISSION TOMOGRAPHY

Tumor cells show higher metabolic activity than benign cells. Positron emission tomography with 2-[fluorine-18]-fluoro-2-deoxy-D-glucose (FDG) uses this fundamental biochemical difference in glucose metabolism to distinguish benign SPNs from malignant ones.<sup>43</sup> A number of studies have shown that positron emission tomography can identify malignant SPNs with a 93% to 97% sensitivity and an 80% to 100% specificity,<sup>43–47</sup> but this technology is expensive and is not readily available in many medical centers. Therefore, its exact role in the management of SPNs remains unclear.

### ■ THERAPEUTIC DECISION-MAKING

No single ideal approach to the management of patients with an SPN has been developed. Several complex issues influence the thera-

**No ideal approach to managing patients with an SPN has been developed**



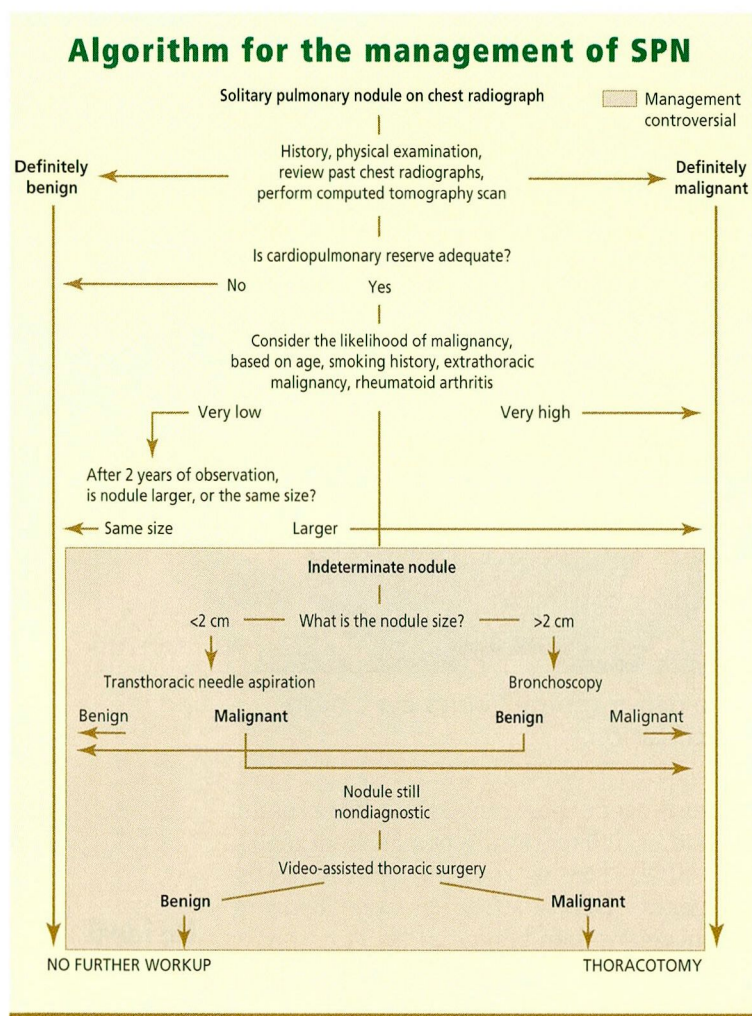


FIGURE 2.

peutic decision-making process, such as probability of malignancy, cardiopulmonary reserve, and patient preferences and values. Our simplified, algorithmic approach to management of SPNs is outlined in **FIGURE 2**.

After comprehensive evaluation, physicians need to decide whether the nodule is benign or malignant. A number of clinical and radiological features help make that decision (**TABLE 4**). As a general rule, when clinical and radiological features strongly suggest a benign SPN, no further intervention is warranted. These patients should be reassured and may be followed prospectively with serial chest radiography for further confirmation of benignity.

On the other hand, patients in whom the likelihood of malignancy is very high may undergo surgery with curative intent without further diagnostic testing.

Still, in a significant proportion of patients, the initial clinical and radiological evaluation fails to confirm if the SPN is benign or malignant, despite advances in imaging technology. Studies have shown that 20% to 25% of nodules ultimately turn out to be histopathologically benign.

There is no consensus as to what constitutes the best approach to patients with indeterminate SPNs. Management options include biopsy of the SPN, prospective observation, and referral to a thoracic surgeon for definitive resection. Probability of malignancy, confounding medical illnesses, and individual risk from a major thoracic procedure should be carefully weighed before making a final recommendation. In this context, there is no substitute for active involvement of the patient in the decision-making process.

### Biopsy in further evaluation

Biopsy of the SPN by either flexible bronchoscopy or a transthoracic approach is perhaps the most frequently chosen step for further evaluation of solitary nodules that remain indeterminate after initial radiographic studies. Some experts advocate biopsy of the SPN to document malignancy in all patients referred for thoracotomy. Most experts, however, agree that routine biopsy before subjecting patients to surgery is unnecessary when the likelihood of malignancy is very high.

The primary goal of performing biopsy is to identify a benign etiology of an SPN beyond a reasonable doubt, so that unnecessary thoracotomy can be avoided. However, as discussed below, preoperative biopsy of an SPN often fails to provide a specific benign diagnosis. In actual clinical practice, biopsy plays a more important role when the physician requires more definitive evidence of malignancy than clinical judgment alone before recommending thoracotomy. For instance, patients with significant cardio-pulmonary disease may not accept a higher-than-normal risk of perioperative mortality and morbidity with thoracotomy unless presented with biopsy evidence of malignancy and potential for cure with the surgery.

### Flexible bronchoscopy

Flexible bronchoscopy plays a limited role in the management of patients with SPNs.<sup>48</sup> In





TABLE 4

**Differentiating benign from malignant solitary pulmonary nodules**

FEATURE	BENIGN	MALIGNANT
Age	< 35	> 50
Smoking	Nonsmokers	Smokers
Previous history of malignancy	No	Yes
Size of nodule	< 2 cm	> 2 cm
Calcification	Bull's eye, diffuse, laminated, or popcorn pattern	None
Doubling time	< 20 or > 400 days	20 to 400 days
Radiological stability over 2 years	More likely	Less likely
Spiculated edges	Less likely	More likely
Margins	Smooth	Irregular or lobulated
Air bronchogram sign	Less likely	More likely
Pleural tail sign	Less likely	More likely
Satellite lesions	More likely	Less likely
Enhancement on CT after IV contrast	< 20 Hounsfield units	> 20 Hounsfield units
PET with fluorodeoxyglucose	No uptake	Increased uptake

some institutions, all patients scheduled to undergo thoracotomy for the resection of SPNs are subjected to screening bronchoscopy to exclude the presence of a synchronous and occult endobronchial tumor. Because the benefit of this practice in peripheral stage I bronchogenic carcinoma has never been proven, routine airway examination is probably not recommended for these patients.<sup>49,50</sup> More commonly, flexible bronchoscopy for an SPN is performed to establish a specific histological diagnosis. For malignant SPNs, the diagnostic yield of bronchoscopy varies from 10% to 69%.<sup>51,52</sup>

The diagnostic yield from flexible bronchoscopy depends not only on the experience and skill of the operator, but also on the size of the SPN. The likelihood of obtaining diagnostic material varies from 10% to 33% for nodules less than 2 cm in size and from 40% to 69% for nodules 2 to 4 cm in diameter.<sup>53,54</sup> Flexible bronchoscopy only rarely results in a specific diagnosis of benign SPN. Nonspecific findings in specimens obtained with flexible bronchoscopy should never be accepted as conclusive evidence that an SPN is benign.

A number of studies have indicated that the presence of the bronchus sign on chest CT scan increases the diagnostic yield of flexible

bronchoscopy in patients with malignant SPNs. A 60% to 80% yield can be expected when the bronchus sign is present as opposed to only a 0% to 30% yield when the bronchus sign is absent.<sup>55,56</sup>

**Flexible bronchoscopy is generally safe.** Pneumothorax occurs in no more than 1% to 2% of patients. In most cases, this can be managed conservatively, without a need for chest tube placement.

**Transthoracic needle aspiration**

Recent advances in imaging technology, biopsy, and cytopathology have expanded the role of transthoracic needle aspiration in the workup of indeterminate SPNs.<sup>57</sup> The sensitivity of fluoroscopic or CT-guided transthoracic needle aspiration for malignant SPNs varies from 75% to 97%.<sup>58,59</sup> The false-positive rate for cancer is less than 1%.<sup>60</sup> The agreement between transthoracic needle aspiration cytology and final histology varies from 60% to 90%.<sup>61–63</sup>

The diagnostic yield of transthoracic needle aspiration for a specific benign diagnosis such as granuloma or hamartoma is from 12% to 68%.<sup>64</sup> While specific benign diagnosis can be accepted as such, the problem arises when nonspecific results—eg, “benign tissue,”

**Management by watchful waiting is controversial**



inflammation, histiocytes, giant cells—are reported by the cytopathologist. The absence of malignant cells in the specimen obtained via transthoracic needle aspiration does not establish benignity. In fact, in some studies, 20% to 68% of nodules initially reported as nonspecific subsequently proved to be malignant.<sup>58,65,66</sup> Data indicate that the negative predictive value of transthoracic needle aspiration to exclude malignancy in SPNs varies from 52% to 88%.<sup>58,64,67</sup>

**Further management of patients** in whom transthoracic needle aspiration fails to establish a specific diagnosis is largely a matter of clinical judgment. Surgery is indicated if the suspicion of malignancy remains high.

**The main complication** of transthoracic needle aspiration is pneumothorax, which occurs in 25% to 30% of patients.<sup>57</sup> Up to 50% of all patients who develop pneumothorax after transthoracic needle aspiration require chest tube placement. Patients with chronic obstructive pulmonary disease with a low forced expiratory volume in 1 second (FEV<sub>1</sub>) seem to be at a higher risk of developing pneumothorax after transthoracic needle aspiration.<sup>68,69</sup> Minor hemoptysis develops in 5% to 10% of patients and resolves spontaneously in a majority of patients. Fatal hemorrhage and air embolism are exceedingly rare after transthoracic needle aspiration.<sup>70</sup>

#### ■ FOLLOW-UP OBSERVATION

Whether to observe with serial chest radiographs, perform biopsy, or proceed directly to thoracotomy should be decided only after carefully considering the likelihood of malignancy and the patient's operative risk. Close observation of an indeterminate nodule for a few months in young and otherwise healthy nonsmokers is the least invasive approach, and is acceptable to most patients and their physicians. Prospective observation may be the only viable option for those who refuse further invasive procedures.

#### **Watchful waiting is controversial**

A wait-and-watch approach for patients with indeterminate SPNs is controversial.<sup>71</sup> During the observation period, delays in resection of malignant nodules are inherent. Long-term

survival is longer after resection of smaller, as opposed to larger, malignant SPNs.<sup>72</sup>

An increase in the size of a nodule and the potential for lymph node metastasis during the observation period that may result in a lower 5-year survival rate are the main arguments against the watchful waiting. Although this is a valid concern, the magnitude of the risk associated with waiting a few months before resection remains unknown. However, this question has never been tested in rigorous clinical studies.

The proponents of prospective observation, on the other hand, argue that by the time a malignant SPN has reached the threshold size for radiological detection, it has already undergone at least 30 doublings,<sup>73</sup> and waiting another few months is unlikely to have a major impact on ultimate outcome.

#### ■ SURGERY

Surgery is the treatment of choice for non-small cell lung cancers that present as SPNs. In the absence of lymph node metastasis, 5-year survival of up to 80% can be expected after surgery, emphasizing the need for prompt resection of all malignant SPNs.<sup>74</sup> Surgical resection also remains the most definitive method of establishing the etiology of an SPN. With recent advances in imaging technology, the incidence of thoracotomy for benign SPNs has fallen to as low as 10% to 20%.

#### **Morbidity and mortality**

Perioperative mortality and morbidity with thoracotomy depend not only on the extent of lung resection but also on whether the surgery is performed for a benign or malignant SPN.<sup>75</sup> When patients undergo surgery for bronchogenic carcinoma, the 30-day mortality rate after the surgery is 6.2% for pneumonectomy, 2.9% for lobectomy, and 1.4% for wedge resection. The perioperative complication rate is higher in patients over age 70 than in those under age 60. After resection of a benign SPN, the 30-day mortality rate is less than 1%.

#### ■ THORACOSCOPY

In recent years, video-assisted thoracic surgery via the thoracoscope has been used to remove

**Surgery is the treatment of choice for non-small cell lung cancers presenting as SPNs**





nodules located in the periphery of the lung.<sup>76</sup> Video-assisted thoracic surgery provides a minimally invasive alternative to formal thoracotomy for the diagnosis and, in selected patients, management of indeterminate SPNs. The results of frozen-section examination of specimen resected via video-assisted thoracic surgery assist in directing the further course in the operating room. For benign nodules, the entire lesion can be resected with video-assisted thoracic surgery, and no further intervention is needed.<sup>77</sup>

### Conversion to standard thoracotomy

Presently, video-assisted thoracic surgery alone is not considered adequate for the management of malignant SPNs.<sup>78</sup> Accurate assessment of the local spread of the tumor and of mediastinal lymph node involvement is best made after converting video-assisted

thoracic surgery to standard thoracotomy. The reported conversion rate from video-assisted thoracic surgery to thoracotomy varies from 17% to 50%.<sup>78,79</sup> Occasionally, failure to locate an SPN with video-assisted thoracic surgery leads to a decision to proceed with thoracotomy.

### Candidates for wedge resection

A select group of patients with localized bronchogenic carcinoma who are poor surgical candidates due to impaired cardiopulmonary reserve, advanced age, or other confounding medical illnesses have been managed with thoracoscopic wedge resection alone. However, most surgeons believe that optimal surgical management of most patients with malignant SPNs mandates converting video-assisted thoracic surgery to full thoracotomy to ensure removal of the entire tumor.<sup>80</sup>

## REFERENCES

- Lillingston GA, Caskey CI. Evaluation and management of solitary pulmonary nodule. *Clin Chest Med* 1993; 14:111-119.
- Midthun DE, Swensen SJ, Jett JR. Approach to the solitary pulmonary nodule. *Mayo Clin Proc* 1993; 68:378-85.
- Comstock GW, Vaughan RH, Montgomery G. Outcome of solitary pulmonary nodule discovered in an x-ray screening program. *N Engl J Med* 1956; 254:1018-1022.
- Good CA, Wilson TW. The solitary circumscribed pulmonary nodule. Study of seven hundred five cases encountered roentgenologically in a period of three and one-half years. *JAMA* 1958; 66:210-215.
- Stoller JK, Ahmad M, Rice TW. Solitary pulmonary nodule. *Cleve Clin J Med* 1988; 55:68-74.
- Holin SM, Dwork RE, Glaser S, Rikli AE, Stocklen JB. Solitary pulmonary nodule found in a community-wide chest roentgenographic survey: A five year follow-up study. *Am Rev Tuberc* 1959; 79:427-439.
- Steele JD. The solitary pulmonary nodule. Report of a cooperative study of resected asymptomatic solitary pulmonary nodules in males. *J Thorac Cardiovasc Surg* 1963; 46:21-39.
- Higgins GA, Shields TW, Keehn RJ. The solitary pulmonary nodule. Ten year follow-up of veteran administration-armed forces cooperative study. *Arch Surg* 1975; 110:570-575.
- Libby DM, Henschke CI, Yankelevitz DF. The solitary pulmonary nodule: Update 1995. *Am J Med* 1995; 99:491-496.
- Rubins JB, Rubins HB. Temporal trends in the prevalence of malignancy in resected solitary pulmonary lesions. *Chest* 1996; 109:100-103.
- Toome H, Delphendhal A, et al. The coin lesion of the lung. A review of 955 resected coin lesions. *Cancer* 1983; 51:534-537.
- Jackman RJ, et al. Survival rates in peripheral bronchogenic carcinomas up to four centimeters in diameter presenting as solitary pulmonary nodules. *J Thorac Cardiovasc Surg* 1969; 57:1-8.
- Ray JF 3rd, Lawton BR, Magnin GE, et al. The coin story: update 1976. Twenty years experience with early thoracotomy for 179 suspected malignant coin lesions. *Chest* 1976; 70:332-336.
- Vance JW, et al. The solitary circumscribed pulmonary lesion due to bronchogenic carcinoma. *Dis Chest* 1959; 36:231-237.
- Neifeld JP, Michaelis LL, Doppman JL. Suspected pulmonary metastasis. Correlation of chest x-ray, whole lung tomograms and operative findings. *Cancer* 1977; 39:383-387.
- Casey JJ, Stempel BG, Scanlon EF, Fry WA. The solitary pulmonary nodule in the patient with breast cancer. *Surgery* 1984; 96:801-805.
- Lai RS, et al. Diagnostic value of transbronchial biopsy under fluoroscopic guidance in solitary pulmonary nodule in an endemic area of tuberculosis. *Respir Med* 1996; 90:139-143.
- Forseth J, Rohwedder JJ, et al. Experience with needle biopsy for coccidioidal lung nodules. *Arch Intern Med* 1986; 146:319-320.
- Frost JK, Ball WC, Levine ML, et al. Results of initial (prevalence) radiologic and cytologic screening in the Johns Hopkins study. *Am Rev Respir Dis* 1984; 130:549-554.
- Kundell HL. Predictive value and threshold detectability of lung tumors. *Radiology* 1981; 139:25-29.
- Kundell HL, Nodine CF, Carmody D. Visual scanning, pattern recognition and decision making in pulmonary nodule detection. *Invest Radiol* 1978; 13:175-181.
- Swensen SJ, Jett JR, Viggiano RW, Pairolero PC, Trastek VF. An integrated approach to the evaluation of solitary pulmonary nodule. *Mayo Clin Proc* 1990; 65:173-186.
- Steel JD, Buell P. Asymptomatic solitary pulmonary nodules. Host survival, tumor size, and growth rate. *J Thorac Cardiovasc Surg* 1973; 65:140-151.
- Nathan MH. Management of solitary pulmonary nodules: an organized approach based on growth rate and statistics. *JAMA* 1974; 227:1141-1144.
- Madewell JE, Feigin DS. Benign tumors of the lung. *Semin Roentgenol* 1977; 12:175-185.
- Goodwin RA Jr, Snell JR Jr. The enlarging histoplasmosis. *Am Rev Respir Dis* 1969; 100:1-12.
- Siegelman SS, Khouri NF, Leo FP, Fishman EK, Braverman RM, Zerhouni EA. Solitary pulmonary nodules: CT assessment. *Radiology* 1986; 160:307-312.
- Zerhouni EA, Stitik FP, Siegelman SS, et al. CT of the pulmonary nodule: A cooperative study. *Radiology* 1986; 160:319-327.
- Woodring JH. Pitfalls in the radiologic diagnosis of lung cancer. *AJR* 1990; 154:1165-1175.
- Heelan RT, Flehinger BJ, et al. Non-small cell lung cancers: results of the New York screening program. *Radiology* 1984; 151:289-293.
- Muhm JR, Miller WE, et al. Lung cancer detected during a screening program using four-month chest radiographs. *Radiology* 1983; 148:609-615.
- Caskey CI, Templeton PA, Zerhouni EA. Current evaluation of solitary pulmonary nodule. *Rad Clin North Am* 1990; 28:511-520.





33. McHugh K, Blaquiére RM. CT features of rounded atelectasis. *AJR* 1989; 153:257-260.
34. Roberts CM, Citron KN, Strickland B. Intrathoracic aspergilloma: Role of CT in diagnosis and treatment. *Radiology* 1987; 165:123.
35. Remy J, Remy-Jardin M, Wattinne L, Deffontaines C. Pulmonary arteriovenous malformations: Evaluation with CT of the chest before and after treatment. *Radiology* 1992; 182:809-816.
36. Siegelman SS, Khouri NF, Scott WW, Leo FP, Hamper UM, Fishman EK, Zerhouni EA. Pulmonary hamartoma: CT findings. *Radiology* 1986; 160:313-317.
37. Becker GL, Whitlock WL, Schaefer PS, Tenholder MF. The impact of thoracic computed tomography in clinically staged T1, N0, M0 chest lesions. *Arch Intern Med* 1990; 150:557-559.
38. American Thoracic Society/European Respiratory Society. Pretreatment evaluation of non-small cell lung cancer. *Am J Respir Crit Care Med* 1997; 156:320-332.
39. Zwirowich CV, Vedal S, Miller RR, Muller NL. Solitary pulmonary nodule: High resolution CT and radiologic-pathologic correlation. *Radiology* 1991; 179:469-476.
40. Kuriyama K, Tateishi R, Doi O, et al. Prevalence of air bronchogram in small peripheral carcinomas of the lung on thin section CT: Comparison with benign tumors. *AJR* 1991; 156:921-924.
41. Kui M, Templeton PA, White CS, Cai ZL, Bai YX, Cai YQ. Evaluation of air bronchogram sign on CT in solitary pulmonary lesions. *J Comput Assist Tomogr* 1996; 20:983-986.
42. Gaeta M, Barone M, Russi EG, et al. Carcinomatous solitary pulmonary nodule: Evaluation of the tumor bronchi relationship with thin section CT. *Radiology* 1993; 187:535-539.
43. Gupta NC, Frank AR, Dewan NA, et al. Solitary pulmonary nodules: Detection of malignancy with 2-[F-18]-fluoro-2-deoxy-D-glucose. *Radiology* 1992; 184:441-444.
44. Rege SD, Hoh CK, Gaspy JA, et al. Imaging of pulmonary mass lesions with whole body positron emission tomography and fluorodeoxyglucose. *Cancer* 1993; 72:82-90.
45. Patz EF Jr, Lowe VJ, Hoffman JM, Paine SS, Harris LK, Goodman PC. Persistent or recurrent bronchogenic carcinoma: Detection with PET and 2-[F-18]-fluoro-2-deoxy-D-glucose. *Radiology* 1994; 191:379-382.
46. Gupta NC, et al. Probability of malignancy in solitary pulmonary nodules using fluorine-18-FDG and PET. *J Nucl Med* 1996; 37:943-948.
47. Worsley DF, Celler A, Adam MJ, et al. Pulmonary nodules: Differential diagnosis using 18-F-fluorodeoxyglucose single-photon emission computed tomography. *AJR* 1997; 168:771-774.
48. Mehta AC, Kathawalla SA, et al. Role of bronchoscopy in the evaluation of solitary pulmonary nodule. *J Bronchol* 1995; 4:315-322.
49. Torrington KG, Kern JD. The utility of fiberoptic bronchoscopy in the evaluation of the solitary pulmonary nodule. *Chest* 1993; 104:1021-1024.
50. Goldberg SK, Walkenstein MD, Steinbach A, Aranson R. The role of staging bronchoscopy in the preoperative assessment of a solitary pulmonary nodule. *Chest* 1993; 104:94-97.
51. Katis K, Ingelso E, Zachariadis E, et al. The role of transbronchial needle aspiration in the diagnosis of peripheral lung masses or nodules. *Eur Respir J* 1995; 8:963-966.
52. Swinburn CR, Veale D, et al. A prospective randomized comparison of fine needle aspiration biopsy and fiberoptic bronchoscopy in the investigation of peripheral pulmonary opacities. *Respir Med* 1989; 83:493-495.
53. Shure D, Fedullo PF. Transbronchial needle aspiration of peripheral masses. *Am Rev Respir Dis* 1983; 128:1090-1092.
54. Chehani V. Bronchoscopic diagnosis of solitary pulmonary nodules and lung masses in the absence of endobronchial abnormality. *Chest* 1996; 109:620-625.
55. Gaeta M, Pandolfo I, Volta S, et al. Bronchus sign on CT in peripheral carcinoma of the lung: Value in predicting results of transbronchial biopsy. *AJR* 1991; 157:1181-1185.
56. Gaeta M, Russi EG, Spada FL, Barone M, Casablanca G, Pandolfo I. Small bronchogenic carcinomas presenting as solitary pulmonary nodules. Biopsy approach guided by CT positive bronchus sign. *Chest* 1992; 102:1167-1170.
57. Salazar AN, Wescott JL. The role of transthoracic needle biopsy for the diagnosis and staging of lung cancer. *Clin Chest Med* 1993; 14:99-110.
58. Garcia-Rio F, Lobato SD, Pino JM, et al. Value of CT-guided fine needle aspiration in solitary pulmonary nodules with negative fiberoptic bronchoscopy. *Acta Radiologica* 1994; 35:478-480.
59. Li H, Boisselle PM, Shepard JO, Trotman-Dickenson B, McLoud TC. Diagnostic accuracy and safety of CT-guided percutaneous needle aspiration biopsy of the lung: Comparison of small and large pulmonary nodules. *AJR* 1996; 167:105-109.
60. Sinner WN. Pulmonary neoplasm diagnosed with transthoracic needle biopsy. *Cancer* 1979; 43:1533-1540.
61. Greene R, et al. Supplementary tissue core histology from fine-needle transthoracic aspiration biopsy. *AJR* 1985; 144:787-792.
62. Taft PD, et al. A study of variability in cytologic diagnosis based on pulmonary aspiration specimens. *Am J Clin Pathol* 1980; 73:36-40.
63. Thornbury JR, Burkee DP, Naylor B. Transthoracic needle aspiration biopsy: accuracy of cytologic typing of malignant neoplasms. *AJR* 1981; 136:719-724.
64. Calhoun P, Feldman PS, Armstrong PS, et al. The clinical outcome of needle aspirations of lung cancer when cancer is not diagnosed. *Ann Thorac Surg* 1986; 41:592-596.
65. Milman N, Faurischou P, Grode G. Diagnostic yield of transthoracic needle aspiration biopsy following negative fiberoptic bronchoscopy in 103 patients with peripheral circumscribed pulmonary lesions. *Respiration* 1995; 62:1-3.
66. Mitruka S, et al. Diagnosing the indeterminate pulmonary nodule: percutaneous versus thoracoscopy. *Surgery* 1995; 118:676-684.
67. Westcott JL, Rao N, Colley DP. Pulmonary needle biopsy of small pulmonary nodules. *Radiology* 1997; 202:97-103.
68. Kazerooni EA, Lim FT, Mikhail A, Martinez FJ. Risk of pneumothorax in CT-guided transthoracic needle aspiration biopsy of the lung. *Radiology* 1996; 198:371-375.
69. Garcia-Rio F, Pino JM, Casadevall J, et al. Use of spirometry to predict risk of pneumothorax in CT-guided needle biopsy of the lung. *J Comput Assist Tomogr* 1996; 20:20-23.
70. Tolly JS, Feldmeier JE, Czamecki D. Air embolism complicating percutaneous lung biopsy. *AJR* 1988; 150:555-556.
71. Lillington GA. Pulmonary nodules: Solitary and multiple. *Clin Chest Med* 1982; 3:361-367.
72. Gail MH, Eagan RT, Feld R, et al. Prognostic factors in patients with resected stage I non-small cell lung cancer: a report from Lung Cancer Study Group. *Cancer* 1984; 54:1802-1813.
73. Spratt JS, Ter-Pogossian M, Long RTL. The detection and growth of intrathoracic neoplasm. *Arch Surg* 1963; 86:283-287.
74. Takise A, Kodama T, Shimamoto Y, et al. Histopathologic prognostic factors in adenocarcinomas of the peripheral lung cancers less than 2-cm in diameter. *Cancer* 1988; 61:2083-2088.
75. Ginsberg RJ, Hill LD, Eagan RT, et al. Modern thirty-day operative mortality for surgical resections in lung cancer. *J Thorac Cardiovasc Surg* 1983; 86:654-658.
76. Miller DL, Allen MS, Deschamps C, Trastek VF, Pairorero PC. Video-assisted thoracic surgical procedure: Management of solitary pulmonary nodule. *Mayo Clin Proc* 1992; 67:462-467.
77. Landreneau RJ, Hazelrigg SR, Ferson PF, et al. Thoracoscopic resection of 85 pulmonary lesions. *Ann Thorac Surg* 1992; 54:415-420.
78. Allen MS, Deschamps C, Lee RE, Trastek VF, Daly RC, Pairorero PC. Video assisted thoracoscopic stapled wedge resection for indeterminate pulmonary nodules. *J Thorac Cardiovasc Surg* 1993; 106:1048-1052.
79. Bernard A and the Thorax Group. Resection of pulmonary nodules using video assisted thoracic surgery. *Ann Thorac Surg* 1996; 61:202-205.
80. Santaambrogio L, Nosotti M, Bellaviti N, Mezzetti M. Video thoracoscopy versus thoracotomy for the diagnosis of the indeterminate solitary nodule. *Ann Thorac Surg* 1995; 59:868-871.

ADDRESS: Alejandro C. Arroliga, MD, Department of Pulmonary and Critical Care Medicine, A90, The Cleveland Clinic Foundation, 9500 Euclid Avenue, Cleveland, OH 44195, e-mail arrolia@cesmtp.ccf.org.