



## Beta<sub>2</sub>-microglobulin amyloidosis in renal failure: Understanding this recently recognized condition

**JONATHAN KAY, MD**

Section of Rheumatology, Lahey Clinic; assistant clinical professor of medicine, Harvard Medical School

### ABSTRACT

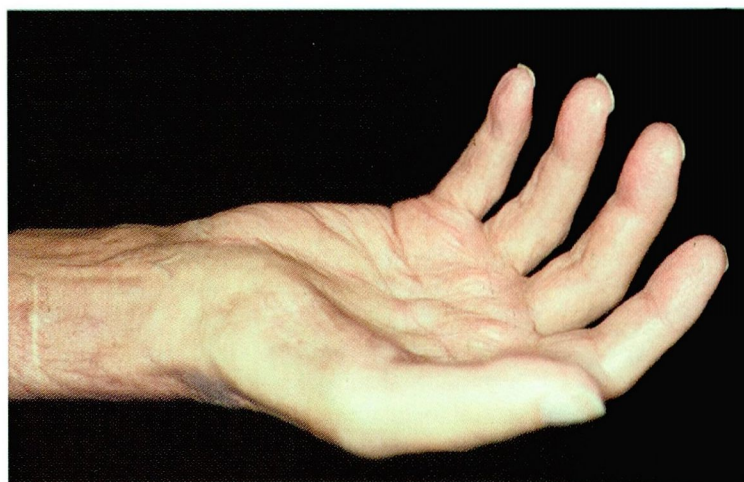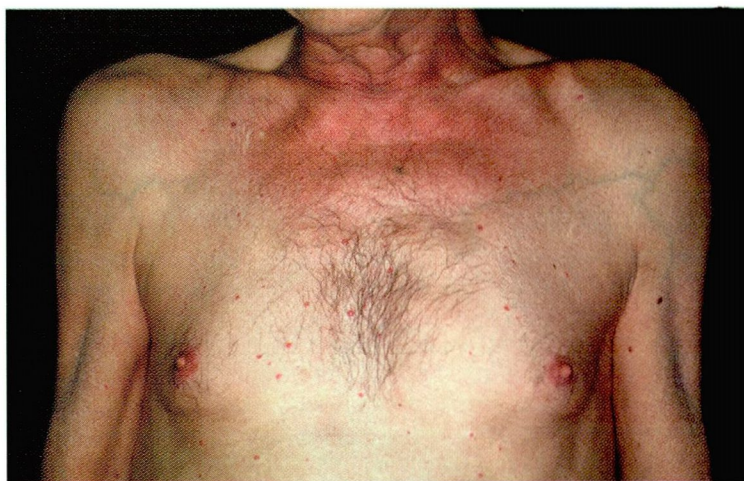Beta<sub>2</sub>-microglobulin amyloidosis can cause significant suffering in patients with chronic renal failure. Although renal transplantation is currently the only treatment, medical and surgical therapies may decrease pain and disability.

**P**HYSICIANS WHO care for patients with chronic renal failure need to recognize and treat beta<sub>2</sub>-microglobulin amyloidosis, a common and disabling complication of chronic renal failure that has been identified only in the past 15 years. The condition is characterized by amyloid deposition, leading to a variety of musculoskeletal problems including carpal tunnel syndrome and pathologic fractures. Its prevalence increases with duration of hemodialysis, from approximately 20% within 2 years of starting dialysis to nearly 100% after 13 years, although occasional patients with prolonged renal failure may exhibit the condition before the initiation of dialysis.

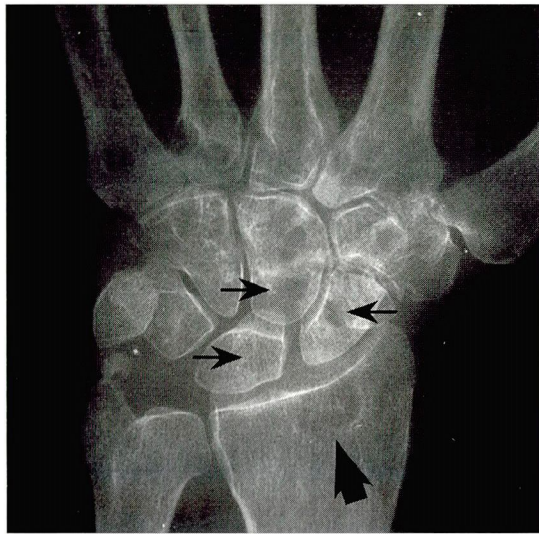Currently there is no treatment to prevent the progression of beta<sub>2</sub>-microglobulin amyloidosis other than renal transplantation, although there are a variety of therapies to reduce the pain associated with this condition.

### PATHOPHYSIOLOGY

Beta<sub>2</sub>-microglobulin is a naturally occurring glycosylated polypeptide that is present on the surface of all nucleated mammalian cells. In



**FIGURE 1.** Top, bilateral shoulder pads in a patient with beta<sub>2</sub>-microglobulin amyloidosis who was receiving long-term hemodialysis. Bottom, fixed flexion contractures of the fingers due to beta<sub>2</sub>-microglobulin amyloid deposits in the hand of a patient receiving long-term hemodialysis. Amyloid deposits, appearing as soft tissue fullness around the wrist, resulted in carpal tunnel syndrome and atrophy of the thenar muscle.



**FIGURE 2.** Wrist radiograph of a patient with beta<sub>2</sub>-microglobulin amyloidosis who was on long-term hemodialysis, showing cysts in the carpal bones (small arrows) and the distal radius (large arrow.)

humans, normal serum levels range from 1.5 mg/L to 3 mg/L. Beta<sub>2</sub>-microglobulin is excreted by the kidney, so serum levels in patients with chronic renal failure can increase by 10-fold to 20-fold. However, elevated levels of beta<sub>2</sub>-microglobulin alone do not explain the development of amyloidosis.

Instead, through a process that is not yet fully understood, the beta<sub>2</sub>-microglobulin is incorporated into beta<sub>2</sub>-microglobulin amyloid. This abnormal insoluble aggregate of proteins deposits preferentially in bone, articular cartilage, synovium, muscle, and ligaments (FIGURE 1). Patients with this type of amyloidosis often present with a characteristic triad:

- Shoulder pain
- Carpal tunnel syndrome
- Flexor tendon deposits in the hands.

The spine may be affected by a destructive spondyloarthropathy, and beta<sub>2</sub>-microglobulin amyloid may be deposited in the spinal canal or around the odontoid process in the upper cervical spine. Deposits in subchondral bone form cystic lesions that can result in pathologic fractures.

Beta<sub>2</sub>-microglobulin can also be deposited in the blood vessels and interstitial spaces of viscera, notably the gastrointestinal tract.

Most patients with visceral deposits have undergone hemodialysis for 10 years or longer and also have either carpal tunnel syndrome or arthropathy. These visceral deposits usually do not cause symptoms, although complications of the gastrointestinal tract and cardiovascular system have been reported.

As noted, the pathogenesis of beta<sub>2</sub>-microglobulin amyloidosis is incompletely understood. Important factors may include elevated levels of beta<sub>2</sub>-microglobulin, limited proteolytic cleavage of this molecule, modification of beta<sub>2</sub>-microglobulin and other proteins with advanced glycation end-products, and elevated circulating levels of proinflammatory cytokines.

The role of advanced glycation end-products (AGEs) may be particularly important and is the focus of much current research. AGEs are complex carbohydrate structures formed by nonenzymatic glycosylation between reducing sugars and free amino groups on proteins. AGEs and their precursors accumulate in aging and in patients with diabetes mellitus because of increased production. AGE-modified proteins are presumed to contribute to the development of atherosclerosis and complications of diabetes, including nephropathy, neuropathy, retinopathy, and cataracts. In uremia, AGEs accumulate because of decreased removal, as dialysis does not clear AGE-modified proteins as well as does a functioning kidney. AGE-modified beta<sub>2</sub>-microglobulin is a major component of the amyloid deposits and may play a primary role in the pathogenesis of beta<sub>2</sub> microglobulin amyloidosis. Recent research indicates that AGE-modified beta<sub>2</sub>-microglobulin may interfere with type I collagen synthesis.

Because the condition occasionally occurs in persons with chronic renal disease who have not yet started dialysis, it is not a consequence of dialysis alone. However, factors related to the dialysis prescription may contribute to its development. For instance, the type of dialysis membrane used may affect beta<sub>2</sub>-microglobulin production and clearance.

Older age appears to be important in the development of beta<sub>2</sub>-microglobulin amyloidosis. A 75-year-old patient may develop the condition within 3 to 4 years after beginning dialysis, whereas a patient who is 25 years old

**Nearly all dialysis patients develop the disease after 13 years**



at the beginning of dialysis may not develop it for 8 years or longer.

## ■ DIAGNOSIS

The diagnosis of beta<sub>2</sub>-microglobulin amyloidosis is suggested primarily by the characteristic triad noted earlier: shoulder pain, carpal tunnel syndrome, and flexor tendon deposits in the hand. Radiographic findings corroborate the diagnosis (FIGURE 2).

Ultrasonography of the shoulder provides a relatively sensitive and highly specific adjunct to the clinical diagnosis if it reveals either of two characteristic changes:

- Rotator cuff thickness greater than 8 mm
- Echogenic pads between muscles of the rotator cuff.


However, the gold standard for diagnosis is to identify beta<sub>2</sub>-microglobulin amyloid by Congo red and immunohistochemical staining in biopsy specimens or in centrifuged synovial fluid sediments.

## ■ TREATMENT

At present, only renal transplantation can slow or halt the progression of beta<sub>2</sub>-microglobulin amyloidosis. However, the disease does not appear to regress after renal transplantation.

Medical therapies, such as NSAIDs and

glucocorticoids, may decrease the pain caused by this condition, but do not alter the disease course. Surgical procedures can be performed to remove large amyloid deposits and to replace joints that have been damaged by these deposits.

Future interventions, such as inhibitors of AGE formation, might address biologic processes involved in the pathogenesis of beta<sub>2</sub>-microglobulin amyloidosis to prevent its occurrence and permit amyloid deposits to regress. 

## ■ SUGGESTED READING

**Hou FF, Chertow GM, Kay J, et al.** Interaction between beta<sub>2</sub>-microglobulin and advanced glycation end products in the development of dialysis-related amyloidosis. *Kidney Int* 1997; 51:1514-1519.

**Jadoul M, Garbar C, Vanholder R, et al.** Prevalence of histological beta<sub>2</sub>-microglobulin amyloidosis in CAPD patients on hemodialysis. *Kidney Int* 1998; 54:956-959.

**Jimenez RE, Price DA, Pinkus GS, et al.** Development of gastrointestinal beta<sub>2</sub>-microglobulin amyloidosis correlates with time on dialysis. *Am J Surg Pathol* 1998; 22:729-735.

**Kay J.** beta<sub>2</sub>-microglobulin amyloidosis. *Amyloid: Int J Expt Clin Invest* 1997; 4:187-211.

**Kay J, Benson CB, Lester S, et al.** Utility of high resolution ultrasound for the diagnosis of dialysis-related amyloidosis. *Arthritis Rheum* 1992; 35:926-932.

**Miyata T, Oda O, Inaga R, et al.** beta<sub>2</sub>-microglobulin modified with advanced glycation end products is a major component of hemodialysis-associated amyloidosis. *J Clin Invest* 1993; 92:1243-1252.

# We Welcome Your Letters

WE ENCOURAGE YOU TO WRITE, either to respond to an article published in the *Journal* or to address a clinical issue of importance to you. You may submit letters by mail, fax, or e-mail.

### MAILING ADDRESS

Letters to the Editor  
*Cleveland Clinic Journal of Medicine*  
9500 Euclid Ave., EE37  
Cleveland, OH 44195

### FAX

216.444.9385

### E-MAIL

ccjm@cesmtp.ccf.org

Please be sure to include your full address, phone number, fax number, and e-mail address. Please write concisely, as space is limited. Letters may be edited for style and length. We cannot return materials sent. Submission of a letter constitutes permission for the *Cleveland Clinic Journal of Medicine* to publish it in various editions and forms.

DEDICATED TO LIFELONG LEARNING  
**CLEVELAND  
CLINIC  
JOURNAL OF  
MEDICINE**

