



# Angioedema: Frightening and frustrating

**WILLIAM O. WAGNER, MD**

Head, Section of Allergy and Immunology, Cleveland Clinic

## ■ ABSTRACT

Angioedema can have a variety of causes, including drug reactions, food allergies, and C1 esterase inhibitor deficiency, but many cases are idiopathic. Swelling usually subsides in days if the offending agent can be removed. The throat is often involved, but few patients actually require intubation.

**A** 43-YEAR-OLD MAN awoke with slight swelling of the left side of his lower lip, which progressed as the morning went on. He had taken ibuprofen before going to bed, but had never had a reaction to it before.

The patient had no history of hives, suspected food allergies, abdominal pain, or dyspnea. However, he had experienced a similar episode 12 years previously. At that time, he had not taken any nonsteroidal anti-inflammatory drugs (NSAIDs). The swelling had involved his lips, hands, and feet, and it resolved in a few days without treatment. He had no family history of angioedema.

The physical examination was normal except for nontender edema of the lower lip. The complete blood count, C4 level, liver enzyme levels, sedimentation rate, and C-reactive protein levels were normal. The patient was treated with H1 and H2 antihistamines until the angioedema resolved, which was in 48 hours.

## ■ ANGIOEDEMA: SIGNS AND SYMPTOMS

The dramatic swelling of angioedema commonly involves the eyelids, lips, tongue, throat, hands, and feet. Usually, it occurs in

combination with urticaria. The swelling is painless but is often preceded by a tingling paresthesia of the skin. It develops in minutes to hours and resolves spontaneously in hours to a few days. Swelling that fails to resolve within 4 days is not likely to be angioedema.

Occasionally, patients have chest pain due to swelling of the wall of the esophagus. More commonly, they have abdominal pain due to swelling of the bowel wall.

Patients are often frightened by the dramatic swelling, in which the eyelids may be swollen shut or the lips three times normal size. However, the only real danger is when the throat is involved. If breathing is impaired, the patient needs to go to a medical facility where intubation would be possible. Fortunately, airway compromise to a point requiring intubation almost never occurs among outpatients, although the throat is often involved, the voice is often affected, and there is often temporary dysphagia. Postoperative patients with angioedema following extubation may need to be reintubated in the recovery room.

Angioedema often is frustrating to patient and physician alike, especially when it recurs and the cause is not evident.

## ■ CAUSES OF ANGIOEDEMA

Acute angioedema and urticaria may be caused by an allergic reaction. However, chronic urticaria and angioedema are rarely of allergic etiology.

### Drug reactions

Urticaria and angioedema developing within an hour of the first dose of a new medicine strongly suggest a true allergy, especially if the

**The only real  
danger is  
airway  
obstruction**

medicine (eg, penicillin) is known to cause allergic reactions mediated by IgE.

Penicillins and other beta lactam antibiotics are among the drugs most frequently causing true allergic drug reactions. These drugs are of low molecular weight, but they bind to serum proteins, creating a complete antigen. Other drugs likely to cause allergic reactions are themselves proteins, such as protamine for reversal of heparin anticoagulation.

In some cases, drugs may falsely be blamed for hives or angioedema. If a patient claims antibiotics of many different classes cause hives or angioedema after a few days, consider that the infection may be the trigger, rather than the antibiotic. The patient with angioedema of the mouth after dental work usually has not reacted to the local anesthetic, but may have reacted to the latex gloves or to the trauma. Angioedema patients develop exaggerated swelling in response to minor trauma.

Some drugs (eg, sulfa and cefaclor) can cause an immune reaction that includes hives, fever, and joint pain after days or weeks. These late reactions are called “serum sickness” type reactions because they follow a time course similar to serum sickness and are thought to involve similar non-IgE immune mechanisms. NSAIDs and angiotensin-converting enzyme (ACE) inhibitors can induce angioedema promptly or after prolonged therapy, but these reactions are not mediated by IgE, and most reactions to NSAIDs usually occur within minutes to an hour.

No skin or blood test is available to identify patients at risk for angioedema from NSAIDs or ACE inhibitors. In the case presented, the previous episode of angioedema unrelated to an NSAID and the passage of several hours between the dose of ibuprofen and the peak of the angioedema weakens the likelihood of a causal link. An oral challenge could resolve the issue if NSAID treatment is needed.

### Food allergies

Patients with a swollen mouth or throat are often concerned about food allergy. Nuts, peanuts, fish, and shellfish account for the vast majority of true food allergies in adults.

True food allergies produce prompt and consistent reactions. Food skin testing can help confirm or eliminate patients' concerns in this area.

### C1 esterase inhibitor deficiency

Congenital or acquired deficiency of C1 esterase inhibitor is a rare but well-recognized cause of angioedema. This deficiency does not cause hives; therefore, patients with a history of angioedema not accompanied by hives need to be screened for this deficiency. Lack of the inhibitor results in uncontrolled initiation of the complement cascade. C4 levels are consistently low, even between attacks. C4 is the screening test of choice for hereditary or acquired deficiency of C1 esterase. The acquired form of deficiency is seen in late decades of life and is associated with low-grade B lymphocyte malignancies.

### Other causes

Angioedema represents an inflammatory response, and anything that triggers an immune response may contribute to a flare of urticaria or angioedema. These causes include viral infections, including herpes infections. In addition, evidence is accumulating that autoantibodies may contribute to the common “idiopathic” cases.

### Differential diagnosis

The differential diagnosis of angioedema includes:

- Cellulitis (painful)
- Hypothyroidism (develops slowly and persists)
- Superior vena cava syndrome (often in the setting of malignancy and an indwelling catheter)
- Granulomatous cheilitis (lips persistently indurated).

### TREATMENT

Angioedema is the result of leakage of fluid out of blood vessels beneath the skin. Once the fluid is in the subcutaneous tissue, time is required to reabsorb the fluid. Intervention can only hope to prevent additional leakage. Once the swelling has resolved, no further treatment of that episode is needed.

## C1 esterase inhibitor deficiency causes angioedema without hives

The easiest cases are the ones in which the episodes cease after a drug is stopped. The most frustrating cases are the ones in which episodes recur and there is no evidence of an external trigger for the angioedema and no treatable underlying disease.

**Antihistamines.** If angioedema is recurring as frequently as once a week, daily treatment with a combination of H1 and H2 antihistamines may help reduce the frequency and severity of attacks. Preventive antihistamine therapy is taken for weeks or months, until there seems to be a remission. Because of the prolonged therapy, the H1 antihistamine is usually a nonsedating one (astemizole, loratadine, or fexofenadine) or a mildly sedating one (cetirizine). The addition of an H2 antihistamine such as ranitidine may add to the benefit of the H1 antihistamine.

Unfortunately, antihistamines do not seem to be as effective in altering angioedema as they are in reducing hives, probably because inflammatory mediators other than histamine are involved.

**Corticosteroids** are often prescribed for severe episodes of angioedema, but it is not clear that they alter the course of the episode. If corticosteroids are used at all, they should be stopped as soon as the angioedema has resolved. Corticosteroids have too many side effects to use them to prevent angioedema.

**Androgens.** The most successful treatment for angioedema is in cases associated with deficiency of C1 esterase inhibitor. In such cases, androgen therapy can increase the levels of C1 esterase inhibitor, often ending or greatly reducing the severity of angioedema attacks.

#### ■ SUGGESTED READING

**Acker CG, Greenberg A.** Angioedema induced by the angiotensin II blocker losartan [letter]. *N Engl J Med* 1995; 333:1572.

**Bain BJ, Catovsky D, Ewan PW.** Acquired angioedema as the presenting feature of lymphoproliferative disorders of mature B lymphocytes. *Cancer* 1993; 72:3318–3322.

**Brickman CM, Tsokos GC, Balow JE, et al.** Immunoregulatory disorders associated with hereditary angioedema. I. Clinical manifestations of autoimmune disease. *J Allergy Clin Immunol* 1986; 77:749–757.

**Cicardi M, Agostoni A.** Hereditary angioedema [editorial]. *N*

*Engl J Med* 1996; 334:1666–1667.

**Donaldson VH, Evans RR.** A biochemical abnormality in hereditary angioneurotic edema. *Am J Med* 1963; 35:37.

**Frank MM.** C1 esterase inhibitor: clinical clues to the pathophysiology of angioedema [editorial]. *J Allergy Clin Immunol* 1986; 78:848–850.

**Hedner T, Samuelsson O, Lindholm L, Andren L, Wilholm BE.** Precipitation of angioedema by antihypertensive drugs. *J Hypertens* 1991; 9:S360–S361.

**Jain M, Armstrong L, Hall J.** Predisposition to and late onset of upper airway obstruction following angiotensin-converting enzyme inhibitor therapy. *Chest* 1992; 102:871–874.

**McElligott S, Perloth M, Raish L.** Angioedema after substituting lisinopril for captopril [letter]. *Ann Intern Med* 1992; 116:426.

**Melamed J, Alper CA, Cicardi M, Rosen FS.** The metabolism of C1 inhibitor and C1q in patients with acquired C1-inhibitor deficiency. *J Allergy Clin Immunol* 1986; 77:322–326.

**Nielsen EW, Gran JT, Straume B, Mellbye OJ, Johansen HT, Mollnes TE.** Hereditary angioedema: new clinical and autoimmune screening, complement, and kallikrein-kinin analyses. *J Intern Med* 1996; 239:119–130.

**Orfan N, Patterson R, Dykewicz MS.** Severe angioedema related to ACE inhibitors in patients with a history of idiopathic angioedema. *JAMA* 1990; 264:1287–1289.

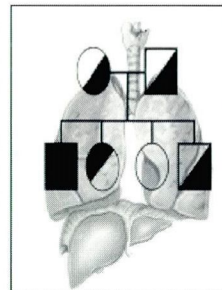
**Sheffer AL, Fearon DR, Austen KF.** A decade of management with stanazolol (Winstrol). *J Allergy Clin Immunol* 1987; 89:855–860.

## ANNOUNCING

### The Alpha One Foundation Research Registry for individuals diagnosed with **Alpha<sub>1</sub>-Antitrypsin Deficiency**

*Enroll your patients in the Alpha One Research Registry, the only one of its type in the United States.*

*Patients and their physician will have an opportunity to participate in clinical trials and research protocols to develop new therapies.*



*All data is confidential and managed by the University of Miami School of Medicine Department of Epidemiology and Public Health*

**For Patient Enrollment  
Call 1-888-825-7421 Ext.6**

*Visit The Alpha One Foundation on the Web at [www.alphaone.org](http://www.alphaone.org) or E-mail us at [registry@alphaone.org](mailto:registry@alphaone.org)*