

**OUSSAMA WAZNI, MD**Department of General Internal  
Medicine, Cleveland Clinic**HITINDER GURM, MBBS**Department of General Internal  
Medicine, Cleveland Clinic**CRAIG NIELSEN, MD**Department of General Internal  
Medicine, Cleveland Clinic

# A 64-year-old woman with fever and acute polyarthriti

**A** 64-YEAR-OLD WOMAN presented to the emergency department with worsening low back pain. She also had swelling and pain in the joints of both hands, which began 2 days earlier. She had had no antecedent urogenital or gastrointestinal symptoms.

The patient had undergone a laminectomy 20 years previously. She said she had gone to other local emergency departments on numerous occasions because of chronic low back pain and was usually treated with narcotic analgesics. She did not have a regular primary care physician. The rest of the review of systems and past medical history was negative.

The patient said she takes nifedipine for hypertension and oral codeine for pain. She stated that she does not use tobacco, alcohol, or illicit drugs.

## Physical examination

The patient's temperature was 101.7°F (38.7°C), pulse rate 130 per minute, blood pressure 110/60 mm Hg, and respiratory rate 26 per minute.

On examination, the patient had cellulitis of the left arm and inflammation of the left sternoclavicular joint, the proximal interphalangeal joint, and the distal interphalangeal joint of the right fifth finger and the proximal interphalangeal joint of the left third finger. There were puncture marks on both arms and hands. The patient attributed these to unsuccessful attempts at gaining intravenous access in emergency departments visited previously.

A grade 3/6 holosystolic murmur was heard on chest examination. The urinary bladder was distended. Percussion of the lower spine elicited mild tenderness. The right leg

was slightly weaker than the left, with a muscle strength of 4 on a scale of 5. Both legs had normal range of motion.

Laboratory tests disclosed a white blood cell count of  $19.6 \times 10^9/L$  with 95% neutrophils, and a serum creatinine level of 1.6 mg/dL. A urinalysis revealed more than 25 white blood cells per high-power field. Blood cultures and urine cultures were obtained.

## DIFFERENTIAL DIAGNOSIS

**1** What is the most likely cause of this patient's polyarticular arthritis?

- Gout
- Pseudogout
- Reactive arthritis
- Rheumatoid arthritis
- Septic arthritis

**Gouty arthritis** is usually monoarticular, although polyarticular onsets may be more common in women. Episodes are very painful and associated with low-grade fever. Involvement of the sacroiliac, sternomanubrial, and spinal joints is very rare.

**Pseudogout** most commonly affects the knee. Other sites include the wrists, shoulders, ankles, elbows, and hands. Fever can also be present.

**Reactive arthritis.** Patients with reactive arthritis present with acute-onset musculoskeletal symptoms. The joints are very painful, and the arthritis is usually additive, with more joints being involved over time. There is often a history of antecedent infection. Other manifestations include urogenital lesions, which may reflect either an infection or a reactive inflammatory process.



**Rheumatoid arthritis** is usually chronic, although 10% of patients present with rapidly developing polyarthritis. An abrupt onset is more common in elderly patients.<sup>1</sup> In most cases, joint involvement is symmetric.

**Septic arthritis** is usually associated with fever. In most cases it is acquired hematogenously, although trauma to a joint can allow bacteria to enter directly. Only 10% to 19% of adults with bacterial arthritis have polyarticular involvement. Risk factors include but are not limited to host phagocytic and immunologic defects, direct penetration (eg, due to intravenous drug abuse or puncture wounds), and joint damage due to chronic arthritis or prosthetic-joint surgery.<sup>2</sup>

In our patient the most likely diagnosis was septic arthritis.

#### ■ EVALUATION

**2** What should be the next procedure or test?

- A roentgenogram of the hands
- Aspiration of the affected joints
- Measurement of the erythrocyte sedimentation rate
- A serologic test for rheumatoid factor

**Aspiration** of the affected joints should be the first course of action in a patient with fever and polyarthritis. The procedure should be undertaken promptly: delay in treatment is the best predictor of poor outcome in patients with septic arthritis.

The studies of the synovial fluid of highest priority and greatest diagnostic yield are examination by microscopy for crystals, Gram stain, and bacterial cultures.<sup>3</sup> Infection in a joint with crystalline deposition can lead to crystal shedding and, therefore, to synovitis due to both crystals and microorganisms.<sup>2</sup> A Gram stain identifies bacteria in 50% to 75% of cases of septic arthritis, whereas more than 90% of cultures are positive.<sup>2</sup> If all three studies are negative, then other diagnoses such as viral, reactive, or systemic arthritis should be considered, and **serologic tests** for rheumatoid factor or viral infections may be appropriate.

The white blood cell count in synovial fluid is also useful. Normally, it should be less

than  $2.0 \times 10^9/L$ , but it can range from 2.0 to 50.0 in inflammatory conditions, and greater than 50.0 in infections.

**Roentgenograms** have limited diagnostic value early in the course of septic arthritis or any rheumatologic disease, since it may take 2 to 4 weeks for rarefaction and erosion of subchondral bone to become evident.<sup>3</sup> The **erythrocyte sedimentation rate** is a nonspecific marker, as it can be elevated in all the inflammatory arthritides.

#### Case continued

Studies of aspirated synovial fluid from the hand joints in this patient revealed no crystals. However, many Gram-positive cocci in clusters were seen, and the white blood cell count in the synovial fluid was  $70.0 \times 10^9/L$ .

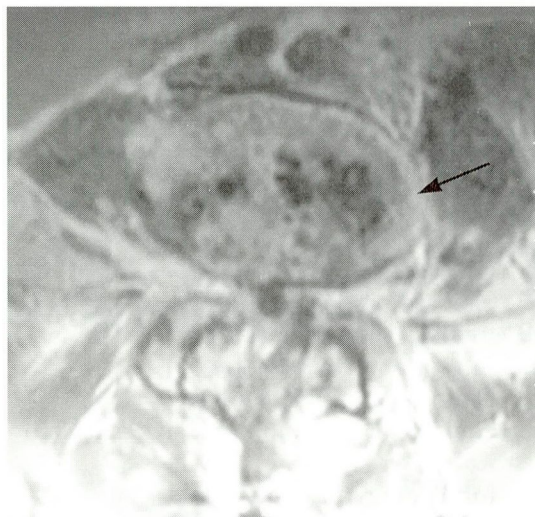
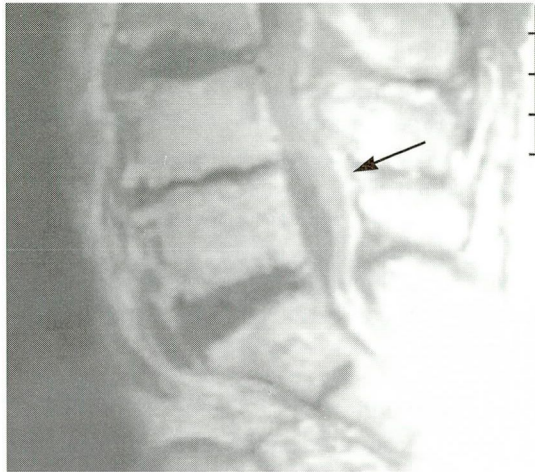
#### ■ THERAPY

**3** How would you treat this case of septic arthritis?

- Oral antibiotics
- Intravenous antibiotics
- Intra-articular antibiotics
- Drainage and articular rest
- Oral antibiotics, drainage, and articular rest
- Intravenous antibiotics, intra-articular antibiotics, drainage, and articular rest
- Intravenous antibiotics, drainage, and articular rest

The best treatment would be the combination of intravenous antibiotics, drainage, and articular rest. The initial choice of antibiotics should be based on the results of the Gram stain. If the Gram stain reveals no bacteria but the synovial fluid is purulent, antibiotics should still be started immediately, the choice being dictated by the clinical setting. For example, an elderly patient with signs of sepsis should receive broad antibiotic coverage for *Staphylococcus aureus*, streptococci, and *Escherichia coli*. In contrast, a young, healthy, sexually active patient should receive coverage for gonococci. The intravenous combination of a third-generation cephalosporin and oxacillin or vancomycin would be appropriate initial therapy in both cases.

**Prompt arthrocentesis is key in acute arthritis**



**FIGURE 1.** The patient's magnetic resonance imaging scans, with gadolinium contrast. **Top,** sagittal view shows a noncompressive epidural abscess (arrow). **Bottom,** axial view shows inflammation of the L5-S1 disc (arrow).

To treat  
septic arthritis,  
use IV  
antibiotics,  
drainage, and  
joint rest

Intravenous antibiotics achieve adequate bactericidal levels in inflamed synovial effusions. Therefore, there is no need for intra-articular injection of antibiotics.

Closed needle aspiration and drainage must be attempted, except in infected hips, shoulders, and prosthetic joints, where open drainage is advisable.

During the acute course of the infection, the joint should be kept in an optimal functional position by using a splint or a cast along with occasional passive exercises. Active exercises should be undertaken once the pain starts to subside.<sup>3</sup>

## HOSPITAL COURSE

Vancomycin was started empirically to provide broad-spectrum coverage against Gram-positive organisms, and the affected joints were drained. The patient's heart murmur raised concern about probable endocarditis and prompted a transthoracic echocardiogram, which revealed mitral regurgitation of grade 2–3 on a scale of 4 but no mitral vegetations. There were echodensities on the aortic valve consistent with either vegetations or calcifications. Rifampin and gentamicin were added to the regimen to treat probable endocarditis.

Cultures of fluid aspirated from the affected joints, blood, and urine all grew methicillin-sensitive *S aureus*. To avoid overuse of vancomycin and emergence of vancomycin-resistant organisms, vancomycin was replaced by oxacillin, which has activity similar to that of methicillin.

Because the patient's back pain persisted, she underwent a magnetic resonance imaging (MRI) scan of the back. This revealed inflammation of the L5–S1 disc and a noncompressive epidural abscess (FIGURE 1). Blood cultures became sterile on the third day in the hospital.

The cause of this patient's sepsis remained elusive until 2 days before discharge, when a family member disclosed that the patient was in fact an active intravenous drug abuser. In retrospect this explained the suspicious needle tracks the patient had on both arms. In addition, the patient's frequent visits to local emergency departments requesting narcotics for back pain could have raised suspicion of drug-seeking behavior.

The patient was discharged to a skilled nursing facility 11 days after admission for a prolonged course of antibiotics and rehabilitation.

## REFERENCES

1. Kavanaugh A. Rheumatoid arthritis in the elderly: Is it a different disease? *Am J Med* 1997; 103(6a):405–485.
2. Goldenberg D, Reed J. Bacterial arthritis. *N Engl J Med* 1985; 312:764–771.
3. Pinals R. Polyarthrititis and fever. *N Engl J Med* 1994; 330:769–774.

**ADDRESS:** Craig Nielsen, MD, Department of Internal Medicine, A91, The Cleveland Clinic Foundation, 9500 Euclid Avenue, Cleveland, OH 44195, e-mail nielsenccf@ccf.org.