



DEBABRATA MUKHERJEE, MD

Department of Cardiology, Cleveland Clinic

STEPHEN G. ELLIS, MD

Director, Sones Cardiac Catheterization
Laboratories, Department of Cardiology,
Cleveland Clinic

‘Rescue’ angioplasty for failed thrombolysis

ABSTRACT

Early restoration of patency of the infarct-related artery is a universally accepted goal in the treatment of acute myocardial infarction. However, even with the most successful fibrinolytic regimen only approximately 50% of patients achieve restoration of normal flow at 90 minutes. “Rescue” angioplasty, the mechanical reopening of an infarct-related artery after unsuccessful fibrinolytic therapy, appears to be beneficial.

KEY POINTS

Fibrinolysis is the most commonly used method for recanalization of the infarct-related artery.

Improved coronary flow correlates with better clinical outcome.

Patients with evolving chest pain and ST-segment elevation that persist for 90 minutes following fibrinolysis are candidates for emergent angiography and, if the infarct-related artery is occluded, rescue angioplasty.

Patients with cardiogenic shock benefit from early revascularization with angioplasty or coronary artery bypass grafting.

CONFRONTED WITH the classic dilemma of whether to treat ST-elevation myocardial infarction (MI) with fibrinolytic drugs (which are readily available but fail to restore complete perfusion in up to 50% of cases) or primary angioplasty (which produces better results but is not widely available and may introduce unacceptable delays), physicians are increasingly taking a third, empiric course: start the fibrinolytic drugs right away and then consider “rescue” angioplasty for the sizeable group in whom fibrinolysis fails.

Unfortunately, data are few and firm recommendations are lacking. Unanswered are questions about which patient subgroups may particularly benefit from rescue angioplasty, which markers of failure of reperfusion we should rely on, what is the optimum time window for performing rescue angioplasty, and what is the optimum adjuvant medical therapy.

Still, rescue angioplasty seems logical and, in the limited studies performed to date, appears beneficial. This paper reviews the evidence and presents our recommendations on this evolving topic.

THE DILEMMA IN BRIEF

In treating an acute MI, the goal is to restore the patency of the infarct-related artery quickly. The GUSTO-1 study¹ found that the more patients who achieved full reperfusion at 90 minutes (ie, grade 3 on the TIMI scale—TABLE 1), the lower the mortality rate at 30 days: 4.4% for patients with normal (TIMI grade 3) flow vs 8.9% for those with occluded arteries (TIMI grades 0 or 1), regardless of subsequent therapeutic strategy

TABLE 1

Flow nomenclature in the Thrombolysis in Myocardial Infarction (TIMI) study

GRADE	CRITERIA
0	Contrast does not penetrate beyond the clot
1	Contrast penetrates beyond vessel occlusion but does not fill the vessel completely
2	Contrast fills the vessel completely, but slower than in adjacent normal vessels
3	Normal brisk flow

ADAPTED FROM THE TIMI STUDY GROUP. SPECIAL REPORT. THE THROMBOLYSIS IN MYOCARDIAL INFARCTION (TIMI) TRIAL. PHASE I FINDINGS. N ENGL J MED 1985; 312: 932-936.

($P = .009$). Normal flow at 90 minutes also predicted a higher ejection fraction and lower end-systolic volume than did impaired flow.

Either fibrinolysis or angioplasty can be used as first-line treatment, but most patients receive fibrinolysis simply because it is more available.

But fibrinolysis often fails. The GUSTO-1¹¹ study used the most successful fibrinolytic regimen devised to date—tissue plasminogen activator (t-PA, also called alteplase) given on an accelerated basis—and only 54% of the patients achieved TIMI grade 3 flow.

Therefore, approximately half of patients who undergo fibrinolysis might potentially be candidates for additional therapy to recanalize the occluded vessel and optimize coronary flow. The most attractive therapeutic option in these patients is angioplasty (the other options being continued medical therapy or, in a select subgroup, coronary artery bypass surgery).

■ EVIDENCE IN SUPPORT OF RESCUE ANGIOPLASTY

In theory, rescue angioplasty should improve flow, salvage ischemic myocardium, and “definitively” treat the underlying lesion, thereby preventing recurrent ischemia. Actual data from clinical trials are somewhat sparse, but on the whole they support this practice.

Observational studies

In a large observational study from one center,² 257 patients with acute MI underwent angiography 90 minutes after the onset of fibrinolytic therapy, and rescue angioplasty was performed in patients if fibrinolysis had failed. In this study rescue and direct angioplasty provided effective early reperfusion to patients in whom thrombolysis failed.

In the TAMI phase 5 study,³ patients who underwent angiography (and angioplasty if indicated) 90 minutes after starting fibrinolysis had better regional wall motion in the infarct zone and fewer adverse events (death, stroke, reinfarction, heart failure, or recurrent ischemia) than did patients who underwent angiography 5 to 10 days later (55% vs 67%, $P = .004$).

Randomized clinical trials

Randomized studies of rescue angioplasty are hard to perform owing to difficulty in recruitment: cardiologists generally believe that patients with failed fibrinolysis *should* undergo angioplasty and are therefore reluctant to let their patients be randomized to undergo conservative therapy.

Nevertheless, four small randomized trials of rescue angioplasty vs conservative treatment have been performed.⁴⁻⁷ The first included only 28 patients and found no significant differences in clinical outcomes between the two treatment strategies.⁵ The second was considerably larger, with 151 patients with anterior MIs, and showed a trend towards less severe heart failure in the rescue angioplasty group.⁴ Recent preliminary reports from the other two trials^{6,7} showed modest trends in reduction of 30-day composite end points of death, reinfarction, and heart failure with rescue angioplasty.

Given these data, it would seem logical to refer patients for urgent angiography and possible angioplasty if:

- Facilities are available
- The patient has a moderate or large MI manifest electrocardiographically or by hemodynamic instability
- The patient appears not to have achieved adequate reperfusion by 75 to 120 minutes after the start of fibrinolytic therapy.

Nearly half of MI patients might be candidates for rescue angioplasty

■ PRACTICAL QUESTIONS AWAITING DEFINITIVE ANSWERS

A number of practical questions about rescue angioplasty await definitive answers.

How to tell that fibrinolysis has failed?

After giving a fibrinolytic drug, how does one know whether the occluded artery has opened without resorting to angiography?

Resolution of ST elevation. At present, this determination—one of the most difficult that cardiologists must make when treating an acute MI—is based entirely on whether the symptoms and ST-segment elevation persist or resolve.

ST elevation is not an ideal marker, however. If ST elevation resolves quickly and completely we can be confident that coronary flow has been restored.⁸ But on the other hand, if ST elevation does not resolve, we cannot assume that flow has not been restored: absence of ST resolution is fairly insensitive.

In the INJECT study,⁹ which included 1,398 patients, the greater the degree of ST elevation resolution at 3 hours, the lower the mortality rate at 35 days: 2.5% for patients with more than 70% resolution, compared with 4.3% in patients with 30% to 70% resolution, and 17.5% in patients with less than 30% resolution ($P < .0001$).

However, other reports were less optimistic about the diagnostic accuracy of ST-segment monitoring. In the GUSTO-1 study,¹⁰ although more patients who received t-PA had patent arteries at 90 minutes than did patients who received streptokinase, their ST-segment elevation did not resolve any faster, casting doubt on the usefulness of this marker.

Other markers of reperfusion. No other reliable markers of reperfusion have been thoroughly validated, but newer markers and techniques under study include blood levels of cardiac troponin T,¹¹ continuous multiple ST-segment monitoring, myocardial contrast echocardiography, Doppler flow wire studies, magnetic resonance imaging, and nuclear scintigraphy.

Recommendations. Patients with evolving chest pain and ST-segment elevation that

persist for 90 minutes after the start of fibrinolysis are candidates for emergent angiography and, if the infarct-related artery is occluded, rescue angioplasty.

What patient subgroups might benefit?

In their current guidelines for managing acute MI, the American College of Cardiology and the American Heart Association rate the evidence in support of different therapies in different situations.¹² According to these guidelines, the evidence for performing angiography early on is as follows:

- **Cardiogenic shock or persistent hemodynamic instability:** class IIa (ie, the weight of evidence or opinion is in favor of usefulness or efficacy of angiography). The SHOCK trial demonstrated that in patients with cardiogenic shock, emergency revascularization (angioplasty or coronary artery bypass grafting) significantly improved survival at 6 months.¹³ The investigators concluded that early revascularization should be strongly considered for patients with acute MI complicated by cardiogenic shock.

- **Evolving large or anterior infarction after thrombolytic treatment when it is believed that reperfusion has not occurred and rescue angioplasty is planned:** class IIb (usefulness or efficacy of angiography is less well explained by evidence or opinion).

Still, the large reperfusion trials suggest that the greater the initial risk, the greater the benefit of primary reperfusion therapy in terms of reduced mortality—patients with large infarcts benefit the most. In fact, timely reperfusion therapy with fibrinolysis or angioplasty now allows patients to survive extensive infarctions that previously would have been uniformly fatal.¹⁴ The same principle should hold true for rescue angioplasty—the absolute risk reduction should be greater in patients with a large myocardial perfusion territory at risk than in those with a small one.

- **Marginal hemodynamic status but not actual cardiogenic shock when standard management (optimizing filling pressures) does not result in improvement:** class IIb.

FIGURE 1 shows a management algorithm that defines how candidates for early angiography and rescue angioplasty can be identified.

Persistent chest pain and ST elevation are still the best markers of failed reperfusion



Management algorithm for 'rescue' angioplasty

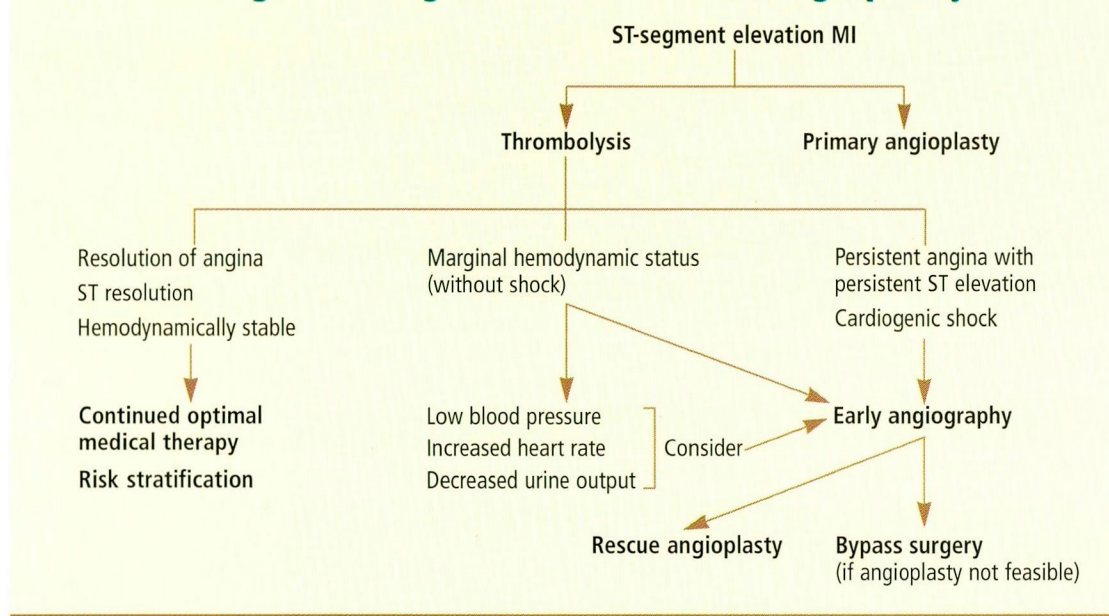


FIGURE 1

What is the optimum time window?

Another critical issue is the time window to perform rescue angioplasty. Both the beginning and end of this window pose clinical dilemmas. On one hand, patency rates after fibrinolysis increase over 24 hours,¹ but on the other hand, there is ample evidence that patients fare better the earlier brisk flow is restored. Also, the substantial “door-to-balloon” time necessary to prepare for angioplasty has to be taken into account. Thus, if rescue angioplasty is an option, the decision should ideally be made within 90 minutes of beginning fibrinolysis.

Which arteries need intervention?

No specific strategy has been proposed that would fundamentally distinguish rescue angioplasty from other types of emergency angioplasty such as primary angioplasty for MI. Usually, only the infarct-causing lesion is treated, and no “complete revascularization” is attempted during the acute intervention.

Should patients receive stents and glycoprotein IIb/IIIa inhibitors?

Stents and the platelet glycoprotein (GP) IIb/IIIa inhibitors are increasingly being used in acute coronary syndromes. Preliminary

data from the randomized use of stents and the GP IIb/IIIa inhibitor abciximab in primary angioplasty in MI show a significant advantage in terms of adverse events in patients receiving these new adjunctive treatments.^{15–17} These results should encourage the use of stents and abciximab in rescue angioplasty as well, which, when it fails, has an extremely high rate of adverse events, including death.

In the GUSTO-3¹⁸ trial, 392 patients underwent angioplasty a median of 3.5 hours after failed fibrinolytic therapy with reteplase or alteplase for acute MI. The use of abciximab for rescue angioplasty after clinically failed fibrinolysis resulted in trends toward a lower mortality rate at 30 days. Use of stents in rescue angioplasty also has shown significant benefit.¹⁹

Should the fibrinolytic regimen be modified if rescue angioplasty is planned?

A serious concern about rescue angioplasty is whether patients who have received fibrinolytics would have an unacceptably high risk of bleeding, especially if they also receive GP IIb/IIIa inhibitors.

Accordingly, an evolving concept is “facilitated angioplasty,” ie, giving fibrinolyt-

Ideally, one should decide on rescue angioplasty within 90 minutes of starting fibrinolysis

ics and GP IIb/IIIa inhibitors in reduced doses in patients presenting with ST-segment elevation MI, and then performing angioplasty. Also, the addition of GP IIb/IIIa inhibitors to fibrinolytics alone without angioplasty may also significantly increase the TIMI 3 flow in infarct-related arteries.^{20,21}

Herrmann et al²² reported that giving the combination of abciximab and reduced-dose reteplase before angioplasty was safe, facilitated TIMI grade 3 flow, and improved outcome in acute MI. Similarly, L'Allier et al²³ reported that a strategy of immediate angioplasty with ongoing low-dose fibrinolysis and platelet inhibition appears to be safe and effective.²³

Recently the PACT investigators²⁴ randomized 606 acute MI patients to receive either a 50-mg bolus of t-PA (a low dose) or placebo; all patients then underwent angiography and, if needed, angioplasty. On arrival in the catheterization laboratory, 61% of the patients who received t-PA had TIMI grade 2 or 3 flow, compared with 34% with placebo ($P = .001$). Left ventricular ejection fractions were no higher in the t-PA group than in the placebo group, but they were higher in patients with TIMI grade 3 flow compared with those with lesser grades.

THE AUTHORS' APPROACH

Up to half of patients with acute MI do not achieve reperfusion despite fibrinolytic therapy. In these patients, rescue angioplasty appears to be beneficial in terms of clinical outcomes, although a clear-cut superiority has not been unequivocally proven because of the difficulties in enrolling these patients into prospective studies.

Nevertheless, early mechanical intervention for patients with failed thrombolysis and moderate-to-large infarctions appears to be beneficial. In particular, the effect of contemporary aggressive adjunctive medical therapy (abciximab) and of stenting may be reasonably expected to support and extend the role of rescue angioplasty, for example, to patients with TIMI 2 flow in the infarct vessel at angiography.

Thus, clinical wisdom indicates that angiography and rescue angioplasty should be

strongly considered if fibrinolysis is clinically thought to have failed, in a time window up to 12 hours (and possibly longer) after onset of infarction, and in particular if the electrocardiogram or hemodynamics indicate that the infarct is large.

REFERENCES

1. The GUSTO Angiographic Investigators. The effects of tissue plasminogen activator, streptokinase, or both on coronary-artery patency, ventricular function, and survival after acute myocardial infarction. *N Engl J Med* 1993; 329:1615–1622.
2. Juliard JM, Himbert D, Golmard JL, et al. Can we provide reperfusion therapy to all unselected patients admitted with acute myocardial infarction? *J Am Coll Cardiol* 1997; 30:157–164.
3. Califf RM, Topol EJ, Stack RS, et al. Evaluation of combination thrombolytic therapy and timing of cardiac catheterization in acute myocardial infarction. Results of thrombolysis and angioplasty in myocardial infarction—phase 5 randomized trial. TAMI Study Group. *Circulation* 1991; 83:1543–1556.
4. Ellis SG, da Silva ER, Heyndrickx G, et al. Randomized comparison of rescue angioplasty with conservative management of patients with early failure of thrombolysis for acute anterior myocardial infarction. *Circulation* 1994; 90:2280–2284.
5. Belenkie I, Traboulsi M, Hall CA, et al. Rescue angioplasty during myocardial infarction has a beneficial effect on mortality: a tenable hypothesis. *Can J Cardiol* 1992; 8:357–362.
6. Bednár F, Widimský P, Groch L, Zelízko M, Aschermann M. Transport to primary PTCA in acute myocardial infarction complicated by acute heart failure. Results from the Prague study (national multicenter randomized study) [abstract]. *Eur Heart J* 1999; 20(Suppl):30.
7. Vermeer F, Ophuis AJ, Berg EJ, et al. Prospective randomized comparison between thrombolysis, rescue PTCA, and primary PTCA in patients with extensive myocardial infarction admitted to a hospital without PTCA facilities: a safety and feasibility study. *Heart* 1999; 82:426–431.
8. de Lemos J, Antman E, Gibson M, et al. Abciximab improves both epicardial flow and myocardial reperfusion in ST elevation myocardial infarction: A TIMI 14 analysis [abstract]. *Circulation* 1999; 100 (Suppl):I-649.
9. Schroder R, Wegscheider K, Schroder K, Dissmann R, Meyer-Sabellek W. Extent of early ST segment elevation resolution: a strong predictor of outcome in patients with acute myocardial infarction and a sensitive measure to compare thrombolytic regimens. A substudy of the International Joint Efficacy Comparison of Thrombolytics (INJECT) trial. *J Am Coll Cardiol* 1995; 26:1657–1664.
10. Langer A, Krucoff MW, Klootwijk P, et al. Noninvasive assessment of speed and stability of infarct-related artery reperfusion: results of the GUSTO ST segment monitoring study. Global Utilization of Streptokinase and Tissue Plasminogen Activator for Occluded Coronary Arteries. *J Am Coll Cardiol* 1995; 25:1552–1557.
11. Abe S, Arima S, Yamashita T, et al. Early assessment of reperfusion therapy using cardiac troponin T. *J Am Coll Cardiol* 1994; 23:1382–1389.
12. Scanlon PJ, Faxon DP, Audet AM, et al. ACC/AHA guidelines for coronary angiography: executive summary and recommendations. A report of the American College of

Consider rescue angioplasty especially in patients with large MIs



- Cardiology/American Heart Association Task Force on Practice Guidelines (Committee on Coronary Angiography) developed in collaboration with the Society for Cardiac Angiography and Interventions. *Circulation* 1999; 99:2345-2357.
13. Hochman JS, Sleeper LA, Webb JG, et al. Early revascularization in acute myocardial infarction complicated by cardiogenic shock. SHOCK Investigators. Should We Emergently Revascularize Occluded Coronaries for Cardiogenic Shock. *N Engl J Med* 1999; 341:625-634.
 14. McCallister BD Jr, Christian TF, Gersh BJ, Gibbons RJ. Prognosis of myocardial infarctions involving more than 40% of the left ventricle after acute reperfusion therapy. *Circulation* 1993; 88(4 Pt 1):1470-1475.
 15. Steinhubl SR, Topol EJ. Stenting for acute myocardial infarction. *Lancet* 1997; 350:532-533.
 16. Brener SJ, Barr LA, Burchenal JE, et al. Randomized, placebo-controlled trial of platelet glycoprotein IIb/IIIa blockade with primary angioplasty for acute myocardial infarction. ReoPro and Primary PTCA Organization and Randomized Trial (RAPPORT) Investigators. *Circulation* 1998; 98:734-741.
 17. Neumann FJ, Blasini R, Schmitt C, et al. Effect of glycoprotein IIb/IIIa receptor blockade on recovery of coronary flow and left ventricular function after the placement of coronary-artery stents in acute myocardial infarction. *Circulation* 1998; 98:2695-2701.
 18. Miller JM, Smalling R, Ohman EM, et al. Effectiveness of early coronary angioplasty and abciximab for failed thrombolysis (reteplase or alteplase) during acute myocardial infarction (results from the GUSTO-III trial). Global Use of Strategies To Open occluded coronary arteries. *Am J Cardiol* 1999; 84:779-784.
 19. Moreno R, Garcia E, Abeytua M, et al. Coronary stenting during rescue angioplasty after failed thrombolysis. *Catheter Cardiovasc Interv* 1999; 47:1-5.
 20. Antman EM, Giugliano RP, Gibson CM, et al. Abciximab facilitates the rate and extent of thrombolysis: results of the thrombolysis in myocardial infarction (TIMI) 14 trial. The TIMI 14 Investigators. *Circulation* 1999; 99:2720-2732.
 21. Califf RM. Glycoprotein IIb/IIIa blockade and thrombolytics: early lessons from the SPEED and GUSTO IV trials. *Am Heart J* 1999; 138(1 Pt 2):S12-15.
 22. Herrmann H, Moliterno DJ, Bode C, Betriu A, Lincoff AM, Ohman M. Combination abciximab and reduced-dose reteplase facilitates early PCI in acute MI—Results From the SPEED trial [abstract]. *Circulation* 1999; 100:1-188.
 23. L'Allier PL, Lopez J, Vrobel T, Strony, Brener S. Favorable results with immediate coronary intervention after low dose t-PA and eptifibatide for acute MI: Results from the INTRO-AMI trial [abstract]. *Circulation* 1999; 100:1-359.
 24. Ross AM, Coyne KS, Reiner JS, et al. A randomized trial comparing primary angioplasty with a strategy of short-acting thrombolysis and immediate planned rescue angioplasty in acute myocardial infarction: the PACT trial. PACT investigators. Plasminogen-activator Angioplasty Compatibility Trial. *J Am Coll Cardiol* 1999; 34:1954-1962.

ADDRESS: Stephen G. Ellis, MD, Department of Cardiology, F25, The Cleveland Clinic Foundation, 9500 Euclid Avenue, Cleveland, Ohio 44195; e-mail: ellis@ccf.org.