



**BRIEF QUESTIONS
AND ANSWERS
ON CURRENT
CLINICAL
CONTROVERSIES**

Q: When do you x-ray ankle sprains in patients with acute ankle injuries?

TERRY PHILBIN, DO

Department of Orthopaedic Surgery, Cleveland Clinic

BRIAN G. DONLEY, MD

Department of Orthopaedic Surgery, Cleveland Clinic

A: IN DECIDING whether a patient with an acute ankle injury needs radiographs, we generally use the Ottawa rule—a set of criteria developed using logistic regression analysis by Stiell et al¹ in Ottawa, Canada, to help physicians reduce the excessive use of ankle radiographs. In brief, an ankle radiographic series is indicated only if:

- The patient has pain near the malleoli, and if any of the following are true:
- The patient is 55 years old or older
- The patient could not bear weight on the ankle immediately after the injury and currently cannot walk four steps on it
- The patient has bone tenderness at the posterior edge or tip of either malleolus (FIGURE 1).

In addition, we obtain radiographs if the patient cannot communicate (owing to altered mental status, alcohol intoxication, or other problems) or if pain and swelling do not resolve within 7 to 10 days after an injury.

■ MANY ARE SPRAINED, BUT FEW ARE FRACTURED

Ankle trauma is one of the most common reasons for visits to an emergency room. Approximately 27,000 ankle sprains occur every day in the United States.² Ankle sprain is the most common injury in sports. Fractures are diagnosed in only 7% to 36% of ankle injuries, even though most patients undergo a radiographic evaluation. Decreasing excessive radiographs would decrease patient exposure to radiation, waiting time, and medical costs.

■ IMPORTANCE OF PHYSICAL EXAMINATION

A thorough physical examination can help decrease the need for a high number of radiographs obtained in patients with acute ankle injuries. The basic ankle examination should evaluate the neurovascular status, any gross instability, and skeletal tenderness. The joints above and below the injury should be examined (eg, the proximal fibula and the fifth metatarsal). Physical findings such as gross deformity, instability, crepitation, localized bony tenderness, severe soft tissue tenderness, moderate or severe edema, and ecchymosis can help delineate whether radiographs are needed.³

■ HOW RELIABLE IS THE OTTAWA RULE?

When originally published, the Ottawa rule was said to have 100% sensitivity and 40% specificity for detecting malleolar fractures. Therefore, all patients who truly had a fracture would still get a radiograph, but a good many who did not have fractures would be weeded out—36% by the investigators' estimate.¹ And when the rule was implemented in eight Canadian hospitals, waiting times, medical costs, and the need for radiographs all decreased significantly.⁴

However, subsequent independent studies^{5,6} reported that the Ottawa rule had lower sensitivity (93% to 95%) and specificity (6% to 11%) than originally thought.

Nevertheless, although the Ottawa rule is not perfect, it provides an excellent guide to help determine when radiographs are necessary in patients with acute ankle injuries.

■ CARE OF ANKLE SPRAINS

Patients with acute ankle injuries that do not require radiographs should rest the injured

**The Ottawa rule
helps reduce
excessive x-rays**



When to x-ray the ankle

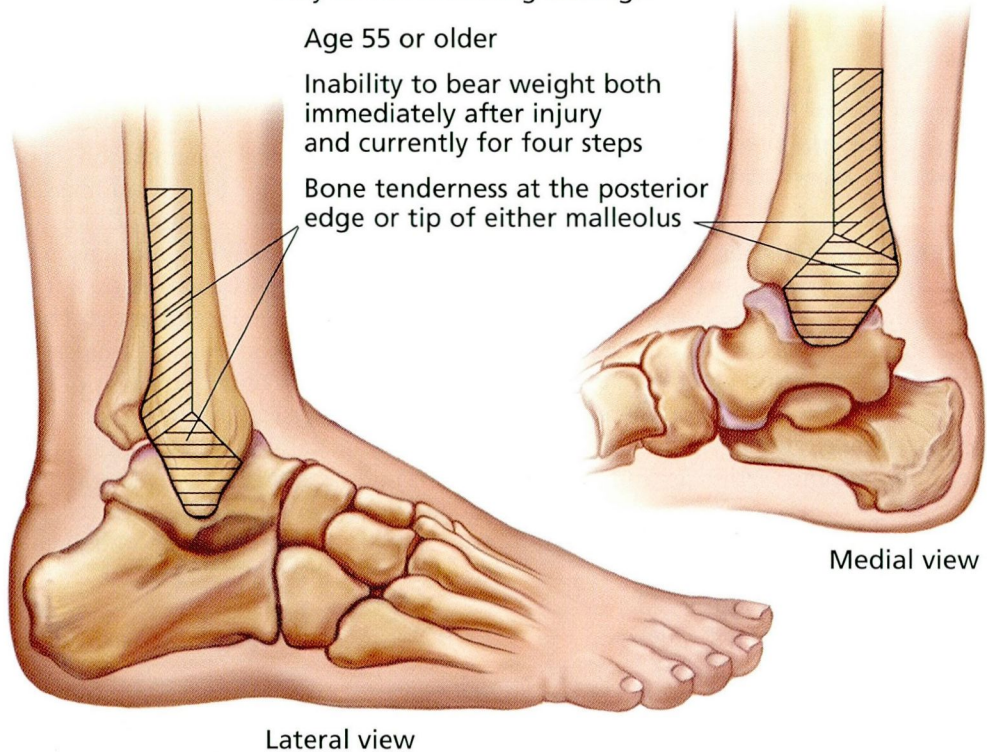
The Ottawa rule: Obtain an ankle radiographic series only if there is:

- Pain near the malleoli, and
- Any of the following findings:

Age 55 or older

Inability to bear weight both immediately after injury and currently for four steps

Bone tenderness at the posterior edge or tip of either malleolus



Lateral view

Medial view

CCF
©2000

ADAPTED FROM STIELL IG, GREENBERG GH, MCKNIGHT RD, NAIR RC, MCDOWELL I, WORTHINGTON JR. A STUDY TO DEVELOP CLINICAL DECISION RULES FOR THE USE OF RADIOGRAPHY IN ACUTE ANKLE INJURIES. ANN EMERG MED 1992; 21:384-390.

FIGURE 1

ankle, ice it, elevate it, and wrap it with a compressive bandage. If the pain and swelling do not abate in 7 to 10 days, reevaluation is necessary.

REFERENCES

1. Stiell IG, Greenberg GH, McKnight RD, Nair RC, McDowell I, Worthington JR. A study to develop clinical decision rules for the use of radiography in acute ankle injuries. *Ann Emerg Med* 1992; 21:384-390.
2. Bennet WF. Lateral ankle sprains: Part 1 Anatomy, biomechanics, diagnosis, and natural history. *Orthop Rev* 1994; 23:381-387.
3. Auletta AG, Conway WF, Hayes WF, Guisto DF, Gervin AS. Indications for radiography in patients with acute ankle injuries: Role of the physical examination. *AJR* 1991; 157:789-791.
4. Stiell I, Wells G, Laupacis A, et al for the Multicentre Ankle Rule Study Group. Multicentre trial to introduce

the Ottawa ankle rules for use of radiography in acute ankle injuries. *BMJ* 1995; 311:594-597.

5. Auleley GR, Kerboull L, Durieux P, Courpied JP, Ravaud P. Validation of the Ottawa rules in France: A study in the surgical emergency departments of a teaching hospital. *Ann Emerg Med* 1998; 32:14-18.
6. Kerr L, Kelly AM, Grant J, et al. Failed validation of a clinical decision rule for the use of radiography in acute ankle injury. *NZ Med J* 1994; 107:294-295.

ADDRESS: Brian G. Donley, MD, Department of Orthopaedic Surgery, A41, The Cleveland Clinic Foundation, 9500 Euclid Avenue, Cleveland, Ohio 44195; e-mail donleyb@ccf.org.

CME ANSWERS



Answers to the CREDIT TEST on page 455 of this issue

1 A 2 C 3 B 4 E 5 E 6 D 7 B 8 B 9 B 10 A
11 D 12 E