

**RAMESH MAZHARI, MD**

Department of Medicine, George Washington University Medical Center, Washington, DC

**PAUL L. KIMMEL, MD**

Division of Renal Diseases and Hypertension, Department of Medicine, George Washington University Medical Center, Washington, DC

# Hematuria: An algorithmic approach to finding the cause

## ■ ABSTRACT

Many conditions can cause hematuria, but the differential diagnosis can be simplified with a systematic approach. We discuss the common causes of hematuria and how to evaluate it.

## ■ KEY POINTS

Even if a dipstick test for hematuria is positive, a key question is whether this truly represents blood in the urine vs free myoglobin or hemoglobin.

The combination of hematuria plus proteinuria suggests glomerular disease.

Painless hematuria without proteinuria should prompt a search for coagulation disorders, structural abnormalities, and cancer.

Imaging studies and cystoscopy usually are necessary for diagnosis after an inconclusive initial evaluation, especially in patients with hematuria without proteinuria.

**H**EMATURIA CAN BE a sign of disease anywhere in the genitourinary system or a sign of nonurologic systemic disease, or it can even be factitious. This makes the differential diagnosis extensive and seemingly disjointed.

Nevertheless, an orderly, comprehensive approach can greatly simplify the diagnosis.<sup>1</sup>

This paper briefly reviews the common causes of hematuria in adults, suggests an algorithmic approach to the workup (**FIGURE 1**), and reviews the further evaluation of patients with hematuria.

## ■ COMMON, POTENTIALLY SERIOUS

Hematuria is common. For example, in one study,<sup>2</sup> 2.5% of men ages 28 to 57 tested positive for heme when screened by dipstick testing, as did 5.4% of men ages 18 to 54 in another study.<sup>3</sup>

Hematuria can be due to an isolated anatomic disorder of any part of the genitourinary tract (**TABLE 1**)—or it can be the harbinger of a systemic disorder, notably cancer.

A panel convened by the American Urological Association<sup>4</sup> recently found that the prevalence of highly or moderately significant disease in patients with hematuria ranged from 0% to 56%. The prevalence of urologic malignancy in the studies reviewed ranged from 0% to 25.8%. The prevalence varied with the age and sex of the population assessed, the referral source, and the clinical setting, but it was highest in patients undergoing urologic evaluation, in the elderly, and in men.<sup>4</sup>

In a prospective study of 100 patients over age 16 who were referred because of hematuria,<sup>5</sup> 37% were found to have urinary tract cancer, while another 15% had a stone, chronic urinary retention, or ureteropelvic junction obstruction.

## Workup for hematuria

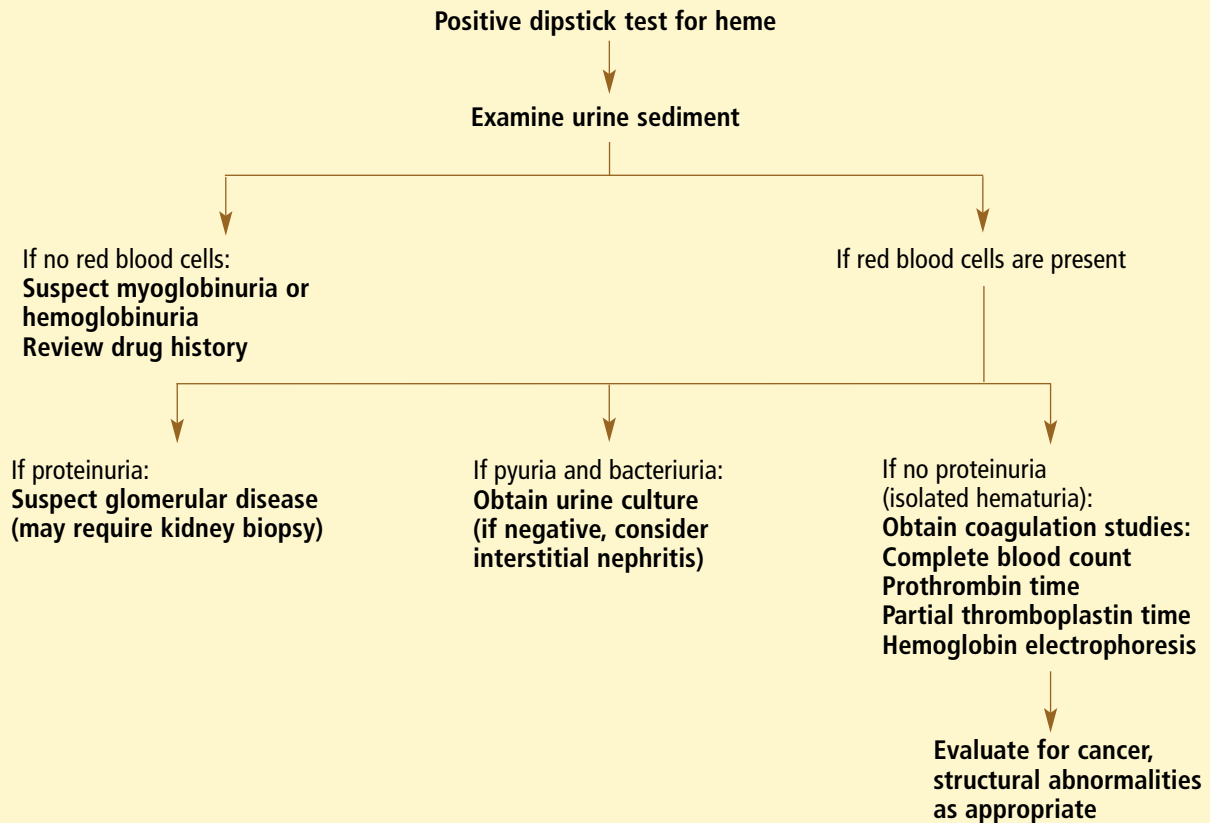


FIGURE 1

In a retrospective analysis of 110 patients who presented with hematuria,<sup>4</sup> the most common cause was neoplasia (41.8% of patients). Cancer was found in 22%, and the most common primary sites were the bladder (9%), the kidneys (6%), and the prostate (6%). The most common benign condition was benign prostatic hypertrophy (19%). Infection was the second most common diagnosis (26%), followed by nephrolithiasis (13.6%). A congenital abnormality was the cause in 3.6% of patients, trauma was the cause in 2%, and 12% had no identifiable cause.<sup>6</sup>

### DEFINING HEMATURIA

Hematuria is usually defined as more than 5 red blood cells per high-power field in the urinary sediment, although the definition is variable.<sup>4</sup> Dipstick tests that use orthotolidine can

detect this low number of red blood cells, but they also may be positive in the presence of free hemoglobin or myoglobin.

Healthy people can excrete as many as 3 red blood cells per high-power field, or even more (temporarily) following vigorous exercise as a result of injury to structures in the kidney or bladder.<sup>7,8</sup>

### CLUES FROM THE HISTORY

#### When during urination does the blood appear?

Hematuria at the start of urination suggests a problem in the urethra distal to the urogenital diaphragm, while hematuria throughout urination suggests upper urinary tract or upper bladder disease, and hematuria at the end of urination suggests a problem in the bladder neck or the prostatic urethra.

**TABLE 1****Causes of pigmenturia and hematuria****Endogenous causes of pigmenturia**

Bilirubin  
Melanin  
Porphyrins

**Exogenous causes of pigmenturia**

Azathioprine  
Deferoxamine  
Doxorubicin  
Laxatives  
Phenazopyridine  
Phenothiazine  
Phenytoin  
Riboflavin  
Rifampin  
Warfarin

**Drugs that can cause myoglobinuria**

Amphotericin B  
Barbiturates  
Cocaine  
Codeine  
Diazepam  
Ethanol  
Heroin  
HMG-CoA reductase inhibitors (statins)  
Methadone

**Drugs that can cause hematuria**

Analgesics  
Anticoagulants  
Busulfan  
Cyclophosphamide  
Oral contraceptives  
Penicillins (extended-spectrum)  
Quinine  
Vincristine

**Systemic causes of hematuria**

Bleeding diathesis  
Sickle cell disease

**Metabolic causes of hematuria**

Hypercalciuria  
Hyperuricosuria

**Renal vascular causes of hematuria**

Arteriovenous malformation  
Renal artery disease  
Thrombosis, embolus, dissecting aneurysm, malignant hypertension  
Renal vein thrombosis

**Renal causes of hematuria**

Vasculitis  
Henoch-Schönlein purpura, periarteritis nodosa, Wegener granulomatosis  
Glomerular disease  
Poststreptococcal glomerulonephritis  
Other postinfectious glomerulonephritides  
Immunoglobulin A nephropathy  
Lupus nephritis  
Mesangial proliferative glomerulonephritis  
Alport syndrome  
Thin basement membrane disease  
Nail-patella syndrome  
Fabry disease  
Other types of glomerulonephritis  
Tubulointerstitial disease  
Polycystic kidney disease  
Nephrolithiasis  
Analgesic nephropathy  
Reflux nephropathy  
Tumors (primary renal cell, leukemic infiltrate, metastatic)  
Infection (pyelonephritis; rare)  
Renal masses (vascular, neoplastic, congenital)

**Urinary tract diseases**

Infection or cancer of the ureter, bladder, prostate, urethra  
Nephrolithiasis

**Colicky pain  
in a patient  
with hematuria  
suggests a stone**

In a woman with hematuria, it is important to determine if she is menstruating at the time of the evaluation so that extra care is taken to obtain an uncontaminated urine specimen for analysis.

**Do you have to urinate often?****Does it hurt?**

Increased frequency and dysuria in a patient with hematuria may point to a urinary tract

infection or uroepithelial malignancy. Colicky pain suggests a stone.

Hematuria without pain suggests something other than nephrolithiasis, infection, or papillary necrosis, but does not rule them out. Nevertheless, painless hematuria in the absence of signs and symptoms of renal disease or urinary tract infection should prompt an investigation for genitourinary malignancy.

Many drugs  
either cause  
hematuria  
or discolor  
the urine

### Have you lost weight or been sick?

Weight loss, extrarenal manifestations (rash), arthritis, arthralgia, or pulmonary symptoms suggest a variety of systemic illnesses, including vasculitic syndromes, malignancy, and tuberculosis. A recent sore throat or skin infection is consistent with poststreptococcal glomerulonephritis.

### Do you take any medications?

A detailed history of drugs prescribed to and used by the patient is very useful, since many drugs can cause either hematuria or discoloration of the urine (TABLE 1). Heavy or surreptitious use of analgesics may be associated with analgesic nephropathy, which can be associated with hematuria, and papillary necrosis.<sup>9</sup> Use of oral contraceptives has been associated with loin-pain hematuria syndrome. Smokers have a higher risk of developing bladder cancer, as do patients treated with cyclophosphamide.

### Family history, travel history

Ask about any family history of hematuria, sickle cell disease, polycystic kidney disease, or other renal disease, and about travel to areas where schistosomiasis or malaria is endemic.

## ■ PHYSICAL EXAMINATION

Hypertension, especially if new, may be a sign of renal disease. Petechiae, arthritis, mononeuritis multiplex, and rash suggest coagulopathy, immunologic disease, or vasculitis. Hearing should be evaluated if Alport syndrome is suspected (see below). Examination of the prostate and urethral meatus is part of a complete evaluation.

## ■ LABORATORY ANALYSIS

### Is it really blood?

The clinician must distinguish hematuria from pigmenturia (discoloration of the urine). Therefore, the first step in the laboratory evaluation is to inspect the urine and do a dipstick test. (Remember, however, that the dipstick test will be positive in cases of hemoglobinuria or myoglobinuria, as well as in hematuria.) Dipstick tests also give a semiquantitative measure of protein excretion.

If the dipstick test is positive for heme, the next step is to determine if urine protein excretion is increased and if red blood cells, white blood cells, casts, or crystals of the urine are shown on microscopic examination. The physician should perform microscopic urinalysis in every case in which the differential diagnosis of hematuria is considered.

### Is there protein in the urine?

The dipstick test already gave you information about protein, which you can follow up with either a random or a 24-hour quantitative measurement if the urine protein is greater than trace.

Increased urinary protein excretion can be an extremely important diagnostic discriminator. Since the glomerular basement membrane is normally relatively impermeable to albumin, an increased ratio of urinary albumin to creatinine is diagnostic of glomerular disease, typically either glomerulonephritis (such as lupus nephritis) or glomerulopathy (such as membranous nephropathy).

Urinary protein excretion in the range of 1 to 1.5 g/24 hours may accompany tubulointerstitial disease rather than glomerular disease, especially if albumin is not an important component of the urinary protein. Proteinuria in the nephrotic range ( $> 3$  or  $3.5$  g/24 hours or a urinary protein-to-creatinine ratio  $> 3$  or  $3.5$  on a spot specimen) is typically associated with glomerular disease.

### Are there cells or casts in the urine?

The next step is to perform a microscopic examination of the sediment of a recently obtained and centrifuged urine sample under both low and high power.

If the dipstick test is positive but no red blood cells are seen in the sediment, then endogenous and exogenous causes of pigmenturia should be considered (TABLE 1). Hematuria without formed elements (blood cells or casts) or proteinuria is called "isolated hematuria." We will discuss the specific aspects of the evaluation of isolated hematuria below.

Dysmorphic or irregularly shaped red blood cells may be detected with phase-contrast microscopy.<sup>10</sup> If more than 20% of cells are dysmorphic, this strongly suggests a glomerular origin of the bleeding.<sup>10</sup>

Another clue that the bleeding is of glomerular origin are red blood cell casts, which are usually diagnostic of glomerulonephritis.

Red blood cell casts suggest an inflammatory process rather than a disorder of basement membrane structure or function, or abnormal glomerular matrix metabolism. Pyuria with hematuria necessitates testing to rule out urinary tract infection, a very common cause of hematuria (FIGURE 1). A urine Gram stain, culture, or both should be performed.

### Does the patient have a bleeding diathesis?

If a patient has a positive dipstick test, erythrocytes in the sediment, and no protein in the urine (ie, isolated hematuria), the next step is to test for a bleeding diathesis by obtaining a platelet count, prothrombin time, and partial thromboplastin time, and, if the patient is black, a test for sickle cell trait.<sup>11</sup>

If these tests are negative, then the patient should be evaluated for renovascular and urologic diseases as well as nephrolithiasis, using radiographic techniques (see below).

### Does the patient have cancer?

Patients with isolated hematuria and an otherwise unremarkable laboratory evaluation should undergo imaging of the kidney and genitourinary tract as well as cystoscopy, because of the possibility of malignancy, its ominous prognosis, and the need for rapid treatment.

How much emphasis to place on the patient's age when planning this evaluation is controversial, but the American Urological Association recently issued guidelines on risk stratification.<sup>4,12</sup> Cystoscopy can be deferred in low-risk patients, eg, those under age 40 without risk factors for bladder cancer.<sup>12</sup> However, these patients should undergo voiding urinary cytologic testing.

**Urine cytology** is a cost-effective test that is especially recommended if cystoscopy needs to be deferred.<sup>4</sup> It has a sensitivity of 40% to 76% for detecting bladder cancer, depending on the number of samples sent and the stage of the malignancy.

Urine cytology may be particularly useful in patients at high risk for uroepithelial tumors (eg, smokers, people who overuse

analgesics, people over age 40, people exposed to chemicals or dyes, and people with irritative voiding symptoms).<sup>4</sup>

All patients with hematuria and abnormal findings on voided urinary cytology should undergo a complete urologic evaluation, including cystoscopy.<sup>4</sup>

Other potential urinary markers for genitourinary malignancies are reviewed by Grossfeld et al.<sup>4</sup>

### Patients taking anticoagulants

A complete urologic evaluation is also necessary for patients with hematuria who are taking anticoagulants.

The significance of hematuria in these patients has been addressed in several studies. A retrospective study of patients who presented with gross hematuria while receiving warfarin or aspirin revealed urologic findings in 74%.<sup>13</sup>

If the evaluation does not reveal a structural abnormality, then glomerular causes of isolated hematuria (such as immunoglobulin A nephropathy or thin basement membrane disease) or small arteriovenous malformations should be considered.

## ■ DIAGNOSTIC IMAGING METHODS

A variety of imaging methods are available for the further diagnostic workup of patients with hematuria. The choice of method depends on the suspected cause of hematuria, based on the history and laboratory analysis. For example, patients with isolated hematuria require a technique that yields the best images of both the renal parenchyma and uroepithelium.

### Intravenous pyelography

Intravenous pyelography, the traditional choice for evaluating the urinary tract, provides detailed images of the collecting structures. Other advantages: it is relatively inexpensive and its technique is standardized.

However, intravenous pyelography has low sensitivity in detecting masses smaller than 3 cm in diameter and has limited use in evaluating the bladder and urethra.<sup>14</sup> It also requires contrast material, which poses a risk of nephrotoxicity in patients with renal insufficiency.

**Smoking, heavy analgesic use, age over 40, and chemical exposure increase tumor risk**



Renal masses are often found during the radiologic evaluation of patients with isolated hematuria (TABLE 2). The character of a mass detected by intravenous pyelography should be further investigated by ultrasonography or computed tomography (CT).<sup>15,16</sup>

If intravenous pyelography is negative in a patient with isolated hematuria, urologic evaluation including cystoscopy is the next step (see below).

### Ultrasonography

Ultrasonography of the kidney is excellent for confirming and characterizing a cyst and can be used in patients with renal insufficiency, as it does not require intravenous contrast. Disadvantages: its accuracy is lower for detecting solid lesions smaller than 3 cm in diameter, and it is poor for evaluating the uroepithelium.<sup>12</sup>

### Computed tomography

CT with contrast is the best imaging test for detecting small renal parenchymal masses, urolithiasis, and renal abscesses. It is approximately as good as magnetic resonance imaging (MRI) at detecting small parenchymal masses, and it is less expensive. However, it is more expensive than ultrasonography or intravenous pyelography. The major limitation of CT is that it lacks sensitivity in detecting uroepithelial malignancies.

CT urography, ie, the combination of CT and radiography after contrast-enhanced CT, provides higher detection rates.<sup>12</sup> In patients with underlying renal insufficiency or contrast allergy or both, the combination of ultrasonography and retrograde pyelography should be considered.<sup>12</sup>

### Cystoscopy

None of the above tests can completely evaluate the bladder mucosa, so cystoscopy should be part of the evaluation of all patients with isolated hematuria over 40 years of age, and of younger patients with risk factors for genitourinary malignancy.<sup>12</sup>

### Angiography

If the above studies are negative, the possibility of a small arteriovenous malformation should be considered, and angiography may be

TABLE 2

## Types of renal masses

### Vascular

- Arteriovenous malformation
- Hemangioma
- Hematoma (after trauma)
- Renal artery aneurysm
- Renal vein thrombosis

### Neoplastic

#### Benign

- Angiomyolipoma
- Cyst (simple, multilocular, dermoid)
- Fibroma
- Leiomyoma
- Lipoma
- Neurofibroma

#### Malignant

- Lymphoma or leukemia
- Metastatic disease
- Myeloma
- Nephroblastoma
- Renal cell carcinoma
- Sarcoma

### Congenital

- Polycystic kidney disease

used to evaluate for this. Otherwise, the patient should be followed at 6, 12, 24, and 36 months, since bladder cancer can be preceded by hematuria.<sup>12</sup> Urinalysis, urine cytology, and blood pressure should be assessed during follow-up visits.

## EVALUATION OF A RENAL MASS

Any mass found on intravenous pyelography must be defined as a simple cyst, a complex cyst, or a solid mass. An avascular cyst with a thin, sharply marginated wall and homogeneously radiolucent density fulfills the criteria for a simple cyst. Confirmation of the nature of a complex cyst or solid mass typically requires ultrasonography, CT, or MRI, as these techniques can detect and characterize lesions of the renal parenchyma.<sup>12,16</sup> Complex cysts and solid masses are more likely to represent malignancies.

When ultrasonography and CT studies were combined in one study,<sup>17</sup> 95% of lesions were characterized correctly. If the lesion

**Complex cysts and solid masses more likely represent malignancy**



appears to be a complex cyst or a solid mass, the patient should be referred for urologic consultation. The further radiologic and surgical management of these patients is beyond the scope of this article.

## ■ RENOVASCULAR DISEASES

### Renal arteriovenous malformations

Renal arteriovenous malformations are usually asymptomatic, but some can present with gross hematuria. These malformations are more common in young female patients and are either acquired or congenital.

**Acquired arteriovenous malformations,** or arteriovenous fistulae, account for 70% to 80% of renal arteriovenous malformations. They can result from surgery, trauma, tumors, or inflammation, and they are usually asymptomatic. The most common clinical manifestation is an abnormal bruit, although this may not be present in every case.<sup>18</sup> Congenital arteriovenous malformations usually present with gross hematuria.

**Diagnosis.** If a renal arteriovenous malformation ruptures, the patient can present with flank pain and signs of retroperitoneal bleeding.<sup>19</sup> The appearance of the malformation on CT is a valuable diagnostic tool during the vascular and early cortical nephrographic phases.<sup>18</sup> Magnetic resonance angiography (MRA) studies provide more sensitive tissue contrast and evaluation of the renal vasculature and do not require contrast. The gold standard for the diagnosis of a renal arteriovenous malformation, however, remains arteriography.<sup>20</sup>

### Renal artery thrombosis

Renal artery thrombosis can result from trauma, inflammatory vascular disease,<sup>21</sup> or infections that damage the endothelium. It can present with flank and abdominal pain, nausea and vomiting, and gross or microscopic hematuria,<sup>22,23</sup> but the presentation is variable. Whether renal insufficiency, oliguria, or both develop depends on the extent of the involvement and whether the disease is bilateral.

### Atheroembolic disease

Atheroembolism of the renal arteries is associated with cardiac disease and arrhythmias and

may also be a complication of intra-arterial catheterization. The presentation depends on the size, number, and location of the emboli. Patients can present with abdominal pain, fever, nausea, vomiting, and gross hematuria, as well as variable levels of renal insufficiency.

### Renal vein thrombosis

Renal vein thrombosis often presents insidiously in patients with nephrotic syndrome<sup>24</sup> or renal cell carcinoma.<sup>25</sup> Acute renal vein thrombosis is rare in adults, but may occur after blunt abdominal trauma or renal transplantation.<sup>26</sup> Oral contraceptive use and hyperhomocysteinemia may be risk factors for acute renal vein thrombosis.<sup>27</sup>

The clinical presentation depends on the rapidity and extent of the renal vein occlusion. Acute renal vein thrombosis is typically characterized by sudden onset of flank pain and macroscopic hematuria.

Doppler ultrasonography is usually used as an initial study for evaluation of suspected renal vein thrombosis. If the ultrasound findings are indeterminate and renal function is impaired, MRI is useful. CT is also used for diagnosis if renal function is preserved.<sup>19,28</sup> Renal venography remains the gold standard to establish the diagnosis, but this invasive procedure may not be necessary in many cases.

### Loin-pain hematuria syndrome

Loin-pain hematuria syndrome is rare. The cause is not known.<sup>9</sup> It has typically been seen in young women of childbearing age who were using oral contraceptives. The clinical presentation is usually hematuria without pyuria, but low-grade proteinuria may be present.

The diagnosis is usually made after an unrevealing imaging study is followed by renal angiography. Although these patients may have microscopic renal vascular and histologic abnormalities,<sup>29</sup> arteriography reveals narrowing and tortuosity of terminal branches of the renal vessels and segmental ischemia.

One study suggested a relationship between loin-pain hematuria syndrome and glomerular abnormalities,<sup>29</sup> but large epidemiologic or clinicopathologic correlative studies to confirm the association have not been performed.

**Renal AV malformation is usually asymptomatic and is most common in young females**



The first step in treatment is to stop oral contraceptives, but symptoms do not always remit. Occasionally, renal autotransplantation has been performed.<sup>9</sup>

## ■ GLOMERULAR DISEASES

### Poststreptococcal glomerulonephritis

Poststreptococcal glomerulonephritis typically presents with hematuria associated with edema, hypertension, or both<sup>30</sup>; 30% of patients have an episode of gross hematuria. Renal insufficiency is usually present and often progresses over days. The subclinical form of the disease can present with microscopic hematuria with or without hypertension. It follows an episode of pharyngitis (1 to 3 weeks) or impetigo (3 to 6 weeks) and typically affects children between the ages of 2 and 10 years. Fewer than 10% of patients are over age 40.<sup>30</sup>

Deposits of IgG and C3 are found within glomeruli, suggesting deposition of immune complexes. Poststreptococcal glomerulonephritis is typically associated with hypocomplementemia.

Renal biopsy is not indicated if the clinical suspicion of poststreptococcal glomerulonephritis is high—for example, in a patient with typical findings and with high titers of antistreptolysin O and low complement C3 levels. But in a patient with normal serum complement levels at the time of presentation or persistently low complement levels after 2 months, renal biopsy should be considered to rule out other glomerulopathies that can have a similar presentation, such as lupus nephritis and membranoproliferative glomerulonephritis (TABLE 1).

The disease is usually self-limited, and the long-term prognosis is excellent.

### Immunoglobulin A nephropathy

IgA nephropathy is a glomerular disease most common in persons of Asian and southern European descent and very uncommon in African Americans. It affects mostly children and young men. Patients often present with macroscopic or microscopic hematuria after an upper respiratory infection.

On light microscopy, different types of proliferative glomerulonephritis can be seen,

such as focal or diffuse mesangial proliferative glomerulonephritis.<sup>31</sup> Immunofluorescence microscopy demonstrates IgA immune deposits in the mesangium and the glomerular capillary walls. On electron microscopy, electron-dense deposits corresponding to immune deposits may be appreciated in the mesangium and within glomerular capillaries.

The course is often indolent, but about one third of patients reach end-stage renal disease after 20 years, particularly those who have hypertension, heavy proteinuria, or renal insufficiency at the time of presentation.<sup>32</sup>

### Thin basement membrane disease

Thin basement membrane disease presents most commonly with microscopic hematuria, usually with minimal or no proteinuria.

No histologic abnormality is found on light and immunofluorescence microscopy. Diffuse and uniform thinning of the glomerular basement membrane is seen on electron microscopy, but this can also be seen in early Alport syndrome and IgA nephropathy.<sup>33</sup> Renal function is normal.

The clinical course is benign, and the disease is not associated with progressive loss of renal function or the development of end-stage renal disease.

There are undefined familial patterns of inheritance (benign familial hematuria). Relatives of patients with this disease often have microscopic hematuria. In a prospective study of the natural history of nonproteinuric hematuria,<sup>34</sup> IgA nephropathy and thin basement membrane disease were the most prevalent pathologic findings.

It is important, however, to establish the diagnosis of a particular glomerulonephritis with a degree of clinical certainty, since many of these diseases may have an ominous prognosis. Kidney biopsy may be desirable for further evaluation.

## ■ HEREDITARY GLOMERULAR DISEASES

### Alport syndrome

Alport syndrome is one of the best studied hereditary glomerulopathies. Two forms of Alport syndrome have been recognized on a molecular genetic basis: an X-linked domi-

**Hematuria after a URI may indicate IgA nephropathy in an Asian or southern European patient**



nant form and an autosomal-recessive form.<sup>35</sup> The disease is caused by a mutation in a gene encoding for a protein of type IV collagen.

The pathologic findings on light microscopy are nonspecific. Immunofluorescence microscopy may show nonspecific granular deposits of C3 and IgM. The salient diagnostic abnormality is the variable thickening, thinning, and lamellation of the glomerular basement membrane seen on electron microscopy.

Hematuria is the cardinal feature in affected males and in some female carriers. In children, episodes of hematuria may follow a sore throat or other infection. Hematuria may reflect fragility of the glomerular basement membrane in the absence of the normal collagen network formed by the type IV collagen chains.

Progressive renal dysfunction and the development of renal failure are almost universal in affected males. Most female carriers, however, survive into old age with minimal renal disease. Sensorineural hearing loss, eye defects, and cataracts are commonly associated with this syndrome.<sup>35</sup>

### Fabry disease

Fabry disease is an X-linked recessive lysosomal storage disorder caused by a deficiency of alpha-galactosidase A, leading to accumulation of glycosphingolipids in the kidneys, skin, nerves, and eyes. Skin involvement occurs typically as reddish purple macules. Peripheral and autonomic neuropathy and accelerated coronary artery disease are other clinical manifestations. Renal involvement is manifested by hematuria and proteinuria, which often progresses to nephrotic-range proteinuria.

The major histologic findings are enlarged glomerular epithelial cells with foamy-appearing vacuoles on light microscopy and “zebra bodies” within the cytoplasm of podocytes on electron microscopy.<sup>36</sup>

### Nail-patella syndrome

Nail-patella syndrome is a congenital glomerular disease that can present with microscopic hematuria and proteinuria. Renal involvement is associated with characteristic skeletal changes such as dystrophic nails, patellar hypoplasia, and dislocation of the radial head

of the elbow. It is inherited in an autosomal-dominant fashion. Approximately 30% of the patients progress to end-stage renal failure.<sup>36</sup>

## TUBULOINTERSTITIAL DISEASE

### Polycystic kidney disease

Polycystic kidney disease is a systemic hereditary disorder, with several different genetic loci associated with different phenotypic presentations. The disease has autosomal-dominant and autosomal-recessive (childhood) forms. It is the fourth most common cause of end-stage renal disease in the United States.

The classic presentation used to be hematuria in the presence of a flank mass, but intensive family studies, including screening and less cumbersome diagnostic techniques, have rendered this scenario relatively uncommon. Hematuria can be present in 50% of cases.

Polycystic kidney disease is easily diagnosed by ultrasonography, CT, or MRI, but ultrasonography is the procedure of choice, since it is relatively inexpensive and highly sensitive.<sup>37</sup> MRI is more sensitive in detecting the disease in younger patients, however.

The disease is often progressive, but progression is variable.

### Analgesic nephropathy

Analgesic nephropathy is usually chronic and asymptomatic. The disease is typically characterized by renal insufficiency, non-nephrotic, low-grade proteinuria, and asymmetric, scarred kidneys. Patients are often found to have abnormal renal function, and a history of long-term analgesic use (typically in the range of kilograms ingested over years) is paramount to the diagnosis.

CT of the kidneys may be quite helpful in confirming the diagnosis. Patients with renal papillary necrosis, however, can present with pain and macroscopic hematuria. Patients with analgesic nephropathy may have an “active sediment,” ie, with pyuria, proteinuria, and red blood cells. Urinary tract infection must be ruled out in such cases. Urologic evaluation is mandatory, since analgesic use may be associated with the development of uroepithelial tumors.<sup>38–40</sup>

**Polycystic kidney disease often progresses, but variably**



## Nephrolithiasis

Nephrolithiasis is common and can present with hematuria. Colicky pain is often an important accompanying complaint, aiding diagnosis. The disease may be idiopathic or associated with metabolic disorders such as hyperparathyroidism, gout, cystinuria, or hypercalciuria.

The diagnosis can be suggested by crystal-luria and is often confirmed by an imaging study. The types of syndromes associated with nephrolithiasis<sup>41</sup> are beyond the scope of this review. Nephrolithiasis is often associated with urinary tract infection and should be considered as a diagnostic possibility in the patient with recurrent symptoms unresponsive to antibiotic therapy (see below).

## Sickle cell nephropathy

Sickle cell trait and disease are associated with a number of renal diseases.<sup>11</sup> Sickle cell nephropathy can present with hematuria. The most common manifestations are hematuria, proteinuria (occasionally in the nephrotic range), acute renal failure, chronic renal insufficiency, and renal tubular acidosis.<sup>11</sup>

## KIDNEY INFECTIONS

### Pyelonephritis

Pyelonephritis can present with microscopic or gross hematuria. The associated symptoms are typically flank pain and fever. Gram stain and culture of the urine confirm the diagnosis.

### Renal tuberculosis

Renal tuberculosis can present with gross hematuria, flank pain, dysuria, and pyuria. Constitutional symptoms are seen in 10% of cases. This condition is a local manifestation of a generalized infection and occurs as a result of bloodstream dissemination.<sup>42</sup> Genitourinary

tract tuberculosis should be suspected if the patient has sterile pyuria, a history of tuberculosis, a positive purified protein derivative (PPD) test, or renal parenchymal calcifications on abdominal radiography.

*Mycobacterium tuberculosis* in the urine<sup>42</sup> or a positive urine culture confirms the diagnosis. Ureteral strictures associated with the scarring of renal tuberculosis can appear as “beading” on intravenous pyelography.

## BLADDER DISEASE

Bladder diseases that can cause hematuria include cystitis, tumors, tumor-like lesions, stones, and inflammatory processes (TABLE 1). Transitional-cell carcinomas account for approximately 85% of malignant bladder tumors.

### Schistosomiasis

*Schistosoma haematobium* is endemic in many areas of Africa and the Middle East. It causes a bladder lesion as a result of the deposition of eggs in the submucosa, with a subsequent granulomatous reaction. Patients may experience severe irritative symptoms during voiding. Hematuria is common. The disease may progress to renal insufficiency, with the subsequent gradual onset of hydronephrosis or obstructive uropathy.

### Tuberculosis of the bladder

Tuberculosis can cause bladder lesions, almost always as a consequence of renal involvement. Red, inflamed, bullous lesions, which usually appear near the ureteral orifices, are associated with ureteral strictures and hydronephrosis.

### Other conditions

Prostatitis, benign prostatic hyperplasia, prostatic carcinoma, and urethritis can also present with hematuria.<sup>4</sup>

**Travel to Africa or the Middle East raises suspicion of schistosomiasis in a patient with hematuria**

## REFERENCES

1. Kimmel PL, Yepes M, Murad L, von Albertini B. Recurrent hematuria in a patient with a history of anaphylactic reaction to radiographic contrast. *Military Med* 1994; 159:347–350.
2. Ritchie CD, Bevan EA, Collier SJ. Importance of occult haematuria found at screening. *BMJ* 1986; 292:681–683.
3. Froom P, Gross M, Froom J, Caine Y, Margalioth S, Benbassat J. Factors associated with microhematuria in asymptomatic young men. *Clin Chem* 1986; 32:2013–2015.
4. Grossfeld GD, Litwin MS, Wolf JS, et al. Evaluation of asymptomatic microscopic hematuria in adults: the American Urological Association Best Practice Policy-Part I: definition, detection, prevalence, and etiology. *Urology* 2001; 57:599–603.
5. Gillat DA, O'Reilly PH. Hematuria analyzed: a prospective study. *J R Soc Med* 1987; 80:559–562.
6. Carter WC, Rous SN. Gross hematuria in 110 adult urologic hospital patients. *Urology* 1981; 18:342–344.
7. Abarbanel J, Benet AE, Lask D, Kimche D. Sports hematuria. *J Urol* 1990; 143:887–890.



8. Gambrell RC, Blount BW. Exercise-induced hematuria. *Am Fam Physician* 1996; 53:905–911.
9. Glasscock RJ. Hematuria and pigmenturia. In: Massry SG, Glasscock RJ, editors. *Massry and Glasscock's Textbook of Nephrology*, 4th ed. Philadelphia: Lippincott Williams and Wilkins, 2001:503–508.
10. Mohammad KS, Bdesha AS, Snell ME, Witherow RON, Coleman DV. Phase contrast microscopic examination of urinary erythrocytes to localize source of bleeding: an overlooked technique? *J Clin Pathol* 1993; 46:642–645.
11. Pham PT, Phuong-Chi T, Wilkinson AH, Lew SQ. Renal abnormalities in sickle cell disease. *Kidney Int* 2000; 57:1–8.
12. Grossfeld GD, Litwin MS, Wolf JS, et al. Evaluation of asymptomatic microscopic hematuria in adults: the American Urological Association Best Practice Policy-Part II: patient evaluation, cytology, voided markers, imaging, cystoscopy, nephrology evaluation, and follow up. *Urology* 2001; 57:604–610.
13. Avidor Y, Nadu A, Matzkin H. Clinical significance of gross hematuria and its evaluation in patients receiving anticoagulant and aspirin treatment. *Urology* 2000; 55:22–24.
14. Amis ES Jr. Epitaph for the urogram [editorial]. *Radiology* 1999; 213:639–640.
15. Warshauer DM, McCarthy SM, Street L, et al. Detection of renal masses: sensitivities and specificities of excretory urography/linear tomography, US, and CT. *Radiology* 1988; 169:363–365.
16. Wolf JS. Evaluation of management of solid and cystic renal masses. *J Urol* 1998; 159:1120–1133.
17. Curry NS, Bissada NK. Radiologic evaluation of small and indeterminate renal masses. *Urol Clin North America*; 1997; 24:493–505.
18. Crotty KL, Orihuela E, Warren MM. Recent advances in the diagnosis and treatment of renal arteriovenous malformations and fistulas. *J Urol* 1993; 150:1355–1359.
19. Kawashima A, Sandler CM, Ernst RD, et al. CT evaluation of renovascular disease. *Radiographics* 2000; 20:1321–1340.
20. Vasavada SP, Manion S, Flanigan RC, Novick AC. Renal arteriovenous malformations masquerading as renal cell carcinoma. *Urology* 1995; 46:716–721.
21. Rysava R, Zabka J, Peregrin JH, Tesar V, Merta M, Rychlik I. Acute renal failure due to bilateral renal artery thrombosis associated with primary antiphospholipid syndrome. *Nephrol Dial Transplant* 1998; 13:2645–2647.
22. Stables DP, Pouches RF, De Villera Van Nierkerk J. Traumatic renal artery occlusion: 21 cases. *J Urol* 1974; 115:229–235.
23. Amilineni V, Lackner DF, Morse WS, Srinivas N. Contrast-enhanced CT for acute flank pain caused by acute renal artery occlusion. *Am J Roentgenol* 2000; 174:105–106.
24. Wagoner RD, Stanson AW, Holley K, et al. Renal vein thrombosis in idiopathic membranous glomerulopathy and the nephrotic syndrome: incidence and significance. *Kidney Int* 1983; 23:368–376.
25. Zucchelli P. Renal vein thrombosis. *Nephrol Dial Transplant* 1992; 7(suppl 1):105–108.
26. du Buf-Vereijken PW, Hilbrands LB, Wetzels JF. Partial renal vein thrombosis in a kidney transplant: management by streptokinase and heparin. *Nephrol Dial Transplant* 1998; 13:499–502.
27. Chan HH, Douketis JD, Nowaczyk MJ. Acute renal vein thrombosis, oral contraceptive use, and hyperhomocysteinemia. *Mayo Clin Proc* 2001; 76:212–214.
28. Rahmouni A, Jaserli N, Radier C, et al. Evaluation of magnetic resonance imaging for the assessment of renal vein thrombosis in the nephrotic syndrome. *Nephron* 1994; 68:271–272.
29. Hebert LA, Bets JA, Sedmak DD, Cosio FG, Bay WH, Carlton S. Loin-pain hematuria syndrome associated with thin glomerular basement membrane disease and hemorrhage into renal tubules. *Kidney Int* 1996; 49:168–173.
30. Hricik DE, Chung-Park M, Sedor JR. Glomerulonephritis. *N Engl J Med* 1998; 339:888–899.
31. Haas M. Histologic subclassification of IgA nephropathy: a clinico-pathologic study of 244 cases. *Am J Kidney Dis* 1997; 29:829–842.
32. Galla JH. IgA nephropathy. *Kidney Int* 1995; 47:377–387.
33. Cosio FG, Falkenhain ME, Sedmak DD. Association of thin glomerular basement membrane with other glomerulopathies. *Kidney Int* 1994; 46:471–474.
34. Nieuwhof C, Doorebos C, Grave W, et al. A prospective study of the natural history of idiopathic non-proteinuric hematuria. *Kidney Int* 1996; 49:222–225.
35. Kashtan CE, Michael AF. Alport syndrome. *Kidney Int* 1996; 50:1445–1463.
36. Brady RO, Schiffmann R. Clinical features of and recent advances in therapy for Fabry disease. *JAMA* 2000; 284:2771–2775.
37. Gabow PA. Autosomal dominant polycystic kidney disease. *N Engl J Med* 1993; 329:332–342.
38. Porpacz P, Schramek P. Analgesic nephropathy and phenacetin-induced transitional cell carcinoma: analysis of 300 patients with long-term consumption of phenacetin-containing drugs. *Eur Urol* 1981; 7:349–354.
39. Gonwa TA, Buckalew VM, Corbett WT. Analgesic nephropathy and urinary-tract carcinoma. *Ann Intern Med* 1979; 90:432–433.
40. De Broe ME, Elseviers MM. Analgesic nephropathy. *N Engl J Med* 1998; 338:446–452.
41. Coe FL, Parks JH, Asplin JR. The pathogenesis and treatment of kidney stones. *N Engl J Med* 1992; 327:1141–1152.
42. Roberts JA. Management of pyelonephritis and upper urinary tract infections. *Urol Clin North Am* 1999; 26:753–763.

---

**ADDRESS:** Paul L. Kimmel, MD, Division of Renal Diseases and Hypertension, Department of Medicine, George Washington University Medical Center, 2150 Pennsylvania Avenue NW, Washington, DC 20037.