PAUL SCHOENHAGEN, MD
Fellow, Cardiovascular Medicine,
Department of Cardiovascular Medicine,
The Cleveland Clinic

E. MURAT TUZCU, MD
Department of Cardiovascular Medicine,
The Cleveland Clinic

Coronary artery calcification and end-stage renal disease: Vascular biology and clinical implications

KEY POINTS

Coronary artery calcifications appear to be an indicator of total atherosclerotic disease burden, but their relation to the stability of individual atherosclerotic plaques is not well understood.

Plaque rupture and acute coronary syndromes can occur without plaque calcification and may be more often associated with noncalcified, soft plaque.

Pharmacologic control of calcium and phosphate metabolism should be guided by the nephrologic and endocrinologic needs of the renal failure patient and not withheld out of concern about coronary calcifications.

Efforts to slow coronary artery disease progression in patients with end-stage renal disease should emphasize aggressive control of recognized cardiovascular risk factors.

Both authors have indicated that they have no affiliation with or financial interest in a commercial organization that poses a potential conflict of interest with their article.

THE METABOLIC CHANGES associated with end-stage renal disease (ESRD) and its treatment may accelerate development of cardiovascular disease. In fact, cardiovascular disease, particularly coronary artery disease and chronic heart failure, is the leading cause of death in patients with ESRD.[1,2] Yet the pathophysiology of this association is complex and only partially understood.[3]

Increased coronary artery calcification is one of the metabolic changes related to ESRD. This review summarizes current knowledge on the clinical significance of coronary calcification in patients with ESRD, the role of pharmacologic therapies to prevent skeletal bone loss, and their impact on calcium deposition in the vascular wall.

CALCIFICATION AND ESRD: A CONNECTION TO CARDIOVASCULAR DISEASE?

The strong association between coronary artery disease and ESRD may be partly explained by the many risk factors shared by the two conditions, such as advanced age, hypertension, diabetes mellitus, hyperhomocysteinemia, and hyperlipidemia.[3,4] As reviewed separately in this supplement,[5] recent attention has focused on disorders of calcium and phosphate metabolism and their treatments as potential accelerants of cardiovascular disease in ESRD. Briefly, decreased phosphate excretion and hypovitaminosis D cause hyperphosphatemia and subsequent hyperparathyroidism.[6–8] These changes cause altered bone metabolism with skeletal bone resorption (renal osteodystrophy) and extraosseal calcifications (FIGURE 1). Extraosseal cal-

Downloaded from www.ccjm.org on April 20, 2024. For personal use only. All other uses require permission.

cifications apparently result from passive precipitation of calcium if the level of the calcium/phosphate product in blood increases above local conditions of saturation.[6] Calcifications are prominent in the kidney but have also been described in various cardiovascular tissues, such as heart valves, myocardium, and coronary arteries.[9–12] Clear and compelling data have shown an increased prevalence of cardiac calcifications in ESRD, especially after long-term dialysis, but the pathogenesis and clinical significance of these calcifications are incompletely understood.

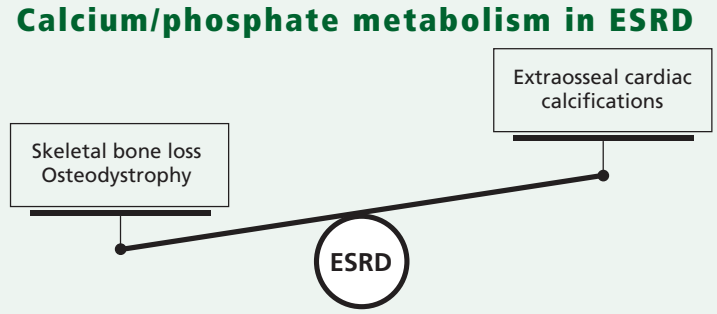

FIGURE 1. Balance between skeletal bone loss and extraosseal calcification in patients with end-stage renal disease (ESRD).

CORONARY CALCIFICATIONS AND ATHEROSCLEROTIC PLAQUE

Two seemingly discordant principles must be understood about the role of calcification in the development of atherosclerotic coronary plaques and their relation to coronary risk:

- The prevalence of coronary atherosclerosis and calcifications is high in persons who do not have clinically evident coronary artery disease.
- Plaque rupture and acute coronary syndrome can occur without calcification and, in fact, may be more frequently associated with noncalcified, soft plaque.

Biology of coronary calcifications

Coronary artery calcifications occur almost exclusively at sites of atherosclerotic lesions.[13] Calcification in the development of these plaques is a complicated, actively regulated process of mineralization that is similar to bone formation and remodeling.[14–17] Coronary artery calcification is found in small amounts in early lesions and more extensively in advanced lesions (FIGURE 2).[18]

Calcium phosphate (hydroxyapatite) is formed in vesicles that pinch off from arterial wall cells, analogous to the way that matrix vesicles pinch off from chondrocytes in developing bone. A close spatial association exists between cholesterol deposits and hydroxyapatite. Atherosclerotic lesions in younger adults reveal small aggregates of crystalline calcium among the lipid particles of the necrotic plaque core. It has been postulated that membrane vesicles derived from apoptotic foam cells within extracellular, lipid-rich necrotic plaque cores may serve as the sites of calcium deposits. Macrophages in atherosclerotic lesions express 1-alpha-hydroxylase activity, producing 1,25-vitamin D,[19] and also have osteoclastic capacity for phagocytic removal of calcium mineral from the artery wall.

Epidemiology of coronary calcifications

There are many risk factors for coronary artery calcifications besides ESRD,[20–23] including advanced age,[22] male gender,[24] elevated plasma cholesterol,[25,26] diminished high-density lipoprotein cholesterol,[26] cigarette smoking,[20,21] elevated blood pressure,[21] obesity,[26] diabetes,[20] and elevated triglycerides.[26]

Coronary calcifications and atherosclerotic plaque are much more common than clinically symptomatic coronary artery disease, positive stress tests, or angiographic stenosis. Coronary calcification is present in 50% of persons 40 to 49 years old and 80% of those 60 to 69 years old.[21,23,24,27–30] Similarly, histologic studies and intravascular ultrasonography show that the prevalence of atherosclerotic plaque rises from 40% to 50% among persons 20 to 29 years old to 60% to 80% among those 30 to 39 years old.[31,32] However, results from the Framingham study[33] indicate that the expected 8-year incidence of coronary events ranges from less than 1% for persons younger than 40 to 15% for those older than 80, and significant angiographic stenoses are present in 30% of persons 60 to 69 years old.[34] Thus, the prevalence of coronary calcifications correlates better with the prevalence of atherosclerotic plaque than with coronary events[35,36]

The prevalence of cardiac calcifications is increased with ESRD, especially after long-term dialysis

Downloaded from www.ccjm.org on April 20, 2024. For personal use only. All other uses require permission.

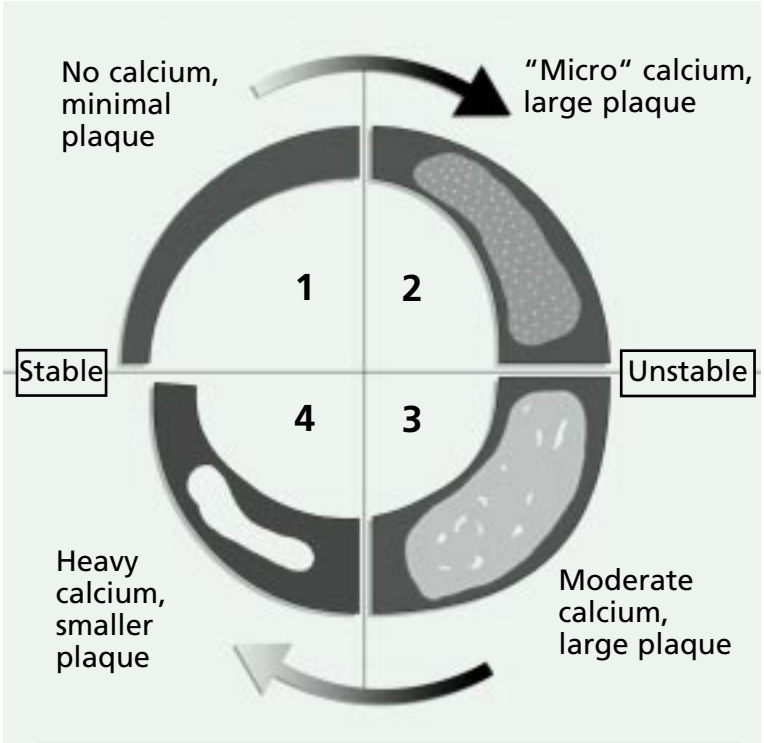

FIGURE 2. Atherosclerotic lesion development and the role of calcification. Different phases of plaque development are shown in the four quadrants, indicating temporal development. Calcium's role in lesion instability is complex and incompletely understood.

or angiographically severe stenosis.

Atherosclerotic plaque and coronary calcifications are frequently present in asymptomatic persons. While the overall plaque burden may predict cardiovascular risk, only a small proportion of persons with atherosclerosis and detectable coronary calcium will eventually experience clinical coronary events.

Plaque vulnerability and acute coronary syndromes

Traditional models of coronary artery disease described slow, progressive plaque growth with increasing passive calcification, eventually leading to vessel occlusion and acute coronary syndromes. According to these models, the amount of calcification in individual lesions should be directly related to the risk of these lesions causing ischemic events. These advanced, calcified plaques were often compared to "rusty pipes."

More recent vascular biology studies show that this analogy is incomplete and even misleading.[37,38] Several angiographic studies show that the progression of coronary artery disease in humans is neither linear nor predictable.[39–42] It has become apparent that sudden, episodic changes of mildly stenotic coronary plaques residing in the vessel wall are most important in disease progression.[43] Most acute coronary events result from rupture of these "vulnerable" plaques, which often accompany more advanced atherosclerotic lesions, and subsequent thrombosis.[37] These vulnerable lesions may account for as many as two thirds of cases of unstable angina or other acute coronary syndromes.

"Plaque vulnerability" describes the tendency of atherosclerotic lesions to cause acute coronary syndromes. Vulnerable lesions are characterized by an accumulation of inflammatory cells and the formation of a lipid-rich, necrotic core separated from the lumen by a fibrous cap.[43–45] The relatively large size of these atheromas is not well reflected by luminal stenosis because adaptive arterial enlargement maintains lumen size in spite of increasing plaque burden. This compensatory vessel enlargement in response to plaque growth is termed positive arterial remodeling[46–48] and appears to be associated with development of acute coronary syndromes.[49–52]

The junction between the necrotic core of the plaque and the normal vessel wall (plaque shoulder) is a location of high stress that is predisposed to rupture.[53,54] Local secretion of proteolytic enzymes (such as matrix metalloproteinases and myeloperoxidase) by smooth muscle cells and macrophages contributes to degradation of the intercellular matrix of the fibrous cap, initiating plaque rupture.[55,56]

As described above, coronary artery wall calcification is part of the development of atherosclerosis. The relation of coronary calcifications to the probability of plaque rupture is unknown, and plaques vulnerable to rupture or erosion are frequently not calcified.[17,57] In fact, intravascular ultrasonography indicates that vulnerable plaques are most often not calcified[49,50,58,59] and that calcification is associated with plaques causing stable rather than unstable coronary syndromes.

It has been hypothesized that early micro-

Downloaded from www.ccjm.org on April 20, 2024. For personal use only. All other uses require permission.

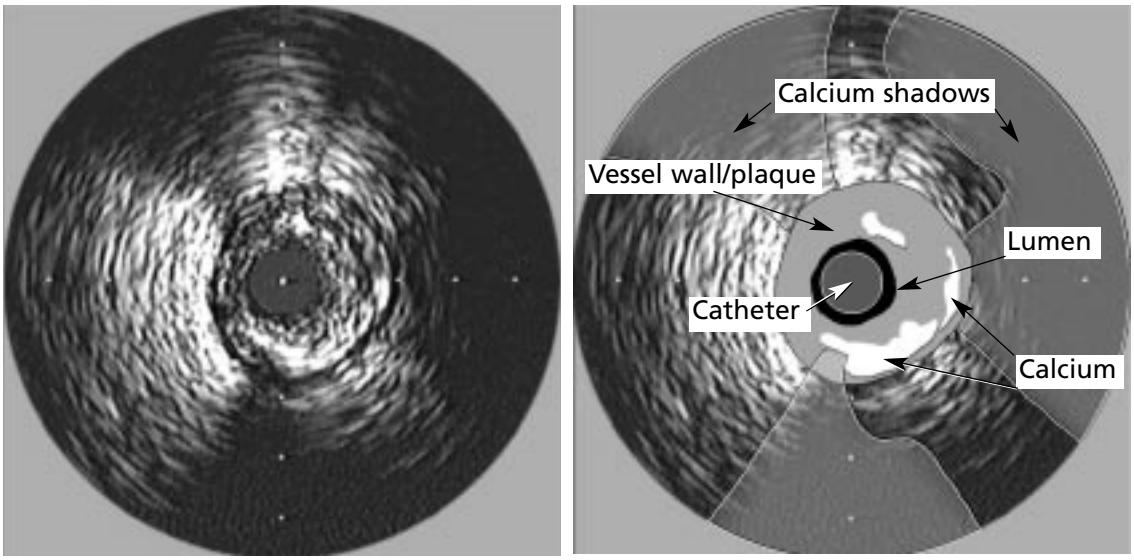

FIGURE 3. Intravascular ultrasound image of a highly stenotic, calcified coronary lesion.

calcifications near the junction of the plaque and the adjacent normal intima may lead to increased stress at the interface between calcified and noncalcified atherosclerotic sections, which could facilitate plaque rupture. However, more extensive calcification and fibrosis of the vessel could eventually eliminate these weak points and reduce the risk of rupture. Biomechanical data support the concept that calcified lesions are much stiffer than cellular lesions and are unlikely to be associated with sites of plaque rupture.[60] According to these concepts, calcifications could in fact represent an attempt to stabilize weakened atherosclerotic plaque prone to rupture.

METHODS FOR IDENTIFYING LESION CALCIFICATIONS

Intravascular ultrasonography

Intravascular ultrasonography, performed during cardiac catheterization, provides tomographic images of the vessel wall that demonstrate vessel size, plaque size, and plaque morphology.[61,62] A miniature ultrasound catheter is placed beyond the target lesion site and is then withdrawn during continuous imaging, resulting in a series of cross-sections. The vessel wall of each cross-section can be described by its signal characteristics on a continuum from echodense (bright echo signal) to echolucent (faint echo signal).

Several studies demonstrate the reliability of ultrasound imaging in predicting the composition of atherosclerotic plaque relative to histology.[58,59] Calcified tissues are recognized as bright echoes with a characteristic signal shadow (FIGURES 3 AND 4).

Ultrasound imaging shows significant superiority over fluoroscopy or angiography in detecting coronary calcification.[63] The severity of calcification has been quantified according to the angle subtended by the calcified arc of the vessel wall.[64,65] When calcium was detected angiographically, the calcification detected by ultrasound was likely greater than 90 degrees.[64] The image characteristics of microcalcifications, as described above, are incompletely understood.[57]

Only a small share of patients with atherosclerosis and coronary calcium will experience coronary events

Computed tomography

Computed tomography (CT) is very sensitive in detecting and quantifying coronary artery calcifications and can survey the entire coronary tree noninvasively. Computed tomography techniques are described more fully in an accompanying article in this supplement.[66] Briefly, different calcium scoring algorithms, including the traditional Agatston score,[67] the total calcium volume score,[68,69] and calcium mass,[70,71] can be applied to either electron-beam CT or mechanical CT images and provide a measure of total coronary plaque burden.[72,73] The prognostic value of this informa-

Downloaded from www.ccjm.org on April 20, 2024. For personal use only. All other uses require permission.

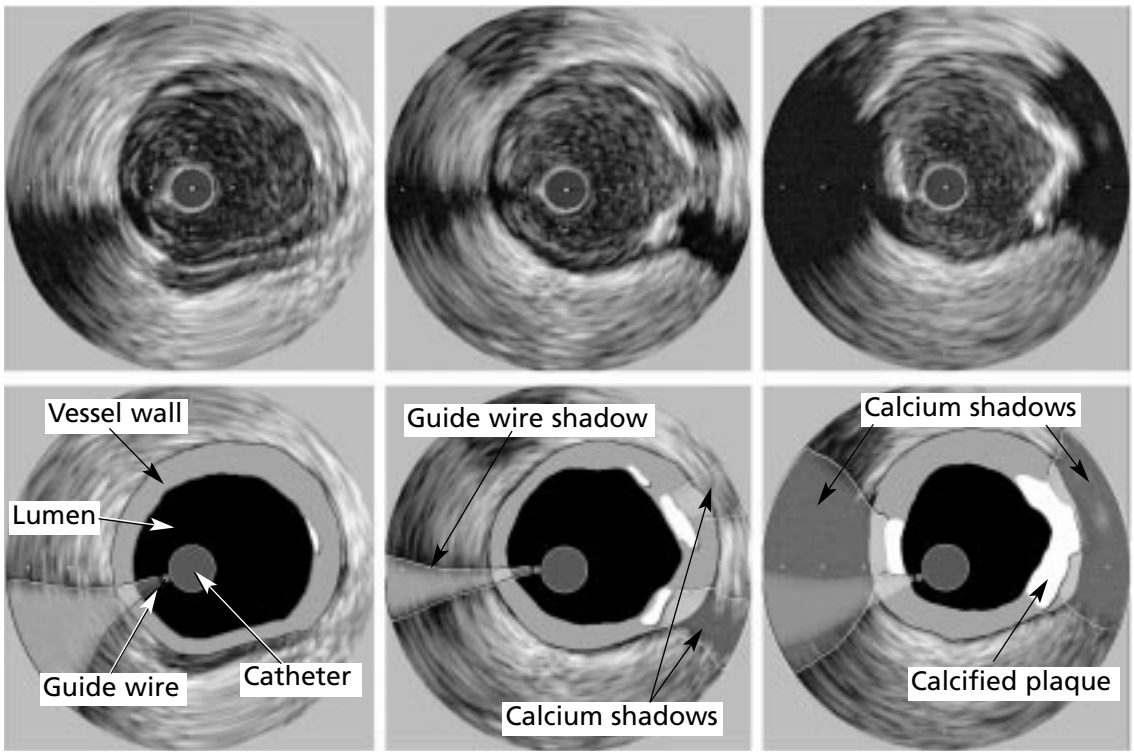

FIGURE 4. Intravascular ultrasound images of a mildly stenotic plaque with calcification. Three adjacent images of the same lesion are shown.

Reliable identification of vulnerable plaques is currently not possible

tion has been examined in several studies[74] in individuals without chronic renal failure, as discussed in detail elsewhere in this supplement.[66] Because compensatory vessel enlargement (positive remodeling) allows plaque accumulation without stenosis, the correlation of calcium area with luminal dimension is only moderate.[75,76]

Coronary angiography

Coronary angiography is not a sensitive method for evaluating calcification compared with intravascular ultrasound and CT.[63,64,77–79] The coronary angiogram shows a silhouette of the vessel lumen but not the vessel wall and plaque.[38,80] Information on calcifications of the vessel wall is limited, although the extent of fluoroscopic calcifications is a marker of the overall atherosclerotic disease burden and does have prognostic value.[81–83]

Magnetic resonance imaging

Magnetic resonance imaging (MRI) is a noninvasive technique that differentiates tissue structures on the basis of their proton magnetic properties. A wide range of image contrast can be obtained with different pulse sequences, which is more helpful for differentiation of soft-tissue structures than for calcifications.[84–86] Shinnar et al[86] described the diagnostic accuracy of MRI for plaque characterization and emphasized the significant technical improvements in resolution and gating that are needed before this technique can be used to examine coronary arteries in clinical settings.

CLINICAL IMPLICATIONS OF CORONARY CALCIFICATION IN ESRD

Uncertain value for risk assessment

Noninvasive quantification of coronary calcium with electron-beam CT calcium scores has been shown to reflect the total atherosclerotic plaque burden,[17,35,36] at least in individuals without chronic renal failure. For this reason, CT can help to predict future risk and offers the potential, through serial imaging, to follow disease progression, stabilization, and possible regression.[87,88] This information can

Downloaded from www.ccjm.org on April 20, 2024. For personal use only. All other uses require permission.

help guide the aggressiveness of risk-factor modification.

However, according to a current consensus statement of the American Heart Association and American College of Cardiology,[89] the incremental value of calcium scores over "traditional" multivariate risk-assessment models has not yet been established. This consensus statement does not recommend CT screening of coronary calcification for asymptomatic individuals, but it concludes that such screening may be justified in select patient groups with intermediate risk (ie, those in whom CT results could change the aggressiveness of risk-factor modification).

Applying these consensus recommendations to patients with chronic renal failure or ESRD is particularly difficult. As discussed above, these patients are already in a high-risk group and aggressive risk-factor modification may be justified independent of the CT result. It is conceivable that asymptomatic young patients with moderate renal failure could fall into an intermediate-risk group. This needs to be examined in further studies, especially since current guidelines for lipid management do not provide specific recommendations for patients with ESRD.

Vulnerable plaques hard to pinpoint

It is important to understand that calcium scoring has prognostic value but does not localize areas of vulnerable plaque. Studies in individuals without chronic renal failure show that coronary calcium scores correlate with atherosclerotic plaque burden. However, while more calcifications (ie, a higher calcium score) may be associated with a greater number of vulnerable plaques overall, coronary calcifications of individual lesions are not markers of lesion vulnerability and are often found in stable patients.[90] Currently, reliable identification of vulnerable plaques is not possible,[91] but preliminary results with intravascular ultrasound[92] and contrast-enhanced multislice CT[93,94] demonstrate the potential role of these tomographic imaging techniques.

Role of medications

The derangements of calcium, phosphate, vitamin D, and parathyroid hormone in patients with chronic renal failure or ESRD are characterized by extraosseal calcifications (**FIGURE 1**), including cardiac calcifications. The high prevalence of coronary calcification in ESRD occurs in a clinical context far removed from the extensive studies done on coronary calcifications and cardiac risks in persons without chronic renal failure. This context includes the common use of calcium, calcium-containing phosphate binders, and pharmacologic doses of vitamin D in a setting where renal clearance of calcium and phosphate is markedly reduced or absent.

As a result, questions arise about the effect of these medications on coronary calcifications and how to interpret calcifications in this markedly different patient population. For example, excessive intake of vitamin D or its metabolites and analogues may lead to arterial calcifications,[95,96] but appropriate doses of vitamin D metabolites given to control secondary hyperparathyroidism might actually reduce the propensity for vascular calcification.[97]

A direct interaction between these medications and coronary calcifications has not been consistently shown. In addition, there is no evidence of an increased risk of coronary calcifications independent of atherosclerotic atheroma burden. Therefore, the pharmacologic control of calcium and phosphate metabolism should be directed by the patient's nephrologic and endocrinologic needs and not be withheld for concern about coronary calcifications. The cardiologist should emphasize aggressive cardiovascular risk-factor modification to slow progression of coronary artery disease in patients with ESRD. This includes tight control of hypertension, diabetes mellitus, and lipid abnormalities. Unfortunately, current lipid management guidelines do not specify a particular strategy for patients with ESRD.

Guidelines for lipid management do not specify a strategy for patients with ESRD

CONCLUSION

Studies in subjects without chronic renal failure indicate that coronary calcifications are a manifestation of coronary atherosclerosis and develop in an actively controlled mineralization process. Their quantity correlates with the overall extent of atherosclerotic disease burden. The role of coronary calcifications in

Downloaded from www.ccjm.org on April 20, 2024. For personal use only. All other uses require permission.

the development of acute coronary syndromes is complex and incompletely understood. Calcification of individual lesions may not be a marker of lesion instability. However, the presence of calcified lesions implies the likely association of lipid-rich and possibly unstable plaque.

Although calcified coronary lesions are more common in patients with ESRD, no independent increase in cardiovascular risk has been associated with these calcifications. Current evidence does not support the concept that specific attempts to reduce coronary calcium may benefit patients with renal failure. On the other hand, these patients have a high risk of developing coronary artery disease and are candidates for aggressive risk-factor modification, including control of hypertension, diabetes mellitus, and hypercholesterolemia.

CT helps to predict future risk and enables monitoring of disease progression

REFERENCES

1. **Foley RN, Parfrey PS, Sarnak MJ.** Clinical epidemiology of cardiovascular disease in chronic renal disease. Am J Kidney Dis 1998; 32:S112–S119.
2. **U.S. Renal Data System.** USRDS 200 Annual Report. Bethesda, Md: National Institute of Diabetes and Digestive and Kidney Diseases; June 2000.
3. **Rostand SG.** Coronary heart disease in chronic renal insufficiency: some management considerations. J Am Soc Nephrol 2000; 11:1948–1956.
4. **Moustapha A, Gupta A, Robinson K, et al.** Prevalence and determinants of hyperhomocysteinemia in hemodialysis and peritoneal dialysis. Kidney Int 1999; 55:1470–1475.
5. **Fatica RA, Dennis VW.** Cardiovascular mortality in chronic renal failure: hyperphosphatemia, coronary calcification, and the role of phosphate binders. Cleve Clin J Med 2002; 69(suppl 3):S-21–S-27.
6. **Block GA, Hulbert-Shearon TE, Levin NW, Port FK.** Association of serum phosphorus and calcium x phosphate product with mortality risk in chronic hemodialysis patients: a national study. Am J Kidney Dis 1998; 31:607–617.
7. **Rostand SG, Drueke TB.** Parathyroid hormone, vitamin D, and cardiovascular disease in chronic renal failure. Kidney Int 1999; 56:383–392.
8. **Watson KE, Abrolat ML, Malone LL, et al.** Active serum vitamin D levels are inversely correlated with coronary calcification. Circulation 1997; 96:1755–1760.
9. **Schwarz U, Buzello M, Ritz E, et al.** Morphology of coronary atherosclerotic lesions in patients with end-stage renal failure. Nephrol Dial Transplant 2000; 15:218–223.
10. **Maher ER, Young G, Smyth-Walsh B, Pugh S, Curtis JR.** Aortic and mitral valve calcification in patients with end-stage renal disease. Lancet 1987; 2:875–877.
11. **Maher ER, Pazianas M, Curtis JR.** Calcific aortic stenosis: a complication of chronic uremia. Nephron 1987; 47:119–122.
12. **Rostand SG, Sanders C, Kirk KA, Rutsky EA, Fraser RG.** Myocardial calcification and cardiac dysfunction in chronic renal failure. Am J Med 1988; 85:651–657.
13. **Blankenhorn DH.** Coronary arterial calcification: a review. Am J Med Sci 1961; 242:41–49.
14. **Demer LL.** A skeleton in the atherosclerosis closet. Circulation 1995; 92:2029–2032.
15. **Fitzpatrick LA, Severson A, Edwards WD, et al.** Diffuse calcification in human coronary arteries. Association of osteopontin with atherosclerosis. J Clin Invest 1994; 94:1597–1604.
16. **Doherty TM, Detrano RC.** Coronary arterial calcification as an active process: a new perspective on an old problem. Calcif Tissue Int 1994; 54:224–230.
17. **Wexler L, Brundage B, Crouse J, et al.** Coronary artery calcification: pathophysiology, epidemiology, imaging methods, and clinical implications. Circulation 1996; 94:1175–1192.
18. **Lee RT, Grodzinsky AJ, Frank EH, Kamm RD, Schoen FJ.** Structure-dependent dynamic mechanical behavior of fibrous caps from human atherosclerotic plaques. Circulation 1991; 83:1764–1770.
19. **Cadranel J, Garabedian M, Milleron B, Guillozo H, Akoun G, Hance AJ.** 1,25(OH)2D2 production by T lymphocytes and alveolar macrophages recovered by lavage from normocalcemic patients with tuberculosis. J Clin Invest 1990; 85:1588–1593.
20. **Detrano RC, Wong ND, French WJ, et al.** Prevalence of fluoroscopic coronary calcific deposits in high-risk asymptomatic persons. Am Heart J 1994; 127:1526–1532.
21. **Goel M, Wong ND, Eisenberg H, Hagar J, Kelly K, Tobis JM.** Risk factor correlates of coronary calcium as evaluated by ultrafast computed tomography. Am J Cardiol 1992; 70:977–980.
22. **Lie JT, Hammond PI.** Pathology of the senescent heart: anatomic observations on 237 autopsy studies of patients 90 to 105 years old. Mayo Clin Proc 1988; 63:552–564.
23. **Beadenkopf WG, Daoud AS, Love BM.** Calcification in the coronary arteries and its relationship to arteriosclerosis and myocardial infarction. Am J Roentgenol 1964; 92:865–871.
24. **Wong ND, Kouwabunpat D, Vo AN, et al.** Coronary calcium and atherosclerosis by ultrafast computed tomography in asymptomatic men and women: relation to age and risk factors. Am Heart J 1994; 127:422–430.
25. **Hoeg JM, Feuerstein IM, Tucker EE.** Detection and quantitation of calcific atherosclerosis by ultrafast computed tomography in children and young adults with homozygous familial hypercholesterolemia. Arterioscler Thromb 1994; 14:1066–1074.
26. **Mahoney LT, Burns TL, Stanford W, et al.** Coronary risk factors measured in childhood and young adult life are associated with coronary artery calcification in young adults: the Muscatine Study. J Am Coll Cardiol 1996; 27:277–284.
27. **Blankenhorn DH, Stern D.** Calcification of the coronary arteries. Am J Roentgenol 1959; 81:772–777.
28. **Eggen DA, Strong JP, McGill HC Jr.** Coronary calcification: relationship to clinically significant coronary lesions and race, sex, and topographic distribution. Circulation 1965; 32:948–955.
29. **Frink RJ, Achor RW, Brown AL Jr, Kincaid OW, Brandenburg RO.** Significance of calcifications of the coronary arteries. Am J Cardiol 1970; 26:241–247.
30. **Janowitz WR, Agatston AS, Kaplan G, Viamonte M Jr.** Differences in prevalence and extent of coronary artery calcium detected by ultrafast computed tomography in asymptomatic men and women. Am J Cardiol 1993; 72:247–254.
31. **Strong JP, Malcom GT, McMahan CA, et al.** Prevalence and extent of atherosclerosis in adolescents and young adults: implications for prevention from pathobiological determinants of atherosclerosis in youth study. JAMA

Downloaded from www.ccjm.org on April 20, 2024. For personal use only. All other uses require permission.

1999; 281:727–735.
32. **Tuzcu EM, Kapadia SR, Tutar E, et al.** High prevalence of coronary atherosclerosis in asymptomatic teenagers and young adults. Circulation 2001; 103:2705–2710.
33. **Grundy SM, Pasternak R, Greenland P, Smith S, Fuster V.** Assessment of cardiovascular risk by use of multiple-risk-factor assessment equations. J Am Coll Cardiol 1999; 34:1348–1359.
34. **Tejada C, Strong JP, Montenegro MR, Restrepo C, Solberg LA.** Distribution of coronary and aortic atherosclerosis by geographic location, race, and sex. Lab Invest 1968; 18:509–526.
35. **Simons DB, Schwartz RS, Edwards WD, Sheedy PF, Breen JF, Rumberger JA.** Noninvasive definition of anatomic coronary artery disease by ultrafast computed tomographic scanning: a quantitative pathologic comparison study. J Am Coll Cardiol 1992; 20:1118–1126.
36. **Rumberger JA, Simons DB, Fitzpatrick LA, Sheedy PF, Schwartz RS.** Coronary artery calcium area by electron-beam computed tomography and coronary atherosclerotic plaque area. Circulation 1995; 92:2157–2162.
37. **Libby P.** Molecular bases of the acute coronary syndromes. Circulation 1995; 91:2844–2850.
38. **Libby P.** Current concepts of the pathogenesis of the acute coronary syndromes. Circulation 2001; 104:365–372.
39. **Giroud D, Li JM, Urban P, Meier B, Rutishauser W.** Relation of the site of acute myocardial infarction to the most severe coronary arterial stenosis prior to angiography. Am J Cardiol 1992; 69:729–732.
40. **Ambrose JA, Tannenbaum MA, Alexopoulos D, et al.** Angiographic progression of coronary artery disease and the development of myocardial infarction. J Am Coll Cardiol 1988; 12:56–62.
41. **Little WC, Constantinescu M, Applegate RJ, et al.** Can coronary angiography predict the site of a subsequent myocardial infarction in patients with mild-to-moderate coronary artery disease? Circulation 1988; 78:1157–1166.
42. **Ambrose JA, Winters SL, Arora RR, et al.** Angiographic evolution of coronary artery morphology in unstable angina. J Am Coll Cardiol 1986; 7:472–478.
43. **Ross R.** The pathogenesis of atherosclerosis: a perspective for the 1990s. Nature 1993; 362:801–809.
44. **Moreno PR, Falk E, Palacios IF, Newell JB, Fuster V, Fallon JT.** Macrophage infiltration in acute coronary syndromes: implications for plaque rupture. Circulation 1994; 90: 775–778.
45. **Shah PK, Falk E, Badimon JJ, et al.** Human monocyte-derived macrophages induce collagen breakdown in fibrous caps of atherosclerotic plaques. Circulation 1995; 92:1565–1569.
46. **Glagov S, Weisenberg E, Zarins CK, Stankunavicius R, Kolettis GJ.** Compensatory enlargement of human atherosclerotic coronary arteries. N Engl J Med 1987; 316:1371–1375.
47. **Gibbons GH, Dzau VJ.** The emerging concept of vascular remodeling. N Engl J Med 1994; 330:1431–1438.
48. **Clarkson TB, Prichard RW, Morgan TM, Petrick GS, Klein KP.** Remodeling of coronary arteries in human and non-human primates. JAMA 1994; 271:289–294.
49. **Schoenhagen P, Ziada KM, Kapadia SR, Crowe TD, Nissen SE, Tuzcu EM.** Extent and direction of arterial remodeling in stable and unstable coronary syndromes. Circulation 2000; 101:598–603.
50. **Smits PC, Pasterkamp G, de Jaegere PPT, de Feyter PJ, Borst C.** Angioscopic complex lesions are predominantly compensatory enlarged: an angioscopic and intracoronary ultrasound study. Cardiovasc Res 1999; 41:458–464.
51. **Nakamura M, Nishikawa H, Mukai S, et al.** Impact of coronary artery remodeling on clinical presentation of coronary artery disease: an intravascular ultrasound study. J Am Coll Cardiol 2001; 37:63–69.
52. **Wexberg P, Gyongyosi M, Sperker W, et al.** Pre-existing arterial remodeling is associated with in-hospital and late adverse cardiac events after coronary interventions in patients with stable angina pectoris. J Am Coll Cardiol 2000; 36:1860–1869.
53. **Richardson PD, Davies MJ, Born GV.** Influence of plaque configuration and stress distribution on fissuring of coronary atherosclerotic plaques. Lancet 1989; 2:941–944.
54. **Loree HM, Kamm RD, Stringfellow RG, Lee RT.** Effects of fibrous cap thickness on peak circumferential stress in model atherosclerotic vessels. Circ Res 1992; 71:850–858.
55. **Schoenhagen P, Vince DG, Ziada K, et al.** Increased presence of matrix-metalloproteinase 3 in human coronary lesions with positive arterial remodeling [abstract]. J Am Coll Cardiol 2000; 35(2supplA):58A.
56. **Pasterkamp G, Schoneveld AH, Hijnen DJ, et al.** Atherosclerotic arterial remodeling and the localization of macrophages and matrix metalloproteases 1, 2 and 9 in the human coronary artery. Atherosclerosis 2000; 150:245–253.
57. **Schmermund A, Erbel R.** Unstable coronary plaque and its relation to coronary calcium. Circulation 2001; 104:1682–1687.
58. **Gussenhoven EJ, Essed CE, Lancee CT, et al.** Arterial wall characteristics determined by intravascular ultrasound imaging: an in vitro study. J Am Coll Cardiol 1989; 14: 947–952.
59. **Hodgson JMcB, Reddy KG, Suneja R, Nair RN, Lesnefsky EJ, Sheehan HM.** Intracoronary ultrasound imaging: correlation of plaque morphology with angiography, clinical syndrome, and procedural results in patients undergoing coronary angioplasty. J Am Coll Cardiol 1993; 21:35–44.
60. **Huang H, Virmani R, Younis H, Burke AP, Kamm RD, Lee RT**. The impact of calcification on the biomechanical stability of atherosclerotic plaques. Circulation 2001; 103:1051–1056.
61. **Nissen SE, Gurley JC, Grines CL, et al.** Intravascular ultrasound assessment of lumen size and wall morphology in normal subjects and patients with coronary artery disease. Circulation 1991; 84:1087–1099.
62. **Nissen SE, Yock P.** Intravascular ultrasound: novel pathophysiological insights and current clinical applications. Circulation 2001; 103:604–616.
63. **Mintz GS, Douek P, Pichard AD, et al.** Target lesion calcification in coronary artery disease: an intravascular ultrasound study. J Am Coll Cardiol 1992; 20:1149–1155.
64. **Tuzcu EM, Berkalp B, De Franco AC, et al.** The dilemma of diagnosing coronary calcification: angiographic versus intravascular ultrasound. J Am Coll Cardiol 1996; 27: 832–838.
65. **Honye J, Mahon DJ, Jain A, et al.** Morphological effects of coronary balloon angioplasty in vivo assessed by intravascular ultrasound imaging. Circulation 1992; 85:1012–1025.
66. **Halliburton SS, Stillman AE, White RD.** Noninvasive quantification of coronary artery calcification: methods and prognostic value. Cleve Clin J Med 2002; 69(suppl 3): S-6–S-11.
67. **Agatston AS, Janowitz WR, Hildner FJ, Zusmer NR, Viamonte M, Detrano R.** Quantification of coronary artery calcium using ultrafast computed tomography. J Am Coll Cardiol 1990; 15:827–832.
68. **Callister TQ, Cooil B, Raya SP, Lippolis NJ, Russo DJ, Raggi P.** Coronary artery disease: improved reproducibility of calcium scoring with an electron-beam CT volumetric method. Radiology 1998; 208:807–814.
69. **Callister T, Janowitz W, Raggi P.** Sensitivity of two electron beam tomography protocols for the detection and quantification of coronary artery calcium. AJR Am J

Downloaded from www.ccjm.org on April 20, 2024. For personal use only. All other uses require permission.

Roentgenol 2000; 175:1743–1746.
70. **Yoon HC, Greaser LE, Mather R, Sinha S, McNitt-Gray MF, Goldin JG.** Coronary artery calcium: alternate methods for accurate and reproducible quantitation. Acad Radiol 1997; 10:666–673.
71. **Detrano R, Tang W, Kang X, et al.** Accurate coronary calcium phosphate mass measurements from electron beam computed tomograms. Am J Card Imaging 1995; 3:167–173.
72. **Becker CR, Knez A, Leber A, et al.** Initial experience with multi-slice detector spiral CT in diagnosis of arteriosclerosis of coronary vessels. Radiologe 2000; 40:118–122.
73. **Becker CR, Kleffel T, Crispin A, et al.** Coronary artery calcium measurement: agreement of multirow detector and electron beam CT. Am J Roentgenol 2001; 176:1295–1298.
74. **Secci A, Wong N, Tang W, Wang S, Doherty T, Detrano R.** Electron beam computed tomographic coronary calcium as a predictor of coronary events. Circulation 1997; 96:1122–1129.
75. **Tanenbaum SR, Kondos GT, Veselik KE, Prendergast MR, Brundage BH, Chomka EV.** Detection of calcific deposits in coronary arteries by ultrafast computed tomography and correlation with angiography. Am J Cardiology 1989; 63:870–872.
76. **Sangiorgi G, Rumberger JA, Severson A, et al.** Arterial calcification and not lumen stenosis is highly correlated with atherosclerotic plaque burden in humans: a histologic study of 723 coronary artery segments using nondecalcifying methodology. J Am Coll Cardiol 1998; 31:126–133.
77. **Baumgart D, Schmermund A, Goerge G, et al.** Comparison of electron beam computed tomography with intracoronary ultrasound and coronary angiography for detection of coronary atherosclerosis. J Am Coll Cardiol 1997; 30:57–64.
78. **Kajinami K, Seki H, Takekoshi N, Mabuchi H.** Coronary calcification and coronary atherosclerosis: site-by-site comparative morphologic study of electron beam computed tomography and coronary angiography. J Am Coll Cardiol 1997; 29:1549–1556.
79. **Becker CR, Jakobs TF, Aydemir S, et al.** Helical and single-slice conventional CT versus electron beam CT for the quantification of coronary artery calcification. AJR Am J Roentgenol 2000; 174:543–547.
80. **Topol EJ, Nissen SE.** Our preoccupation with coronary luminology: the dissociation between clinical and angiographic findings in ischemic heart disease. Circulation 1995; 92:2333–2342.
81. **Detrano RC, Wong ND, Tang W, et al.** Prognostic significance of cardiac cinefluoroscopy for coronary calcific deposits in asymptomatic high-risk subjects. J Am Coll Cardiol 1994; 24:354–358.
82. **Detrano R, Hsiai T, Wang S, et al.** Prognostic value of coronary calcification and angiographic stenoses in patients undergoing coronary angiography. J Am Coll Cardiol 1996; 27:285–290.
83. **Margolis JR, Chen JTT, Kong Y, Peter RH, Behar VS, Kisslo JA.** The diagnostic and prognostic significance of coronary artery calcification. Radiology 1980; 137:609–616.
84. **Toussaint JF, LaMuraglia GM, Southern JF, Fuster V, Kantor HL.** Magnetic resonance images lipid, fibrous, calcified, hemorrhagic, and thrombotic components of human atherosclerosis in vivo. Circulation 1996; 94:932–938.
85. **Worthley SG, Helft G, Fuster V, et al.** Serial in vivo MRI documents arterial remodeling in experimental atherosclerosis. Circulation 2000; 101:586–589.
86. **Shinnar M, Fallon JT, Wehrli S, et al.** The diagnostic accuracy of ex vivo MRI for human atherosclerotic plaque characterization. Arterioscler Thromb Vasc Biol 1999; 19:2756–2761.
87. **Janowitz WR, Agatston AS, Viamonte M.** Comparison of serial quantitative evaluation of calcified coronary artery plaque by ultrafast computed tomography in persons with and without coronary artery disease. Am J Cardiol 1991; 68:1–6.
88. **Callister TQ, Raggi P, Cooil B, Lippolis NJ, Russo DJ.** Effect of HMG-CoA reductase inhibitors on coronary artery disease by electron-beam computed tomography. N Engl J Med 1998; 339:1972–1978.
89. **O'Rourke RA, Brundage BH, Froelicher VF, et al.** American College of Cardiology/American Heart Association Expert Consensus Document on electron-beam computed tomography for the diagnosis and prognosis of coronary artery disease. Circulation 2000; 102:126–140.
90. **Mintz GS, Pichard AD, Popma JJ, et al.** Determinants and correlates of target lesion calcium in coronary artery disease: a clinical, angiographic and intravascular ultrasound study. J Am Coll Cardiol 1997; 29:268–274.
91. **Schoenhagen P, McErlean ES, Nissen SE.** The vulnerable coronary plaque. J Cardiovasc Nurs 2000; 15:1–12.
92. **Yamagishi M, Terashima M, Awano K, et al.** Morphology of vulnerable coronary plaque: insights from follow-up of patients examined by intravascular ultrasound before an acute coronary syndrome. J Am Coll Cardiol 2000; 35:106–111.
93. **Schroeder S, Kopp AF, Baumbach A, et al.** Noninvasive detection and evaluation of atherosclerotic coronary plaques with multislice computed tomography. J Am Coll Cardiol 2001; 37:1430–1435.
94. **Becker CR, Knez A, Ohnesorge B, Schoepf UJ, Reiser MF.** Imaging of noncalcified coronary plaques using helical CT with retrospective ECG gating. AJR Am J Roentgenol 2000; 175:423–424.
95. **Milliner DS, Zinsmeister AR, Liebermann E, Landing B.** Soft tissue calcification in pediatric patients with end-stage renal disease. Kidney Int 1990; 38:931–936.
96. **Hsu CH.** Are we mismanaging calcium and phosphate metabolism in renal failure? Am J Kidney Dis 1997; 29:641–649.
97. **Watson KE, Abrolat ML, Malone LL, et al.** Active serum vitamin D levels are inversely correlated with coronary calcification. Circulation 1997; 96:1755–1760.

ADDRESS: *E.M. Tuzcu, MD, The Cleveland Clinic Foundation, F25, 9500 Euclid Avenue, Cleveland OH 44195; e-mail tuzcue@ccf.org.*

Downloaded from www.ccjm.org on April 20, 2024. For personal use only. All other uses require permission.