

**ROY K. GREENBERG, MD**

Director, Endovascular Research, Department
of Vascular Surgery, The Cleveland Clinic

Endovascular therapy or conventional vascular surgery? A complex choice

■ ABSTRACT

Endovascular therapy and open vascular surgery have advantages and disadvantages. A single therapeutic option is rarely ideal for all patients. Rather, the two options are tools that are best used selectively; their availability allows for therapy to be tailored to optimize patient care.

■ KEY POINTS

For aneurysms, endovascular repair has a lower incidence of acute morbidity and patients recover faster than with surgery, but surgical repair may offer better long-term protection from aneurysm rupture.

For carotid stenosis, physiologically ill patients can undergo open carotid endarterectomy. However, carotid stenting is preferable in certain circumstances, eg, in patients who have undergone prior neck surgery or radiation therapy to the neck, or with lesions that extend high into the neck. Carotid stenting remains untested in low-risk patients.

Neither surgery nor endovascular therapy is traditionally offered to patients with claudication, as most of them do not develop limb-threatening ischemia. Rather, interventions (open or endovascular) are generally reserved for patients with pain at rest or tissue loss.

Mesenteric and renal artery stenting have replaced open surgical bypass for occlusive lesions in these arteries.

The author has indicated that he has received grant or research support from the Boston Scientific, Cook, Cordis Endovascular, Jomed, and Vascutek corporations and serves as a consultant for the Boston Scientific and Cook corporations.

This paper discusses therapies that are investigational or are not approved by the US Food and Drug Administration for the use under discussion.

ENDOVASCULAR TREATMENTS—angioplasty and stenting for stenoses, thrombolysis for thrombotic lesions, and grafting procedures for aneurysms—now allow us to treat patients less invasively than with open surgery. This is particularly helpful in patients with comorbidities that would previously have precluded any treatment.

For individual patients, however, the choice is more complicated. Endovascular treatments have been compared with traditional surgery in nearly all areas of the body in many clinical series, and despite the plethora of literature, the benefit of one over the other remains hotly debated.

For instance, endovascular aneurysm repair is less traumatic to the patient, but may be less durable and more prone to complications such as leakage at the stenting site. Neither surgery nor endovascular therapy is traditionally offered to patients with claudication unless the case is particularly severe. Yet mesenteric and renal artery stenting have generally replaced the open procedures.

Therefore, patients must be individually assessed to determine the risks and benefits of each therapy, taking into account the patient's arteries, his or her physical condition, and how comfortable the patient and the physician feel with the various options.

This article reviews the options for treating aortic aneurysms, carotid stenosis, peripheral vascular disease of the legs, and stenosis of visceral vessels.

■ ANEURYSMAL DISEASE

When to treat an aneurysm

Abdominal aortic aneurysms have historically been repaired if they are bigger than 5 or 5.5

cm,^{1,2} and thoracic aortic aneurysms are repaired if they exceed 5.5 or 6 cm.³

These criteria are not hard and fast, although they can serve as guidelines for patient referral. Smaller aneurysms may be electively treated in healthy young patients, while an aneurysm of the same size in a frail patient may be simply observed and followed over time.

Two recent randomized trials of observation vs surgery demonstrated that watchful waiting is safe for abdominal aortic aneurysms smaller than 5.5 cm,^{4,5} although about half of the patients in the observation groups eventually had their aneurysms repaired within 4 years.

Whether the aneurysm is treated or not, it is mandatory to treat related medical conditions optimally, including hypertension (best managed with beta-blockers if not contraindicated), platelet aggregation (with aspirin or clopidogrel), and dyslipidemia (with statins).

Surgical treatment of aneurysms

Traditionally, aneurysms of the thoracic and abdominal aorta have been treated with open surgery. This involves a left thoracotomy to expose the thoracic aorta, or a transperitoneal (midline) or retroperitoneal (left flank) incision to expose the abdominal aorta.

Regardless of the route, the aorta must be cross-clamped while the prosthetic graft is interposed immediately proximal and distal to the diseased segment.

Endovascular treatment of aneurysms

Now, aneurysms can also be treated from within the artery with a device called a *stentgraft*, which is a metal stent covered with graft material (FIGURE 1).

The device is constrained within a delivery system that is usually introduced through one of the femoral arteries, accessed through an oblique incision in the groin. Once appropriately positioned, the constraining component of the delivery system is removed, allowing the stentgraft to expand and appose itself to the aortic wall above and below the diseased aortic segment, similar to an open repair.

Complications of open surgery for aneurysm repair

Open surgical repair of abdominal aortic aneurysms is plagued by high rates of serious complications such as death (5% to 6%), myocardial infarction (5%), pulmonary complications (8%), renal failure (1.2%), and limb loss (1%).⁶

Moreover, in a number of reports,⁶⁻⁸ up to 15% of patients who underwent an open repair needed to undergo a second operation, typically to treat a bowel obstruction, false aneurysm, hernia, continued aneurysmal dilation of the more proximal aorta, dilation of the iliac arteries, or erosion between the graft and surrounding structures.

Endovascular complications:

Endoleaks, migration, and material failure

A greater number of patients may require a second intervention after receiving a stentgraft for an abdominal aortic aneurysm, but the reasons and the interventions are entirely different.⁹

One of the problems with endovascular aneurysm repair of the abdominal aorta is that blood can continue to enter the aneurysm sac, a complication called an *endoleak*.^{10,11} The incidence of endoleak varies with different devices, but typically ranges between 10% and 25%. Endoleaks are categorized into five types:

Type 1—leakage around the points of proximal or distal fixation

Type 2—blood entering the aneurysm sac in a retrograde manner through a patent inferior mesenteric artery or lumbar artery (which are typically ligated during an open approach)

Type 3—extravasation of blood through a fabric defect or modular joint

Type 4—due to graft porosity

Type 5—due to transmission of pressure through a thrombus when blood is not visualized in the sac.

Endoleaks are detected and classified by either computed tomography or detailed Doppler ultrasonographic examination of the aneurysm sac. They are almost always asymptomatic and are not universally predictive of a required intervention.

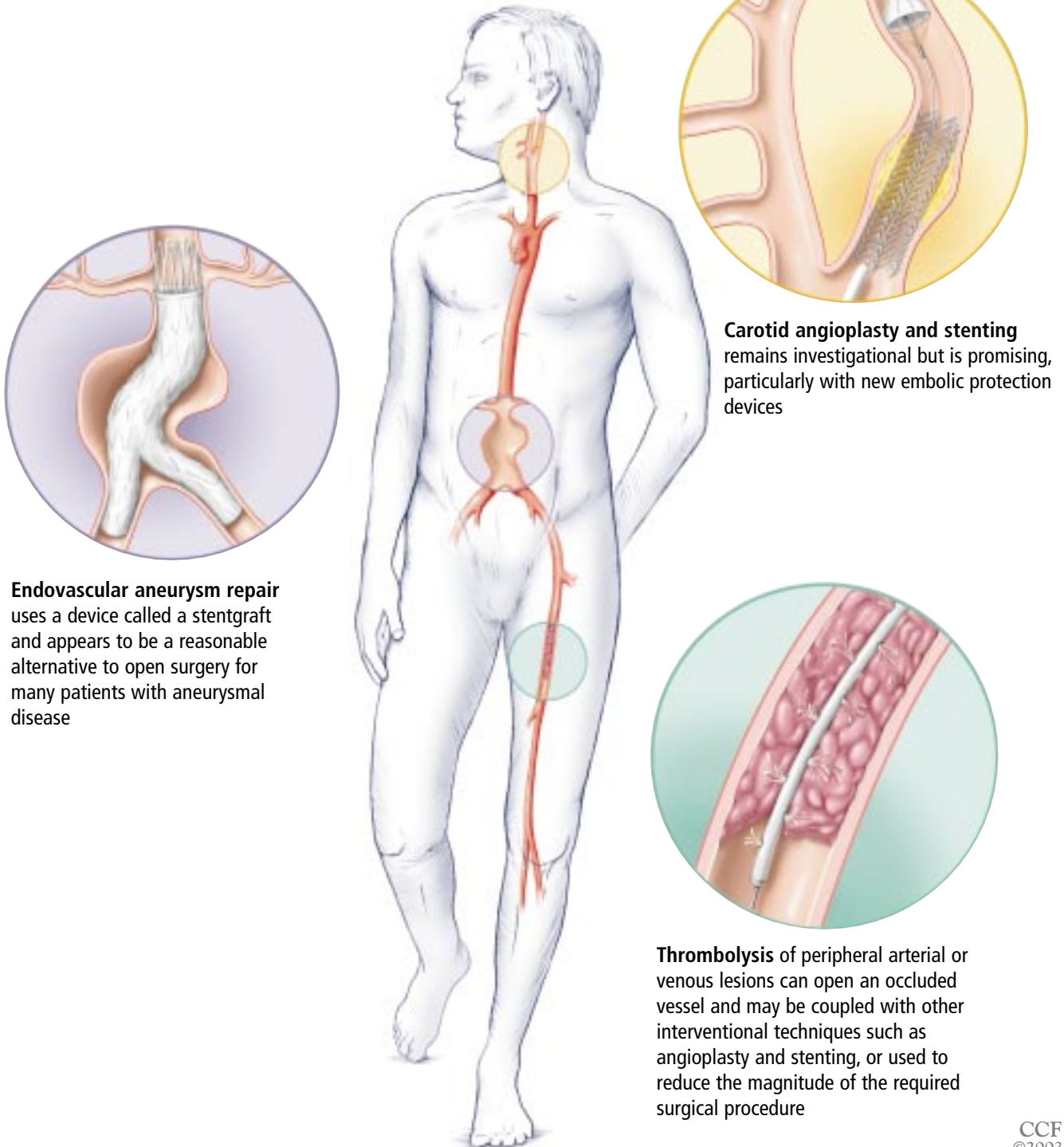
Whether to treat an endoleak depends on the type. Most interventionalists agree that

Watchful waiting is advisable for some abdominal aortic aneurysms < 5.5 cm



■ Endovascular therapy

Endovascular treatments are less invasive than open vascular surgery, but each has advantages and disadvantages, and the choice is often complicated in individual patients.



Endovascular aneurysm repair uses a device called a stentgraft and appears to be a reasonable alternative to open surgery for many patients with aneurysmal disease

Carotid angioplasty and stenting remains investigational but is promising, particularly with new embolic protection devices

Thrombolysis of peripheral arterial or venous lesions can open an occluded vessel and may be coupled with other interventional techniques such as angioplasty and stenting, or used to reduce the magnitude of the required surgical procedure

CCF
©2003

FIGURE 1

TABLE 1

Surgery or endovascular repair for aortic aneurysms?

	LOW ANATOMIC RISK*	HIGH ANATOMIC RISK
Low physiologic risk*	Open surgery or enrollment in a study†	Open surgery
High physiologic risk	Endograft	Endograft if possible using adjunctive techniques

*Physiologic risk is the perceived risk to the patient, were the patient to undergo open surgical repair. Anatomic risk refers to the complexity of the anatomy: eg, a long, straight distance between the renal arteries and the aneurysm would likely be considered a low anatomic risk.

†Healthy patients desiring endovascular repair are treated in this manner, provided they agree to follow-up protocols and understand the risks and benefits involved.

Endovascular aneurysm repair requires meticulous follow-up

aneurysms with a type 1 or 3 endoleak after endovascular repair are still at risk of rupture and that these leaks must be treated. In contrast, approximately 50% of type 2 endoleaks spontaneously seal during the first year of follow-up, and most interventionalists feel that type 2 leaks may not cause long-term problems and may not require therapy in most cases. Whether to treat type 4 and type 5 leaks is controversial.

When therapy is indicated, such as for a type 1 or 3 leak, or a type 2 leak associated with aneurysm expansion, it is often accomplished with an additional endovascular intervention such as additional stentgraft placement or embolization of collateral branches.

Are endovascular stentgrafts durable?

Grafts placed during open surgery are very durable, but endovascular stentgrafts may be less so. Some issues are:

Migration. Surgical grafts are sutured in place proximally and distally, but stentgrafts are held in place through a combination of radial force (from the stent), hooks or barbs, and longitudinal support (stiffness). An ideal means of fixation has not been discovered.

Mechanical failure of the stentgraft. This issue touches on both the material properties of the device (particularly the marriage of the metal stent to the graft material) and the forces to which it is subjected. Although graft material alone rarely degenerates within 10 to 15 years, it can develop accelerated fatigue

when it is combined with metallic structures. Tortuous arteries can make stentgrafts more prone to fatigue, especially if the device is stiff. A more detailed analysis of this topic is presented elsewhere.¹²

If a defect develops in the graft material or the fixation mechanisms are overcome, allowing the device to slip, the aneurysm is again at risk for rupture. This underscores the importance of radiographic follow-up after endovascular repair.

How to decide between surgery or endovascular repair?

Both procedures have advantages and disadvantages. Endovascular aneurysm repair is associated with a lower incidence of acute morbidity, and patients recover faster, with an average 2-day hospital stay. On the other hand, surgical repair offers better long-term protection from aneurysm rupture.

For patients who are too ill to undergo surgery, the choice is between medical therapy and endovascular repair (TABLE 1).¹³ Those who have an aneurysm that is anatomically amenable to endovascular repair are likely best served with that approach.

In contrast, patients who are fit and have an anatomically complex aneurysm not well suited for endovascular repair are better treated with open surgery.

Patients at high physiologic risk with complex anatomy are either treated medically (antihypertensive regimens) or with endografting techniques using adjunctive (less



invasive) surgical methods or newer grafts that are under investigation.

How to manage patients at low physiologic risk who have straightforward anatomy is the most controversial. These patients need a careful explanation of the risks and benefits of each therapy.

In fact, all patients with aneurysms should understand their options. Should endovascular grafting be entertained, the patient must understand that lifelong follow-up will probably be needed, because the long-term durability of the endovascular devices is unknown.

Since we do not yet have any long-term data with contemporary endografts, we cannot make any definitive comparisons between surgery and endovascular treatment. However, a multicenter prospective randomized trial is underway in Europe to evaluate the potential superiority of one technique over the other.¹⁴

Which type of endovascular device?

At this time, there are four commercially available devices (Ancure,¹⁵ Excluder,^{16,17} AneuRx,¹⁸ and Zenith^{19,20}) and four investigational devices (Lifepath,²¹ Powerlink,²² Talent,²³ and Terramed²⁴). It is anticipated that an additional investigational device will be approved by the end of 2003.

The choice of the device depends on the patient's anatomy, the physician's familiarity with the devices, and, for an investigational device, whether the patient is willing to participate in a research trial. Some patients have more options than others, owing to anatomic restrictions.

New procedures using novel techniques and devices have been developed for patients with thoracic, juxtarenal, suprarenal, and ruptured aneurysms, as well as complex aortic dissections (FIGURE 2). Although these procedures are technically complicated, early results have been favorable. Currently, most complex endovascular repair procedures are done only in investigational device protocols.

■ CAROTID DISEASE

Most treatment for occlusive disease within the carotid arteries is done to prevent a stroke. Thus, the treatment is prophylactic (like the

Endovascular repair of a ruptured aneurysm

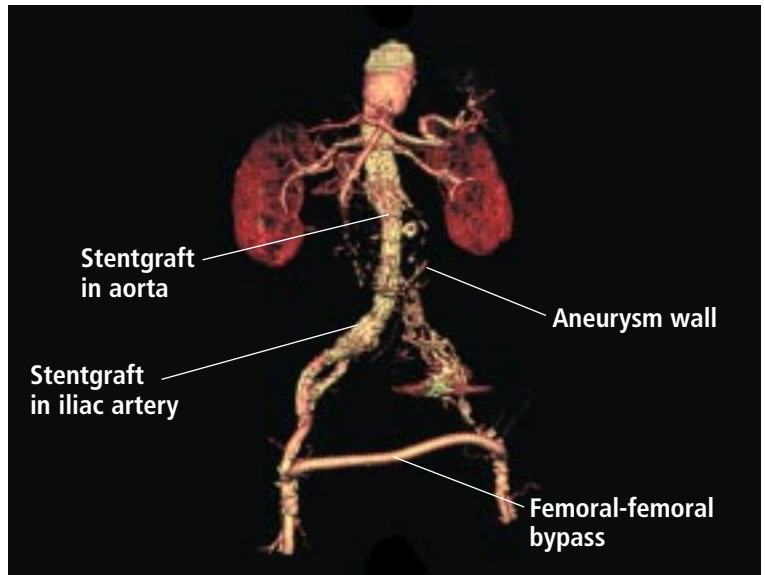


FIGURE 2. This computed tomographic scan reconstruction depicts a follow-up study on a patient who underwent successful endovascular repair of a ruptured abdominal aortic aneurysm with a stentgraft and femoral-femoral bypass.

management of aneurysms), and the physician and patient must understand the natural history of the disease, the risks of stroke with medical therapy, and the risks associated with intervention.

Trials support surgery for carotid disease

Although still controversial, endarterectomy surgery for asymptomatic and symptomatic carotid disease has undergone rigorous study in prospective randomized trials. Two clinical advisories,^{25,26} followed by publications,^{27,28} have tipped the balance in favor of performing surgery early for significant internal carotid artery disease.

The NASCET (North American Symptomatic Carotid Endarterectomy Trial) concluded that patients should undergo carotid endarterectomy if they have symptoms attributable to stenosis and the stenosis is greater than 70%. In these patients, surgery reduced the 5-year risk of ipsilateral stroke to 9%, compared with 25.6% with medical management.²⁹ Patients with symptomatic intermediate-grade stenoses (50%–70%) also benefited from surgery.³⁰

The ACAS (Asymptomatic Carotid Atherosclerosis Study) found that carotid

The balance has tipped in favor of early intervention for internal carotid disease

endarterectomy was beneficial in patients with asymptomatic carotid stenoses in excess of 60%. In men, the 5-year risk of stroke was 4.1% with treatment vs 12.1% without treatment, a relative risk reduction of 66%.²⁹ However, in women, the relative risk reduction was only 17%, although the sex-specific conclusions have been contested by some.³¹

Of note: this benefit was only in patients with a perceived surgical risk of less than 3% and a life expectancy of at least 5 years.

Carotid stenting

Angioplasty and stenting of the carotid artery became somewhat popular in the late 1990s. The procedural risks are relatively low and comparable to those of surgery.^{32–35}

Moreover, devices that prevent embolism during the procedure by occluding the distal carotid artery, by trapping emboli in a filter,^{36–38} or by reversing the flow³⁹ have been reported to decrease the incidence of periprocedural neurologic events,^{34,35} and most interventionalists believe that using these devices will prove to be superior to treatment without such a device.⁴⁰

To date, carotid stenting remains controversial. In the United States the procedure remains investigational, and Medicare and many other insurance companies will provide reimbursement for it only if it is performed under an investigational protocol.

Ongoing trials of carotid stenting

The SAPHIRE trial (Stenting and Angioplasty with Protection in Patients at High Risk for Endarterectomy) is evaluating carotid stenting in patients with and without symptoms who are believed to be at high risk for complications; the CREST (Carotid Endarterectomy vs Stent Trial) is in patients with symptoms. Prospective registries are also accruing patients.

These studies should show whether carotid stenting is inferior, equivalent, or superior to carotid endarterectomy with respect to acute procedural complications and short-term protection from stroke. However, they will tell us little about long-term rates of stroke or restenosis. For that, long-term studies with more patients will be needed.

Carotid stenting procedure

Patients first receive heparin to maintain the activated clotting time greater than 250 seconds. Some interventionalists also use intravenous antiplatelet agents. However, we prefer to give the patient loading doses of the oral antiplatelet drug clopidogrel 3 days before the procedure and maintenance doses for 30 days afterward.

Carotid stenting is performed under local anesthesia. Typically, a long sheath or guide is advanced through the femoral artery and tracked over a wire that is placed in the external carotid artery until the sheath is lodged within the common carotid artery proximal to the stenosis.

Once the sheath is in place, the lesion is crossed with an 0.014" wire. If the lesion is tight, predilation with a small coronary balloon can be performed, although preferably, a protection device would be in place prior to any angioplasty. If one is using a filter-type embolic protection device, access across the lesion may be lost if a "buddy wire" (dual wire access) is not established with the filter wire prior to predilation, in which case the lesion must then be recrossed with an embolic protection device wire. The embolic protection device is deployed at least 5 cm distal to the diseased segment, and the stent is then advanced over the protection device wire.

The stent is deployed to cover approximately 0.5 to 1 cm above and below the lesion. Balloon-expandable stents, which were initially favored, have been largely replaced by more flexible self-expanding stents, some specifically designed for the carotid system.

After the stent delivery system is removed, a balloon that is slightly smaller or equal in diameter to the carotid artery is then used to expand the stent. The embolic protection system is recaptured and withdrawn through the sheath or guide within the common carotid artery after angiography is completed.

The heart must be monitored meticulously throughout the procedure, as bradycardia and ectopy are common due to stretching forces in the region of the carotid sinus.

**Carotid
stenting
remains
controversial
and
investigational**

We obtain a duplex ultrasound scan the following day to determine the amount of baseline of residual stenosis. Follow-up is similar to that for open carotid endarterectomy, with ultrasound examinations at 30 days, 6 months, 12 months, and annually thereafter.

Complications of carotid stenting

Complication rates are similar with carotid stenting vs carotid endarterectomy,³³ but the complications are not entirely comparable. Rates of major problems such as intracranial hemorrhage, stroke (thrombotic or embolic), myocardial infarction, and death are easily compared and are believed to be similar,³³ although the preliminary results of the SAP-PHIRE trial (presented in abstract form⁴¹) demonstrated a lower combined rate of stroke, myocardial infarction, or death in high-risk patients treated with stenting vs open surgery.

Procedure-specific complications include puncture site hematomas, pseudoaneurysms, contrast nephropathy, and noncranial atheroembolic events, which are all difficult to compare with complications of open surgery such as wound infection and cranial nerve injuries.

How to decide between carotid stenting vs endarterectomy?

Ultimately, the decision to undergo an open carotid endarterectomy or carotid stent placement is made by a well-informed patient in conjunction with a physician who is familiar with both treatments. Currently, there is no approved carotid stenting system; therefore, most patients undergoing this form of therapy are enrolled in a clinical trial.

Physiologically ill patients do not necessarily have to forgo open carotid endarterectomy in favor of stenting, because the surgery can be done under local anesthesia and has a similar effect on cardiovascular physiology as carotid stenting.

However, carotid stenting is clearly more preferable in certain circumstances, eg, in patients who have undergone prior neck surgery or radiation therapy to the neck (both of which destroy the normal anatomic planes, causing an increased risk of cranial nerve

injury), or who have lesions that extend high into the neck.

With open surgery, practice makes perfect: the most favorable results are obtained by experienced teams with high patient volumes,^{42,43} and the same will probably hold true for endovascular procedures.

■ PERIPHERAL VASCULAR DISEASE OF THE LEGS

Surgery

The primary surgical procedures for improving the circulation in the legs are femoropopliteal and femorotibial bypass. These operations are largely reserved for patients who have truly disabling claudication (femoral-popliteal bypass), or limb-threatening ischemia (femoral-tibial bypass) as evidenced by pain at rest or tissue loss (nonhealing ulcers or gangrene).

The success of these procedures depends on the inflow to the lower extremity via the iliac arteries, the outflow to the foot via the tibial and plantar vessels, and the conduit that is used (autologous vein or prosthetic material such as polytetrafluoroethylene or Dacron).

In general, autologous veins make better conduits than prosthetic materials with respect to patency and limb salvage.⁴⁴ However, both types of conduits have been used quite successfully for above-the-knee procedures⁴⁵ and have had acceptable results for more distal bypasses when used in conjunction with surgical adjunctive techniques designed to improve patency (eg, the intentional creation of an arteriovenous fistula or the use of a vein cuff at the distal anastomosis).^{44,46}

However, any surgical procedure in the legs can be associated with complications, incisions are painful and may become infected, and most notably, ischemia can progress as a result of the bypass (due to complications or the development of neointimal hyperplasia) or in spite of the bypass.

For this reason, neither surgery nor endovascular therapy is traditionally offered to patients with claudication, as most of them do not develop limb-threatening ischemia. Rather, these procedures are reserved for patients with pain at rest or tissue loss.

Dissection risk is higher with use of large tibial artery balloons



Endovascular therapy for peripheral vascular disease

Endovascular therapies for lower-extremity lesions include balloon angioplasty, stenting, thrombolysis, and stentgraft placement. Laser therapy, atherectomy devices, and gene therapies continue to be evaluated in clinical trials.

The critical factors predicting success of endovascular therapy for atherosclerotic occlusive disease are the anatomic location of the lesion (the more proximal the better) and the length of the lesion.^{47–49}

For iliac lesions, success rates are excellent with balloon angioplasty and stenting, which is now the initial treatment of choice for these lesions.⁵⁰ In some circumstances, such as small vessel size and recurrent disease, aortobifemoral or biiliac grafting may be favored, however.

Short, focal lesions of the superficial femoral artery have respectable intermediate-term results with angioplasty and stenting.⁵¹ However, long lesions in either circulation bed, occlusions, or multilevel disease are predictors of failure,⁴⁷ and must be treated with extreme caution when employing endovascular means.

If the lesion is complex, we tend to use endovascular treatment only if the patient has no acceptable bypass conduits (precluding autologous bypass grafting) or would obviously develop wound complications should an incision be made on the leg (eg, if the patient is on hemodialysis, is steroid-dependent, or is morbidly obese). In these patients, we can use long stents or segmental stenting to treat focal hemodynamic problems in the superficial femoral artery, and subintimal dissection (recanalization) and angioplasty to treat the tibial vessels.

Lesions of intermediate length in the superficial femoral artery have been successfully treated with endovascular grafting,⁵² with respectable 2-year patency results.

Interventional procedures for the lower extremities can be divided into iliac procedures and lower-leg procedures.

Iliac procedures

Iliac lesions can be approached from either the groin or the brachial artery. We prefer con-

tralateral groin access because it allows the most freedom to address both the proximal and distal iliac arteries.

Although some randomized trials showed angioplasty without stenting to be as good as stenting in the iliac arteries, most interventionalists prefer to use stents.^{53–55}

Short focal lesions at the aortic bifurcation are typically treated with balloon-expandable stents. Caution must be taken to protect the other iliac artery at the level of the aortic bifurcation from compression during balloon and stent expansion. This is done using a “kissing stent” or balloon technique (bilateral inflations performed simultaneously).

More distal iliac lesions, particularly those traveling distally into the external iliac arteries, are better handled with the more flexible self-expanding stents. Pressure gradients and careful angiographic assessment of the artery just distal to the stented segment for evidence of flow-limiting dissections will improve results.

Femoral artery procedures

Interventions in the superficial femoral artery have been the subject of great controversy. Angioplasty and stenting procedures of this vessel have been faulted for having low patency rates, high rates of neointimal hyperplasia, and, given the flexibility of the artery, device-integrity issues over time.

However, the results with focal stenoses or even short occlusions have been more favorable with newer stents and a better understanding of the technical aspects of the procedure. An individualized approach is best, and both the patient and physician should understand the natural history of the disease, the risks of open and endovascular procedures, and the expected long-term results. We do not routinely advocate the endovascular treatment of long-segment occlusions; on the other hand, it is extremely uncommon to offer an open surgical bypass operation for a short stenosis of the superficial femoral artery.

Procedures in the superficial femoral artery or tibial arteries can be done via a contralateral or ipsilateral approach. Crossing the offending lesion is best done through a subin-

Patients with occluded visceral vessels need lifelong aspirin

timal plane (if very tight) or through the true lumen. Predilation with small-diameter balloons should precede stent or stent graft placement in the superficial femoral artery. We try to avoid stenting in or distal to the popliteal artery if possible. Long, small-diameter balloons (2–4 mm) are ideal for long tibial lesions, and one should be careful not to use too large a balloon, given the severe consequences of an arterial dissection or disruption in these vessels.

Adequate anticoagulation is achieved with heparin, and patients are premedicated with clopidogrel starting 3 days before the procedure and continuing for at least 30 days afterward.

Thrombolysis

Thrombolysis has been used for quite some time to treat occlusive lesions in native vessels or bypass grafts. Thrombolysis of an occluded bypass graft has the potential to restore the graft to its preoccluded state, unmasking the offending lesions and allowing the physician to best address these lesions in a directed manner.

The risks associated with thrombolytic therapy (remote hemorrhage and puncture site problems) must be weighed against the benefits of reopening an occluded vessel. This calculation is not straightforward and requires a detailed knowledge of the patient's medical history and the risks of open surgery, and an assessment of the level of difficulty and prediction of success of the lysis procedure.

Even though no thrombolytic agent has been approved to treat acute peripheral ischemia, three agents are currently being used: urokinase, recombinant tissue plasminogen activator (alteplase), and reteplase. Urokinase has been the agent best studied for peripheral occlusive disease,^{56–58} and was recently re-released after being withdrawn from the market. None of the agents has been shown to be effective for the treatment of chronic occlusions.


■ VISCERAL VESSEL PROCEDURES

Mesenteric and renal artery stenting have evolved over the past 10 years and have largely replaced open surgical bypass for occlusive lesions in these arteries. Experienced interventionalists have achieved high levels of technical success.⁵⁹

We currently rely on interventional means to treat most acute and chronic cases of ischemic bowel disease and nearly all renal artery lesions, unless they are associated with aneurysmal disease of the renal artery or aorta. Exceptions to this rule include pediatric renal stenosis and some forms of arteritis. Indications for renal interventions are controversial but generally include cases in which the pathologic process is presumed to be due to angiotensin. Mesenteric interventions are reserved for patients with acute or chronic symptomatic stenosis of the superior mesenteric or celiac artery.

Although most renal interventions can be done with a femoral approach, mesenteric angioplasty and stenting are more typically done with a brachial approach. Balloon-expandable stents are usually used to maximize the radial force needed to oppose the highly calcific lesions typically found at the ostia of the visceral vessels.

Furthermore, most occlusive lesions of the visceral vessels extend into the aorta; thus, one must be certain to extend the stent into the aorta. However, stents protruding into the aortic lumen preclude other types of interventional therapies—specifically endovascular aneurysm repair. In this light, patients with aneurysmal and visceral occlusive disease are best handled by physicians familiar with both procedures.

Patients with occlusive disease treated with an endovascular or open approach should be placed on lifelong aspirin therapy. A 4-week course of clopidogrel following angioplasty or stenting of an occlusive lesion is likely to decrease the risk of acute and subacute thrombosis and may lower the long-term risk of restenosis. 

■ REFERENCES

1. **Nevitt MP, Ballard DJ, Hallett JW Jr.** Prognosis of abdominal aortic aneurysms. A population-based study. *N Engl J Med* 1989; 321:1009–1014.
2. **Cronenwett J, Katz D.** When should infrarenal abdominal aortic aneurysms be repaired: What are the critical risk factors and dimensions? In: Veith FJ, editor. *Current Critical Problems in Vascular Surgery*. St. Louis: Quality Medical Publishing, 1993:256.
3. **Davies RR, Goldstein LJ, Coady MA, et al.** Yearly rupture or dissection rates for thoracic aortic aneurysms: simple prediction based on size. *Ann Thorac Surg* 2002; 73:17–27.



4. **The United Kingdom Small Aneurysm Trial Participants.** Long-term outcomes of immediate repair compared with surveillance of small abdominal aortic aneurysms. *N Engl J Med* 2002; 346:1445–1452.
5. **Lederle FA, Wilson SE, Johnson GR, et al.** Immediate repair compared with surveillance of small abdominal aortic aneurysms. *N Engl J Med* 2002; 346:1437–1444.
6. **Johnston KW.** Multicenter prospective study of nonruptured abdominal aortic aneurysm. Part II. Variables in predicting morbidity and mortality. *J Vasc Surg* 1989; 9:437–447.
7. **Hallett JW Jr, Marshall DM, Petterson TM, Gray DT, Bower TC, Cherry KJ Jr.** Graft-related complications after abdominal aortic aneurysm repair: Reassurance from a 36-year population-based experience. *J Vasc Surg* 1997; 25:277–286.
8. **Plate G, Hollier La, O'Brien P, Pairolero PC, Cherry KJ, Kazmier FJ.** Recurrent aneurysms and late vascular complications following repair of abdominal aortic aneurysms. *Arch Surg* 1985; 120:590–594.
9. **Arko FR, Lee WA, Hill BB, et al.** Aneurysm-related death: primary endpoint analysis for comparison of open and endovascular repair. *J Vasc Surg* 2002; 36:297–304.
10. **White GH, Yu W, May J.** Endoleak—a proposed new terminology to describe incomplete aneurysm exclusion by an endoluminal graft [letter]. *J Endovasc Surg* 1996; 3:124–125.
11. **White GH, May J, Vaughn RC, Chaufour X, Yu W.** Type III and type IV endoleak: toward a complete definition of blood flow in the sac after endoluminal AAA repair. *J Endovasc Surg* 1998; 5:305–309.
12. **Greenberg RK.** Abdominal aortic endografting: fixation and sealing. *J Am Coll Surg* 2002; 194(suppl 1):S79–S87.
13. **Greenberg R, Clair D, Srivastava S, et al.** Should patients with challenging anatomy be offered endovascular aneurysm repair. *J Vasc Surg.* In press.
14. **Hinchliffe R, Hopkinson BR.** Endovascular repair of abdominal aortic aneurysm: current status. *J R Coll Surg Edinb* 2002; 47:523–527.
15. **Makaroun M.** The Ancure endografting system: An update. *J Vasc Surg* 2001; 33:S129–S134.
16. **Moore WS.** The EVT tube and bifurcated endograft systems: technical considerations and clinical summary. *EVI Investigators. J Endovasc Surg* 1997; 4:182–194.
17. **Matsumura J, Katzen B, Hollier L, Dake M.** Update on the bifurcated Excluder endoprosthesis: Phase I results. *J Vasc Surg* 2001; 33:S150–S153.
18. **Zarins C, White R, Schwarten D, et al.** AneuRx stent graft versus open surgical repair of abdominal aortic aneurysms: multicenter prospective clinical trial. *J Vasc Surg* 1999; 29:292–308.
19. **Greenberg R, Lawrence-Brown M, Bhandari G, et al.** An update on the Zenith endovascular graft for abdominal aortic aneurysms: initial implantation and mid-term follow-up data. *J Vasc Surg* 2001; 2:S157–S165.
20. **Abraham C, Chuter T, Reilly LM, et al.** Abdominal aortic aneurysm repair with the Zenith stent graft: short to mid term results. *J Vasc Surg* 2002; 36:217–225.
21. **White GH, Yu W, May J, et al.** Three-year experience with the White-Yu Endovascular GAD Graft for transluminal repair of aortic and iliac aneurysms. *J Endovasc Surg* 1997; 4:124–136.
22. **White R.** Clinical and design update on the development and testing of a one-piece, bifurcated, polytetra-fluoroethylene endovascular graft for abdominal aortic aneurysm exclusion: the Endologix device. *J Vasc Surg* 2001; 33(suppl 2):S154–S156.
23. **Criado F, Fry P.** The Talent endoluminal stent-graft system: technical success and acute clinical outcome: report of a collective international experience. *J Endovasc Surg* 1998; 5:1–9.
24. **Brener B, Faries P, Connelly T, et al.** An in situ adjustable endovascular graft for the treatment of abdominal aortic aneurysms. *J Vasc Surg* 2002; 35:109–113.
25. **NASCET Investigators.** Clinical alert: benefit of carotid endarterectomy for patients with high-grade stenosis of the internal carotid artery. National Institute of Neurologic Disorders and Stroke, Stroke and Trauma Division. North American Symptomatic Carotid Endarterectomy Trial. *Stroke* 1991; 22:816–817.
26. **ACAS Investigators.** Clinical advisory: carotid endarterectomy for patients with asymptomatic internal carotid stenosis. *Stroke* 1994; 25:2523–2524.
27. **Executive Committee for the Asymptomatic Carotid Atherosclerosis Study.** Endarterectomy for asymptomatic carotid stenosis. *JAMA* 1995; 273:1428.
28. **North American Symptomatic Carotid Endarterectomy Trial Collaborators.** Beneficial effect of carotid endarterectomy in symptomatic patients with high-grade carotid stenosis. *N Engl J Med* 1991; 325:445–453.
29. **Biller J, Feinberg WM, Castaldo J, et al.** Guidelines for carotid endarterectomy: a statement for healthcare professionals from a special writing group of the Stroke Council, American Heart Association. *Stroke* 1998; 29:554–562.
30. **Barnett H, Taylor D, Eliasziw M, et al.** Benefit of carotid endarterectomy in patients with symptomatic moderate or severe stenosis. *N Engl J Med* 1998; 339:1415–1425.
31. **Mattos M, Sumner D, Bohannon W, et al.** Carotid endarterectomy in women: challenging the results from ACAS and NASCET. *Ann Surg* 2001; 234:438–445.
32. **Wholey M, Wholey M, Mathias K, et al.** Global experience in cervical carotid artery stent placement. *Catheter Cardiovasc Interv* 2000; 50:160–167.
33. **CAVATAS Investigators.** Endovascular versus surgical treatment in patients with carotid stenosis in the Carotid and Vertebral Artery Transluminal Angioplasty Study (CAVATAS): a randomised trial. *Lancet* 2001; 2:1729–1737.
34. **Roubin G, New G, Iyer S, et al.** Immediate and late clinical outcomes of carotid artery stenting in patients with symptomatic and asymptomatic carotid artery stenosis. *Circulation* 2001; 103:532–537.
35. **Veith F, Amor M, Ohki T, et al.** Current status of carotid bifurcation angioplasty and stenting based on a consensus of opinion leaders. *J Vasc Surg* 2001; 33(suppl 2):S111–S116.
36. **Whitlow P, Lylyk P, Londero H, et al.** Carotid artery stenting protected with an emboli containment system. *Stroke* 2002; 33:1308–1314.
37. **Ohki T, Roubin G, Veith F, Iyer S, Brady E.** Efficacy of a filter device in the prevention of embolic events during carotid angioplasty and stenting: An ex vivo analysis. *J Vasc Surg* 1999; 30:907–913.
38. **Al-Mubarak N, Roubin G, Vitek J, Iyer S, New G, Leon M.** The effect of distal-balloon protection system on microembolization during carotid stenting. *Circulation* 2001; 104:1999–2002.
39. **Ohki T, Parodi J, Veith F, et al.** Efficacy of proximal occlusion catheter with reversal of flow in the prevention of embolic events during carotid artery stenting: an experimental analysis. *J Vasc Surg* 2001; 33:504–509.
40. **Veith FJ, Amor M, Ohki T, et al.** Current status of carotid bifurcation angioplasty and stenting based on a consensus of opinion leaders. *J Vasc Surg* 2001; 33S:111–116.
41. **Yadav J, for the SAPHIRE Investigators.** Stenting and angioplasty with protection in patients at high risk for endarterectomy. Abstract presented by K. Ouriel at the Society for Vascular Surgery, June, 2003.
42. **Hertzner N.** Society for Vascular Surgery—Presidential Address. *J Vasc Surg* 1995; 21:6–15.
43. **Cebul R, Snow R, Pine R, Hertzner N, Norris D.** Indications, outcomes, and provider volumes for carotid endarterectomy. *JAMA* 1998; 279:1304–1306.
44. **Moneta G, Porter J.** Arterial substitutes in peripheral vascular surgery: a review. *J Long Term Eff Med Implants* 1995; 5:47–67.
45. **Green R, Abbott W, Matsumoto T, et al.** Prosthetic above-knee femoropopliteal bypass grafting: five-year results of a randomized trial. *J Vasc Surg* 2000; 31:417–425.
46. **Eagleton M, Ouriel K, Shortell C, Green R.** Femoral-infrapopliteal bypass with prosthetic grafts. *Surgery* 1999; 126:759–764.
47. **Rutherford R.** Options in the surgical management of aorto-iliac occlusive disease: a changing perspective. *Cardiovasc Surg* 1999; 7:5–12.
48. **Gray B, Olin J.** Limitations of percutaneous transluminal angioplasty



- ty with stenting for femoropopliteal arterial occlusive disease. *Semin Vasc Surg* 1997; 10:8–16.
49. **Gray B, Sullivan T, Childs M, Young J, Olin J.** High incidence of restenosis. Reocclusion of stents in the percutaneous treatment of long-segment superficial femoral artery disease. *J Vasc Surg* 1997; 25:74–83.
 50. **Bosch J, Hunink M.** Meta-analysis of the results of percutaneous transluminal angioplasty and stent placement for aortoiliac occlusive disease. *Radiology* 1997; 204:87–96.
 51. **Becquemin J, Cavillon A, Haiduc F.** Surgical transluminal femoropopliteal angioplasty: Multivariate analysis outcome. *J Vasc Surg* 1994; 19:495–502.
 52. **Rubin B, Sicard G.** The Hemobahn endoprosthesis: a self-expanding polytetrafluoroethylene-covered endoprosthesis for the treatment of peripheral arterial occlusive disease after balloon angioplasty. *J Vasc Surg* 2001; 33(suppl 2):S124–S128.
 53. **Vorwerk D, Guenther R, Schurmann K, Wendt G, Peters I.** Primary stent placement for chronic iliac artery occlusions: follow-up results in 103 patients. *Radiology* 1995; 194:745–749.
 54. **Richter G, Rhoen T, Noeldge G, Landwehr P, Kauffmann G, Palmaz J.** Superior clinical results of iliac stent placement versus percutaneous transluminal angioplasty: four year success rates of a randomized study [abstract]. *Radiology* 1991; 181:161.
 55. **Tetteroo E, van der Graaf Y, Bosch J, et al.** Randomised comparison of primary stent placement versus primary angioplasty followed by selective stent placement in patients with iliac artery occlusive disease. *Lancet* 1998; 351:1153–1159.
 56. **Ouriel K, Veith F, Sasahara A.** A comparison of recombinant urokinase with vascular surgery as initial treatment for acute arterial occlusion of the legs. *N Engl J Med* 1998; 338:1105–1111.
 57. **Ouriel K, Veith FJ, Sasahara AA.** Thrombolysis or peripheral arterial surgery: phase I results. TOPAS Investigators. *J Vasc Surg* 1996; 23:64–73.
 58. **Greenberg R, Ouriel K, Srivastava S, et al.** Mechanical versus chemical thrombolysis: an in vitro differentiation of thrombolytic mechanism. *J Vasc Intervent Radiol* 2000; 11:199–205.
 59. **Dorros G, Jaff M, Mathiak L, He T.** Multicenter Palmaz stent renal artery stenosis revascularization registry report: four-year follow-up of 1,058 successful patients. *Catheter Cardiovasc Interv* 2002; 55:182–188.

ADDRESS: Roy K. Greenberg, MD, Director, Endovascular Research, Department of Vascular Surgery, S40, The Cleveland Clinic, 9500 Euclid Avenue, Cleveland, OH 44195; e-mail greenbr@ccf.org.