

**RAED H. ABDELHADI, MD**Department of Internal Medicine,
The Cleveland Clinic**CURTIS M. RIMMERMAN, MD**Head, Section of Clinical Electrocardiography,
Department of Cardiovascular Medicine,
The Cleveland Clinic

A 77-year-old man with septic shock

A 77-YEAR-OLD MAN is urgently transferred from a rehabilitation center for the homeless to our intensive care unit. His nurse at the center had found him to be poorly responsive, hypotensive, and febrile. Paramedics intubated him and resuscitated him with a large amount of intravenous fluid.

For the past 10 days, he has complained of abdominal pain and decreased appetite. His medical history is significant for chronic bronchitis, paroxysmal atrial fibrillation, and heavy alcohol use.

Physical examination

The patient is malnourished, sedated, and on mechanical ventilation; systolic blood pressure 100 mm Hg (on vasopressors), heart rate 80 and regular, rectal temperature 38.5°C (101.3°F).

Lungs. Bronchial breath sounds at the right upper lobe with dull percussion notes; his left lung is clear to auscultation.

Heart. Normal S₁ and S₂ sounds without S₃ or S₄ gallops, and a 3/6 pansystolic murmur at the cardiac apex with radiation to the axilla. This murmur was not noted in previous examinations. His neck veins are collapsed. No lower extremity edema is present.

Neurologic examination. Grossly normal.

Abdomen. Tender; the patient guards the infraumbilical area. Diminished bowel sounds. Stool is brown and tests positive for occult blood.

Initial arterial blood values

Values are after intubation; FiO₂ 100%:

- Bicarbonate 13 mmol/L (normal 22–26)
- pH 7.4 (7.35–7.45)
- PCO₂ 21 mm Hg (34–46)
- PO₂ 216 mm Hg (85–95)

Chemistry profile

- Alanine transaminase 12 U/L (normal 5–50)

- Alkaline phosphatase 79 U/L (20–120)
- Amylase 933 U/L (0–137)
- Aspartate transaminase 34 U/L (7–40)
- Blood urea nitrogen 47 mg/dL (10–25)
- Chloride 102 mmol/L (98–110)
- Creatinine 1.6 mg/dL (0.6–1.2)
- Glucose 124 mg/dL (70–115)
- Lactate 10 mmol/L (0.5–2.2)
- Lipase 27 U/L (12–70)
- Potassium 4.7 mmol/L (3.5–5)
- Sodium 136 mmol/L (135–146)
- Troponin T 0.08 ng/mL (0–0.10)

Complete blood cell count

- Hemoglobin 8.2 g/dL (normal 13.5–17.0)
- Platelet count 426 × 10⁹/L (150–400)
- White blood cell count 21 × 10⁹/L (4.0–10.0)

Diagnostic tests and imaging studies

An electrocardiogram shows an accelerated junctional rhythm with a nonspecific intraventricular conduction delay (FIGURE 1).

A chest radiograph shows a focal infiltrate in the right upper lobe and a clear left lung. An abdominal radiograph shows a nonobstructive gas pattern.

Empiric treatment started

The patient is started empirically on piperacillin sodium-tazobactam sodium, gentamycin sulfate, and vancomycin hydrochloride to treat sepsis syndrome in the setting of presumed facility-acquired pneumonia. Ventilatory support, intravenous fluids, and vasopressors are continued.

WHAT IS THE NEXT DIAGNOSTIC STEP?

- 1 Which of the following tests is *not* indicated at this point?

- ☐ Computed tomography (CT) of the abdomen

His lab

findings:

Amylase 933

Bicarbonate 13

BUN 47

Lactate 10

WBCs 21

The patient's ECG on admission

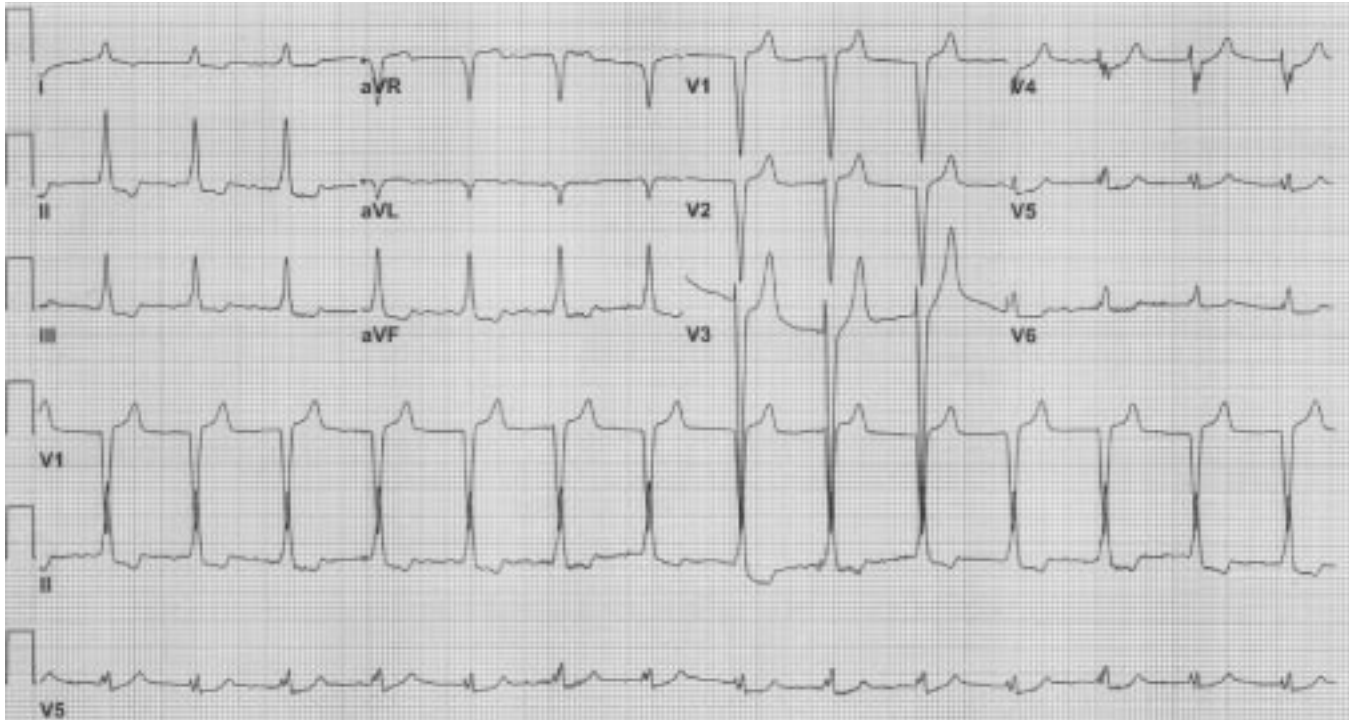


FIGURE 1. The electrocardiogram shows accelerated junctional rhythm with nonspecific intraventricular conduction delay.

Suspect infective endocarditis in patients with fever and a new heart murmur

- ☐ Echocardiography
- ☐ Coagulation profile
- ☐ Ventilation/perfusion scan of the lungs

The patient has findings on physical examination and initial evaluation that cannot be explained by pneumonia and sepsis alone.

The abdominal examination and the elevated serum amylase level raise the possibility of an intra-abdominal process. CT is an appropriate initial test.

Infective endocarditis should always be considered when fever coexists with a suspected new heart murmur; thus, echocardiography is appropriate.

Patients with sepsis are at high risk for disseminated intravascular coagulation; therefore, a coagulation profile is appropriate.

Pulmonary embolism alone cannot explain the fever and abdominal and cardiac findings on his physical examination. The clinical and radiographic findings are consistent with pneumonia, which can explain the presence of a wide alveolar-arterial gradient and lower the clinical probability of pul-

monary embolism. With low pretest probability for pulmonary embolism and the presence of an infiltrate on his chest radiograph, a lung scan is unlikely to be diagnostic.

Case continued

The patient's CT scan shows focal aneurysmal dilatation of the juxtarenal abdominal aorta. Low attenuation surrounding the lumen above and below this dilated area suggests a mycotic aneurysm (**FIGURE 2**).

A surface echocardiogram shows severe mitral regurgitation, a mobile echodensity on the atrial surface of the anterior mitral valve leaflet, and leaflet perforation (**FIGURE 3**).

The next day, a blood culture grows *Streptococcus pneumoniae*, and a sputum culture grows both *S pneumoniae* and *Staphylococcus aureus*.

A coagulation profile is normal. The elevation in serum amylase level can be attributed to multiple factors, including intestinal infarction and possible aneurysmal leak with peritonitis and pancreatic irritation (although this was not definitively noted on the CT scan).



■ DOES THIS PATIENT HAVE INFECTIVE ENDOCARDITIS?

2 According to the modified Duke criteria, which of the following is *not* a major criterion for diagnosing infective endocarditis?

- ☐ Two positive blood cultures for viridans streptococcus
- ☐ A change in a preexisting murmur
- ☐ An echocardiogram that is positive for infective endocarditis
- ☐ A single blood culture that is positive for *Coxiella burnetii*

The Duke criteria, published in 1994, included major and minor criteria for diagnosing infective endocarditis.^{1,2} The major criteria include blood cultures that are positive for typical organisms and evidence of endocardial involvement. New valvular regurgitation is a major criterion, but a change in a preexisting murmur is not.

The Duke University investigators³ modified the criteria in 1999 to include another major criterion: a single positive culture for *Coxiella burnetii* or an immunoglobulin G (IgG) titer greater than 1:800, in addition to other modifications (TABLE 1).

Our patient has evidence of endocardial involvement on transthoracic echocardiography (TTE), as well as three minor criteria; thus, he has a “definite” case of infective endocarditis.⁴ His minor criteria are fever, a single positive blood culture, and a mycotic aneurysm.

■ WHAT CAN TEE OR TTE TELL US?

3 What is the role of a transesophageal echocardiography (TEE) in the diagnosis of infective endocarditis?

Both TTE and TEE are highly specific for detecting infective endocarditis, but TEE is more sensitive (90% vs 60%).^{5,6} The difference in sensitivity is even greater for prosthetic valves, myocardial abscesses, and perivalvular involvement. In these situations, TEE rather than TTE is recommended. When evaluating native valves, the clinical probability of infective endocarditis rather than the

Mycotic aortic aneurysm

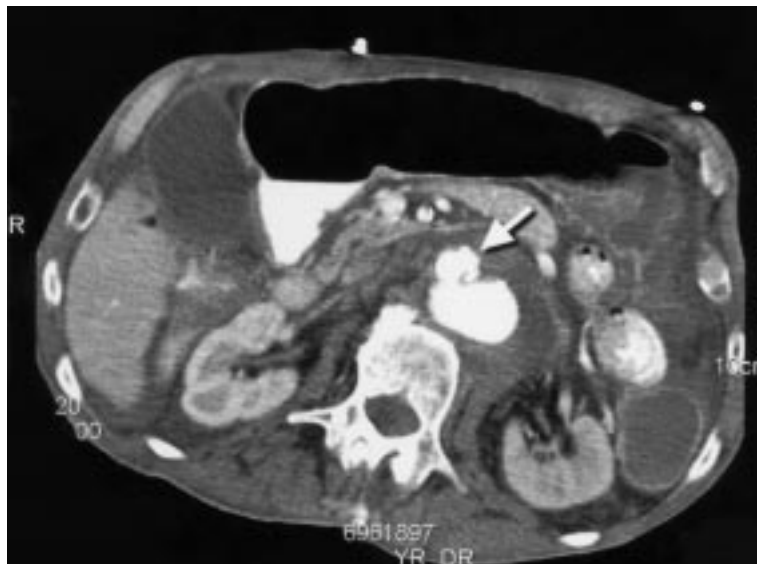


FIGURE 2. Computed tomographic scan showing saccular aneurysmal dilatation at the anterior aspect of the abdominal aorta (arrow) with low attenuation surrounding the lumen.

findings on TTE is the best indication to proceed with TEE.

In patients with a low clinical probability of infective endocarditis, a negative TTE examination is clinically satisfactory to rule out infective endocarditis; moreover, TTE is less expensive and less invasive than TEE. Patients with an intermediate pretest probability are best served by a TEE examination if a TTE examination is not diagnostic.

On the other hand, Heidenreich et al⁷ demonstrated that initial use of TEE in patients with an intermediate pretest probability of infective endocarditis is more cost-effective and provides the most quality-adjusted life years.

This analysis⁷ also suggested that patients with a very low probability of infective endocarditis can be treated for simple bacteremia, and that patients with a very high probability can be treated for endocarditis without the need for echocardiography. In the latter group, TEE should still be performed if the patient has suspected cardiac complications, such as perivalvular leak and myocardial abscess. The study investigators set specific pretest probabilities that depend on the clinical presentation.⁷

The modified Duke criteria recommend TEE as the initial diagnostic test in patients

TEE is most cost-effective in patients with an intermediate probability of infective endocarditis

Mitral regurgitation, perforation

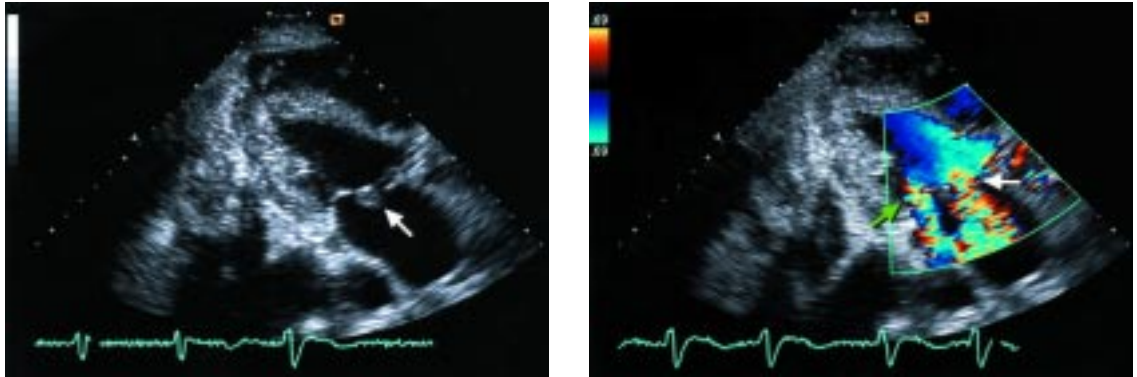


FIGURE 3. Left, surface echocardiogram showing mobile echodensity on the atrial surface of the anterior mitral valve leaflet (arrow); right, color Doppler echocardiogram showing two regurgitant jets through the mitral valve orifice (green arrow) and a perforated leaflet (white arrow).

with at least possible infective endocarditis by clinical criteria. The investigators also advise using TEE rather than TTE for evaluating prosthetic valves, myocardial abscess, and perivalvular involvement.

■ PNEUMOCOCCAL INFECTIVE ENDOCARDITIS: WHAT LIES BENEATH?

4 Which of the following is not true about pneumococcal infective endocarditis?

- ☐ Alcoholism is a common risk factor
- ☐ The lungs are the most common port of entry
- ☐ Meningitis commonly coexists with it
- ☐ It mainly affects patients with preexisting valvular disease
- ☐ It is an aggressive form of infective endocarditis

Although streptococcal pneumonia is no longer a common cause of endocarditis (as it was in the preantibiotic era), it is associated with a highly aggressive course, high rates of morbidity and mortality, and destructive valvular involvement.⁸ In one series,⁹ valve perforation was reported in 20% of cases, ring abscess in 13.3%, and rupture of the chordae tendineae in 10%. Aronin et al¹⁰ reported valve destruction in 28.9% of cases and perforation in 2.6%.

Pneumococcal infective endocarditis typ-

ically follows a primary infection, most commonly pneumonia (62%–82% of patients with a known portal of entry); meningitis was reported in 40% to 60% of patients with pneumococcal infective endocarditis.

Alcoholism was found to be one of the most significant risk factors for pneumococcal infective endocarditis; other risk factors include immunosuppression and pulmonary disease. It is not completely clear why alcoholism predisposes patients to serious invasive pneumococcal diseases, including endocarditis; the reason is mostly multifactorial and is likely related to alcohol's deleterious effects on neutrophil function, decreased opsonization, decreased splenic clearance, and concomitant malnutrition and aspiration risk.

Most patients with pneumococcal infective endocarditis have no predisposing valve disease.

■ OUR PATIENT'S OUTCOME

Our patient subsequently developed multorgan failure that included a non-ST-elevation myocardial infarction that was presumed to be embolic in origin. He underwent an endovascular exclusion of his aortic aneurysm using an aortic tube graft. His guardian, after prolonged discussion with the health care team, decided not to pursue further invasive interventions. The patient died 1 week after admission. No autopsy was performed.

S pneumoniae
can cause
an aggressive
form of
infectious
endocarditis

**TABLE 1****Modified Duke criteria for the diagnosis of infective endocarditis****MAJOR CRITERIA****Blood culture evidence of infective endocarditis**

Typical microorganism consistent with infective endocarditis from two separate blood cultures:

Viridans streptococcus, *Streptococcus bovis*, HACEK group (*Haemophilus* species, *Actinobacillus actinomycetem-comitans*, *Cardiobacterium hominis*, *Eikenella corrodens*, *Kingella* species), *Staphylococcus aureus*; or
Community-acquired enterococci in the absence of primary focus; or

Microorganisms consistent with infective endocarditis from persistently positive blood cultures, defined as follows:

At least two positive cultures of blood samples drawn more than 12 hours apart; or

Three of three or a majority of four or more separate cultures of blood (with first and last sample drawn more than 1 hour apart)

Single positive blood culture for *Coxiella burnetii* or antiphase I immunoglobulin G antibody titer greater than 1:800

Evidence of endocardial involvement

New valvular regurgitation (worsening or changing of preexisting murmur not sufficient)

Positive echocardiogram for infective endocarditis defined as follows:

Oscillating intracardiac mass on valve or supporting structure, in the path of regurgitant jets, or on implanted material in the absence of an alternative anatomic explanation; or

Abscess; or

New partial dehiscence of prosthetic valve

MINOR CRITERIA

Predisposition: either a predisposing heart condition or injecting drug use

Fever (temperature > 38° C)

Vascular phenomena: major arterial emboli, septic pulmonary infarctions, mycotic aneurysm, intracranial hemorrhage, conjunctival hemorrhages, and Janeway lesions

Immunologic phenomena: glomerulonephritis, Osler nodes, Roth spots, and rheumatoid factor

Microbiologic evidence: positive blood culture (does not meet a major criterion) or serologic evidence of active infection with organism consistent with infective endocarditis

Definite infectious endocarditis: 2 major criteria, or 1 major criterion and 3 minor criteria, or 5 minor criteria

Possible infectious endocarditis: 1 major criterion and 1 minor criterion, or 3 minor criteria

ADAPTED FROM LI JS, SEXTON DJ, MICK N, ET AL. PROPOSED MODIFICATIONS TO THE DUKE CRITERIA FOR THE DIAGNOSIS OF INFECTIVE ENDOCARDITIS. CLIN INFECT DIS 2000; 30:633–638.

■ LESSONS FROM THIS REVIEW

- Infective endocarditis should be considered in every patient with a new regurgitant murmur and fever—even if the fever can be attributed to another source of infection.
- *Streptococcus pneumoniae* can cause an aggressive form of infective endocarditis.

■ REFERENCES

1. American College of Chest Physicians/Society of Critical Care Medicine Consensus Conference. Definitions for sepsis and organ failure and guidelines for the use of innovative therapies in sepsis. Crit Care Med 1992; 20:864–874.
2. Mylonakis E, Calderwood SB. Infective endocarditis in adults. N Engl J Med 2001; 345:1318–1330.
3. Li JS, Sexton DJ, Mick N, et al. Proposed modifications to the Duke Criteria for the diagnosis of infective endocarditis. Clin Infect Dis 2000; 30:633–638.
4. Durack DT, Lukes AS, Bright DK. New criteria for diagnosis of infective endocarditis: utilization of specific echocardiographic findings. Duke Endocarditis Service. Am J Med 1994; 96:200–209.

Alcoholism is an important risk factor. Pneumonia is commonly the primary focus of infection, and meningitis is likely to coexist.

- In deciding whether to pursue TEE, the primary reasons should be the pretest probability of infectious endocarditis plus the suspicion of cardiac complications rather than the result of the TTE.





5. **Roe MT, Abramson MA, Li J, et al.** Clinical information determines the impact of transesophageal echocardiography on the diagnosis of infective endocarditis by the Duke criteria. *Am Heart J* 2000; 139:945–951.
 6. **Krivokapich J, Child JS.** Role of transthoracic and transesophageal echocardiography in the diagnosis and management of infective endocarditis. *Cardiol Clin* 1996;14:363–382.
 7. **Heidenreich PA, Masoudi FA, Maini B, et al.** Echocardiography in patients with suspected endocarditis: a cost-effectiveness analysis. *Am J Med* 1999; 107:198–208.
 8. **Lefort A, Mainardi JL, Selton-Suty C, Casassus P, Guillevin L, Lortholary O.** *Streptococcus pneumoniae* endocarditis in adults: a multicenter study in France in the era of penicillin resistance (1991–1998). The Pneumococcal Endocarditis Study Group. *Medicine* 2000; 79:327–337.
 9. **Lussier N, Girouard Y, Chapleau D.** Mycotic aneurysm of the suprarenal aorta due to *Streptococcus pneumoniae*: case report and literature review. *Can J Surg* 1999; 42:302–304.
 10. **Aronin SI, Mukherjee SK, West JC, Cooney EL.** Review of pneumococcal endocarditis in adults in the penicillin era. *Clin Infect Dis* 1998; 26:165–171.
-
- ADDRESS:** Curtis M. Rimmerman, MD, Department of Cardiovascular Medicine, F15, The Cleveland Clinic Foundation, 9500 Euclid Avenue, Cleveland, OH 44195, e-mail rimmerc@ccf.org.