



**PETE S. BATRA, MD**

Section of Nasal and Sinus Disorders,  
Head and Neck Institute, The Cleveland  
Clinic Foundation

# Radiologic imaging in rhinosinusitis

## ABSTRACT

To diagnose rhinosinusitis, the history and physical examination usually suffice. However, imaging may be necessary to guide further treatment in patients whose condition is refractory to treatment and patients with chronic or recurrent acute rhinosinusitis or acute rhinosinusitis with complications. A brief review of current imaging options and their recommended use is presented.

## KEY POINTS

Plain radiography is not very sensitive for rhinosinusitis, but its cost is relatively low, it involves only small doses of radiation, and it is often portable, which can be helpful in the intensive care setting.

Computed tomography has become the imaging study of choice in the diagnosis and management of chronic and recurrent acute rhinosinusitis.

Magnetic resonance imaging is reserved for rare cases of suspected sinonasal neoplasia, fungal sinusitis, or suspected intracranial or orbital complications of rhinosinusitis.

**R**HINOSINUSITIS, A DISEASE ENCOUNTERED often by primary care physicians, accounts for 2.5 million office visits and \$2 billion in direct medical expenses every year.<sup>1</sup> A careful history and physical examination usually suffice to make the diagnosis, at least in patients with uncomplicated rhinosinusitis lasting for 12 weeks or less.

But patients with refractory sinusitis, chronic or recurrent acute rhinosinusitis, or acute rhinosinusitis with complications may require further evaluation with an imaging study. This brief overview will discuss when imaging is appropriate, and which method is preferred—plain radiography, computed tomography (CT), or magnetic resonance imaging (MRI).

## CLASSIFICATION AND DIAGNOSTIC CRITERIA

Rhinosinusitis is defined as inflammation of the nasal cavity and the adjacent paranasal sinuses. The terms acute (less than 4 weeks), subacute (4 to 12 weeks), and chronic (greater than 12 weeks) rhinosinusitis have been used to define the illness by its duration.

The diagnosis of rhinosinusitis is based on clinical grounds. In 1997 the Task Force of Rhinosinusitis developed the major and minor symptomatic criteria for diagnosing rhinosinusitis (TABLE 1).<sup>2</sup> The presence of two major or one major and two minor symptoms is generally sufficient to make a clinical diagnosis of acute rhinosinusitis.

## IMAGING OPTIONS

Advances in sinonasal imaging have occurred at the same time as our understanding of paranasal sinus anatomy and the pathophysiology of sinonasal inflammatory disease has



**TABLE 1**

## Diagnostic criteria for rhinosinusitis

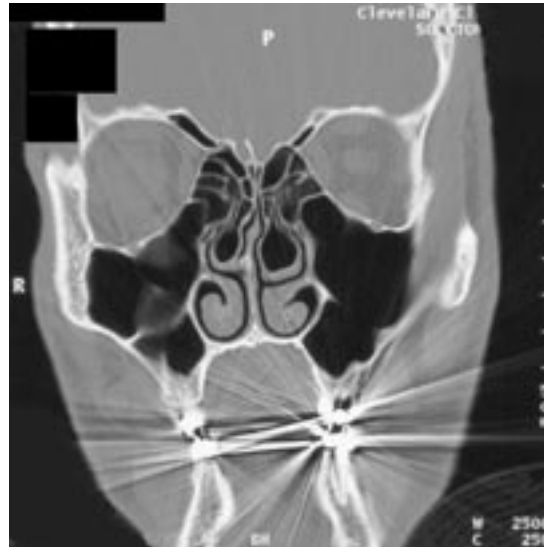### Major criteria

- Nasal drainage
- Nasal congestion
- Facial pain, pressure
- Postnasal drip
- Hyposmia, anosmia

### Minor criteria

- Fever
- Cough
- Fatigue
- Dental pain
- Ear fullness, pressure

ADAPTED FROM LANZA DC, KENNEDY DW. ADULT RHINOSINUSITIS DEFINED. OTOLARYNGOL HEAD NECK SURG 1997; 1179(SUPPL):S1-S7.



**FIGURE 1:** Coronal computed tomographic (CT) scan of the paranasal sinuses provides detailed information and an unparalleled view of the sinuses, including the bony anatomy.

improved. Traditional plain radiography has been supplanted by CT of the sinuses, and with the evolution of advanced endoscopic techniques, MRI now holds an important role in certain cases.<sup>3</sup>

### Plain radiography

The plain radiographic examination for rhinosinusitis can include Waters, Caldwell, lateral, and submental vertex views. Potential findings include air-fluid level, mucosal thickening, or complete opacification of the involved sinus. Low cost and small radiation dosage (1.4 cGy)<sup>4</sup> are advantages of this technique, and the capability for portable examination can be helpful in the intensive care setting. The major drawback of plain radiography is its low sensitivity in the diagnosis of rhinosinusitis.

Konen et al<sup>5</sup> noted that the sensitivity and specificity of plain radiography in the diagnosis of maxillary sinus abnormalities were 67.7% and 87.6%, respectively, with CT serving as the gold standard. The positive and negative predictive values were reported as 82.5% and 76.9%, respectively. The sensitivity for the ethmoid, frontal, and sphenoid sinuses was significantly lower at 0% to 58.9%, 1.9% to 54.0%, and 0% to 3.8%, respectively.<sup>5</sup> Thus, a negative plain film does not necessarily eliminate the diagnosis of rhinosinusitis.

### Computed tomography of the sinuses

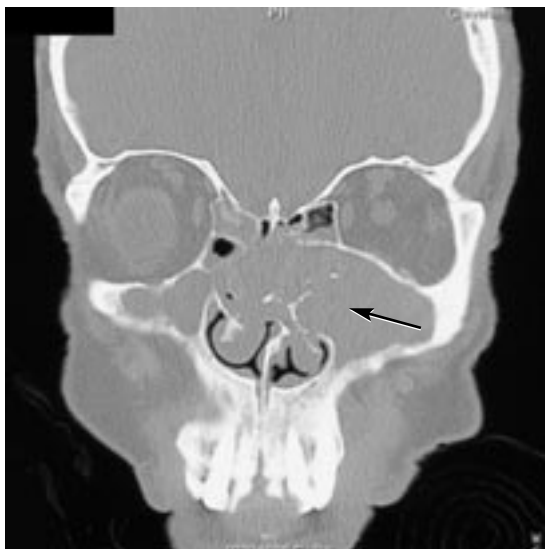
CT has become the imaging method of choice for the paranasal sinuses. It provides detailed information and an unparalleled view of the sinuses, especially the bony anatomy (FIGURE 1). The primary role of CT is to aid in the diagnosis and management of chronic and recurrent acute rhinosinusitis. Coronal CT performed at 3-mm cuts is essential for defining the anatomy prior to endoscopic sinus surgery. Advances in computer-aided surgery now allow for 1-mm reconstruction for management of complex intranasal pathology, including sinonasal polyposis, fungal sinusitis (FIGURE 2), and sinonasal neoplasia.

The main drawbacks of CT are poor soft-tissue differentiation and physical limitations in performing coronal imaging, including patient claustrophobia and the inability to hyperextend the neck. The radiation dose of 5 to 6 cGy is also higher than that used in plain radiography.<sup>4</sup>

### Magnetic resonance imaging

MRI allows for superior visualization and differentiation of the soft-tissue structures of the paranasal sinuses and the adjacent orbital and intracranial cavities. MRI with gadolinium contrast is used to evaluate for sinonasal neo-

**Fine-cut CT and MRI are not needed in the initial diagnosis of uncomplicated rhinosinusitis**



**FIGURE 2:** Coronal CT scan demonstrates left maxillary fungal “ball” (arrow).

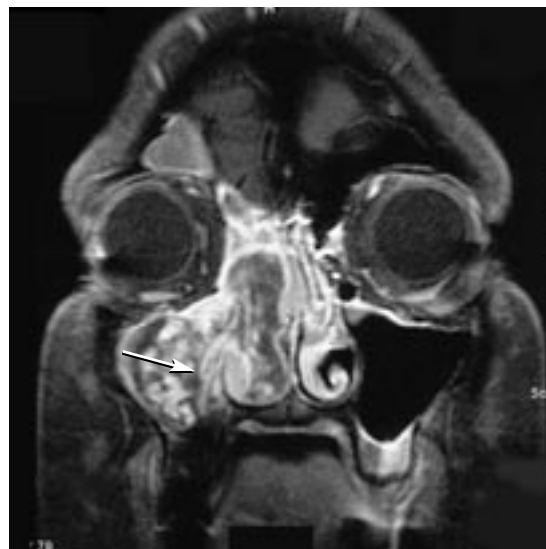plasia (FIGURE 3) and fungal disease or suspected intracranial or orbital complications of rhinosinusitis.

The drawbacks include higher cost, longer acquisition time, and poor delineation of bony anatomy. MRI should not be used routinely in the diagnosis of rhinosinusitis in the primary care setting.

### ■ RECOMMENDATIONS

Clinical judgment with a careful history and physical examination should generally suffice in the diagnosis of uncomplicated acute or subacute rhinosinusitis. The working definition of rhinosinusitis advocated by the Rhinosinusitis Task Force has been reported to have 87.7% sensitivity for the diagnosis of rhinosinusitis.<sup>6</sup> Thus, confirmatory plain radiography, given its low sensitivity, is rarely necessary in these cases.

In refractory or atypical cases requiring confirmation of sinusitis, simple axial or coronal CT can be sufficient for screening purposes. Patients with chronic or recurrent acute rhinosinusitis refractory to medical therapy or acute rhinosinusitis with complications require more detailed CT imaging to further



**FIGURE 3:** Coronal magnetic resonance imaging with gadolinium contrast shows extensive inverted papilloma of the right nasal cavity and paranasal sinuses (arrow).

delineate the extent of disease with 3-mm coronal sections or 1-mm axial reconstructions. Given the cost of MRI, it should only be used in rare cases of sinonasal neoplasia, fungal sinusitis, or suspected intracranial or orbital complications of rhinosinusitis. Fine-cut CT and MRI should not be utilized in the initial diagnostic stages of patients with uncomplicated rhinosinusitis. ■

### ■ REFERENCES

1. Okuyeni KS, Tsue TT. Radiologic imaging in the management of sinusitis. *Am Fam Physician* 2002; 66:1882–1886.
2. Lanza DC, Kennedy DW. Adult rhinosinusitis defined. *Otolaryngol Head Neck Surg* 1997; 117(suppl):S1–S7.
3. Yousem DM. Imaging of sinonasal inflammatory disease. *Radiology* 1993; 188:303–314.
4. Davidson TM, Brahme FJ, Gallagher ME. Radiographic evaluation for nasal dysfunction: computed tomography versus plain films. *Head Neck* 1989; 11:405–409.
5. Konen E, Faibel M, Kleinbaum Y, et al. The value of occipitomental (Waters') view in diagnosis of sinusitis: a comparative study with computed tomography. *Clin Radiol* 2000; 55:856–860.
6. Orlandi RR, Terrell JE. Analysis of the adult chronic rhinosinusitis working definition. *Am J Rhinol* 2002; 16:7–10.

**ADDRESS:** Pete S. Batra, MD, Section of Nasal and Sinus Disorders, Head and Neck Institute, A71, The Cleveland Clinic Foundation, 9500 Euclid Avenue, Cleveland, OH 44195; e-mail [batrap@ccf.org](mailto:batrap@ccf.org).