



BRIAN F. MANDELL, MD, PhD

Rheumatic and Immunologic Diseases, Center for Vasculitis Care and Research, Vice Chairman of Medicine for Educational Affairs, The Cleveland Clinic Foundation; Editor-in-Chief, Cleveland Clinic Journal of Medicine

Three rheumatologic emergencies: A sore toe, a cough, hypertension

ABSTRACT

Patients often present to internists with symptoms that can represent a minor illness or a rheumatologic emergency. This paper discusses the recognition and treatment of three rheumatologic emergencies: septic arthritis, alveolar hemorrhage as a complication of systemic lupus erythematosus (SLE), and scleroderma renal crisis.

KEY POINTS

Septic arthritis can cause permanent joint damage and has significant associated mortality. It should always be considered in a patient with acute joint swelling and pain.

Patients with SLE who present with dyspnea, pulmonary infiltrates, and new or worsened anemia should be evaluated for alveolar hemorrhage, even if there is no hemoptysis.

Blood pressure must be monitored regularly in patients with scleroderma. New increases, even if still within the normal range, must be followed closely.

Hypertension during scleroderma renal crisis must be treated very aggressively with angiotensin-converting enzyme inhibitors to bring blood pressure into the low-normal range.

Medical Grand Rounds articles are based on edited transcripts from Division of Medicine Grand Rounds presentations at The Cleveland Clinic. They are approved by the author but are not peer-reviewed.

This paper discusses therapies that are experimental or that are not approved by the US Food and Drug Administration for the use under discussion.

RHEUMATOLOGIC EMERGENCIES are not always obvious, be it joint pain in a healthy patient or mild blood pressure elevations in a patient with scleroderma.

In this article I discuss three rheumatologic emergencies that might present to an internist: septic arthritis, alveolar hemorrhage as a complication of systemic lupus erythematosus (SLE), and scleroderma renal crisis.

CASE 1: THE TALE OF A TOE

A 56-year-old man presents to an emergency department with 5 days of toe pain. The base of the toe is slightly swollen and reddened. He has no history of trauma or previous joint problems. He is taking hydrochlorothiazide for hypertension. A plain radiograph is taken and interpreted as normal.

Gout is diagnosed, and the patient is sent home with indomethacin 50 mg twice a day.

Ten days later, he reports to his internist that the pain is only partially relieved. The serum urate level is elevated at 8.8 mg/dL, and the internist agrees with the diagnosis of gout. Indomethacin is increased to 50 mg three times a day, and ranitidine 150 mg twice a day is added as gastric protection with the indomethacin therapy.

A few days later, the patient returns to the internist, reporting no further improvement. A plain radiograph now shows loss of definition at the ends of the metatarsophalangeal joint, with end-plate preservation at the joint space.

One week later, a rheumatologist is consulted. The patient still has toe pain without fever or other systemic complaints. The joint



is aspirated. The synovial fluid contains 28,000 white blood cells per mm^3 (normal < 200) with 96% neutrophils (normal $< 20\%$). No crystals are seen. The culture is positive for *Staphylococcus aureus*.

Diagnosis: septic arthritis. Intravenous oxacillin therapy is started, but the damage to the joint has been done: the radiograph now reveals reduced joint space and loss of bone at both ends.

■ SEPTIC ARTHRITIS

Risk of joint damage and mortality

Misdiagnosing septic arthritis can have serious consequences, not only because it can cause permanent joint damage, but because it is associated with significant mortality.

A 10-year retrospective survey¹ of patients with confirmed septic arthritis found the mortality rate to be 11.5%. Risk factors included age greater than 65 years, mental confusion at presentation, multiple joint involvement, and systemic symptoms (possibly indicating a high bacterial load). An additional 32% of patients were left with dramatically reduced function in the infected joints. Poor outcome was associated with a delay in diagnosis of more than 3 days, diabetes mellitus, and open surgical drainage.

In a 1988–1990 case series,² 100 patients presented with acute monoarticular arthritis. While about three fourths of patients had gout or pseudogout, 17% had septic arthritis. *S aureus* was found in 65% of infected cases and *Streptococcus* species in about 12%. Since this study was done, however, there seemingly has been a worldwide trend toward a higher proportion of streptococcal joint infections.

A small percentage of cases was caused by *Pasteurella multocida*, a serious infection acquired from cat bites that often leads to joint destruction. Obtaining a clinical history of cat bite is critical, because in such cases, I believe the joint should be surgically opened and lavaged.

Distinguishing infection from gout may be difficult

The only way to unequivocally distinguish septic arthritis from gout is to perform arthrocentesis with crystal analysis and culture. The clin-

ical presentation and other laboratory indicators are unreliable in making this distinction.

Toe involvement, even in the “classic” setting of gout—a middle-aged man with toe pain who is taking a thiazide diuretic—does not prove gout. Although knee and shoulder joints are more commonly involved in both monoarticular and polyarticular septic arthritis, in one case series the big toe was involved in 10% of cases.³

Clinical indicators of infection are insufficiently sensitive. In a study of 43 patients with septic arthritis, only 21% had rigors and only 41% had a fever.⁴

Acute-phase markers of infection are also unreliable.^{1,5} In a series of 243 episodes of septic arthritis, the C-reactive protein concentration was normal in 12%, the erythrocyte sedimentation rate was normal in 30%, and the white blood cell count was elevated in only half of patients.¹

Hyperuricemia is neither sensitive nor specific for distinguishing gout from infection. About 40% of patients hospitalized with septic arthritis have high levels of serum urate (B.F.M., unpublished data), and even patients with acute polyarticular gouty arthritis may have normal or even low serum urate levels.⁶ Urate levels may actually be lower in patients with gout during an attack than at other times, possibly due to cytokines released during the acute inflammatory response increasing uric acid excretion.

An initial study of the synovial fluid may also not be adequate to make a diagnosis. In a series of 200 cases in which the joint fluid was at least marginally inflammatory (white blood cell counts $> 2,000/\text{mm}^3$), only 37% of those with septic arthritis had counts greater than 100,000, 67% had more than 50,000, and 26% had fewer than 20,000.⁷ Even a Gram stain may not be positive despite culture-proven infection.^{5,7}

Concurrent gout and septic infection can occur, but fortunately rarely.^{8–10} Once crystals are found in the synovial fluid, one can generally assume that gout is the cause of the acute arthritis unless clinical factors suggest otherwise. It must be remembered that acute crystalline arthritis can be associated with fever, elevated acute-phase reactants, and leukocytosis.

The only way to distinguish septic arthritis from gout is to do arthrocentesis

The patient's chest radiograph

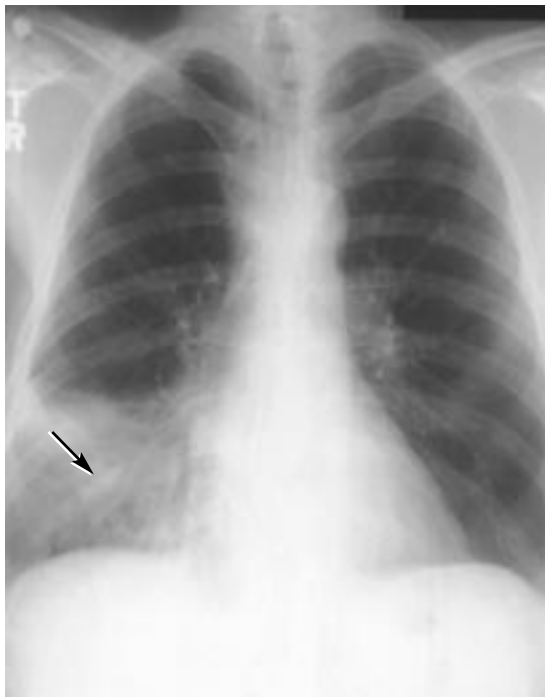

FIGURE 1. Right middle lobe infiltrate (arrow) in a man with systemic lupus erythematosus, fever, pleuritic chest pain, and dyspnea.

His hemoglobin level is 9.2 g/dL and falling

■ CASE 2: YOU ARE WHAT YOU COUGH

A 38-year-old man who has had systemic lupus erythematosus (SLE) for 5 years presents with fever, pleuritic chest pain, and mild dyspnea.

Medical history: The patient was seen 2 weeks ago because of the new onset of cutaneous vasculitis, worsening malar rash, and profound weight loss. He was found to have pancytopenia, hypocomplementemia, and high-titer anti-DNA antibodies. A bone marrow examination showed no evidence of a myelodysplastic process or other reason for pancytopenia.

Medications: prednisone 60 mg/day, calcium, hydroxychloroquine 200 mg twice daily.

Physical examination: respiratory rate 20, heart rate 110, right lateral chest rales, malar lupus rash with some ulceration, and new splinter hemorrhages in the hands.

Chest radiograph: right middle lobe infiltrate (FIGURE 1).

Laboratory values.

- Hemoglobin 9.2 g/dL (normal 13.5–17.5; 2 weeks ago it was 10.1 g/dL)
- White blood cell count $6.6 \times 10^9/L$ (normal 4.0–11.0; 2 weeks ago it was 2.6)
- Platelet count $120 \times 10^9/L$ (normal 150–400).
- A sputum sample cannot be obtained.

The patient is hospitalized

The patient is admitted to the hospital and given broad-spectrum antibiotics. Pulmonary embolism is excluded. His shortness of breath worsens, and he develops a prominent pleural rub.

Laboratory values.

- Hemoglobin 8.6 g/dL
- Lactate dehydrogenase slightly elevated
- Coombs test positive for immunoglobulin G (IgG) antibodies
- Haptoglobin elevated
- Bilirubin normal
- White blood cell count $2.6 \times 10^9/L$.

Still no sputum sample is available.

Chest radiograph: continued right middle lobe infiltrate and a new left lower lobe infiltrate.

Bronchoscopy: blood from the right middle lobe, cultures negative for infection.

Diagnosis: SLE-associated alveolar hemorrhage.

The patient is treated with methylprednisolone 1 g daily, azathioprine (he had developed neutropenia in the past after receiving low-dose cyclophosphamide, the preferred first-line drug), and 3 units of blood for the decreasing hemoglobin.

He continues to have no cough, no sputum, and no hemoptysis. Eight days later, his chest radiograph is completely clear and he is discharged.

Two weeks later the patient presents again with recurrent severe alveolar hemorrhage. He is coughing up scant bloody sputum and his radiograph at this time shows new diffuse bilateral patchy infiltrates.

■ ALVEOLAR HEMORRHAGE IN SLE

Alveolar hemorrhage is a medical emergency associated with a number of conditions (TABLE 1). It can occur in adults and children with



SLE, and occasionally is its initial presenting manifestation. It is fortunately uncommon, occurring in fewer than 5% of patients with SLE, although in a higher percentage of hospitalized patients with SLE.

Alveolar hemorrhage generally reflects lupus activity elsewhere in the body. Published mortality rates have ranged from 23% to 92%.

Classic triad

Alveolar hemorrhage classically involves three components.

Anemia is almost always present. Hemoglobin levels can drop dramatically, even in the absence of hemoptysis, and must be followed daily.

Pulmonary infiltrates may be diffuse or patchy, and usually are perihilar, sparing the apices. Changes, both positive and negative, may evolve more rapidly than in infection. Infiltrates tend to cross fissures and may occasionally mimic interstitial lung disease if the hemorrhage has been chronic and recurrent. Prior radiographs are extremely useful.

Hemoptysis is the most classic finding, but as in this case, may be absent. Bleeding is from low-pressure vessels; it may vary from scant to profuse, but it is rarely massive, as seen in proximal bronchial arterial bleeds.

Diagnosis

Diffusion capacity (DLCO) may be increased to 130%. Alveolar hemorrhage is one of the few conditions that causes hypoxia with an increased DLCO. However, this test is logistically difficult to perform on a patient who is coughing up blood, on a respirator, or unstable, so it is rarely practical in this setting. The DLCO may normalize rapidly over only 48 hours.

Other causes of hypoxia and dyspnea should be excluded. Infection must be considered in almost every case, as many patients with active SLE are on immunosuppressive therapy. Anti-glomerular basement membrane disease must also be excluded at the time of initial presentation because it requires prompt and aggressive apheresis to reduce the antibody load as part of the therapy.

Lupus pneumonitis can mimic alveolar hemorrhage. This is a more benign condition, involving focal inflammatory processes within

TABLE 1

Conditions associated with alveolar hemorrhage

- Systemic lupus erythematosus
- Wegener granulomatosis
- Microscopic polyangiitis
- Small-vessel vasculitis
- Anti-glomerular basement membrane disease
- Infection
- Pulmonary hemosiderosis
- Idiopathic

the lungs. The etiology is not well understood: the inflammatory process tends to come and go more slowly than hemorrhage but more quickly than is expected with infection. It responds to steroids and is treated less aggressively than alveolar hemorrhage.

Bronchoscopy is important to exclude infection and to document the presence of blood when there is no hemoptysis. If no frank bleeding is discovered, hemosiderin-laden macrophages provide proof that bleeding has occurred within the lung. Animal studies¹¹ show that hemosiderin-laden macrophages appear 3 days after blood is introduced into the alveolar space and persist for approximately 2 months. An acute inflammatory response to the blood, which appears as predominantly neutrophils, lasts for about 2 weeks in this mouse model. Cardiac problems with elevated left atrial pressures may also cause small amounts of alveolar hemorrhage and should also be considered when hemosiderin-laden macrophages are found.

Our published experience with SLE-associated alveolar hemorrhage includes 11 episodes among 7 patients found by a chart review over 5 years (out of a cohort of 663 patients with SLE followed at The Cleveland Clinic)¹² and four more episodes in the 4 years since then. No patients died, and radiographic clearing occurred in a mean time of about 8 days (range 4–12 days), despite dramatic “white-out” radiographic findings in some cases.

We learned several lessons from our experience.

Alveolar hemorrhage classically involves anemia, pulmonary infiltrates, and hemoptysis

rience:

Alveolar hemorrhage occurs unpredictably. In the published case series, the initial episode occurred from 2 weeks to 19 years after diagnosis. Almost all episodes occurred while patients were already on aggressive immunotherapy, and it was impossible to predict its development based on prior disease patterns.

Recurrences are very likely, occurring in over half the patients, ranging from 2 weeks to 28 weeks after chest radiographs completely cleared.

Clinical patterns vary. All patients presented with shortness of breath and new pulmonary infiltrates, and fever was a presenting symptom in 82% in the published series. Nearly half of the episodes did not include hemoptysis. Glomerulonephritis was the most common nonpulmonary manifestation, occurring in nearly three fourths of episodes in the initial series. Thrombocytopenia (mild) and leukopenia were also fairly common, reflecting coexisting SLE activity. All bronchoscopy lavage samples had hemosiderin-laden macrophages. The neutrophil counts ranged from 30% to 91%.

Prompt diagnosis, aggressive treatment, and intense supportive care are essential. In our case series, all patients underwent bronchoscopy to exclude infection. Patients were treated with high doses of methylprednisolone (240–1,000 mg/day for 3 days), and ventilator support in the intensive care department was provided as needed. All patients received antibiotics until infection could be excluded.

I believe it is reasonable to offer plasmapheresis until one can be certain that anti-glomerular basement membrane disease is not the cause of the hemorrhage. Despite the absence of data, it may also be reasonable to add plasmapheresis if the patient does not improve despite aggressive immunotherapy.

■ CASE 3: BEAUTY IS SKIN DEEP, KIDNEYS ARE DEEPER

A 41-year-old woman is admitted to the general medicine service for the second time in 2 weeks. She was first admitted for headache and refractory hypertension. Despite increasing doses of clonidine, prazosin, and

hydrochlorothiazide, her blood pressure was 230/130 mm Hg. She was evaluated for pheochromocytoma, but was thought not to have it. Renal artery Doppler ultrasonography (for renal artery stenosis) was normal.

Medical history. She has had Raynaud phenomenon for about 1 year without tissue destruction, and significant esophageal reflux over the past 4 to 5 months.

Physical examination: minimal sclerodactyly (thickening of the skin of the fingers), mouth pursing, and perioral and hand telangiectasias. No neck web sign (a tightening and pursing of the skin of the anterior neck) or tendon friction rubs, both markers of severe and progressive generalized scleroderma. Several dilated, periungual capillaries are noted, but without dropout (areas of absent capillary loops), as might be expected in generalized systemic sclerosis.

Blood pressure: 180/120 mm Hg in both arms.

Ophthalmic examination (undilated): rare retinal hemorrhages.

Cardiac examination: no gallop, no increased second component of pulmonary heart sounds.

Plain chest radiograph: normal.

Laboratory values.

- Antinuclear antibodies 1:640 with a nucleolar pattern (seen more commonly in scleroderma, but also may occur in lupus and other diseases as well as in patients with positive antinuclear antibodies and no underlying disease)
- Anti-double-stranded DNA antibodies undetectable
- Peripheral blood smear shows red blood cell fragments
- Hemoglobin 10.2 g/dL
- Platelet count $126 \times 10^9/L$ (a normal platelet count was documented in her medical chart several years ago during a routine health examination)
- White blood cell count $4.2 \times 10^9/L$
- Creatinine 2.1 mg/dL (normal < 0.7)
- Urinalysis: red blood cells and red blood cell casts documented by rheumatology consultant.

Renal biopsy: Since red blood cell casts suggested the presence of glomerulonephritis, perhaps due to a lupus/scleroderma overlap

In 5 years, we saw 11 episodes of alveolar hemorrhage in 7 patients out of 663 patients with SLE



syndrome, which would be treated aggressively with immunosuppressive drugs and not with “just” antihypertensive therapy, a renal biopsy is obtained. Intimal thickening and fibrosis of blood vessels and glomeruli are noted. Immunofluorescence study was negative. No evidence of inflammation or glomerulonephritis was observed.

Diagnosis: Recent-onset limited scleroderma or CREST syndrome (calcinosis is not evident, but Raynaud phenomenon, esophageal dysmotility, sclerodactyly, and telangiectasias are present) with renal crisis.

■ SCLERODERMA RENAL CRISIS

Scleroderma renal crisis is caused by an acute deterioration in renal function. It typically develops within the first few years after the onset of scleroderma.¹³ Unlike this patient, most patients have generalized scleroderma, with rapidly progressive skin thickening and tightening, friction rubs, and multiorgan involvement. Other features of scleroderma renal crisis include:

Dramatically rising creatinine, by as much as 1 mg/dL daily.

Hypertension in most cases. However, about 10% of patients have normal pressures. Renal crisis must be considered in any patient with scleroderma whose blood pressure rises even mildly, even if it still falls within the normal range: a 10 mm Hg rise above previous recordings warrants evaluation of creatinine level and follow-up blood pressure measurement in 1 or 2 days.

Elevated renin. Scleroderma renal crisis is characteristically associated with increased circulating renin levels. However, renin can be elevated in some patients with scleroderma who do not develop scleroderma renal crisis. Thus, it is not the ideal diagnostic or screening test.

“Bland” urine sediment has been described in most cases. Abnormal sediments, such as in this patient, suggest glomerulonephritis, and occur in a minority of cases. The exact incidence of nephritic sediment in scleroderma renal crisis is not defined.

Microangiopathic anemia, which occurs in nearly half of cases, is usually mild. A special review of the blood smear may be neces-

sary to document its presence.

Mild thrombocytopenia occurs frequently in the setting of scleroderma renal crisis, although it is not a characteristic of scleroderma.

Eye ground changes with retinal hemorrhages are very common. They reflect the acute blood pressure elevation from baseline; however, they can occur even in patients who are normotensive.

Eosinophilia may occur, but not as frequently in patients with scleroderma without scleroderma renal crisis.

A not uncommon, serious complication in patients with scleroderma

In a series from Italy¹⁴ of 300 patients with scleroderma who had been hospitalized for any cause, 13 (4%) had scleroderma renal crisis. Most (11) had generalized (or diffuse) scleroderma, and 2 had the CREST syndrome. Eleven patients were asymptomatic.

In another series of more than 800 patients with scleroderma, renal crisis occurred in 18%. Only 4 patients with renal crisis (3%) had limited scleroderma.¹⁵

The risk factors for development of scleroderma renal crisis are not fully understood. Patients with rapidly progressing generalized skin disease seem to be at highest risk.

Corticosteroid use increases risk

Scleroderma renal crisis is a vascular, not an inflammatory, disease. It does not respond to steroid therapy, and in fact, even low-dose corticosteroid use is a strong risk factor for developing renal crisis in patients with generalized disease. In a study of 110 patients with scleroderma renal crisis and 110 matched scleroderma controls, patients who used prednisone were nearly 9 times more likely to develop renal crisis.¹⁶ Symptom severity was controlled for in the analysis: the increased risk of patients on prednisone to develop scleroderma renal crisis could not be attributed to the more severely affected scleroderma patients selectively receiving steroid therapy.

Outcomes in scleroderma renal crisis

Scleroderma renal crisis is associated with considerable morbidity and mortality: a 50%

Her serum creatinine is 2.1 mg/dL, blood pressure 180/120 mm Hg

mortality rate (9 of 18 patients) was reported in one study.¹⁷


In a series in Pittsburgh, 60% of patients had favorable outcomes; 34 of these patients required only temporary dialysis (2–18 months), and the other 15 did not need dialysis. Mortality was approximately 19%; another 20% remained on chronic dialysis. Those who survived off of dialysis remained on angiotensin-converting enzyme (ACE) inhibitors and did as well as other patients without scleroderma renal crisis.¹⁵

Patients with end-stage renal disease underwent either peritoneal dialysis or hemodialysis. Complications were comparable to those in patients who needed dialysis for other reasons. Six patients received transplants and had outcomes comparable to matched control transplant patients without diabetes. However, other data on scleroderma patients with transplants suggest outcomes similar to those of diabetic patients, ie, worse

than in patients receiving transplants for IgA nephropathy.

Treat hypertension aggressively

Early recognition and aggressive treatment of scleroderma renal crisis are key to improving outcome. The earliest signs in a patient with either limited or generalized scleroderma are listed above. Most specifically, any otherwise unexplained acute increase in blood pressure or rise in serum creatinine (0.5–1.0 mg/dL/day) should raise immediate concern and prompt therapeutic intervention.

Treatment consists of aggressive antihypertensive therapy with ACE inhibitors in combination with other agents as needed to bring blood pressure to the low-normal range. Dialysis may be necessary, and should not preclude the use of ACE inhibitors. ACE inhibitors should be continued even if end-stage renal disease develops, since there may be delayed recovery of renal function. 

REFERENCES

1. Weston VC, Jones AC, Bradbury N, Fawthrop F, Doherty M. Clinical features and outcome of septic arthritis in a single UK Health District 1982–1991. *Ann Rheum Dis* 1999; 58:214–219.
2. Mandell BF. The Graduate Hospital/HUP Philadelphia, 1988–1990 (unpublished observation).
3. Martens PB, Ho G Jr. Septic arthritis in adults: clinical features, outcome, and intensive care requirements. *J Intensive Care Med* 1995; 10:246–252.
4. Schlapbach P, Ambord C, Blochlinger AM, Gerber NJ. Bacterial arthritis: are fever, rigors, leucocytosis and blood cultures of diagnostic value? *Clin Rheumatol* 1990; 9:69–72.
5. Soderquist B, Jones I, Fredlund H, Vikerfors T. Bacterial or crystal-associated arthritis? Discriminating ability of serum inflammatory markers. *Scand J Infect Dis* 1998; 30:591–596.
6. Hadler NM, Franck WA, Bress NM, Robinson DR. Acute polyarticular gout. *Am J Med* 1974; 56:715–719.
7. Coutlakis PJ, Roberts WN, Wise CM. Another look at synovial fluid leukocytosis and infection. *J Clin Rheumatol* 2002; 8:67–71.
8. Yu KH, Luo SF, Liou LB, et al. Concomitant septic and gouty arthritis—an analysis of 30 cases. *Rheumatology (Oxford)* 2003; 42:1062–1066. Epub 2003 Apr 16.
9. Hamilton ME, Parris TM, Gibson RS, Davis JS 4th. Simultaneous gout and pyarthrosis. *Arch Intern Med* 1980; 140:917–919.
10. O'Connell PG, Milburn BM, Nashel DJ. Coexistent gout and septic arthritis: a report of two cases and literature review. *Clin Exp Rheumatol* 1985; 3:265–267.
11. Epstein CE, Elidemir O, Colasurdo GN, Fan LL. Time course of hemosiderin production by alveolar macrophages in a murine model. *Chest* 2001; 120:2013–2020.
12. Santos-Ocampo AS, Mandell BF, Fessler BJ. Alveolar hemorrhage in systemic lupus erythematosus: presentation and management. *Chest* 2000; 118:1083–1090.
13. Steen VD, Medsger TA Jr. Severe organ involvement in systemic sclerosis with diffuse scleroderma. *Arthritis Rheum* 2000; 43:2437–2444.
14. La Montagna G, Baruffo A, Maya L, et al. Scleroderma renal crisis. Analysis of prevalence and outcome in a large Italian series. *J Clin Rheumatol* 1997; 3:188–193.
15. Steen VD, Medsger TA Jr. Long-term outcomes of scleroderma renal crisis. *Ann Intern Med* 2000; 133:600–603.
16. Steen VD, Medsger TA Jr. Case-control study of corticosteroids and other drugs that either precipitate or protect from the development of scleroderma renal crisis. *Arthritis Rheum* 1998; 41:1613–1619.
17. DeMarco PJ, Weisman MH, Seibold JR, et al. Predictors and outcomes of scleroderma renal crisis: the high-dose versus low-dose D-penicillamine in early diffuse systemic sclerosis trial. *Arthritis Rheum* 2002; 46:2983–2989.

ADDRESS: Brian F. Mandell, MD, PhD, Division of Education, NA20, The Cleveland Clinic Foundation, 9500 Euclid Avenue, Cleveland, Oh 44195; e-mail mandellb@ccf.org.

Suspect renal crisis in any scleroderma patient with an acute rise in blood pressure or creatinine