

**AMAN ALI, MD**Department of General Internal Medicine,
The Cleveland Clinic Foundation**NIZAR N. ZEIN, MD**Director, Clinical Hepatology,
Department of Gastroenterology,
The Cleveland Clinic Foundation

Hepatitis C infection: A systemic disease with extrahepatic manifestations

ABSTRACT

Mixed cryoglobulinemia, renal syndromes, lymphoproliferative disorders, Sjögren syndrome, porphyria cutanea tarda, and neuropathies are all strongly associated with hepatitis C virus (HCV) infection. Diabetes, thyroid disease, and the presence of autoantibodies in the serum are also linked to HCV, but less strongly. The pathophysiologic basis for most of these syndromes seems immunologic. Cirrhosis and chronic HCV infection seem to be risk factors.

KEY POINTS

Mixed cryoglobulinemia can be detected in up to half of patients with HCV infection, but in 90% of cases it causes no symptoms and requires no specific treatment.

Mixed cryoglobulinemia can evolve into a florid B-cell malignancy in up to 11% of cases.

The most common renal manifestation of HCV infection is membranoproliferative glomerulonephritis. Less often, HCV causes focal segmental glomerulosclerosis or membranous or proliferative glomerulonephritis.

Antiviral therapy should be considered in patients with severe extrahepatic manifestations such as symptomatic mixed cryoglobulinemia syndrome with systemic cryoglobulinemic vasculitis, severe ulcerations, Raynaud syndrome, and arthralgias.

ALMOST 40% of patients infected with hepatitis C virus (HCV) develop at least one extrahepatic manifestation during the course of the disease.¹ These syndromes are important to recognize, as most HCV-infected patients have no hepatic symptoms, and extrahepatic syndromes may be the reason that they seek medical attention.

Pascual et al² first suggested an association between HCV and extrahepatic syndromes in 1990, when they described two patients with HCV infection and mixed cryoglobulinemia. Since then, various extrahepatic syndromes including renal disease, lymphoproliferative disorders, and many other conditions complicating HCV infection have been reported. In some of the syndromes the role of HCV is well established, while in others it is still speculative (FIGURE 1).

This review focuses on the current understanding and potential clinical implications of extrahepatic syndromes that may complicate HCV infection. It also examines the role of HCV genotypes in the development of these syndromes and the potential benefit of interferon and ribavirin therapy.

HCV IS COMMON

HCV infection affects nearly 2% of the American population and approximately 3% of the world population.^{1,3,4} The virus exists as various genotypes, as shown by nucleotide sequence variability of the viral isolates. This genetic heterogeneity may account for the antigenic and biological diversity seen in HCV-infected patients.⁵

■ MIXED CRYOGLOBULINEMIA IS STRONGLY LINKED TO HCV

The syndrome in which the link to HCV is strongest is mixed cryoglobulinemia with or without associated vasculitis. In fact, most cases of mixed cryoglobulinemia, which used to be called “essential,” are now recognized as being due to HCV.

Three types of cryoglobulins

Cryoglobulins are immunoglobulins that reversibly precipitate at temperatures lower than 37°C, and, when deposited in small blood vessels, may cause a vasculitic syndrome.

Cryoglobulinemias are categorized as type I, II, or III on the basis of the clonality of the responsible immunoglobulin.

- In type I, the cryoprecipitate contains an isolated monoclonal immunoglobulin such as immunoglobulin G (IgG) or IgM, usually lymphoproliferative disease.
- Type II is mixed: the cryoprecipitate consists of polyclonal immunoglobulins (mainly IgG) plus monoclonal immunoglobulins (IgM, IgG, or IgA).
- Type III is also mixed: the cryoprecipitate contains both polyclonal IgG and polyclonal IgM.

Strong associations exist between HCV and mixed cryoglobulinemia types II and III,^{6,7} and some studies⁸ also suggest an association between type I and HCV, in particular the HCV 2a/c genotype.

How does HCV cause cryoglobulinemia?

How HCV causes cryoglobulinemia is not well established, but the virus has tropism for peripheral lymphocytes, which may serve as its reservoir and a place for it to replicate.⁹ Several cellular receptors have been implicated in HCV-induced lymphoproliferation, including the LDL and CD81 receptors.

One hypothesis is that HCV binds to tetraspanin CD81 ligand on the surface of B lymphocytes via E2 protein (the second portion of the HCV envelope),¹⁰ leading to activation of these lymphocytes. This CD81-E2 interaction lowers the antigen threshold necessary for antibody production and could lead to exacerbated assembly of cryoglobulins. The cryoglobulins produced initially are polyclonal

IgG (mixed cryoglobulinemia type III), but as a dominant B-cell clone emerges, it may produce monoclonal immunoglobulins as well (type II mixed cryoglobulinemia). Production of monoclonal rheumatoid factor is common.

In early 1990 several investigators reported that 50% to 90% of patients with mixed cryoglobulinemia had detectable HCV RNA.^{6,7} In a more recent study,¹¹ 321 (73%) of 443 patients with cryoglobulinemia had anti-HCV antibodies. Similarly, the prevalence of cryoglobulins in HCV-infected patients ranges from 0% to 59%, varying widely by region.^{1,11,12}

More evidence that HCV causes mixed cryoglobulinemia is that concentrations of HCV RNA and anti-HCV antibodies are much higher in the cryoprecipitate than in the serum (10 times higher for HCV RNA and 100 times higher for anti-HCV antibodies).^{6,7}

No clear-cut predictors for the development of mixed cryoglobulinemia in HCV infection have been identified, but suggested factors are long-term infection and advanced liver disease (cirrhosis). In addition, some investigators report a higher prevalence of HCV genotype 2a in patients with mixed cryoglobulinemia, although most studies did not confirm this finding.¹³ A study of HLA II alleles in HCV patients found that HLA DRB1*11 (DR11) predicted cryoglobulinemia, whereas HLA DR 27 predicted no cryoglobulinemia.¹⁴

Clinical features of mixed cryoglobulinemia

Although up to half of patients with chronic HCV infection have detectable serum cryoglobulins, 90% have no clinical symptoms and need no specific therapy for cryoglobulinemia.¹⁵ The syndrome of HCV-associated cryoglobulinemic vasculitis, on the other hand, occurs in fewer than 10% of HCV-infected patients with detectable serum cryoglobulins but may lead to involvement of various organ systems, eg:

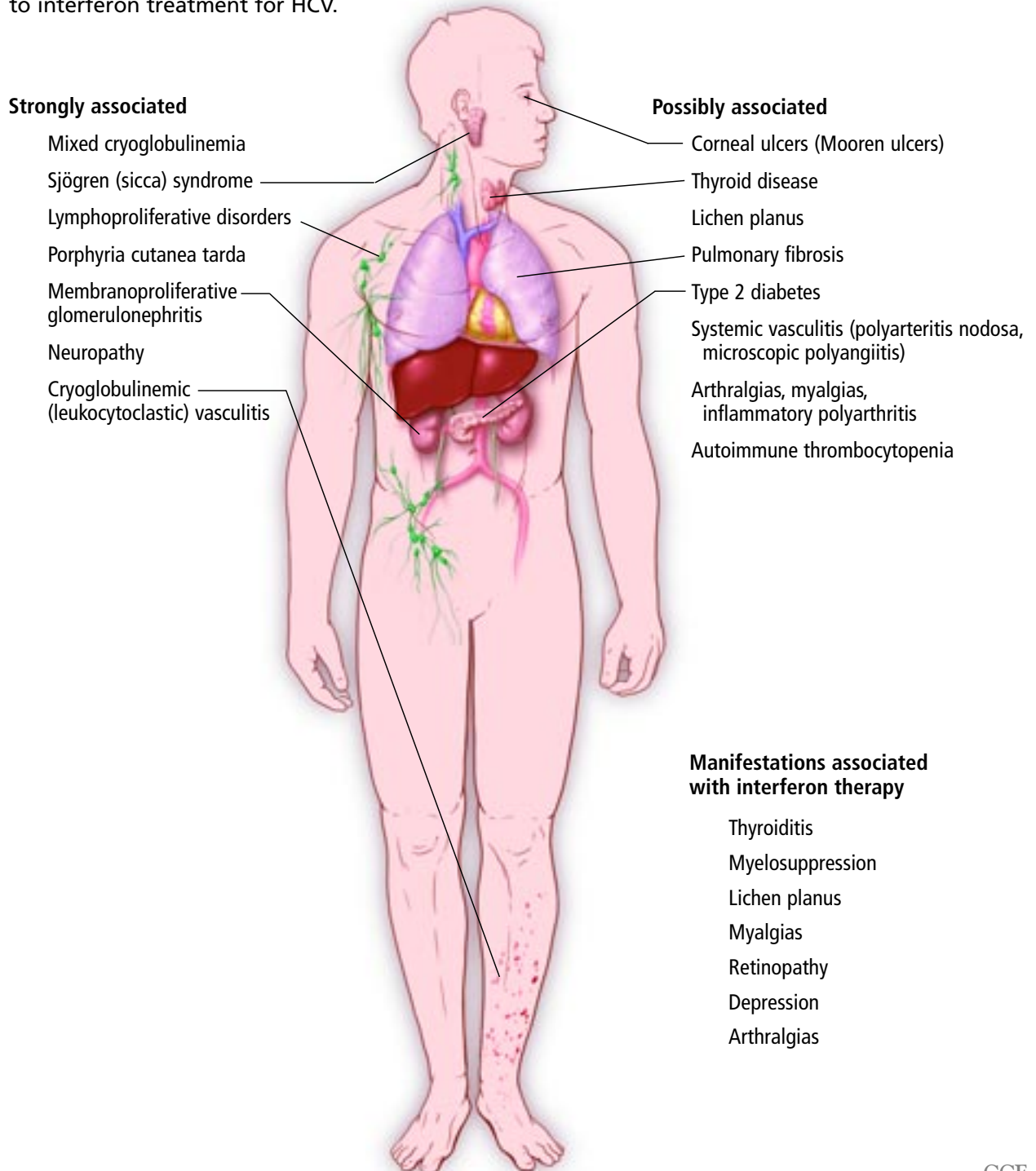
- **Cutaneous manifestations** ranging from palpable purpura (the most common; **FIGURE 1**) to large necrotic ulcerations.
- **Peripheral neuropathy**, eg, sensory neuropathy and mononeuritis multiplex.¹⁶
- **Other clinical manifestations**, including glomerular disease, arthralgias, and arthritis.¹⁷

Cryoglobulins can cause a vasculitic syndrome in various organ systems



Hepatitis C infection: A systemic disease

Many extrahepatic syndromes can complicate hepatitis C virus (HCV) infection. Some are strongly linked to HCV, others are less strongly linked, and yet others are due to interferon treatment for HCV.



CCF
Medical Illustrator: Ross Papalardo ©2005

FIGURE 1

**Mildly elevated
cryoglobulins
do not equal
cryoglobulin
disease**

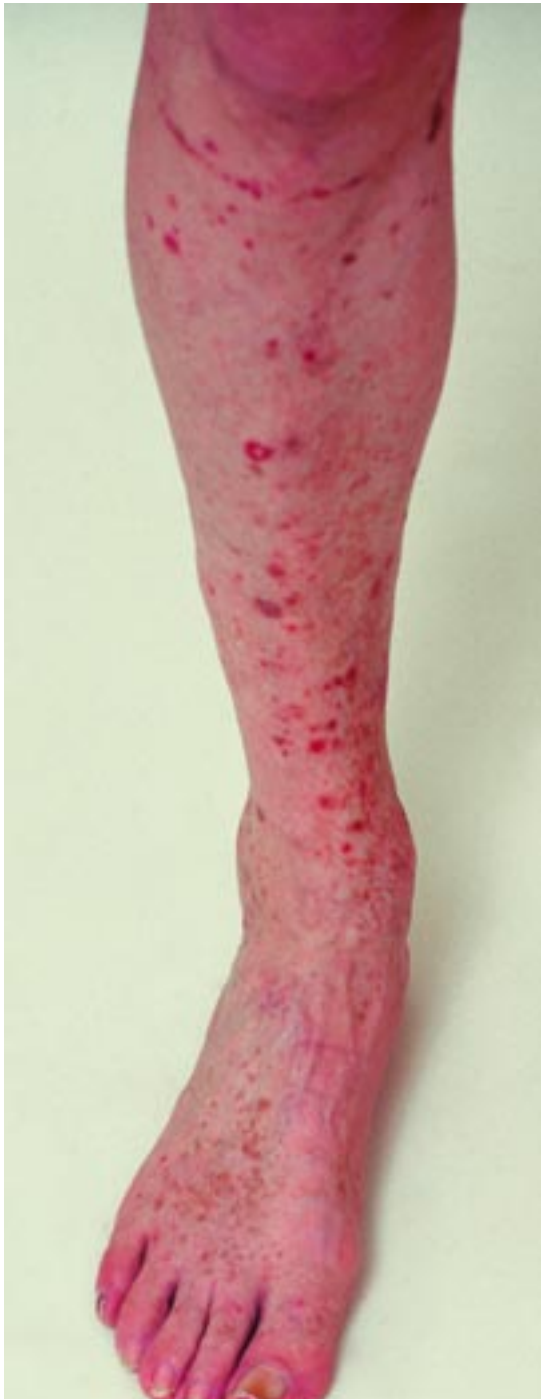

FIGURE 2. Cryoglobulinemic vasculitis.

Caveats in cryoglobulin testing

When mixed cryoglobulinemia is suspected, serum cryoglobulin complement levels should be measured. However, remember that mild elevation of cryoglobulins is common in HCV-infected patients and does not equal

cryoglobulin-associated disease.

Furthermore, a negative cryoglobulin test result does not exclude mixed cryoglobulinemia, as the test can be falsely negative. Reasons for false-negative results include very low serum concentrations of cryoglobulins, failure of standard laboratory tests to detect cryoglobulins, and errors in sample collection technique, the latter being critical for adequate testing. Blood should be drawn in warmed syringes and centrifuged at 37°C. Serum is then stored at 4°C for at least 72 hours before cryoprecipitate can be quantified accurately.

Many patients with mixed cryoglobulinemia have low serum complement levels.⁶

Interferon can ameliorate cryoglobulinemia

Interferon can ameliorate many of the manifestations of mixed cryoglobulinemia, including vasculitis and renal dysfunction, but if the HCV infection relapses after treatment is completed, the cryoglobulinemia and its manifestations often recur.¹⁸

A recent large trial suggested that a sustained viral response leads to lower cryoglobulin levels and less fatigue.¹⁹ For these reasons, the goal of therapy in patients with HCV infection and mixed cryoglobulinemia-associated clinical disease should be to eradicate the virus, since treating the vasculitis syndrome alone without antiviral therapy may yield only temporary control of symptoms.

Interferon alfa is the mainstay of treatment; options or to add a corticosteroid, to add ribavirin, or to use interferon conjugated to polyethylene glycol (“pegylated” interferon) rather than standard interferon.

Interferon-plus-corticosteroid therapy has undergone randomized clinical trials, but its role is yet unclear. Dammacco et al²⁰ showed that the combination of interferon alfa and methylprednisolone resulted in a slightly earlier virologic response and a longer time to virologic relapse after therapy was stopped, but it had no significant long-term advantages over interferon alfa monotherapy.

Interferon plus ribavirin produced marked improvements in proteinuria, arthralgias, and vasculitic symptoms in patients with refractory HCV-related cryoglobulinemia in a study by Zuckerman et al.²¹

Ribavirin monotherapy is not indicated

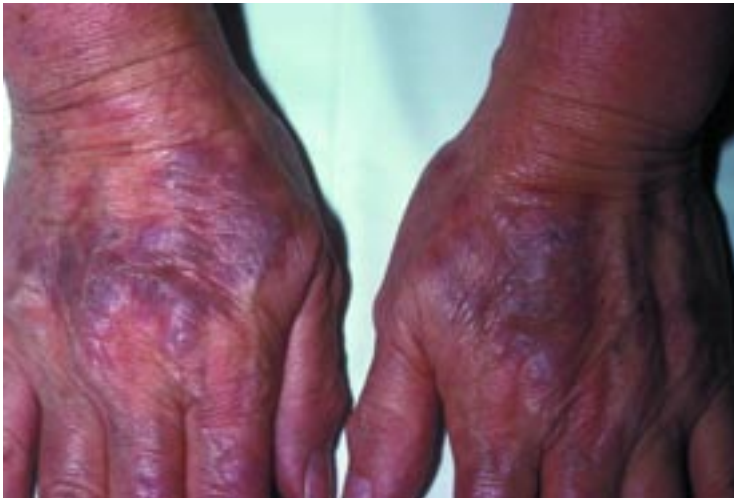

FIGURE 3. Porphyria cutanea tarda.

in HCV treatment (it improves alanine aminotransferase levels but does not clear HCV), but it may have a role in controlling mixed cryoglobulinemia-related symptoms in patients who cannot tolerate interferon.²²

Pegylated interferon with or without ribavirin has yet to be studied in HCV-related mixed cryoglobulinemia, although results are likely to be at least as good as those with standard interferon, given that pegylated interferon produces higher viral eradication rates.

■ DERMATOLOGIC DISORDERS

Dermatologic disorders associated with chronic HCV infection include cryoglobulinemic vasculitis, porphyria cutanea tarda, and lichen planus. Others (pyoderma gangrenosum, erythema nodosum, and urticaria) have been described in case reports only, and their association with HCV seems weak.

Cutaneous (cryoglobulinemic) vasculitis

Mixed cryoglobulinemia most often affects the skin of the legs in the form of palpable purpura (leukocytoclastic vasculitis) and petechiae (**FIGURE 2**). Papules, ulcers, and livedo can also occur and can affect any skin site. Biopsy of these skin lesions shows immune complex vasculitis in small vessels with predominant mononuclear infiltrate in the vessel walls. HCV antigens are detected in skin lesions in 40% of cases.²³

If interferon produces a sustained viral response, it also improves the cutaneous vas-

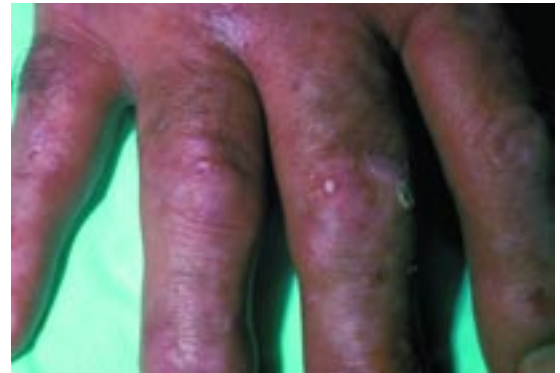


FIGURE 4. Porphyria cutanea tarda.

culitis, usually within the first month of treatment.

Porphyria cutanea tarda

Porphyria cutanea tarda, the most common form of porphyria in the United States, is characterized by low uroporphyrinogen decarboxylase (uro-D) activity.

There are two varieties of porphyria cutanea tarda. Type 1 (the sporadic form) is more common and is characterized by reduced uro-D activity in hepatocytes only. Type 2 (the familial form) is rare, with uro-D activity reduced in other cell types, including erythrocytes. The two types are easily distinguished by measuring uro-D activity in erythrocytes.

Clinical features of porphyria cutanea tarda include photosensitivity, skin fragility, bruising, and vesicles and bullae that may become hemorrhagic (**FIGURE 3**, **FIGURE 4**). The chronic findings include hyperpigmentation, hypopigmentation, hirsutism, and skin thickening similar to that of scleroderma (**FIGURE 4**).

Porphyria cutanea tarda is strongly linked epidemiologically to HCV infection, especially in southern Europe. The prevalence of HCV infection in patients with porphyria cutanea tarda is high: 40% to 50% depending on the country.^{24,25} Conversely, however, the prevalence of porphyria cutanea tarda in patients with chronic HCV infection is low (< 5% in most studies). The highest rates are in patients with HCV-related liver cirrhosis, suggesting that cirrhosis may play a role in the development of porphyria cutanea tarda.¹

**Pegylated
interferon
has not yet
been studied
in HCV-related
cryoglobulin-
emia**

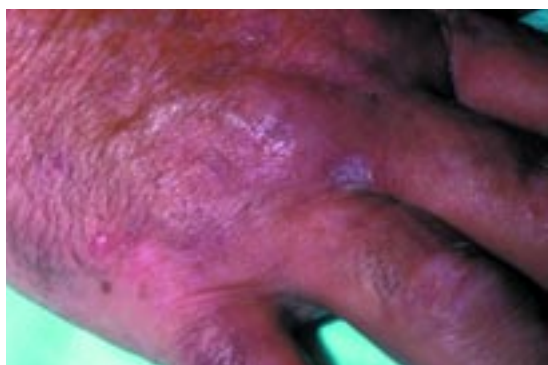


FIGURE 5. Lichen planus.

It is therefore possible that HCV may trigger the clinical expression of porphyria cutanea tarda in some patients, although the mechanism remains obscure. HCV does not directly affect uro-D activity, but some speculate that the development of porphyria cutanea tarda might be related to HCV-induced hepatic iron overload.²⁴

A strong association between the HCV 1b genotype and porphyria cutanea tarda has been reported in at least one study.²⁶

No randomized clinical trials have yet examined the effect of antiviral treatment on porphyria cutanea tarda. However, in case reports, the lesions were said to disappear following interferon therapy for HCV.²⁷ Phlebotomy has traditionally been used for treating porphyria cutanea tarda, given the iron overload often seen.

Lichen planus

Lichen planus is a recurrent pruritic eruption characterized by flat-topped, violaceous papules that can develop on any skin site, with or without mucous membrane (oral) involvement (FIGURE 5, FIGURE 6).

The pathogenesis remains obscure. Skin biopsy typically shows a lymphocytic infiltrate in the upper dermis.

Lichen planus is well known to be associated with liver diseases, especially advanced hepatic disorders. Although small studies have suggested a link between HCV and lichen planus,²⁸ a large prospective study involving predominantly noncirrhotic HCV patients failed to show the association.¹ These findings suggest a possible link between lichen planus and HCV-induced cirrhosis but not the infection alone.

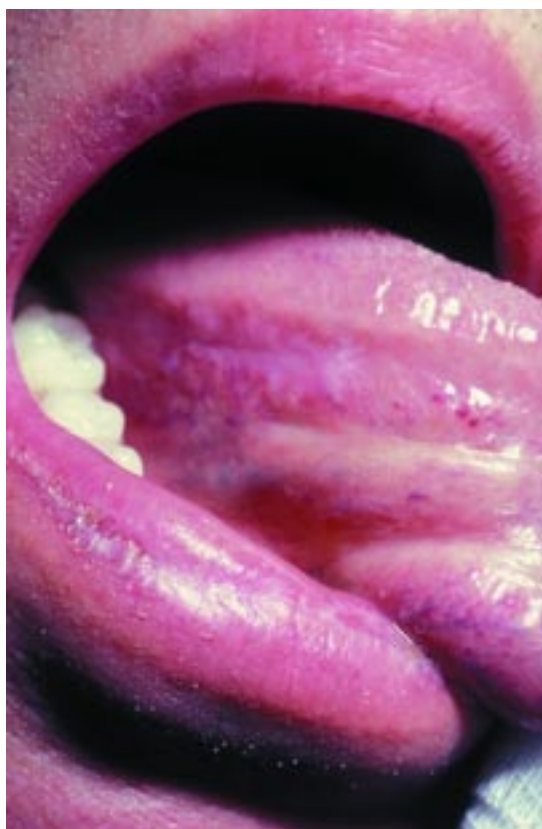

FIGURE 6. Oral lichen planus.

Lichen planus responds variably to interferon treatment: both improvement²⁹ and exacerbation³⁰ of symptoms have been reported.

RENAL SYNDROMES

The most common renal manifestation of HCV infection is membranoproliferative glomerulonephritis (MPGN) with or without mixed cryoglobulinemia.^{31–33} Less often, HCV causes focal segmental glomerulosclerosis or membranous or proliferative glomerulonephritis.^{33,34}

MPGN: Strong link to HCV

MPGN is strongly associated with chronic HCV infection and should be suspected when an infected patient develops significant proteinuria, especially with cryoglobulinemia and hypocomplementemia. Antiviral therapy should be considered and may lessen the proteinuria.

The prevalence of HCV infection in MPGN varies by country, from 60% in Japan³³ to about 10% to 20% in the United States.³¹

Up to 50% of patients with porphyria cutanea tarda have HCV

The prevalence is higher in patients with cryoglobulinemia: HCV RNA is present in nearly 81% of cases of cryoglobulinemia-related MPGN vs only 25% of cases of noncryoglobulinemic MPGN.⁶

Nephrotic-range proteinuria (> 3 g/24 hours) in a patient with chronic HCV infection should raise the suspicion of MPGN. Most patients with these features have detectable cryoglobulins at presentation or follow-up³¹; many have low serum complement levels.⁶ Although approximately 80% of patients with HCV-related MPGN have no symptoms of liver disease, 50% have histologic evidence of cirrhosis.^{33,34}

The pathogenesis of HCV-related MPGN is probably immune-complex-mediated, as renal biopsies typically demonstrate deposition of IgG, IgM with rheumatoid factor activity, and C3.³¹ HCV RNA has been inconsistently demonstrated in the glomeruli, and it may be related to the artifact posed by rheumatoid factor. Other proposed mechanisms are impaired hepatic clearance of immune complexes and direct rheumatoid factor-induced damage to the mesangium of the glomerulus.³⁵

MPGN improves with interferon, but relapses after therapy

Numerous studies^{16,21,31,32} suggest that mixed cryoglobulinemia-related MPGN improves with interferon monotherapy or with combined interferon and ribavirin. However, although proteinuria decreased in those studies, serum creatinine levels did not, and the proteinuria returned after interferon was stopped, as did the HCV infection.

The combination of interferon and corticosteroids may have a short-term benefit in controlling severe exacerbations of MPGN, although no long-term benefit has been observed.²⁰ In addition, long-term corticosteroid therapy can enhance viral replication and causes side effects that limit its use. Despite these limitations, a trial of interferon-plus-corticosteroid treatment is indicated in patients with severe renal disease or MPGN refractory to interferon monotherapy, at least for the potential short-term benefit.²¹

As yet, no large studies have assessed the efficacy and safety of pegylated interferon for

patients with HCV and MPGN.

Finally, limited data regarding the use of rituximab (monoclonal anti-CD20 antibody) in the treatment of mixed cryoglobulinemia associated with HCV has suggested potential benefit in decreasing cryoglobulin values and vasculitis manifestations.^{36,37} Even more limited data suggested a role for apheresis in the treatment of HCV-related cryoglobulinemia.³⁸

■ SJÖGREN SYNDROME, LYMPHOCYTIC SIALOADENITIS

There is a strong epidemiologic link between HCV and lymphocytic sialoadenitis, which closely resembles and is possibly related to sialoadenitis associated with idiopathic Sjögren syndrome. HCV-related sialoadenitis may be differentiated from classic Sjögren syndrome by the absence of anti-SSA/Ro, anti-SSB/La antibodies, milder lymphocytic pericapillaritis, and absence of xerostomia and xerophthalmia in about 90% of patients.^{12,39,40}

Although only 10% of HCV-infected patients have sicca symptoms, up to 75% have histological evidence or a test abnormality (ie, xerophthalmia detected by Rose Bengal stain, Schirmer test, sialometry) consistent with it.^{1,12,39,40}

The pathogenesis of HCV-related sialoadenitis is not completely understood. The virus is unlikely to have a direct effect, as HCV has not been demonstrated in glandular tissue.¹² The proposed mechanisms include cross-reactivity between the HCV envelope and host salivary tissue or HCV envelope-mediated immune stimulation that is directed against salivary glands. These mechanisms are supported by studies in mice that were transgenic for HCV envelope (E2) protein.⁴¹

No trials have studied the effect of interferon treatment on sialoadenitis associated with HCV infection.

■ AUTOANTIBODIES AND AUTOIMMUNE CHRONIC ACTIVE HEPATITIS

From 45% to 65% of HCV-infected patients have various autoantibodies.¹ These antibodies do not affect the outcome and they are not associated with any particular HCV geno-

Suspect MPGN if there is:

- HCV infection
- Proteinuria
- Cryoglobulins
- Low complement



type.⁴² However, they are also present in patients with autoimmune hepatitis and other rheumatologic disorders, creating a diagnostic challenge.

Although the mechanism of production of these antibodies in HCV infection remains obscure, it does not appear to be a nonspecific polyclonal B-cell stimulation. Antiactin antibodies are usually seen in autoimmune hepatitis type 1, and anti-liver, kidney, and microsomal (anti-LKM-1) antibodies are usually seen in autoimmune hepatitis type 2, but they are also produced by HCV-infected patients. In fact, HCV is now recognized as the most common cause of anti-LKM-1 antibodies in the United States.⁴³

Anti-LKM-1 antibodies do not influence the response to interferon treatment. However, during the course of interferon therapy, some patients with these antibodies present with a hepatitis flare that resembles autoimmune hepatitis and that may respond to immunosuppression.⁴⁴ Therefore, it has been proposed that patients with combined features of HCV and autoimmune hepatitis (high levels of autoantibodies and consistent histology) undergo a course of corticosteroids to assess biochemical and histologic response.⁴⁴

■ ENDOCRINE SYNDROMES

Diabetes mellitus

HCV was associated with diabetes mellitus in several epidemiologic studies.^{45–47} In the largest US study, of 1,117 patients with chronic viral hepatitis, Mason and colleagues⁴⁵ found that diabetes was present in significantly more patients with HCV infection than with chronic hepatitis B virus (HBV) infection (21% vs 12%). The combination of diabetes plus chronic HCV infection was strongly associated with advanced liver fibrosis or cirrhosis and with HCV genotype 2a. However, after patients with known predisposing factors for diabetes (including cirrhosis) were excluded, the prevalence of diabetes was not statistically different between the HCV and HBV groups. This finding highlights the well-known association between abnormal glucose metabolism and cirrhosis that has been confirmed by other investigators.⁴⁶

Zein and coworkers⁴⁷ found a higher prevalence of diabetes in patients with cirrhosis due to HCV (25%) or alcoholic liver disease (19%) than in patients with cirrhosis due to cholestatic liver disease (1.3%—the same as in the general population). Bigam et al⁴⁸ noted similar numbers in liver transplant patients.

These findings suggest that cirrhosis alone does not explain the epidemiologic link between HCV and diabetes mellitus and that HCV may independently contribute to the development of diabetes.^{47,49} Cirrhotic patients are believed to have decreased hepatic uptake of glucose along with reduced hepatic clearance of insulin, leading to hyperinsulinemia and insulin resistance syndrome.⁴⁶ Moreover, transgenic mice without cirrhosis developed insulin resistance after being inoculated with HCV core protein.⁵⁰ The coexistence of these two diabetogenic factors (cirrhosis and HCV) is likely to explain the high prevalence of diabetes in HCV patients.

The role of HCV therapy and its effect on diabetes is not known. Interferon therapy has actually been associated with the induction of insulin-dependent diabetes in some patients, possibly by stimulating an autoimmune process against pancreatic beta cells.⁵¹ On the other hand, Konrad et al⁵² suggest that interferon treatment might improve glucose intolerance in nondiabetic HCV patients and therefore may be beneficial.

Thyroid diseases

Thyroid disorders are common in patients with chronic HCV infection. As many as 13% of HCV-infected patients (especially older women) have hypothyroidism, and up to 25% have thyroid antibodies independent of the stage of liver disease^{53,54}—more than in control groups including patients with chronic hepatitis B infection (16%) or people living in iodine-deficient regions (17%).⁵³

Moreover, interferon treatment for HCV may unmask autoimmune thyroid disease in a substantial number of patients, including those with hypothyroidism, Graves disease, Hashimoto thyroiditis, and isolated high titers of thyroid antibodies without thyroid dysfunction.^{54,55}

The most significant risk factor for these disorders during interferon treatment is pre-

Diabetes is very common in HCV patients with cirrhosis

treatment positivity for antithyroid peroxidase antibodies, especially in older women.⁵⁴ The estimated relative risk for developing autoimmune thyroid disorders during interferon treatment for chronic HCV is 4.4 (95% confidence interval 3.2–5.9). Interferon is believed to trigger these disorders in genetically susceptible people.⁵⁶

Interferon-induced hypothyroidism can be treated with thyroid replacement therapy without stopping the interferon treatment.

■ LYMPHOPROLIFERATIVE DISORDERS

Mixed cryoglobulinemia can evolve into a florid B-cell malignancy in up to 11% of cases.⁵⁷

The mechanism for this malignant transformation is still unclear. It may involve clonal B-cell expansion induced by HCV. Another possibility is inhibition of apoptosis of HCV-infected lymphocytes by t(18;14) translocation, which results in overexpression of the bcl-2 oncogene.⁵⁸ Then a second mutation (myc oncogene) may lead to the development of lymphoma.⁵⁹

Several studies in Japan, Italy, and the United States suggested a high prevalence of HCV infection in patients with non-Hodgkin lymphoma.^{61,61} On the other hand, studies in Canada, France, and the United Kingdom^{62,63} failed to show a clear-cut association (possibly owing to geographic variation).

The most common types of non-Hodgkin lymphoma associated with HCV infection are follicular lymphoma and lymphoplasmacytoid/immunocytoma (Lp/Ic) subtype. Some Italian studies⁶¹ confirmed that Lp/Ic has the strongest association with HCV, especially in the presence of cryoglobulinemia.

Approximately 65% of HCV-related lymphomas have extranodal involvement (particularly in salivary glands and the liver) compared with 19% of non-HCV-related lymphomas.⁶⁴ De Vita et al⁶⁵ observed that the relative risk for developing lymphoma in the salivary glands and liver was 50 times higher in HCV-infected patients; in contrast, in the other extranodal sites the risk was four times higher.

Several investigators also demonstrated a strong link between HCV infection and

mucosa-associated lymphoid tissue (MALT) lymphoma.^{66,67} HCV RNA has been isolated in the gastric mucosa of patients with MALT lymphoma,⁶⁷ raising the possibility that HCV may play a role in its pathogenesis. There are no formal recommendations for screening patients with cryoglobulins for lymphoma, however.

Interferon may help in low-grade B-cell lymphoma

The role of interferon therapy in the management of HCV patients with lymphoproliferative disorders is not entirely clear, although some benefit has been demonstrated.

Zuckerman et al⁶⁸ showed that interferon and ribavirin treatment resulted in the loss of t(18;14) in 86% of HCV-infected patients with no lymphoma. Monoclonal heavy chain immunoglobulin gene rearrangements (which may predate the lymphoma) also became negative in 77% of these patients. These findings correlated well with HCV clearance. Two of the untreated patients with t(18;14) eventually developed B-cell lymphoma during follow-up.

Additionally, interferon has been reported to induce regression of HCV-related splenic lymphomas.⁶⁹

These limited available data suggest that low-grade B-cell lymphomas might regress with HCV clearance induced by interferon therapy. However, high-grade B-cell malignancies still require systemic chemotherapy.

■ OTHER SYNDROMES

Mooren ulcers, a progressive ulcerative keratitis, have been reported in association with HCV infection.⁷⁰ Interferon therapy leads to improvement of these ulcers, which recur when the treatment is stopped.⁷⁰

Interferon-induced retinopathy is seen in up to 60% of HCV-infected patients, especially in those with diabetes and hypertension.⁷¹

HCV-related neuropathies are usually associated with mixed cryoglobulinemia, although a few may be related to polyarteritis nodosa.⁷² The presentation of HCV neuropathy associated with mixed cryoglobulinemia ranges from mononeuritis multiplex to symmetric polyneuropathy that is typically

About 65% of HCV-related lymphomas have extranodal involvement


painful with prominent sensory symptoms.

The neuropathy caused by HCV-related polyarteritis nodosa is typically an asymmetrical polyneuritis with prominent motor symptoms. Polyarteritis nodosa can be life-threatening, and a combination of interferon treatment and immunosuppression in a sequential fashion along with plasmapheresis has been demonstrated to be highly effective.⁷³

In general, HCV-related neuropathies are resistant to interferon treatment alone.

Osteosclerosis, a rare disorder character-

ized by increased bone mass, was attributed in the past to intravenous drug abuse,⁷⁴ but has now been associated with HCV. Patients usually complain of painful extremities during the active phase of disease, which is marked by enhanced bone turnover.

Arthritis. HCV infection has been associated with an oligoarticular or polyarticular nonerosive arthritis that can clinically mimic rheumatoid arthritis. Rheumatoid factor may be positive, although anti-CCP antibodies have generally not been detected. 

REFERENCES

- Cacoub P, Renou C, Rosenthal E, et al. Extrahepatic manifestations associated with hepatitis C virus infection. A prospective multicenter study of 321 patients. *Medicine* 2000; 79:47–56.
- Pascual M, Perrin L, Giostra E, Schifferli JA. Hepatitis C virus in patients with cryoglobulinemia type II [letter]. *J Infect Dis* 1990; 162:569–570.
- Roudot-Thoraval F, Bastie A, Pawlotsky JM, Dhumeaux D. Epidemiological factors affecting the severity of hepatitis C virus-related liver disease: a French survey of 6,664 patients. The Study Group for the Prevalence and the Epidemiology of Hepatitis C Virus. *Hepatology* 1997; 26:485–490.
- Trepo C, Pradat P. Hepatitis C virus infection in Western Europe. *J Hepatol* 1999; 31(suppl 1):80–83.
- Zein NN, Rakela J, Krawitt EL, Reddy KR, Tominaga T, Persing DH. Hepatitis C virus genotypes in the United States: epidemiology, pathogenicity, and response to interferon therapy. Collaborative study group. *Ann Intern Med* 1996; 125:634–639.
- Misiani R, Bellavita P, Fenili D, et al. Hepatitis C virus infection in patients with essential mixed cryoglobulinemia. *Ann Intern Med* 1992; 117:573–577.
- Agnello V, Chung RT, Kaplan LM. A role for hepatitis C virus infection in type II cryoglobulinemia. *N Engl J Med* 1992; 327:1490–1495.
- Heer M, Joller-Jemelka H, Fontana A, Seefeld U, Schmid M, Amman R. Monoclonal gammopathy in chronic active hepatitis. *Liver* 1984; 4:255–263.
- Ferri C, Monti M, LaCivita L, et al. Infection of peripheral blood mononuclear cells by hepatitis C virus in mixed cryoglobulinemia. *Blood* 1993; 82:3701–3704.
- Flint M, McKeating JA. The role of the hepatitis C virus glycoproteins in infection. *Rev Med Virol* 2000; 10:101–117.
- Trejo O, Ramos-Casals M, Garcia-Carrasco M, et al. Cryoglobulinemia: study of etiologic factors and clinical and immunologic features in 443 patients from a single center. *Medicine (Baltimore)* 2001; 80:252–262.
- Verbaan H, Carlson J, Eriksson S, et al. Extrahepatic manifestations of chronic hepatitis C infection and the interrelationship between primary Sjögren's syndrome and hepatitis C in Swedish patients. *J Intern Med* 1999; 245:127–132.
- Franguel L, Musset L, Cresta P, Cacoub P, Huraux JM, Lunel F. Hepatitis C virus genotypes and subtypes in patients with hepatitis C with and without cryoglobulinemia. *J Hepatol* 1996; 25:427–432.
- Congia M, Clemente MG, Dessi C, et al. HLA class II genes in chronic hepatitis C virus-infection and associated immunological disorders. *Hepatology* 1996; 24:1338–1341.
- Vassilopoulos D, Calabrese LH. Hepatitis C virus infection and vasculitis: Implications of antiviral and immunosuppressive therapies. *Arthritis Rheum* 2002; 46:585–597.
- David WS, Peine C, Schlesinger P, Smith SA. Nonsystemic vasculitic mononeuropathy multiplex, cryoglobulinemia, and hepatitis C. *Muscle Nerve* 1996; 19:1596–1602.
- Vassilopoulos D, Calabrese LH. Rheumatic manifestations of hepatitis C infection. *Curr Rheumatol Rep* 2003; 5:200–204.
- Misiani R, Bellavita P, Fenili D, et al. Interferon alfa-2a therapy in cryoglobulinemia associated with hepatitis C virus. *N Engl J Med* 1994; 330:751–756.
- Cacoub P, Ratzin V, Myers RP, et al. Impact of treatment on extrahepatic manifestations in patients with chronic hepatitis C (erratum in *J Hepatol* 2002; 37:545). *J Hepatol* 2002; 36:812–818.
- Dammacco F, Sansonno D, Han JH, et al. Natural interferon-alpha versus its combination with 6-methyl-prednisolone in the therapy of type II mixed cryoglobulinemia: a long-term, randomized, controlled study. *Blood* 1994; 84:3336–3343.
- Zuckerman E, Keren D, Slobodin G, et al. Treatment of refractory, symptomatic hepatitis C virus related mixed cryoglobulinemia with ribavirin and Interferon alpha. *J Rheumatol* 2000; 27:2172–2178.
- Durand JM, Cacoub P, Lunel-Fabiani F, et al. Ribavirin in hepatitis C related cryoglobulinemia. *J Rheumatol* 1998; 25:1115–1117.
- Sansonno D, Cornacchiulo V, Iacobelli AR, Di Stefano R, Lospalluti M, Dammacco F. Localization of hepatitis C virus antigens in liver and skin tissues of chronic hepatitis C virus-infected patients with mixed cryoglobulinemia. *Hepatology* 1995; 21:305–312.
- Bonkovsky HL, Poh-Fitzpatrick M, Pimstone N, et al. Porphyria cutanea tarda, hepatitis C, and HFE gene mutations in North America. *Hepatology* 1998; 27:1661–1669.
- DeCastro M, Sanchez J, Herrera JF, et al. Hepatitis C virus antibodies and liver disease in patients with porphyria cutanea tarda. *Hepatology* 1993; 17:551–557.
- Sampietro M, Fracanzani AL, Corbetta N, et al. HCV type 1b in patients with chronic liver diseases and porphyria cutanea tarda (PCT) [abstract]. *Hepatology* 1995; 22:350A.
- Okano J, Horie Y, Kawasaki H, Kondo M. Interferon treatment of porphyria cutanea tarda associated with chronic hepatitis type C. *Hepatogastroenterology* 1997; 44:525–528.
- Jubert C, Pawlotsky JM, Pouget F, et al. Lichen planus and hepatitis C virus-related chronic active hepatitis. *Arch Dermatol* 1994; 130:73–76.
- Doutre MS, Beylot C, Couzigou P, et al. Lichen planus and hepatitis C virus: disappearance of lichen under interferon alpha therapy [letter]. *Dermatology* 1992; 184:229.
- Areias J, Velho GC, Cerqueira R, et al. Lichen planus and chronic hepatitis C: exacerbation of the lichen under interferon-alpha-2a therapy. *Eur J Gastroenterol Hepatol* 1996; 8:825–828.
- Johnson RJ, Gretch DR, Yamabe H, et al. Membranoproliferative glomerulonephritis associated with hepatitis C virus infection. *N Engl J Med* 1993; 328:465–470.
- Johnson RJ, Gretch DR, Couser WG, et al. Hepatitis C virus-associated glomerulonephritis. Effect of alpha-interferon therapy. *Kidney Int* 1994; 46:1700–1704.



33. Yamabe H, Johnson RJ, Gretch DR, et al. Hepatitis C virus infection and membranoproliferative glomerulonephritis in Japan. *J Am Soc Nephrol* 1995; 6:220–223.
34. Johnson RJ, Alpers CE, Gretch D, et al. Renal disease and the liver. In: Gitlin N, editor. *The Liver and Systemic Disease*. New York: Churchill Livingstone; 1997:43–58.
35. Fornasieri A, Armelloni S, Bernasconi P, et al. High binding of immunoglobulin M kappa from rheumatoid factor from type II cryoglobulins to cellular fibronectin: a mechanism of in situ immune complex glomerulonephritis. *Am J Kidney Dis* 1996; 27:476–483.
36. Lamprecht P, Lerin-Lozano C, Merz H, et al. Rituximab induces remission in refractory HCV associated cryoglobulinaemic vasculitis. *Ann Rheum Dis* 2003; 62:1230–1233.
37. Zaja F, De Vita S, Mazzaro C, et al. Efficacy and safety of rituximab in type II mixed cryoglobulinemia. *Blood* 2003; 101:3827–3834.
38. Stefanutti C, Di Giacomo S, Mareri M, et al. Immunoabsorption apheresis (Selesorb) in the treatment of chronic hepatitis C virus-related type 2 mixed cryoglobulinemia. *Transfus Apher Sci* 2003; 28:207–214.
39. Haddad J, Deny P, Munz-Gotheil C, et al. Lymphocytic sialadenitis of Sjögren's syndrome associated with chronic hepatitis C virus liver disease. *Lancet* 1992; 339:321–323.
40. Ramos-Casals M, Garcia-Carrasco M, Cervera R, et al. Hepatitis C virus infection mimicking primary Sjögren's syndrome: a clinical and immunological description of 35 cases. *Medicine* 2001; 80:1–8.
41. Koike K, Moriya K, Ishibashi K, et al. Sialadenitis histologically resembling Sjögren's syndrome in mice transgenic for hepatitis C envelope genes. *Proc Natl Acad Sci USA* 1997; 94:233–236.
42. Zein NN, Persing DH, Czaja AJ. Viral genotypes as determinants of autoimmune expression in chronic hepatitis C. *Mayo Clin Proc* 1999; 74:454–460.
43. Manns MP, Obermayer-Straub P. Viral induction of autoimmunity: mechanisms and examples in hepatology. *J Viral Hepat* 1997; 4(Suppl2):42–47.
44. Bellary S, Schiano T, Hartman G, Black M. Chronic hepatitis with combined features of autoimmune chronic hepatitis and chronic hepatitis C: favorable response to prednisone and azathioprine. *Ann Intern Med* 1995; 123:32–34.
45. Mason AL, Lau JY, Hoang N, et al. Association of diabetes mellitus and chronic hepatitis C virus infection. *Hepatology* 1999; 29:328–333.
46. Caronia S, Taylor K, Pagliaro L, et al. Further evidence for an association between non-insulin-dependent diabetes mellitus and chronic hepatitis C virus infection. *Hepatology* 1999; 30:1059–1063.
47. Zein NN, Abdulkarim AS, Weisner RH. Prevalence of diabetes mellitus in patients with end-stage liver disease due to hepatitis C, alcohol or cholestatic disease. *J Hepatol* 2000; 32:209–217.
48. Bigam DL, Pennington JJ, Carpentier A, et al. Hepatitis C-related cirrhosis: a predictor of diabetes after liver transplantation. *Hepatology* 2000; 32:87–90.
49. Zein NN. Hepatitis C and diabetes mellitus: an ongoing controversy. *Am J Gastroenterol* 1998; 93:2320–2322.
50. Shintani Y, Fujie H, Miyoshi H, et al. Hepatitis C virus infection and diabetes: direct involvement of the virus in the development of insulin resistance. *Gastroenterology* 2004; 126:840–848.
51. Fabris P, Betterle C, Greggio NA, et al. Insulin-dependent diabetes mellitus during alpha-interferon therapy for chronic viral hepatitis. *J Hepatol* 1998; 28:514–517.
52. Konrad T, Zeuzem S, Vicini P, et al. Evaluation of factors controlling glucose tolerance in patients with HCV infection before and after 4 months therapy with interferon-alpha. *Eur J Clin Invest* 2000; 30:111–121.
53. Antonelli A, Ferri C, Pampana A, et al. Thyroid disorders in chronic hepatitis C. *Am J Med* 2004; 117:10–13.
54. Deutsch M, Dourakis S, Manesis EK, et al. Thyroid abnormalities in chronic viral hepatitis and their relationship to interferon alfa therapy. *Hepatology* 1997; 26:206–210.
55. Roti E, Minelli R, Giuberti T, et al. Multiple changes in thyroid function in patients with chronic active HCV hepatitis treated with recombinant interferon-alpha. *Am J Med* 1996; 101:482–487.
56. Prummel MF, Laurberg P. Interferon-alpha and autoimmune thyroid disease. *Thyroid* 2003; 13:547–551.
57. Rasul I, Shepherd FA, Kamel-Reid S, et al. Detection of occult low-grade B-cell non-Hodgkin's lymphoma in patients with chronic hepatitis C virus infection and mixed cryoglobulinemia. *Hepatology* 1999; 20:543–547.
58. Zignego AL, Giannelli F, Marrochi ME, et al. T(14;18) translocation in chronic hepatitis C virus infection. *Hepatology* 2000; 31:474–479.
59. Ellis M, Rathaus M, Ameil A, et al. Monoclonal lymphocyte proliferation and bcl-2 rearrangements in essential mixed cryoglobulinemia. *Eur J Clin Invest* 1995; 25:833–837.
60. Luppi M, Longo G, Ferrari MG, et al. Clinico-pathological characterization of hepatitis C virus-related B-cell non-Hodgkin's lymphoma without symptomatic cryoglobulinemia. *Ann Oncol* 1998; 9:495–498.
61. De Rosa G, Gobbo ML, De Renzo A, et al. High prevalence of hepatitis C virus infection in patients with B-cell lymphoproliferative disorders in Italy. *Am J Hematol* 1997; 55:77–82.
62. Collier JD, Zanke B, Moore M, et al. No association between hepatitis C virus infection and B-cell non-Hodgkin's lymphoma. *Hepatology* 1999; 29:1259–1261.
63. Germanidis G, Haioun C, Dhumeaux D, et al. Hepatitis C infection, mixed cryoglobulinemia, and B-cell non-Hodgkin's lymphoma. *Hepatology* 1999; 30:822–823.
64. De Vita S, Sacco C, Sansonno D, et al. Characterization of overt B-cell lymphoma in patients with hepatitis C virus infection. *Blood* 1997; 90:776–82.
65. De Vita S, Zagonel V, Russo A, et al. Hepatitis C virus, non-Hodgkin's lymphomas and hepatocellular carcinoma. *Br J Cancer* 1998; 77:2032–2035.
66. De Vita S, De Re V, Sansonno D, et al. Gastric mucosa as an additional extrahepatic localization of hepatitis C virus: viral detection in gastric low-grade lymphoma associated with autoimmune disease and chronic gastritis. *Hepatology* 2000; 31:182–189.
67. Tursi A, Brandimante G, Chiarelli F, et al. Detection of HCV RNA in gastric mucosa-associated lymphoid tissue by in situ hybridization: evidence of a new extrahepatic localization of HCV with increased risk of gastric malt lymphoma. *Am J Gastroenterol* 2002; 97:1802–1806.
68. Zuckerman E, Zuckerman T, Sahar D, et al. The effect of antiviral therapy on t (14;18) translocation and immunoglobulin gene rearrangements in patients with chronic hepatitis C virus infection. *Blood* 2001; 97:1555–1559.
69. Hermine O, Lefrere F, Bronowicki JP, et al. Regression of splenic lymphoma with villous lymphocytes after treatment of hepatitis C virus infection. *N Engl J Med* 2002; 347:89–94.
70. Moazami G, Auran JD, Florakis GJ, Wilson SE, Srinivasan DB. Interferon treatment of Mooren's ulcers associated with hepatitis C. *Am J Ophthalmol* 1995; 119:365–366.
71. Kawano T, Shigehira M, Uto H, et al. Retinal complications during interferone therapy for chronic hepatitis C. *Am J Gastroenterol* 1996; 91:309–313.
72. Lidove A, Cacoub P, Maisonnobe T, et al. Hepatitis C virus infection with peripheral neuropathy is not always associated with cryoglobulinemia. *Ann Rheum Dis* 2001; 60:290–292.
73. Lunel F, Cacoub P. Treatment of autoimmune and extrahepatic manifestations of hepatitis C virus infection. *J Hepatology* 1999; 31:210–216.
74. Khosla S, Hassoun AA, Baker BK, et al. Insulin-like growth factor system abnormalities in hepatitis C-associated osteosclerosis. Potential insights into increasing bone mass in adults. *J Clin Invest* 1998; 101:2165–2173.

ADDRESS: Nizar N. Zein, MD, A30, The Cleveland Clinic Foundation, 9500 Euclid Avenue, Cleveland, OH 44195.