



**SASTRY PRAYAGA, MD**

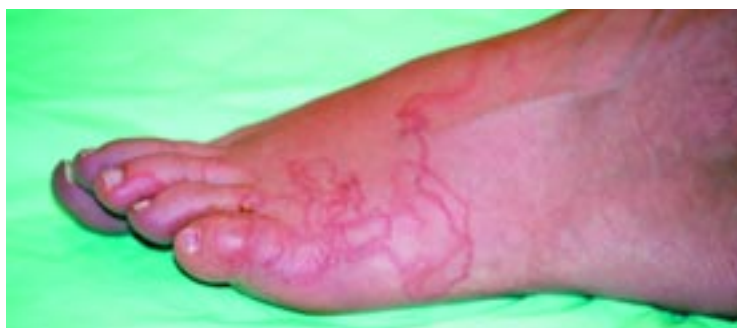Assistant Professor, State University of  
New York Upstate Medical University,  
Syracuse, NY

**GIRI B. MANNEPULI, MD**

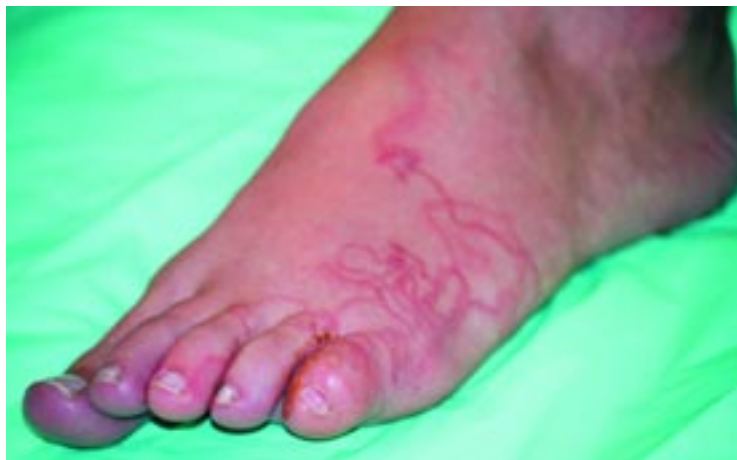Reading Convenient Care, Reading, PA

# The Clinical Picture

## A tropical souvenir not worth picking up



**FIGURE 1.** Note the serpiginous vesicular erythematous rash on the lateral surface of our patient's left foot.



**FIGURE 2.** Individual larval tracts on the dorsal surface.

**A** 22-YEAR-OLD WHITE WOMAN presents with redness, rash, and pain in her left foot for the previous 5 days. She says she has not had a fever or chills. She cannot recollect any injury or falls. Before coming to this office, she had gone to an urgent care center, where she received a prescription for cephalexin, which she has taken for the past 2 days, with no improvement.

On further questioning, she mentions that

she recently went to a beach resort in Jamaica, and that the leg and foot pain and redness started roughly a week after her return.

On examination, her left foot has mild edema of the toes, with serpiginous confluence of red papules and small vesicles tracking along the lateral border and extending onto the dorsal aspect of the foot (**FIGURE 1**). The surrounding area is erythematous, with scratch marks. The popliteal and inguinal lymph nodes are not palpable. She has no rash elsewhere.

In this patient, the history and clinical findings are typical of a creeping eruption, also known as cutaneous larva migrans. After a negative serum pregnancy test, the patient was prescribed oral thiabendazole.

At a follow-up visit 1 week later, the redness, eruption, and edema were dramatically reduced, but the pruritus subsided only after 10 days. At 2 weeks, all signs and symptoms had resolved completely.

### ■ CUTANEOUS LARVA MIGRANS

Cutaneous larva migrans—also known as creeping eruption or sandworm disease—is common among travelers returning from tropical countries.<sup>1</sup> It is caused by larvae of animal hookworms. *Ancylostoma braziliense* is the most common offender, but *A caninum* can also cause it, as can the parasite seen in gnathostomiasis.<sup>2</sup> Cutaneous larva migrans is seen in visitors from tropical countries, and it can also occur in the southeastern United States.

### ■ HOW IT IS ACQUIRED

The animal hookworms implicated in cutaneous larva migrans generally live in the



intestines of dogs and cats; and their ova are deposited in soil in the animals' feces. Humans are "dead-end" hosts for these larvae.

Most often, people pick up the infection by walking through contaminated areas barefoot or with open-type shoes, or by sitting in tainted soil or sand. When temperature and moisture are elevated in shaded areas, ova mature into larvae, which can penetrate the skin of an accidental host. The larvae then become trapped in the upper dermis. The typical serpiginous and pruritic rash appears within a week after exposure. Each larva produces a distinct, visible track, migrating up to 2 cm per day (FIGURE 2).

### ■ TREATMENT IS ADVISED

Left untreated, cutaneous larva migrans resolves spontaneously, but this can take 8 to 12 weeks.<sup>3</sup> In at least one case, the larvae have been known to migrate for up to 1 year.<sup>4</sup> But given the potential severity of common complications (eg, intense pruritus, folliculitis, impetigo, and allergic reactions such as eosinophilia),<sup>5</sup> and given the ability of effective, well-tolerated anthelmintic drugs to clear the symptoms quickly, treatment is considered mandatory in most cases.

**Freezing** the leading edge of the visible skin track with liquid nitrogen or dry ice **should be avoided**. It usually misses the larvae, which can be located several centimeters beyond the leading edge,<sup>6</sup> and the freezing can cause ulcers and blisters.<sup>7</sup>

**Thiabendazole** is effective as a topical application of a 10% to 15% solution or ointment. (Although no manufactured prepara-


tion like this is available, any pharmacist can prepare it.) Patients need to apply it to the affected areas for up to 7 days, although sometimes longer may be advisable.

An oral form of thiabendazole<sup>3,7</sup> can be given as a single dose (50 mg/kg), but efficacy improves from 68% to 89% with longer treatment (ie, up to 5 days). Nausea, dizziness, vomiting, and anorexia are relatively common, making this treatment less tolerable.

**Albendazole** 400 to 800 mg/day for 3 to 5 days is another oral option for cutaneous larva migrans.<sup>8</sup> It is better tolerated than thiabendazole. Giving a single 400-mg dose has wide variations in efficacy rates (46%-100%) and so is not advisable.

**Ivermectin** is another oral anthelmintic, with a reported efficacy of 81% to 100% when given as a single 12-mg dose.<sup>9,10</sup> It is very well tolerated, and no significant adverse effects have been reported. A small open-label study of 21 patients<sup>10</sup> compared ivermectin 12 mg vs albendazole 400 mg as single doses and found ivermectin to be superior (100% cure rate with ivermectin vs 46% with albendazole).

### ■ PREVENTION

When visiting tropical countries, especially beaches and sandy, moist areas, it is best to wear shoes that completely cover the feet. Also, one should avoid sitting or lying on bare sand, even if on a towel. Deworming of pets is recommended.<sup>6</sup> Hand-washing after cleaning pets and dealing with pet excrement is important. Walking and sitting directly on tide-swept portions of beach is better. 

**Walking barefoot and lying on the sand at the beach raise the risk**

### ■ REFERENCES

1. Caumes E, Carriere J, Guernonprez G, Bricaire F, Danis M, Gentilini M. Dermatoses associated with travel to tropical countries: a prospective study of the diagnosis and management of 269 patients presenting to a tropical disease unit. *Clin Infect Dis* 1995; 20:542-548.
2. Beaver PC. Larva migrans: a review. *Exp Parasitol* 1956; 5:587-621.
3. Katz R, Ziegler J, Blank H. The natural course of creeping eruption and treatment with thiabendazole. *Arch Dermatol* 1965; 91:420-424.
4. Chaudhry AZ, Longworth DL. Cutaneous manifestation of intestinal helminthic infections. *Dermatol Clin* 1989; 7:275-290.
5. Jelinek T, Maiwald H, Northdurft HD, Loscher T. Cutaneous larva migrans in travelers: synopsis of histories, symptoms and treatment of 98 patients. *Clin Infect Dis* 1994; 19:1062-1066.
6. Caumes E. Treatment of cutaneous larva migrans. *Clin Infect Dis* 2000; 30:811-814.
7. Katz R, Hood WR. Topical thiabendazole for creeping eruption. *Arch Dermatol* 1966; 94:643-645.
8. Jones SK, Reynolds NJ, Oliwiecki S, Harman RRM. Oral albendazole for the treatment of cutaneous larva migrans. *Br J Dermatol* 1990; 122:99-101.
9. Van den Enden E, Stevens A, Van Gompel A. Treatment of cutaneous larva migrans. *N Engl J Med* 1998; 339:1246-1247.
10. Caumes E, Carriere J, Datry A, Danis M, Gentilini M. A randomized trial of ivermectin versus albendazole for the treatment of cutaneous larva migrans. *Am J Trop Med Hyg* 1993; 49:641-644.

ADDRESS: Sastry Prayaga, MD, State University of New York Upstate Medical University, 750 E. Adams Street, CWB, Rm. 322, Syracuse, NY 13210; e-mail [sprayaga@pol.net](mailto:sprayaga@pol.net).